

Stefan Schaeren
Bernard Jeanneret

Atlantoaxial osteoarthritis: case series and review of the literature

Received: 12 January 2004
Revised: 17 August 2004
Accepted: 27 October 2004
Published online: 4 February 2005
© Springer-Verlag 2005

S. Schaeren (✉) · B. Jeanneret
University Hospital, Dept. of Orthopedic
Surgery, Spitalstr. 21, Basel, Switzerland
E-mail: sschaeren@uhbs.ch
Tel.: +41-61-2652525
Fax: +41-61-2657819

Abstract The intention of this study is to present our experience in the surgical treatment of painful atlantoaxial osteoarthritis (AAOA) and review the literature on this subject. Osteoarthritis of the atlantoaxial joints is more common than is generally suspected. It has a prevalence between 5 and 18%. Only a minority of patients becomes symptomatic suffering from severe suboccipital pain, irradiating into the occiput, vertex and sometimes as far as the eyes. Most often, these patients can successfully be treated conservatively. Some of these patients however require operative treatment. The study includes five patients with painful AAOA (one posttraumatic, four idiopathic) not responding to conservative treatment for a minimum of six months. Rheumatoid arthritis was excluded. All but one patient were female and all but one patient were over 50 years old (mean

64 years). The origin of pain was confirmed by diagnostic C1–C2 facet blocks in all patients. The patients were treated with a C1–C2 transarticular screw fixation and Gallie type fusion. Patients were followed clinically and radiologically for a minimum of 24 months. Mean follow-up was 38 months (24–48). In all patients the typical pain disappeared immediately after surgery and has not reoccurred. Pain intensity on the VAS decreased from 100 to 34. At the latest follow-up radiologically solid fusion and stable implants were found in all cases. All five patients would undergo this surgery for the same condition again. C1–C2 fusion effectively relieves occipitocervical pain in AAOA non responsive to conservative treatment.

Keywords Cervical spine · Osteoarthritis · Spinal fusion · Therapy · Vertebrae

Introduction

Osteoarthritis of the atlantoaxial joints has been recognised as a distinct cause of occasionally severe occipitocervical pain in the elderly. Patients typically complain about unilateral neck pain occurring with the slightest head rotation. The pain ascends unilaterally to the occiput, the parietal skull and sometimes even to the eye. In the English literature only few reports exist on the diagnosis and the treatment of this pathology.

The purpose of this paper is to review the literature and to report our own experience.

Review of the literature

Atlantoaxial osteoarthritis (AAOA) can cause severe occipital neck pain as documented in the literature [5, 11, 12, 17]. The prevalence ranges from 5.4% in the sixth to 18.2% in the ninth decade of life [19]. Most patients are female (74%) presenting with a unilateral arthritis (76%) [11]. Head rotation is usually markedly reduced.

The pain ascends unilaterally to the occiput, the parietal skull and sometimes even towards frontal into the eye. Patients also report visual problems often leading to an ophthalmologic work up. They also frequently report a painful audible crepitation with head rotation. The stabbing pain thereby produced can be so severe, that some patients support their head with both hands while rotating.

Despite the clear visible degenerative changes in standard radiographs or CT scan diagnosis is often delayed.

Dreyfuss et al. [4] showed that an experimental increase in pressure in the atlantoaxial joints by injections caused similar patterns of pain as seen in C1/C2 osteoarthritis and thereby confirmed the role of the atlantoaxial joint as a pain generator.

Conservative treatment consisting of NSAIDs, soft collar and gentle traction can reduce pain to a tolerable level. Steroid injections into the arthritic joint may be very successful for a limited period of time [2].

In the literature there are only few previous reports on the outcome of surgical treatment (see Table 1). Whitesides and McDonalds [18] were the first to report a successful treatment with arthrodesis for degenerative AAOA. In the series of Harata et al. [12] only 1 of 31 patients underwent atlantoaxial arthrodesis. Halla and Hardin [11] also reported only on 1 patient. Joseph and Kumar [15] successfully treated four patients with a Gallie fusion. Star et al. [17] reported surgical treatment of five out of nine patients. Performing Gallie/Brooks arthrodesis four patients had an excellent result and one patient who developed a pseudarthrosis was rated fair. After successful rearthrodesis a good result was finally reported.

In a review on surgery in the degenerative cervical spine Grob [9] reported results of eight patients in whom transarticular screw fixation and fusion C1/C2 was performed. With a minimum follow-up of five years solid fusion and significant pain reduction were achieved.

In the only long term follow-up (mean 86 months) Ghanayem et al. [8] presented 15 patients with AAOA. Four patients also had atlantoaxial instability one of

them with a spastic tetraparesis. The patients were treated with a modified Gallie Type fusion. In two patients the fusion was extended caudally and in one patient an occipitocervical fusion was performed. Thirteen patients had an excellent result with solid fusion, one patient with a pseudarthrosis had a fair result and one patient died four days postoperatively from a cardiopulmonary arrest.

Materials and methods

Between July 2000 and July 2002 five patients (four women, one man) with occipitocervical pain and osteoarthritis of the atlantoaxial joints were treated by the senior author (Bernard Jeanneret) with an arthrodesis. The average age of the patients was 64.2 years (46–77 years).

The patients were followed for a minimum of 24 months. Patients were examined preoperatively and followed by the surgeon. The first author (Stefan Schären) was not involved in the treatment and independently performed the latest follow-up.

Radiographs made before surgery, immediately postoperatively and at the latest follow up were available for all patients.

Indication for the arthrodesis was pain not responding to conservative treatment consisting of analgesics, immobilization with a collar and physiotherapy. The average duration of symptoms was 16 months (9–36 months). The patients had been referred by the primary care provider after failed conservative treatment. Rheumatoid arthritis was excluded by clinical and laboratory findings in all patients.

The diagnosis was confirmed by an open mouth view showing typical narrowing of the atlantoaxial joint space. A CT scan was performed in four patients to rule out a tumor or to assess the anatomical details of C1/C2 prior to screw fixation. Flexion–extension views did not reveal atlantoaxial instability in any case.

In order to confirm the origin of pain fluoroscopically guided diagnostic facet blocks C1–C2 were performed in

Table 1 Review of the literature

Authors	Patient number	Surgical treatment	Follow-up (months)	Results
Ehni and Benner [5]	7	Three patients: two rhizotomy, one rhizotomy and C1/C2 arthrodesis	> 24	Good
Star et al. [17]	9	Five patients: two Brooks fusions, three Gallie fusions	22	Four good, one fair with pseudarthrosis
Joseph and Kumar [15]	4	Four patients: Gallie fusion	24	Good
Ghanayem et al. [8]	15	15 patients: 12 modified Gallie fusions, 1 C1/C3, 1 C1/C4, 1 C0/C2	86	13 excellent, 1 pseudarthrosis
Grob [9]	8	Eight patients: C1–C2 screw fixation	60	Good
Fuentes et al. [6]	3	Three patients: two facet blocks, one C1/C2 fusion with graft and clamp	2	Good

all patients showing immediate temporary relief of symptoms.

The operative technique consisted of a posterior midline approach to the upper cervical spine and a C1–C2 transarticular screw fixation as described by Magerl and Seemann [16]. A corticocancellous graft from the iliac crest was fixed between the posterior arch of the atlas and the spinous process of C2 as described by Gallie [7]. Postoperatively all patients were mobilized with a Philadelphia collar for three months.

After a minimum follow-up time of 24 months all patients were examined clinically and radiologically. The following data were collected: location of pain, intensity of pain according to a visual analog scale (VAS; 0 = no pain; 100 = maximum pain), head rotation, pain medication and status of activity.

Results were graded according to the modified Robinson criteria[8]: excellent if the patient had no pain and activity was unlimited; good if residual pain persisted, requiring only occasional use of non-narcotic pain medication and slight reduction in activity; fair if there was moderate pain, necessitating regular non-narcotic pain medication, limiting daily activity; poor if there was no pain relief and symptoms were equal or worse than preoperative.

Patients were asked—Would you have the same treatment again if you had the same condition?—to indicate their treatment satisfaction and could answer—definitely yes, probably yes, not sure, probably not or definitely not—according to the NASS Patient Satisfaction Index [3].

Transoral and lateral radiographs were used to assess the fusion. Fusion was considered solid when a bony bridge between the posterior arch of the atlas and the

spinous process of C2 was present and all implants were stable.

Results

The patients presented with pain localized to the upper cervical spine ascending to the occiput and in one patient radiating frontally behind the eyes (Table 2). The pain was predominantly on the side of the osteoarthritic joint. Head rotation was extremely painful and almost completely blocked in three patients and restricted more than 50% in the remaining two patients. Pain intensity on the VAS was maximal with 100 in all five patients. All patients were neurologically intact.

There were no intra- or postoperative complications. Mean operative time was 89 min (75–100). Mean blood loss was 290 cc (100–600).

All patients reported that they had felt immediate relief of their incapacitating occipitocervical pain postoperatively and had remained free of this particular stabbing pain since then. Pain intensity on the VAS at follow-up was 34 on average (0–80).

Patient no. 3 described a completely new pain of different, dull character, which had started about 18 months postoperatively and was responsible for the pain intensity of 80 on the VAS. She was still satisfied with the procedure since her original preoperative pain had disappeared. Her radiographs showed solid fusion between C1 and C2 but marked progression of degenerative changes from C3 to C5. She was rated as fair with significant new pain limiting her daily activity and regularly requiring nonsteroidal anti-inflammatory medication.

Table 2 Data of the five patients

Patient	Age/ sex	Symptoms	Radiological findings	Follow-up (months)	VAS preoperative/ follow-up	Head rotation left/0/right (°)		Results/ comments
						Preoperative	Follow-up	
1	73/f	Left sided occipital pain extending frontally	Primary arthritis C1/C2 left	48	100/0	0/0/30	45/0/50	Excellent
2	56/f	Left sided neck pain and headache	Primary arthritis C1/C2 left	46	100/50	40/0/50	20/0/10	Good, tension at cervicothoracic junction
3	77/f	Occipital pain right side, extending to the ear	Primary arthritis C1/C2 right	44	100/80	Painfully blocked	20/0/20	Fair, new pain at lower cervical spine
4	73/f	Neck pain and headache left side extending to the shoulder with rotation	Primary arthritis C1/C2 left	28	100/0	10/0/10	50/0/30	Excellent
5	44/m	Neck pain and headache left side	Secondary arthritis C1/C2 left	24	100/40	45/0/20	45/0/20	Good, intermitten tension at cervicothoracic junction

Patients no. 2 and no. 5 presented with residual discomfort in form of tension and stiffness at the cervico-thoracic junction. They did not use analgesics regularly and activity was unlimited, thus they were rated as good.

The two patients (no. 1 and no. 4) who had complete resolution of pain and were fully active were graded excellent.

Head rotation improved in three patients, remained unchanged in one patient and decreased in one patient (Table 2). The limited range of motion especially in head rotation due to the arthrodesis was not considered a handicap since head rotation had been significantly reduced already preoperatively.

All five patients answered the questions if they would undergo this surgery if they had the same condition with "definitely yes".

Radiologically we found solid fusion in form of a continuous bony bridge between the posterior arch of the atlas and the spinous process of C2 and stable

implants (transarticular screws and C1–C2 wires) in all cases at the latest follow-up (Fig. 1)

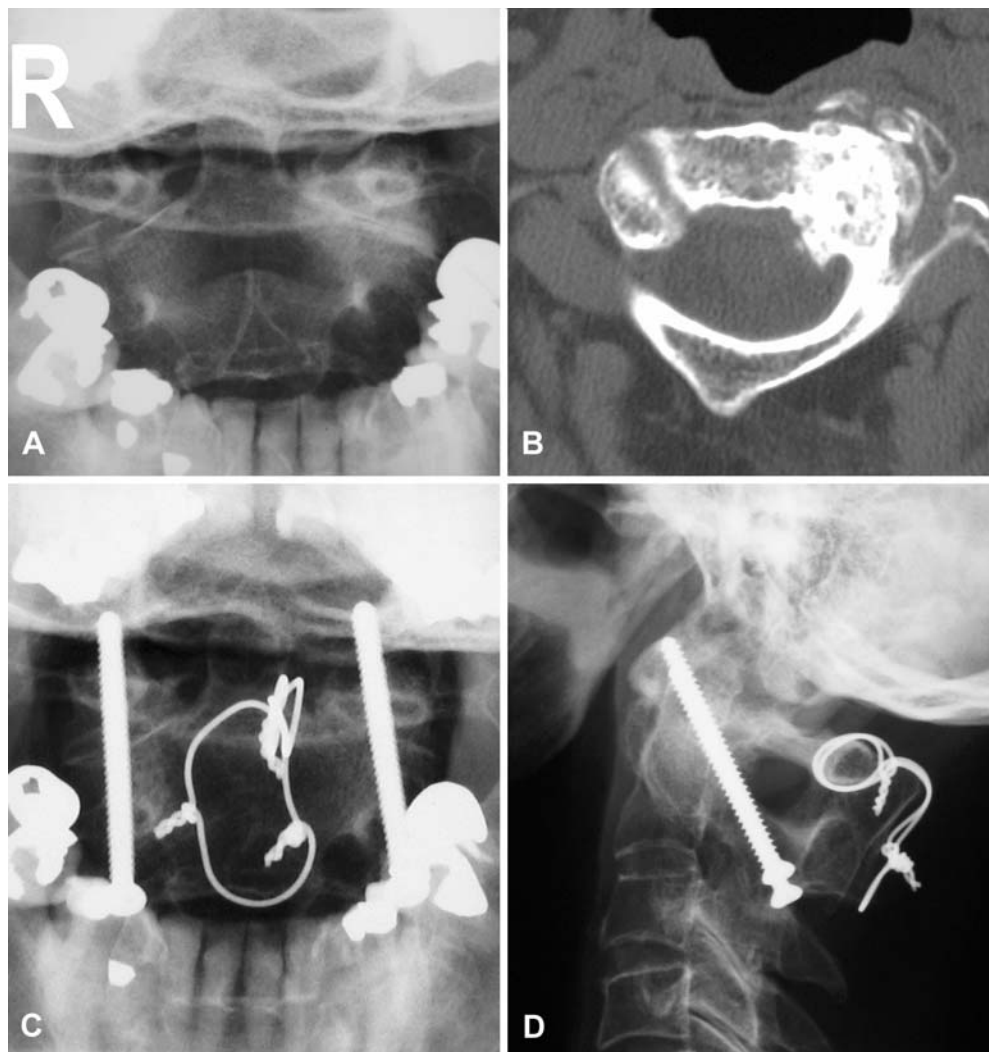
Discussion

The clinical symptoms in AAOA with very typical mostly unilateral occipitocervical pain aggravated by head rotation as reported in literature [5, 17] were seen in all of our patients.

In contrast to the series of Ghanayem et al. [8] no atlantoaxial instability and no neurological deficits were present in our patients.

The diagnosis is primarily made on a standard transoral atlas view, showing the narrowing of the C1–C2 joint space. A bone scan showing increased uptake can also help to establish the diagnosis but is not mandatory. A CT scan can be performed to rule out a tumor or to assess the anatomical details of C1/C2 prior to screw fixation.

Fig. 1 A Seventy-three-year-old female (patient 4); transoral radiograph shows obliteration of atlantoaxial joint space on the left side. B CT scan demonstrates severe destruction of left C1–C2 joint. C, D Transarticular screw fixation C1–C2 and posterior fusion was performed. Transoral and lateral radiographs demonstrate solid fusion and stable implants 24 months postoperatively. The clinical result was excellent



In all five patients we confirmed the clinical and radiological diagnosis by intraarticular C1–C2 blocks. Aprill et al. [1] performed diagnostic blocks in 34 patients with occipital pain with clinical features presumptively suggestive of a C1–C2 origin. Only 21 patients showed complete temporary relief following infiltration demonstrating that the clinical features alone had only a predictive value of 60%. Based on these findings we think it is important to try to verify the origin of pain before proceeding to surgery.

All five patients in our series showed a unilateral arthritis as has been reported by other authors [11, 19]. They were treated with a C1–C2 transarticular screw fixation and Gallie type fusion, which is the author's preference, since it provides good stability and fusion rates [10]. All of our patients showed solid fusion.

In our series four out of five patients were female. Also in the literature women seem to be predominantly affected; 104 of 150 published cases are female. The reason for this difference is not clear. In the knee joint sex-related differences in cartilage volume are reported to have an influence on the development of osteoarthritis [14]. However no comparable data for the cervical spine exist.

Star et al. [17] described a greater than 50% loss of cervical rotation as pathognomonic clinical sign. We had similar findings in our series. Head rotation was markedly restricted or even blocked to avoid pain exacerbation. Although fusion between C1 and C2 reduces head rotation by 30°–60° [13], we found that three of our

patients regained motion in the lower cervical spine once free of their pain. Only in patient no. 2 rotation decreased postoperatively, which was attributed to residual pain at the cervicothoracic junction.

In summary all of our patients were very satisfied with the result and would undergo the same surgery again if they had the same condition. Our own results thus confirm the literature showing that intractable occipitocervical pain due to AAOA can be successfully relieved by arthrodesis.

Conclusion

Symptomatic osteoarthritis of the lateral atlantoaxial joints is seen predominantly in elderly women. The clinical symptom is mostly unilateral neck pain, which is typically triggered by rotation and can ascend to the occiput and towards frontal. Radiologically the degenerative changes of the C1–C2 joints are clearly visible on a standard atlas transoral view. A CT scan may be helpful in determining the extent of osteophyte formation and for planning of surgery. Verification of the origin of pain by intraarticular blocks is recommended. The treatment is conservative as long as it is effective and the symptoms are tolerable. Surgery in form of an atlantoaxial arthrodesis is indicated if pain is intractable. The arthrodesis leads to immediate and persistent relief of the symptoms.

References

1. Aprill C, Axinn MJ, Bogduk N (2002) Occipital headaches stemming from the lateral atlanto-axial (C1-2) joint. *Cephalalgia* 22:15–22
2. Chevrot A, Cermakova E, Vallee C, Chancelier MD, Chemla N, Rousselin B, Langer-Cherbit A (1995) C1-2 arthrography. *Skeletal Radiol* 24:425–429
3. Daltroy LH, Cats-Baril WL, Katz JN, Fossel AH, Liang MH (1996) The North American spine society lumbar spine outcome assessment instrument: reliability and validity tests. *Spine* 21:741–749
4. Dreyfuss P, Michaelsen M, Fletcher D (1994) Atlanto-occipital and lateral atlanto-axial joint pain patterns. *Spine* 19:1125–1131
5. Ehni G, Benner B (1984) Occipital neuralgia and the C1-2 arthrosis syndrome. *J Neurosurg* 61:961–965
6. Fuentes S, Bouillot P, Palombi O, Manera L, Desgeorges M (2001) Atlanto-axial lateral mass osteoarthritis. Three case reports and review of the literature. *Neurochirurgie* 47:51–54
7. Gallie WE (1939) Fractures and dislocations of the cervical spine. *Am J Surg* 46:495–499
8. Ghanayem AJ, Leventhal M, Bohlman HH (1996) Osteoarthrosis of the atlanto-axial joints. Long-term follow-up after treatment with arthrodesis. *J Bone Joint Surg Am* 78:1300–1307
9. Grob D (1998) Surgery in the degenerative cervical spine. *Spine* 23:2674–2683
10. Grob D, Jeanneret B, Aebi M, Markwalder TM (1991) Atlanto-axial fusion with transarticular screw fixation. *J Bone Joint Surg Br* 73:972–976
11. Halla JT, Hardin JG Jr (1987) Atlantoaxial (C1–C2) facet joint osteoarthritis: a distinctive clinical syndrome. *Arthritis Rheum* 30:577–582
12. Harata S, Tohno S, Kawagishi T (1981) Osteoarthritis of the atlanto-axial joint. *Int Orthop* 5:277–282
13. Jeanneret B (1990) Simultaneous rotation and lateral inclination of the head: a clinical sign of limitation of rotation at the atlantoaxial joint. In: Louis R, Weidner A (eds) *Cervical spine II*. Springer, New York, pp 235–240
14. Jones G, Glisson M, Hynes K, Cicuttini F (2000) Sex and site differences in cartilage development: a possible explanation for variations in knee osteoarthritis in later life. *Arthritis Rheum* 43:2543–2549

-
15. Joseph B, Kumar B (1994) Gallie's fusion for atlantoaxial arthrosis with occipital neuralgia. *Spine* 19:454–455
 16. Magerl F, Seemann PS (1986) Stable posterior fusion of the atlas and axis by transarticular screw fixation. In: Kehr P, Weidner A (eds) *Cervical spine*. Springer, Wien, pp 322–327
 17. Star MJ, Curd JG, Thorne RP (1992) Atlantoaxial lateral mass osteoarthritis. A frequently overlooked cause of severe occipitocervical pain. *Spine* 17:S71–S76
 18. Whitesides TE Jr, McDonald AP (1978) Degenerative arthritis of the occipitocervical region—signs and symptoms. *Orthop Trans* 2:32
 19. Zapletal J, de Valois JC (1997) Radiologic prevalence of advanced lateral C1–C2 osteoarthritis. *Spine* 22:2511–2513