

Undifferentiated sarcoma arising in the brain, 23 years after curative treatment of an ependymoma

Silvia Hofer¹, Harald Seeger², Tamara Rordorf¹, Alexander Knuth¹ and Robert Janzer²¹Department of Oncology, University Hospital, Zürich, Switzerland; ²Department of Neuropathology, University Hospital, Zürich, Switzerland

Medulloblastoma and ependymoma account for about 30% of all newly diagnosed brain tumours in children. As curative treatment options are available since many years, our attention has to focus on late effects in survivors of brain tumours. Neurocognitive sequelae are of concern and more rarely development of secondary tumours.

We report on a 37-year-old patient who was treated 23 years earlier for a large supratentorial right tempo-

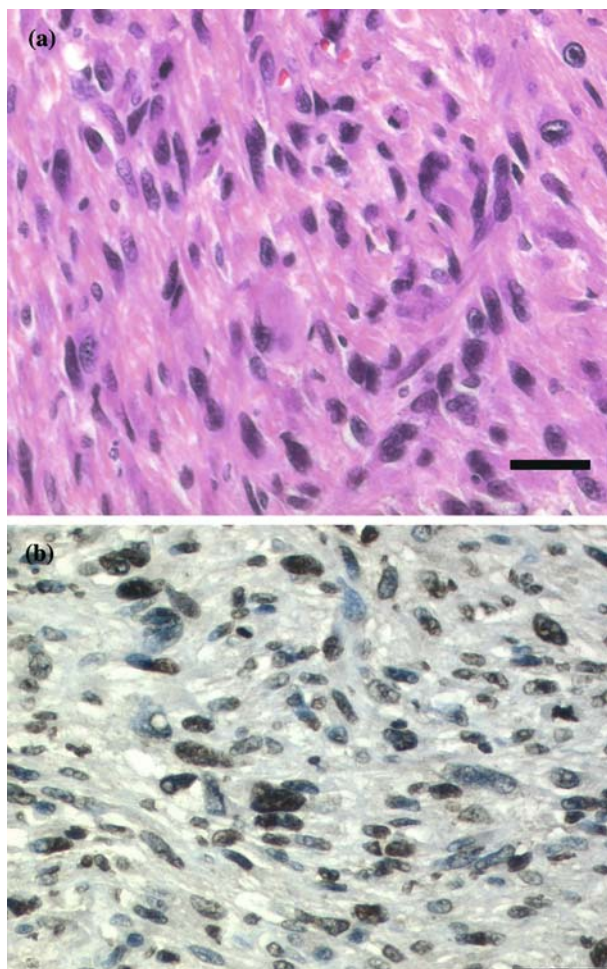


Figure 1. H&E staining (scale bar 50 μ m) depicting undifferentiated sarcoma (FNCLCC grade 3) Moderately to highly cellular tumour consisting of pleomorphic undifferentiated often spindle shaped neoplastic cells with frequent mitosis and a proliferative index of up to 60% (a). Large areas of necrosis (<50% of total specimen). Immunohistochemically tumour cells positive for MyoD1 (b) and negative for EMA, CD34, CD99, desmin, smooth muscle alpha-actin, myogenin and cytokeratins. Staining for glial fibrillary acidic protein (GFAP) and S-100 only labelled reactive astrocytes.

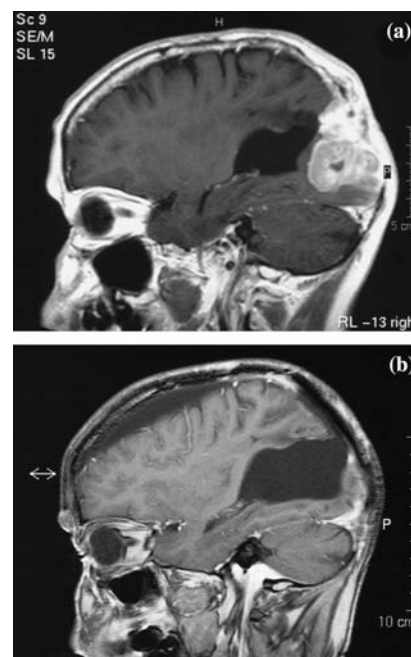


Figure 2. MRI obtained at diagnosis of a secondary tumour in the previously irradiated field (a). Complete remission 16 months later after subtotal resection of an undifferentiated sarcoma and seven cycles of epirubicin and ifosfamide (b).

occipital ependymoma (8 × 7 × 5 cm). This ependymoma was cured with gross-total resection, involved field radiation (54Gy, conventional fractionation) and maintenance chemotherapy (VM-26 and CCNU) for 1 year. After a latency period of more than 20 years an undifferentiated sarcoma with a high proliferation-index (Figure 1a, b) developed in the previously irradiated field involving skull and scalp (Figure 2a). A complete remission of this secondary malignant tumour could be obtained by subtotal surgery followed by seven cycles of epirubicin and ifosfamide (Figure 2b). Our patient experiences good quality of life, 18 months after diagnosis of his secondary tumour. He runs his own toyshop, is able to drive a car and has normal social contacts. Neuropsychological assessment after his last treatment revealed left sided neglect and minor learning deficits for visual patterns.

Address for offprints: Silvia Hofer, MD, Department of Oncology, University Hospital Zürich Rämistrasse 100, 8091 Zürich, Switzerland; Tel.: 0041-1-255-1111; Fax: 0041-1-255-4548; E-mail: silvia.hofer@usz.ch