

Eur Arch Otorhinolaryngol (2010) 267:317–320  
DOI 10.1007/s00405-009-1143-0

## CASE REPORT

# Removal of unusual, large high-velocity metallic maxillary sinus foreign bodies by a modified free bone flap technique

Paolo Scolozzi · Armen Momjian · Tommaso Lombardi

Received: 18 July 2009 / Accepted: 22 October 2009 / Published online: 6 November 2009  
© Springer-Verlag 2009

**Abstract** Metallic foreign bodies are rarely found in the maxillary sinus, and usually they have a dental origin. Potential complications related to foreign bodies include recurrent sinusitis, rhinolith formation, cutaneous fistula, chemical poisoning, facial neuralgic pain and even malignancies. Two main surgical approaches are currently used for the removal of foreign bodies in the maxillary sinus: the bone flap and the endoscopic sinus techniques. We are reporting two unusual cases of large high-velocity foreign bodies removed by a modified maxillary lateral antrotomy, with free bone flap repositioning and fixation with a titanium miniplate.

**Keywords** Maxillary sinus · Foreign bodies · Bone flap

## Introduction

Maxillary sinus foreign bodies are occasionally encountered in ENT and maxillofacial practice [1–11]. Teeth,

dental roots, endodontic material, dental amalgam fillings, and dental implants are the most frequent foreign bodies reported in the literature [1–11]. High-velocity missile or atypical non-missile foreign bodies are rarely found in civilian traumas [2, 4, 7]. Removal of foreign bodies, irrespective of the type of material, is the recommended treatment, especially to avoid potential complications such as acute and/or chronic sinusitis, chemical or mechanical irritations and even malignancies that could develop over the long term [1, 8, 12]. Although the classical Caldwell-Luc approach has been the most commonly used technique for removal of maxillary sinus foreign bodies for decades, this technique has been progressively replaced by endoscopic procedures and by “bone lid” flap techniques [8, 13].

We report two unusual cases of large high-velocity maxillary metallic foreign bodies (a bullet from Kalashnikov automatic rifle and the fragment of an axe), removed by a modified free bone flap technique.

## Patient reports

### Patient 1

A 24-year-old Somalian man presented at the Oral and Maxillofacial Department of the Hôpitaux Universitaires in Geneva (Switzerland), in January 2009 complaining of left hemifacial pain of 1-year duration. He had been struck in the nose by an unknown object during riots in Mogadiscio. In October 2008, he fled Somalia and arrived in Geneva as a political refugee. Physical examination was normal, and no entry wound was noticed. Waters radiograph and CT-scan revealed a probable rifle bullet in the left maxillary sinus together with maxillary sinusitis (Fig. 1a, b). In November 2008, the patient underwent under general

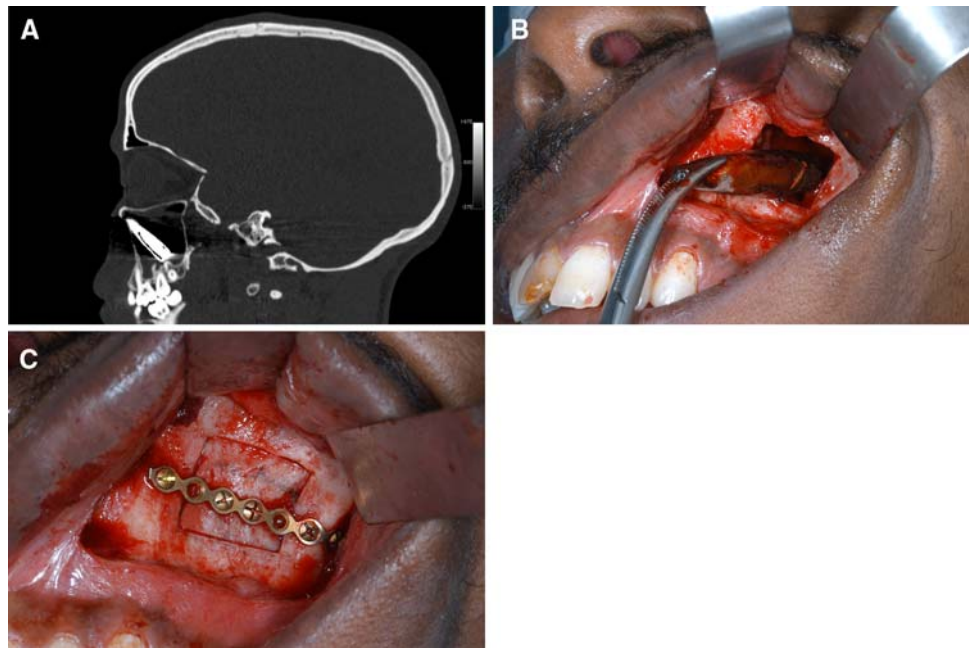
---

P. Scolozzi (✉) · A. Momjian  
Service of Oral and Maxillofacial Surgery,  
Department of Surgery, Hôpitaux Universitaires de Genève,  
1211 Geneva, Switzerland  
e-mail: scolozzi-paolo@diogenes.hcuge.ch

P. Scolozzi  
Division of Oral and Maxillofacial Surgery,  
Department of Otolaryngology/Head and Neck Surgery,  
Centre Hospitalier Universitaire Vaudois,  
1011 Lausanne, Switzerland

T. Lombardi  
Laboratory of Oral Histopathology, Division of Stomatology,  
Faculty of Medicine, 19, Rue Barthélemy-Menn,  
1205 Geneva, Switzerland

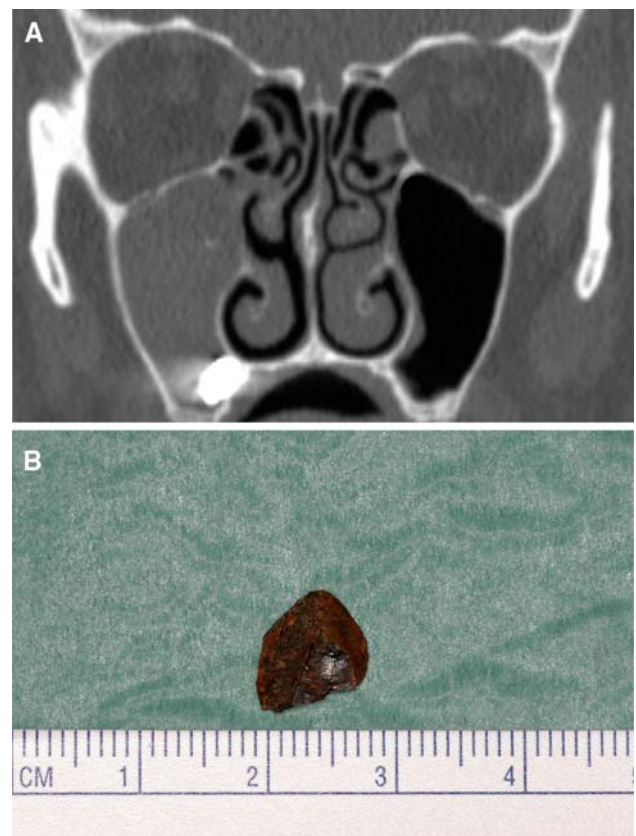
**Fig. 1** Patient 1: **a** Preoperative sagittal CT-scan images revealing the bullet within the left maxillary sinus. **b** Intraoperative view showing the bullet (size 33 mm × 5 mm × 5 mm) removed by the lateral antrotomy. **c** Intraoperative view showing the bone flap replaced and fixed by a titanium plate



anaesthesia, the removal of the bullet by a lateral antrotomy with repositioning and fixation of the bone flap with an AO 1.3 mm straight plate and three monocortical screws according to the technique described by Scolozzi et al. [8] (Fig. 1c) The inflamed sinus mucosa was sent for histopathological examination, which revealed a chronic sinusitis together with foci of squamous metaplasia (Fig. 1). The bullet measured 33 mm × 5 mm × 5 mm (Fig. 1). Postoperative Waters radiograph confirmed the removal of the bullet. The postoperative course was uneventful.

#### Patient 2

A 50-year-old man presented at the emergency room of the Centre Hospitalier Universitaire Vaudois in Lausanne (Switzerland) in October 2006 after he was struck accidentally by an axe's fragment while he was cutting wood. Physical examination demonstrated a small left paranasal punctate cutaneous entry wound. Water radiograph and CT-scan revealed a metallic foreign body located in the left maxillary antral floor together with a hemo sinus (Fig. 2a). On October 31, the patient underwent, under general anaesthesia, the removal of the metallic foreign body by a lateral antrotomy with repositioning and fixation of the bone flap with an AO 1.0 mm straight plate and three monocortical screws according to the technique described by Scolozzi et al. [8] The metallic fragment measured 1 cm × 1 cm × 1 cm (Fig. 2b). The postoperative course was uneventful.



**Fig. 2** Patient 2: **a** Preoperative coronal CT-scan image showing a metallic foreign body lodged in the floor of the right maxillary sinus. **b** Macroscopical view of the metallic fragment measuring 1 cm × 1 cm × 1 cm

## Discussion

Metallic foreign bodies in the maxillary sinuses are not common [1, 5–9, 11]. Since their widespread use in dental surgery in the middle of 1980s, dental implants have probably become the most commonly reported metallic foreign bodies found in the maxillary sinuses [5, 11]. Conversely, reports of penetrating projectiles such as bullets or other unusual objects in the paranasal sinuses are primarily anecdotal [2, 4, 7]. Although there is a consensus concerning the need for removing the foreign bodies, even when they are asymptomatic, there is no international consensus on what is the best surgical approach to use [13]. The natural course of metallic foreign bodies in the maxillary sinuses is still speculative and a source of debate. However, according to previous clinical reports, long-term complications may include ciliary insufficiency, recurrent sinusitis, rhinolith formation, cutaneous fistula, chemical poisoning, and facial neuralgic pain [1, 2, 12]. Chemical and mechanical irritations are the two principal mechanisms responsible for the chronic irritation of the sinus mucosa. Compression of the mucosa in the long term causes decubitus ulcers, which may predispose to mycotic and bacterial superinfections, epithelial metaplasia, and/or even dysplasia. Chemical toxicity results from the different material's components and can be either systemic or local. Systemic toxicity is essentially related to heavy metals such as lead and depends on the duration of the exposure and the age of the person [12]. Children are more prone to develop lead poisoning, because they absorb several times the percentage ingested compared with adults [12]. Also, their brains are more plastic and even limited exposures may negatively affect motor and cognitive cerebral development. This probably explains why cases of lead poisoning after gunshot injuries reported in the literature have concerned predominately children and only rarely adults [12]. Nevertheless, the most common local pathological condition is metallosis, which is defined as aseptic fibrosis, local necrosis secondary to metal corrosion, and release of debris. The metallic particles are incorporated by the cells via endocytosis, thus potentially leading to chromosomal alterations responsible for neoplastic changes [1, 12].

First described for the treatment of chronic maxillary sinusitis, the Caldwell-Luc procedure has rapidly gained popularity [13]. It has become a versatile technique that is used increasingly as a surgical approach *inter alia* for removal of maxillary sinus foreign bodies. The slow and inexorable decline in use of this technique is largely due to the relatively high rate of complications reported in the literature, and the development of alternatives techniques associated with less morbidity. As previously described, the two main surgical techniques currently used for

removal of maxillary sinus foreign bodies are the bone flap technique and sinonasal endoscopy [2, 5, 6, 8–10]. The bone flap technique is germane to the sinus lift approach, a technique first described by Boyne and James in 1980 for grafting of the maxillary sinus to allow further dental implant placement [14]. This technique encompasses two variations—vascularized or not-vascularized—depending on the preservation or not of a periosteal or mucosal flap. In 2009, we described a modified bone lip approach with fixation of the free bone window flap by a titanium plate that was used for the two presented cases [8]. We found that this technique allowed for a panoramic view of the maxillary antral floor, which is of paramount importance for removal of large foreign bodies under good anatomical control. Alternatively, although endoscopy is a minimally invasive technique that could enable a good global view of the maxillary sinus, it is not really appropriate for removal of large foreign bodies, such as those presented in present report. Thus far, according to the literature, all cases of endoscopic removal of maxillary sinus metallic foreign bodies have been performed by a canine fossa approach and not by an inferior or middle meatus antrostomy [2, 3, 5, 6, 11].

In our opinion, this particular approach is not really as conservative as the “classical” nasal approach in terms of bone defect. In fact, leaving an open hole in the bone has the potential of allowing for some amount of cheek soft tissue retraction and collapse through the bony defect. This could be responsible for some facial pain and discomfort in the long term. Moreover, the largest cross-section of foreign body removable by this technique has been found to be 6 mm [6]. This means that beyond this diameter, it is probably highly advisable to use a bone flap technique.

In conclusion, there is strong evidence for complications associated with retained foreign bodies. Therefore, early surgical exploration with removal of the material should be performed, irrespective of the material. For large metallic foreign bodies (>1 cm in diameter), a bone flap technique is preferred over the endoscopic techniques.

**Conflict of interest statement** All authors declare that there is no financial relationship with any type of organization that might have sponsored this research.

## References

1. Birmmeyer G (1963) On late sequelae of metallic foreign bodies in the region of the paranasal sinuses. *Z Laryngol Rhinol Otol* 42:778–785
2. Brinson GM, Senior BA, Yarbrough WG (2004) Endoscopic management of retained airgun projectiles in the paranasal sinuses. *Otolaryngol Head Neck Surg* 130:25–30
3. Connolly AA, White P (1995) How I do it: transantral endoscopic removal of maxillary sinus foreign body. *J Otolaryngol* 24:73–74

4. Mahajan M, Shah N (2004) Accidental lodgement of an air gun pellet in the maxillary sinus of a 6-year old girl: a case report. *Dent Traumatol* 20:178–180
5. Nakamura N, Mitsuyasu T, Ohishi M (2004) Endoscopic removal of a dental implant displaced into the maxillary sinus: technical note. *Int J Oral Maxillofac Surg* 33:195–197
6. Pagella F, Emanuelli E, Castelnovo P (1999) Endoscopic extraction of a metal foreign body from the maxillary sinus. *Laryngoscope* 109:339–342
7. Ragel BT, McCafferty RR (2008) Indirect gunshot wound to the head. *Acta Neurochir* 150:1311–1312
8. Scolozzi P, Martinez A, Lombardi T, Jaques B (2009) Lateral antrotomy as a surgical approach for maxillary sinus: a modified technique with free bone flap repositioning and fixation with a titanium plate. *J Oral Maxillofac Surg* 67:689–692
9. Smith JL II, Emko P (2007) Management of a maxillary sinus foreign body (dental bur). *Ear Nose Throat J* 86:677–678
10. Uckan S, Buchbinder D (2003) Sinus lift approach for the retrieval of root fragments from the maxillary sinus. *Int J Oral Maxillofac Surg* 32:87–90
11. Varol A, Turker N, Goker K, Basa S (2006) Endoscopic retrieval of dental implants from the maxillary sinus. *Int J Oral Maxillofac Implants* 21:801–804
12. Kikano GE, Stange KC (1992) Lead poisoning in a child after a gunshot injury. *J Fam Pract* 34:498–500, 502, 504
13. Kennedy DW (1997) Sinus surgery: a century of controversy. *Laryngoscope* 107:1–5
14. Boyne PJ, James RA (1980) Grafting of the maxillary sinus floor with autogenous marrow and bone. *J Oral Surg* 38:613–616