

# The Role of Surgical Hip Dislocation in the Treatment of Acetabular and Femoral Head Fractures

Marius Keel<sup>1</sup>, Karim Eid<sup>1</sup>, Balz Isler<sup>2</sup>, Otmar Trentz<sup>1</sup>, Wolfgang Ertel<sup>3</sup>

## Abstract

**Background and Purpose:** Surgical hip dislocation by trochanteric flip osteotomy facilitates access to acetabular and femoral head fractures. Furthermore, it allows evaluation of cartilage damage and vascularity of the femoral head. In this study the potential benefits of this procedure for improved fracture management and for prognostic assessment were investigated.

**Patients and Methods:** From July 1997 to October 1999, 20 selected patients with displaced acetabular fractures ( $n = 12$ ), femoral head fractures ( $n = 7$ ), or combined injuries ( $n = 1$ ) were included. Inclusion criteria for acetabular fractures were either displaced posterior wall fragments with cranial extension or complex acetabular fractures involving a displaced transverse fracture line. Open reduction and fixation of either complex acetabular fractures or femoral head fractures were carried out through Kocher-Langenbeck approach, trochanteric flip osteotomy, and complete surgical hip dislocation. Additionally, the extent of cartilage destruction and femoral head perfusion were assessed.

**Results:** Anatomic reduction ( $\leq 1$  mm displacement) of acetabular fractures was achieved in 69% of patients and good reduction ( $\leq 3$  mm) in 31%. In patients with acetabular fractures, severe cartilage destruction of the acetabulum was found in 38% and of the femoral head in 15%, while patients with isolated femoral head fractures revealed severe cartilage damage of the femoral head in 57%. Arterial bleeding from the femoral head, tested by drilling, was observed in all patients. Secondary dislocation of the trochanteric osteotomy occurred in one patient and made refixation necessary. Patients

were reexamined at least 2 years after intervention. 77% of patients with acetabular fractures and all patients with femoral head fractures showed good or excellent results after  $32.6 \pm 6.1$  months according to the functional score of D'Aubigné & Postel.

**Conclusion:** Surgical hip dislocation allows adequate reconstruction of complex acetabular and femoral head fractures and intraoperative evaluation of local cartilage damage and femoral head perfusion.

## Key Words

Acetabular fracture · Femoral head fracture · Trochanteric flip osteotomy · Surgical hip dislocation · Femoral head perfusion

Eur J Trauma 2005;31:138–47

DOI 10.1007/s00068-005-1403-7

## Introduction

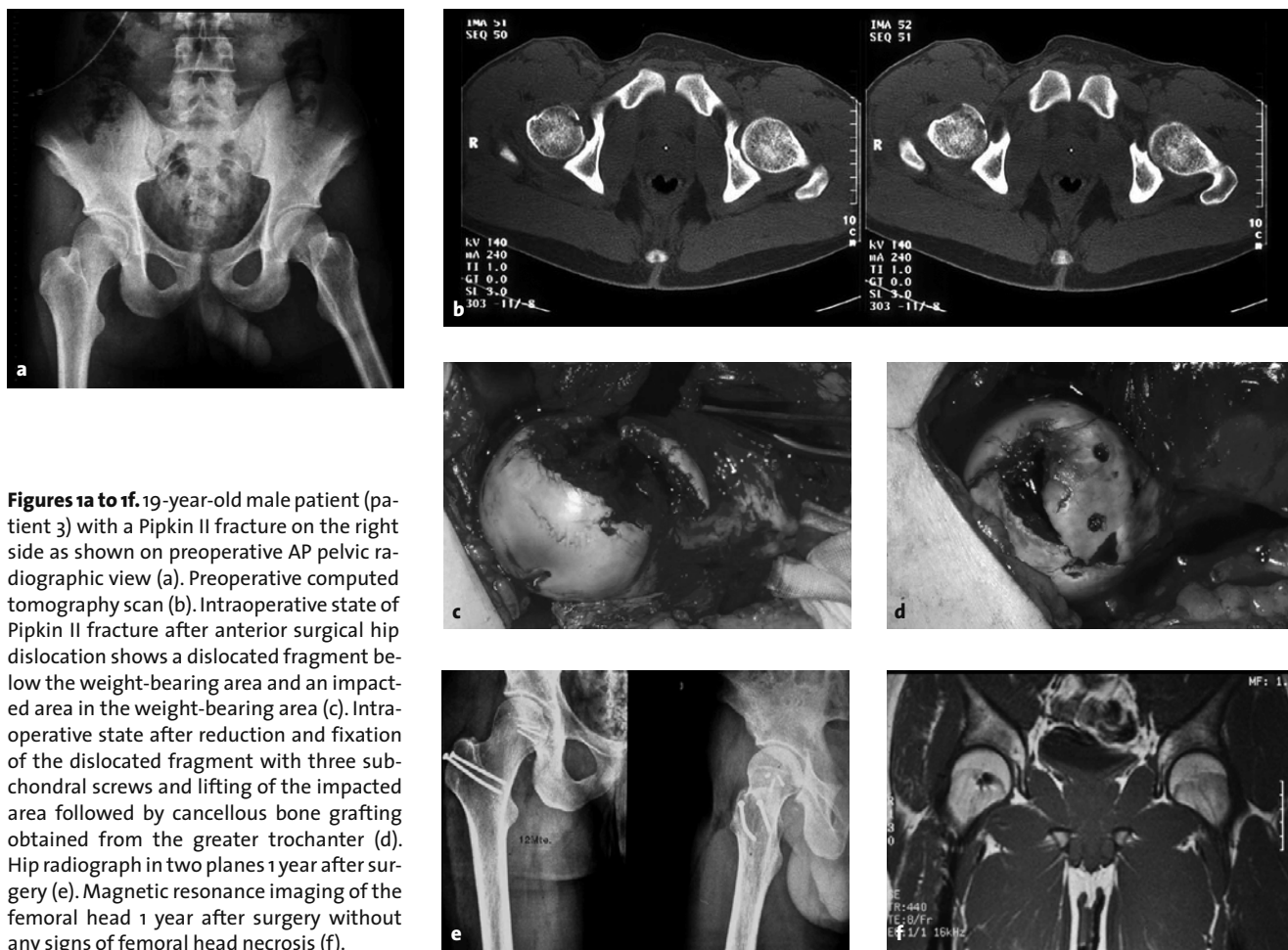The long-term results of displaced acetabular fractures are related to the quality of reduction within the weight-bearing articular surface and congruency of the hip joint [1–13]. The appropriate approach as well as adequate visualization or at least palpation of the fracture lines play a key role to achieve anatomic reduction of displaced acetabular fractures [3]. Since standard posterior approaches provide only limited access to the acetabulum particularly in cranially extended posterior wall fractures and displaced transverse fractures, sometimes extensile approaches such as the extended ilio-

<sup>1</sup> Division of Trauma Surgery, University Hospital Zurich, Zurich, Switzerland,

<sup>2</sup> Department of Orthopedic Surgery, Kantonsspital Winterthur, Winterthur, Switzerland,

<sup>3</sup> Department of Trauma and Plastic Surgery, University Hospital Benjamin Franklin, Free University of Berlin, Berlin, Germany.

Received: February 1, 2004; revision accepted: January 10, 2005.



**Figures 1a to 1f.** 19-year-old male patient (patient 3) with a Pipkin II fracture on the right side as shown on preoperative AP pelvic radiographic view (a). Preoperative computed tomography scan (b). Intraoperative state of Pipkin II fracture after anterior surgical hip dislocation shows a dislocated fragment below the weight-bearing area and an impacted area in the weight-bearing area (c). Intraoperative state after reduction and fixation of the dislocated fragment with three subchondral screws and lifting of the impacted area followed by cancellous bone grafting obtained from the greater trochanter (d). Hip radiograph in two planes 1 year after surgery (e). Magnetic resonance imaging of the femoral head 1 year after surgery without any signs of femoral head necrosis (f).

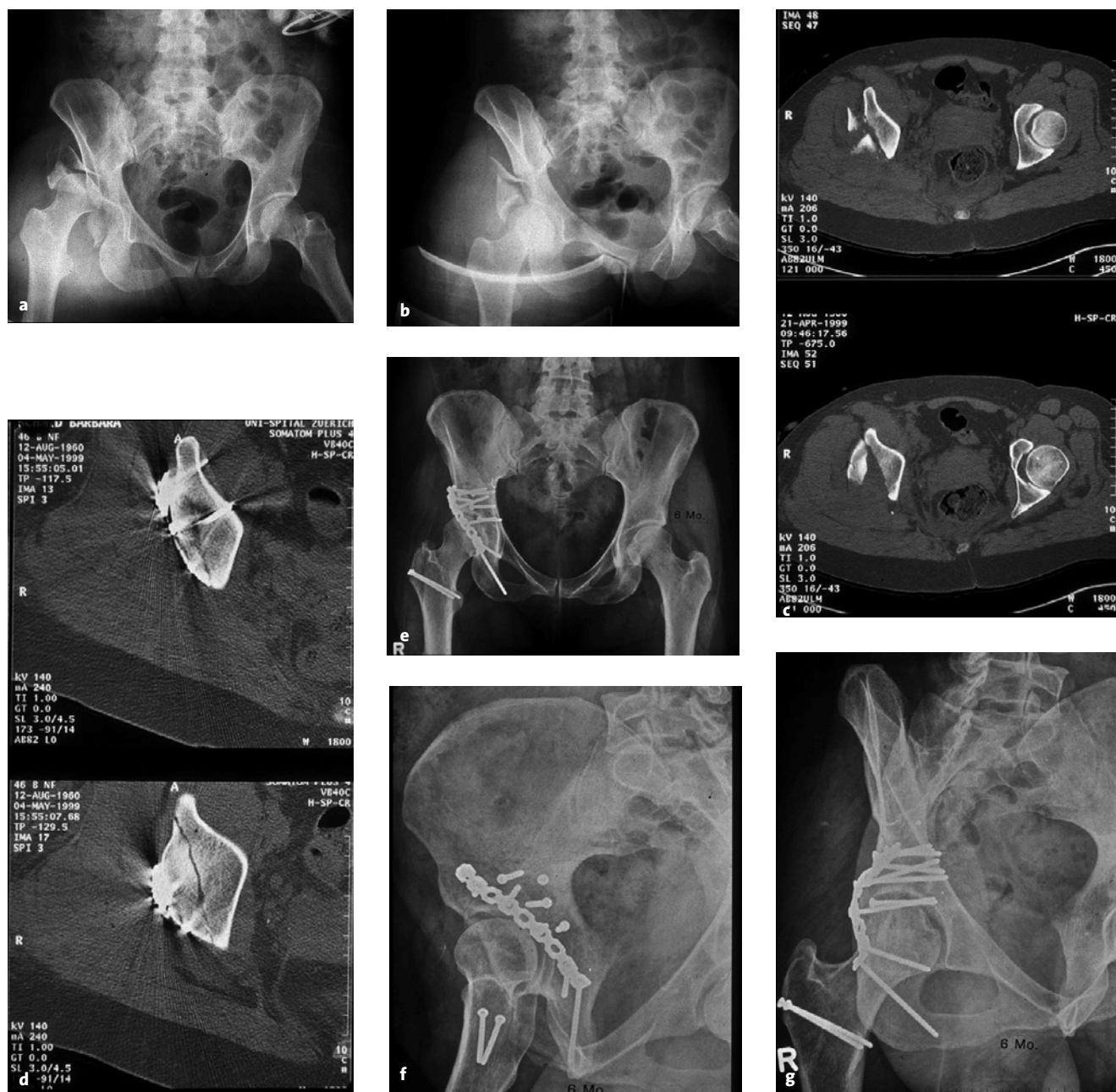
femoral or triradiate approach are used [2, 4–7, 9, 11]. However, these extensile approaches result in significantly increased patient morbidity.

As for complex acetabular fractures, the choice of surgical approach for femoral head fractures is controversially discussed in the literature [14–18]. In contrast to the commonly used Smith-Peterson approach, the posterior approach combined with a trochanteric flip osteotomy allows additional reduction and fixation of femoral neck fractures and posterior wall fractures (Pipkin III/IV, [19]). Furthermore, through excellent visualization and exposure it facilitates reduction and fixation of posteriorly located head fractures otherwise difficult to address through a Smith-Peterson or a Kocher-Langenbeck approach. Preoperative X-rays including CT scan are sometimes not conclusive whether the head fracture can be operated through an anterior approach. Swiontkowski et al. [17] reported that the initial intention of internal fixation of femoral head fragments could not be carried out

in some patients because of limited intraoperative view to the femoral head fragments with consequent removal of those pieces.

Long-term results of acetabular and femoral head fractures depend upon anatomic reduction, cartilage destruction caused by the injury, and the potentially impaired femoral head perfusion leading either to arthritis or avascular necrosis (AVN). To adequately predict the prognosis and for quality assessments, it is valuable to evaluate local cartilage damage and femoral head perfusion. This is hardly possible with simple approaches to the acetabulum.

This study investigates the benefit of better visualization of the hip joint through an extension of the Kocher-Langenbeck approach and anterior surgical dislocation of the femoral head for improved fracture management in complex acetabular and femoral head fractures as well as for evaluation of local cartilage damage and femoral head perfusion.



**Figures 2a to 2g.** 39-year-old female patient (patient 17) with an extended posterior wall fracture on the right side as shown on preoperative AP pelvic radiographic view before closed reduction (a). Preoperative AP pelvic view after closed reduction (b). Cranial extension of the comminuted fracture visualized by a computed tomography scan (c). Postoperative computed tomography scan with optimal reconstructive result (d). AP pelvic radiographs at 6 months (e). Iliac oblique view at 6 months (f). Obturator oblique view at 6 months (g).

**Patients and Methods**

**Patients**

From July 1997 to October 1999, 43 patients with acetabular or femoral head fractures were treated operatively. Of these, 20 patients were included for the study based on the type of acetabular fracture or the presence

of a femoral head fracture. Inclusion criteria were displaced posterior wall fragments with cranial fracture extension, displaced transverse fractures, and T-shaped fractures. Acetabular fractures were classified according to the classification of Letournel & Judet [4, 5]; femoral head fractures according to the scheme of Pipkin

[19]. Moreover, all patients were primarily treated according to the Advanced Trauma Life Support guidelines (ATLS) [20] and our standard trauma protocol [21, 22]. Hip dislocation was managed in all patients by emergent closed reduction in general anesthesia. In the case of persistent instability after closed reduction or central displacement, a supracondylar femoral extension was applied until definitive surgical treatment was performed.

### Surgical Approach and Perioperative Management

For surgical exposure, the patient was positioned in a lateral decubitus position. The typical incision of the Kocher-Langenbeck approach was used. To gain access to the retroacetabular area, tendons of the short external rotator muscles were cut with preservation of the deep branch of the medial circumflex artery while protecting the sciatic nerve. A plane osteotomy was performed with an oscillating saw along a line between the posterior insertion of the medial gluteus and the lateral vastus muscles, leaving a medallion of the greater trochanter with a thickness of 1.5 cm as previously described [23–26]. This trochanteric osteotomy was first described by Mercati et al. in 1972 for difficult total hip replacement and revision surgery [24] and was recently advocated for cranial extension and muscle protection in acetabular fracture fixation [26]. If necessary, an anterior Z-shaped capsulotomy was performed and the femoral head was completely dislocated for evaluation of articular fractures, displacement of the anterior column, and cartilage damage, for removal of interposed intraarticular fragments, assessment of femoral head perfusion by drilling, and open reduction and internal fixation of Pipkin fractures [19] (Figures 1a to 1f). Reattachment of the greater trochanter was secured with two small-fragment lag screws.

Quality of reduction was rated by intraoperative assessment through the senior author, anteroposterior (AP) radiographs, and/or postoperative CT scan and was considered anatomic with  $\leq 1$  mm dislocation, good with 2–3 mm, and poor with  $> 3$  mm displacement [7, 8] (Figures 2a to 2g).

Acetabular and femoral head cartilage damages were graded intraoperatively by the senior author as mild, moderate, or severe damage according to Steinberg et al. with some modifications [27]. Superficial fibrillation and slight irregularity of the surface was graded as mild damage; moderate fibrillation, thinning of the cartilage (impression), or small ( $< 5$  mm) complete

erosion to the bone outside the weight-bearing region of the acetabulum or distal to the fovea of the femoral head (Pipkin I) as moderate damage; marked thinning of cartilage with areas of complete erosion to bone  $\geq 5$  mm or in the weight-bearing region of the acetabulum, or superior to the fovea of the femoral head (Pipkin II) as severe damage.

The vascularity of the femoral head was assessed by drilling one or two holes in the superior quadrant of the femoral head with a 2.0-mm drill [28]. The drill bit was then removed and the head was examined for the presence or absence of active bleeding after 1–2 min. The quality of bleeding from the femoral head was graded in none, delayed, or immediate [28].

Prophylactic medication for heterotopic ossification was given in twelve patients (except for multiply injured patients), consisting of indomethacin (50 mg orally three times a day) for 3 months. Eight patients received a preoperative radiation therapy with 8 Gy of the operative field [29], of which six patients received both indomethacin and irradiation. In six patients with multiple injuries radiation therapy was not practicable, and six patients refused preoperative irradiation (see Table 2).

### Follow-Up

All 20 patients were kept at partial weight-bearing for 12 weeks postoperatively, followed by a standard rehabilitation protocol. The long-term outcome was evaluated in all 20 patients using the score of Thompson & Epstein [15] regarding clinical and radiologic criteria and the functional hip score of D'Aubigné & Postel [30] after a minimum follow-up of 2 years. Heterotopic ossification was classified according to Brooker et al. on AP pelvic radiographs [31].

### Results

Acetabular fractures included three extended posterior wall fractures, one displaced pure transverse fracture, six transverse fractures with posterior wall, one T-shaped fracture, and one both-column fracture (Table 1). There were two Pipkin I fractures, five Pipkin II fractures, and one Pipkin IV fracture (subfoveal fracture associated with transverse acetabular and a posterior wall fracture; Table 1). Patients' age was  $37 \pm 11$  years (mean  $\pm$  SD [standard deviation]; range, 19–60 years; Table 1). The injury mechanisms included car accidents ( $n = 10$ ), motorcycle accidents ( $n = 4$ ), fall from great height ( $n = 2$ ), and there were one crush injury, one bicycle, one pedestrian, and one avalanche accident. Six patients (30%)

**Table 1.** Patients. F: female; ISS: Injury Severity Score [32]; M: male.

No.	Age (years)	Sex	Injury mechanism	Fracture type	Direction of hip dislocation	Reduction <sup>a</sup> and traction	ISS	Associated injuries	Associated pelvic injuries
1	44	M	Fall from height	Extended posterior wall	Posterior	300	34	Thoracic injury, renal injury, extremity fracture	Vertical shear (C); isolated posterior hip dislocation
2	45	F	Car	Transverse, posterior wall	Posterior	120	10	Extremity fracture	No
3	19	M	Car	Pipkin II	Posterior	90	13	Facial fractures, extremity fractures	No
4	40	F	Car	Transverse, posterior wall	Posterior	240; traction	19	Thoracic injury, extremity fracture	No
5	42	M	Car	Transverse, posterior wall	Posterior	80	9	No	No
6	45	M	Crush	Transverse	No	No	29	Head injury, thoracic injury	Vertical shear (C)
7	30	M	Car	Pipkin II	Posterior	210	9	No	No
8	60	M	Fall from height	Both-column	No	No	9	Extremity fracture	No
9	27	F	Car	Transverse, posterior wall	Posterior	160; traction	9	Extremity fracture	No
10	54	M	Pedestrian	T-shaped	Central	120; traction	9	No	No
11	30	F	Bicycle	Transverse, posterior wall	Posterior	190; traction	10	Extremity fracture	No
12	38	M	Avalanche	Pipkin II	Posterior	280	9	No	Open-book (B1); transverse fracture with posterior wall
13	29	M	Motorcycle	Pipkin II	No	No	34	Head injury	No
14	22	M	Car	Pipkin I	Posterior	90	14	Facial fracture, thoracic injury	No
15	41	M	Car	Pipkin I	Posterior	130	14	Facial fracture	No
16	31	M	Motorcycle	Pipkin IV: subfoveal, transverse, posterior wall	Posterior	70; traction	9	No	No
17	39	F	Motorcycle	Extended posterior wall	Posterior	150; traction	10	Facial fracture	No
18	46	M	Motorcycle	Extended posterior wall	Posterior	130; traction	34	Thoracic injury, multiple extremity fractures, soft-tissue injuries	No
19	21	M	Car	Pipkin II	Posterior	240; traction	48	Head injury, thoracic injury, liver injury, spine injury	No
20	29	F	Car	Transverse, posterior wall	No	No	9	No	No

<sup>a</sup> time from accident to closed reduction in emergency room in minutes

had multiple injuries with an average ISS (Injury Severity Score [32]) of  $33 \pm 9$  points (range, 19–48 points). Three patients (15%) sustained an associated pelvic ring injury; one type B1 and two type C pelvic ring disruptions according to the classification of Tile & Pennal [33] (Table 1).

Eight acetabular and seven femoral head fractures were associated with posterior hip dislocation at the time of admission. One acetabular fracture showed a central displacement. Furthermore, patient 1 had a posterior hip dislocation at the contralateral side without bony lesions. Patient 12 suffered a posterior hip dislocation with a severely displaced transverse and posterior wall acetabular fracture on the contralateral side, which

was reconstructed through an anterior and posterior approach without surgical hip dislocation. The mean interval from time of accident to reduction of the hip in the emergency room was  $163 \pm 73$  min (range, 70–300 min; Table 1). Because of persistent joint instability after closed reduction a supracondylar femoral traction was applied in eight patients until definitive surgical treatment, which was carried out  $6 \pm 3$  days after admission (range, 2–12 days; Table 1).

In eight patients with acetabular fractures (extended posterior wall fractures [ $n = 3$ ], transverse fracture with posterior wall fracture [included patient with Pipkin IV fracture;  $n = 5$ ]) and seven patients with isolated femoral head fractures a single Kocher-Langenbeck approach

**Table 2.** Operative management and intraoperative state. HO: heterotopic ossification; NSAID: nonsteroidal anti-inflammatory drug (indomethacin 3 × 50 mg/day); RX: radiation therapy.

No.	Additional approach	Operation time (min)	Blood loss (ml)	Acetabular cartilage damage	Femoral head cartilage damage	Femoral head perfusion	HO prophylaxis	Brooker class	Local complications
1	No	140	500	Severe	Severe	Immediate	NSAID, RX	II	No
2	No	140	700	Severe	Mild	Delayed	No	III	Displacement of the trochanteric flip
3	No	155	150	Mild	Severe	Immediate	No	0	No
4	No	155	300	Moderate	Mild	Immediate	NSAID	II	No
5	No	135	400	Moderate	Mild	Delayed	NSAID, RX	0	Trochanteric irritation
6	Ilioinguinal	185	500	Mild	Mild	Immediate	No	0	Displacement of anterior column
7	No	140	250	Mild	Moderate	Delayed	RX	I	No
8	Ilioinguinal	350	1,500	Mild	Mild	Immediate	NSAID	I	No
9	Ilioinguinal	350	2,000	Mild	Mild	Immediate	NSAID	0	No
10	Ilioinguinal	480	2,500	Severe	Mild	Immediate	NSAID, RX	I	No
11	Ilioinguinal	330	1,200	Moderate	Severe	Delayed	NSAID	0	No
12	No	140	400	Mild	Severe	Immediate	NSAID	I	No
13	No	130	600	Mild	Severe	Immediate	NSAID	I	No
14	No	130	200	Mild	Moderate	Immediate	No	II	No
15	No	90	150	Mild	Moderate	Delayed	RX	I	No
16	No	160	800	Moderate	Moderate	Immediate	NSAID, RX	0	No
17	No	180	1,000	Mild	Mild	Immediate	NSAID, RX	I	No
18	No	195	1,200	Severe	Moderate	Delayed	No	III	No
19	No	120	700	Mild	Severe	Immediate	No	I	No
20	No	240	1,500	Severe	Moderate	Delayed	NSAID, RX	0	No

was used (Table 2). In these 15 patients operative time averaged  $152 \pm 35$  min (range, 90–240 min). The mean blood loss was  $584 \pm 388$  ml (range, 150–1,500 ml; Table 2). In the five patients with Pipkin II fractures open reduction and internal fixation of femoral head fragments were carried out. In the two patients with a Pipkin I lesion and in the patient with a Pipkin IV lesion the small femoral head fragments were resected after surgical hip dislocation (Table 2).

In four patients (transverse fracture with posterior wall [ $n = 2$ ], T-shaped fracture [ $n = 1$ ], both-column fracture [ $n = 1$ ]) an additional ilioinguinal approach in addition to the Kocher-Langenbeck approach was carried out during the same anesthesia because of an insufficient screw fixation of the anterior column (patients 8 and 9) or an insufficient reduction of the anterior column caused by interposed fragments (patients 10 and 11). In this group the mean operative time was  $378 \pm 69$  min (range, 330–480 min), the mean blood loss was  $1,800 \pm 572$  ml (range, 1,200–2,500 ml; Table 2).

Further, patient 6 (transverse fracture, vertical shear injury with symphysis disruption and disruption of the iliosacral joint) had to be reoperated 2 weeks after pri-

mary reconstruction of the acetabulum through an additional ilioinguinal approach because of a secondary displacement of the anterior column.

In 69% of all patients with acetabular fractures the reduction was anatomic and in 31% good (Table 3). In all patients with Pipkin II fractures anatomic reduction was achieved. Poor reduction was not observed in any patient.

In 38% of patients with acetabular fractures the acetabulum revealed severe, in 31% moderate, and in 31% mild cartilage damage, while the femoral head showed severe cartilage damage in 15%, moderate in 23%, and mild in 62% (Table 2). By contrast, isolated femoral head fractures showed only mild cartilage lesions of the acetabulum, whereas the femoral head revealed severe cartilage damage in 57% of patients and moderate cartilage damage in 43% (Table 2).

Arterial bleeding of the femoral head was tested by drilling. In 65% of all patients an immediate and in 35% a delayed bleeding was observed (Table 2). One patient with delayed bleeding (patient 18) developed AVN 1.5 years after injury.

A primary healing of trochanteric flip osteotomy could be documented in 19 cases. In one patient the tro-

chanteric flip dislocated 11 days after surgery and had to be refixed. One patient was irritated by the screws in the greater trochanter. A removal was carried out 2 years after primary surgery. 13 patients (65%) developed heterotopic ossification. In eight patients Brooker class I, in three patients Brooker class II, and in two patients Brooker class III heterotopic ossification was noted [31]. There were no class IV heterotopic ossification. All patients with class III and two of the three class II heterotopic ossification had no preoperative irradiation. Additional acute or delayed postoperative complications were not observed.

13 out of the 20 patients (65%) showed good or excellent results according to the Thompson-Epstein score [15] (Table 3), 25% (n = 5) fair, and 10% (n = 2) poor results (mean follow-up,  $32.6 \pm 6.1$  months; range, 24–44 months). Fair results were seen in patients with transverse fractures with posterior wall (n = 2), pure transverse fracture (n = 1), T-shaped fracture (n = 1), and a Pipkin II fracture (n = 1). One patient with a transverse fracture with associated fracture of the posterior wall and one patient with an extended comminuted posterior wall fracture showed poor results. Only in two of five patients with fair results the reduction was rated as anatomic intraoperatively and in X-rays, whereas the other patients with fair results and the two patients with poor results showed a displacement of 2–3 mm (Table 3). According to the functional score of D'Aubigné & Postel [30] a higher rate of excellent or good results (85%) could be observed than with the Thompson-Epstein score [15], whereas fair results were seen in 10% (n = 2) and poor results in 5% (n = 1; Table 3). Patient 18 with a poor result developed AVN and needed a total hip arthroplasty 2 years after trauma. Three patients with a primary sciatic nerve injury showed a complete recovery within the observation period (Table 3). 80% of the patients returned to their primary professional occupation (Table 3).

### Discussion

The appropriate approach with adequate visualization of the fracture lines plays a key role to achieve anatomic

**Table 3.** Relationship between quality of reduction and long-term results.

No.	Reduction	Follow-up time (months)	Score of Thompson & Epstein [15]	Score of D'Aubigné & Postel [30]	Reintegration in job (%)
1	Anatomic	36	Good	Good	100
2	Good	36	Poor	Fair	50
3	Anatomic	36	Excellent	Excellent	100
4	Anatomic	28	Fair	Good	50
5	Good	26	Fair	Fair	80
6	Anatomic	29	Fair	Good	100
7	Anatomic	31	Good	Excellent	100
8	Anatomic	29	Good	Good	100
9	Anatomic	27	Excellent	Excellent	100
10	Good	26	Fair	Good	100
11	Anatomic	36	Good	Excellent	100
12	Anatomic	44	Good	Good	100
13	Anatomic	42	Fair	Good	100
14	Fragment excision	41	Excellent	Excellent	100
15	Fragment excision	40	Good	Good	100
16	Anatomic	34	Good	Good	100
17	Anatomic	33	Excellent	Excellent	100
18	Good	24	Poor	Poor	0
19	Anatomic	27	Good	Excellent	100
20	Anatomic	26	Good	Good	100

reduction of displaced acetabular fractures [3]. The additional trochanteric flip osteotomy to the Kocher-Langenbeck approach and surgical hip dislocation allow access to the supraacetabular portion of the iliac wing and in part to the anterior column and permit extended visualization, easier reduction, and fixation of complex acetabular fractures [26]. In addition, this technique represents an alternative to the Smith-Peterson approach for femoral head fractures, particularly if they are located posteriorly. Furthermore, it allows reduction and fixation of additional posterior wall fractures (Pipkin IV), which could not be addressed through a Smith-Peterson or simple Kocher-Langenbeck.

The percentage of anatomic and good reduction of complex acetabular fractures (100%) in this study was higher compared to the results of Matta et al. (90%) [7, 8], Letournel & Judet (74%) [5], and Mayo (90%) [9]. In line with the high rate of anatomic and good reductions, 77% of all patients with acetabular fractures showed excellent or good long-term results according to the functional score of D'Aubigné & Postel [30]. These results are similar to the outcome in the series of Letournel & Judet (80%) [5], Matta et al. (78%) [7, 8], and Mayo (75%) [9]. The mean follow-up time in the present study is longer compared to studies by Matta et al.

[7, 8] and Mayo [9] and shorter compared to that of Letournel & Judet [5]. The discrepancy of a higher percentage of anatomic and good reductions compared to the series of Letournel & Judet but similar outcomes could be due to the small number of patients in the series or an inadequate sensitivity of the outcome scores, in which the level of pain dominates the rating. Furthermore, patient 18 with a poor result according to the functional score of D'Aubigné & Postel [30] showed severe acetabular cartilage damage and a delayed femoral head perfusion intraoperatively and developed AVN of the femoral head. In addition, mobilization of this patient was complicated by associated severe limb injuries aggravating the poor outcome. Isolated femoral head fractures showed excellent or good results in all patients according to the functional score of D'Aubigné & Postel [30], whereas the score of Thompson & Epstein [15] revealed excellent or good results in six of seven patients (86%). Thus, the results of this series are better compared to previous results reported by Epstein et al. (47%) [15], Swionkowski et al. (70%) [17], and Marchetti et al. (76%) [16].

Through the excellent visualization of the acetabulum and the femoral head cartilage destruction can be evaluated according to the criteria of Steinberg et al. [27]. In the six patients with acetabular fractures and severe acetabular cartilage damages two poor results and one fair result (50%) could be observed according to the score of Thompson & Epstein [15], whereas patients with mild or moderate cartilage damages revealed one poor and two fair outcomes in eight cases (38%). However, due to the small number of patients and the different fracture types statistical analysis is not feasible. Furthermore, it should be emphasized that assessment of the cartilage damage is complicated by the fact that cartilage "contusion" may represent a corollary to the joint damage that is observed following direct blunt trauma transmitted across articular surfaces without fracture [34].

Drilling of the femoral head allows approximate evaluation of the vascularity in femoral neck fractures [28]. In this study comparable investigations were carried out concerning the vascularity of the femoral head after acetabular or femoral head fractures. In all patients, there was an immediate or delayed bleeding of the femoral head. However, one patient developed AVN and a total hip arthroplasty was implanted 2 years after trauma. Although immediate bleeding from the femoral head seems to exclude development of AVN,

prospective studies with larger patient numbers may be needed to assess the prognostic value of this procedure.

The extension of the Kocher-Langenbeck approach with a trochanteric flip osteotomy allows surgical dislocation of the hip with better visualization of the anterior column, the supraacetabular part of the posterior wall, and a complete view of the femoral head and the acetabulum. Despite these advantages the flip osteotomy revealed a low risk of complications. In the current series, all trochanteric osteotomies healed in an anatomic position. Only in one patient, early in the series, the trochanteric flip dislocated 11 days after surgery which made a refixation of the trochanter necessary. In addition, one patient was irritated by the screws and a removal was carried out 2 years after primary surgery. Our experience is in contrast to previously reported high nonunion rates, ranging up to 35% in patients undergoing a total hip arthroplasty with the traditional trochanteric osteotomy [35]. Trochanteric osteotomies and their complications in nonextensile approaches for acetabular fracture treatment have only occasionally been described [23, 26]. Whereas Bray et al. [23] reported an incidence of 10% of trochanteric pain and abductor weakness despite union of the osteotomized trochanter, Siebenrock et al. [26] could prevent such complications in ten documented patients using the trochanteric flip osteotomy. Additionally, it could be argued that increased blood loss and a prolonged operation time could be potential disadvantages of the additional trochanteric osteotomy and surgical hip dislocation. However, the blood loss and operation time found in this study are comparable to those with the simple Kocher-Langenbeck approach [2, 7, 9, 11]. Furthermore, there is some concern that surgical hip dislocation could lead to AVN of the femoral head. However, in this series only one patient developed AVN, which corresponds with results of other clinical studies [36] and laser Doppler flowmetry studies, demonstrating restoration of blood flow after reduction of the hip [37].

Five acetabular fractures had to be operated through an additional ilioinguinal approach. In three transverse combined with posterior wall fractures, displacement of the anterior column was too large to be solely addressed posteriorly. In one case, a bony fragment was interposed at the anterior part of the transverse fracture hindering anatomic reposition and had to be removed anteriorly. In another patient with a displaced transverse fracture and an additional symphysis rupture, both injuries were addressed through an ilioinguinal approach.



Heterotopic ossification represents a frequent and sometimes debilitating complication after posterior and extensile approaches in acetabular fractures. In the present study, we used a higher dosage and an extended treatment period for prevention of heterotopic ossification when compared to other studies. However, most data are obtained from total hip replacement surgery. In a randomized study of 107 patients with acetabular fractures, indomethacin given at 75 mg per day did not significantly inhibit heterotopic ossification, but there was a trend toward less ectopic bone formation estimated on three-dimensional CT scans especially in patients operated by a Kocher-Langenbeck or an extended iliofemoral approach [38]. It is therefore conceivable that a higher dosage and/or extended treatment period would be sufficient to prevent heterotopic ossification. For the same considerations, patients who had given informed consent were treated additionally with irradiation. Two out of the 20 patients (10%) developed significant heterotopic ossification (Brooker class III) with functional impairment. This is similar to a previous study by Moore et al. [29] showing 9% heterotopic ossifications Brooker class III or IV after a simple Kocher-Langenbeck approach and heterotopic ossification prophylaxis using radiation therapy. Furthermore, heterotopic ossifications Brooker class III in this series were only observed in multiply injured patients where irradiation was impracticable. Thus, the extension of the Kocher-Langenbeck approach by trochanteric flip osteotomy does not increase the incidence of severe heterotopic ossification, if adequate prophylaxis by irradiation is carried out.

There were three patients with sciatic and peroneal nerve palsies. One was observed preoperatively after reduction of the dislocated hip and two are postoperative complications. However, in both patients there was a complete and partial neurologic recovery, respectively.

### Conclusion

Surgical hip dislocation through the Kocher-Langenbeck approach with trochanteric flip osteotomy represents a technique which facilitates the open reduction and fixation of femoral head fractures as well as of complex acetabular injuries. It is predominantly used in displaced transverse acetabular fractures and cranially extended posterior wall fractures without an increased risk of perioperative complications. Furthermore, it is possible to evaluate cartilage damage of the acetabulum and the femoral head as well as the perfusion of the femoral head.

### References

1. Calkins MS, Zych G, Latta L, et al. Computed tomography evaluation of stability in posterior fracture dislocation of the hip. *Clin Orthop* 1988;227:152–63.
2. Helfet DL, Schmeling GJ. Management of complex acetabular fractures through single nonextensile exposures. *Clin Orthop* 1994;305:58–68.
3. Keith JE Jr, Brashear HR Jr, Guilford WB. Stability of posterior fracture-dislocations of the hip. Quantitative assessment using computed tomography. *J Bone Joint Surg Am* 1988;70:711–4.
4. Letournel E. Acetabulum fractures: classification and management. *Clin Orthop* 1980;151:81–106.
5. Letournel E, Judet R. *Fractures of the acetabulum*. New York: Springer, 1993.
6. Matta JM. Operative indications and choice of surgical approach for fractures of the acetabulum. *Tech Orthop* 1986;1:13–20.
7. Matta JM, Mehne DK, Roffi R. Fractures of the acetabulum. Early results of a prospective study. *Clin Orthop* 1986;205:241–50.
8. Matta JM, Anderson LM, Epstein HC, et al. Fractures of the acetabulum. A retrospective analysis. *Clin Orthop* 1986;205:230–40.
9. Mayo KA. Open reduction and internal fixation of fractures of the acetabulum. Results in 163 fractures. *Clin Orthop* 1994;305:31–37.
10. Rowe CR, Lowell JD. Prognosis of fractures of the acetabulum. *J Bone Joint Surg Am* 1961;43:556–61.
11. Schmidt CC, Gruen GS. Non-extensile surgical approaches for two-column acetabular fractures. *J Bone Joint Surg Br* 1993;75:556–61.
12. Tornetta P 3rd. Non-operative management of acetabular fractures. The use of dynamic stress views. *J Bone Joint Surg Br* 1999;81:67–70.
13. Vrahas MS, Widding KK, Thomas KA. The effects of simulated transverse, anterior column, and posterior column fractures of the acetabulum on the stability of the hip joint. *J Bone Joint Surg Am* 1999;81:966–74.
14. Butler JE. Pipkin type-II fractures of the femoral head. *J Bone Joint Surg Am* 1981;63:1292–6.
15. Epstein HC, Wiss DA, Cozen L. Posterior fracture dislocation of the hip with fractures of the femoral head. *Clin Orthop* 1985;201:9–17.
16. Marchetti ME, Steinberg GG, Coumas JM. Intermediate-term experience of Pipkin fracture-dislocations of the hip. *J Orthop Trauma* 1996;10:455–461.
17. Swiontkowski MF, Thorpe M, Seiler JG, et al. Operative management of displaced femoral head fractures: case-matched comparison of anterior versus posterior approaches for Pipkin I and Pipkin II fractures. *J Orthop Trauma* 1992;6:437–42.
18. Kloen P, Siebenrock KA, Ganz R. Modification of the ilioinguinal approach. *J Orthop Trauma* 2002;16:586–93.
19. Pipkin G. Treatment of grade IV fracture dislocation of the hip. *J Bone Joint Surg Am* 1957;39:1027–41.
20. Collicott PE, Hughes I. Training in advanced trauma life support. *JAMA* 1980;243:1156–9.
21. Ertel W, Eid K, Keel M, et al. Therapeutical strategies and outcome of polytraumatized patients with pelvic ring injuries – a six year experience. *Eur J Trauma* 2000;26:278–86.
22. Ertel W, Keel M, Eid K, et al. Control of severe hemorrhage using C-clamp and pelvic packing in multiply injured patients with pelvic ring disruption. *J Orthop Trauma* 2001;15:468–74.
23. Bray TJ, Esser M, Fulkerson L. Osteotomy of the trochanter in open reduction and internal fixation of acetabular fractures. *J Bone Joint Surg Am* 1987;69:711–7.
24. Mercati E, Guary A, Myquel C, et al. A postero-external approach to the hip joint. Value of the formation of a digastric muscle. *J Chir (Paris)* 1972;103:499–504.

25. Schneeberger AG, Murphy SB, Ganz R. Die digastrische Trochanterosteomie. *Operat Orthop Traumatol* 1997;9:1–15.
26. Siebenrock KA, Gautier E, Ziran BH, et al. Trochanteric flip osteotomy for cranial extension and muscle protection in acetabular fracture fixation using a Kocher-Langenbeck approach. *J Orthop Trauma* 1998;12:387–91.
27. Steinberg ME, Corces A, Fallon M. Acetabular involvement in osteonecrosis of the femoral head. *J Bone Joint Surg Am* 1999;81:60–5.
28. Gill TJ, Sledge JB, Ekkernkamp A, et al. Intraoperative assessment of femoral head vascularity after femoral neck fracture. *J Orthop Trauma* 1998;12:474–8.
29. Moore KD, Goss K, Anglen JO. Indomethacin versus radiation therapy for prophylaxis against heterotopic ossification in acetabular fractures: a randomised, prospective study. *J Bone Joint Surg Br* 1998;80:259–63.
30. D'Aubigné MR, Postel M. Functional results of hip arthroplasty with acrylic prosthesis. *J Bone Joint Surg Am* 1954;36:451–8.
31. Brooker AF, Bowerman JW, Robinson RA, et al. Ectopic ossification following total hip replacement. Incidence and a method of classification. *J Bone Joint Surg Am* 1973;55:1629–32.
32. Greenspan L, McLellan BA, Greig H. Abbreviated Injury Scale and Injury Severity Score: a scoring chart. *J Trauma* 1985;25:60–4.
33. Tile M, Pennal GF. Pelvic disruption: principles of management. *Clin Orthop* 1980;151:56–64.
34. Donohue JM, Buss D, Oegema TR Jr, et al. The effects of indirect blunt trauma on adult canine articular cartilage. *J Bone Joint Surg Am* 1983;65:948–57.
35. Glassman AH. Complications of trochanteric osteotomy. *Orthop Clin North Am* 1992;23:321–33.
36. Ganz R, Gill TJ, Gautier E, et al. Surgical dislocation of the adult hip – a technique with full access to the femoral head and acetabulum without the risk of avascular necrosis. *J Bone Joint Surg Br* 2001;83:1119–24.
37. Notzli HP, Siebenrock KA, Hempfing A, et al. Perfusion of the femoral head during surgical dislocation of the hip. Monitoring by laser Doppler flowmetry. *J Bone Joint Surg Br* 2002;84:300–4.
38. Matta JM, Siebenrock KA. Does indomethacin reduce heterotopic bone formation after operations for acetabular fractures? A prospective randomised study. *J Bone Joint Surg Br* 1997;79:959–63.

**Address for Correspondence**

Marius Keel, MD  
Division of Trauma Surgery  
University Hospital Zurich  
Rämistrasse 100  
8091 Zürich  
Switzerland  
Phone (+41/1) 255-3657, Fax -4406  
e-mail: marius.keel@usz.ch