

Hernia (2013) 17:133–136
DOI 10.1007/s10029-011-0824-y

CASE REPORT

Parastomal hernia incarceration due to migrated intragastric balloon

P. Limani · D. C. Steinemann ·
P.-A. Clavien · D. Hahnloser

Received: 31 January 2011 / Accepted: 14 April 2011 / Published online: 3 May 2011
© Springer-Verlag 2011

Abstract The temporary placement of intragastric balloons is a common method to achieve rapid weight loss before planned metabolic surgery. We report the case of a 48-year-old morbidly obese patient. Ten years ago the patient underwent emergency sigmoidectomy with creation of a double-barreled ileostomy for perforated diverticulitis. Over time he developed a giant parastomal hernia. For pre-operative weight reduction before planned restoration of intestinal continuity, an intragastric balloon was inserted 3 years ago. The patient was admitted to our emergency department with peritonism and a septic shock. After computed tomography showing small bowel ileus, laparotomy was performed, revealing marked ischemia of incarcerated small and large intestine. Only postoperatively was the intragastric balloon found in the resected small bowel, causing a mechanical ileus with consecutive incarceration of the bowel. We review the literature on complications due to the migration of intragastric balloons. This clinical case gives a fair warning of the possible deleterious outcome of intragastric balloons, especially in hernia patients.

Keywords Intragastric balloon · Incarceration · Hernia · Parastomal · Balloon migration

Introduction

Implantation of an intragastric balloon has been reported as a temporary, nonsurgical, treatment for morbid obesity [1, 2]. The first generation of air-filled balloons reported many complications and placement problems [3]. Only after a comprehensive workshop, which was held in Tarpon Springs in 1987, were recommendations established to develop safer implants [4]. The placement and removal of these silicone balloons are performed under endoscopic control [5, 6]. Radioopaque construction allows radiological control of balloon localisation once migration is suspected. Minor complications consist of nausea and vomiting (8.6%), abdominal pain and other mild digestive disorders (e.g. dyspepsia, heartburn, flatulence, and digestive subocclusion in 5%). Major complications are balloon deflation and displacement (2.5%), obstruction of the digestive tract (0.8%), gastric perforation (0.1%), and mortality (0.1%) [7]. Successful weight reduction by implantation of an intragastric balloon in morbidly obese patients has been shown temporarily, but is not enduring. Its use is accepted to achieve rapid significant weight loss before a planned metabolic surgery to ease the operative procedure [6, 8].

We report a case of a severe complication after balloon migration, with incarceration of a giant parastomal hernia causing a severe septic shock and bowel ischemia.

Case report

A 48-year-old super-obese man was admitted to our emergency department with severe abdominal pain and a septic condition. The patient was known to have undergone an emergency sigmoid resection for perforated diverticulitis 10 years ago. At that time no reconstruction was performed

This case report was presented at the 97th Annual Meeting of the Swiss Surgical Society, May 2010, Interlaken.

P. Limani · D. C. Steinemann · P.-A. Clavien · D. Hahnloser (✉)
Department of Visceral and Transplantation Surgery,
University Hospital Zurich, Raemistrasse 100,
8091 Zurich, Switzerland
e-mail: dieter.hahnloser@usz.ch

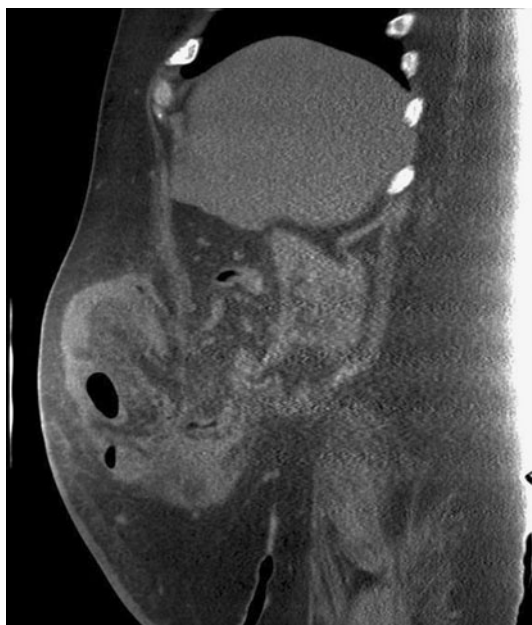


Fig. 1 Abdominal computed tomography (CT) scan: giant parastomal hernia

and the rectal stump as well as the transverse colon were closed blindly and a double-barreled ileostomy was created. Over time, a growing parastomal hernia developed, causing occasionally pain and impaired ostomy function. Suffering from a metabolic syndrome with a BMI of 58 kg/m², insulin-dependent diabetes mellitus and arterial hypertension, the patient's request for reconstruction of intestinal continuity was refused by several surgeons. A significant weight loss was set as a requirement before surgery in order to reduce the perioperative risks. Finally, an intragastric balloon was inserted 3 years ago in an out-of-town clinic. However, no significant weight loss was achieved and surgery was again delayed. Two weeks before admission, the patient was treated antibiotically for subileus and infection of unknown origin in an out-of-town clinic. The symptoms were relieved partially and the patient was discharged. At our emergency department, the patient reported a marked loss of appetite for the past 2 weeks, intermittent vomiting and ceased ostomy function for 2 days. Abdominal palpation showed tenderness over the giant parastomal hernia in the right lower quadrant. The patient developed a septic shock with hypotension, tachycardia and tachypnea. Laboratory values showed a leucocytosis of 17,000/mcl and a CRP level of 360 mg/l. An elevated creatinine of 255 mcmol/l indicated sepsis-related renal insufficiency. A computed tomography (CT) demonstrated multiple air-fluid levels and was highly suggestive of an incarcerated parastomal hernia (Fig. 1). However, an intragastric balloon could not be demonstrated initially in CT. The patient was transferred to the operating room for emergency laparotomy.

Operative procedure

Multiple intraabdominal adhesions were carefully released intraoperatively. A discharge of spontaneous purulent ascites was observed, and a dilated, fibrin-coated small bowel. Only the proximal 140 cm small bowel was vital. The rest of the small bowel was irreducible, ischemic and located in the parastomal hernia and had to be resected together with the remaining 60 cm of ascending and transverse colon. A second incision around the ostomy had to be conducted to mobilize the bowel. A terminal jejunostomy was performed.

Postoperative course

The haemodynamically unstable and septic patient was admitted to the intensive care unit. Resuscitation with high dose epinephrine and massive fluid therapy was successful within 24 h. Antibiotic therapy with tazobactam/piperacillin was initiated intraoperatively followed by adequate regression of the infection. The patient was weaned and extubated at day 3 after surgery. The renal insufficiency was regressive under fluid therapy.

A gastroscopy was ordered at day 1 after surgery for removal of the intragastric balloon. Astonishingly, no foreign body was seen up to the duodenum. The depleted intragastric balloon was found only upon examination of the resected small bowel specimen by the pathologist (Fig. 2). In a review of the CT scans the balloon was identified in the parastomal hernia (Fig. 3).

The postoperative course was complicated by subcutaneous wound infection treated with a vacuum assisted closure (V.A.C.[®]) system. Secondary wound closure was achieved within 3 weeks. The patient was discharged 34 days after surgery. With a remaining small intestine of only 140 cm, the patient developed short bowel syndrome, with recurrent dehydration, dyselectrolytemia and prerenal kidney failure requiring re-hospitalisation. A venous access port was implemented for regular hydration during the night. Reconstruction of bowel continuity promising improvement of the burden from short bowel was planned for 1 year later.

Discussion

Despite the widespread use of intragastric balloons for treatment of obesity since the early 1980s their role is still questionable. There is a lack of enduring weight loss and complications due to migration of the water-filled balloons have been reported [1, 2]. In most cases the balloons spontaneously deflated and were eliminated during defecation. In several cases of balloon migration into the small intestine percutaneous puncture was necessary before anal extrusion [9, 10]. One case of large bowel balloon impaction

Fig. 2 Deflated intragastric balloon

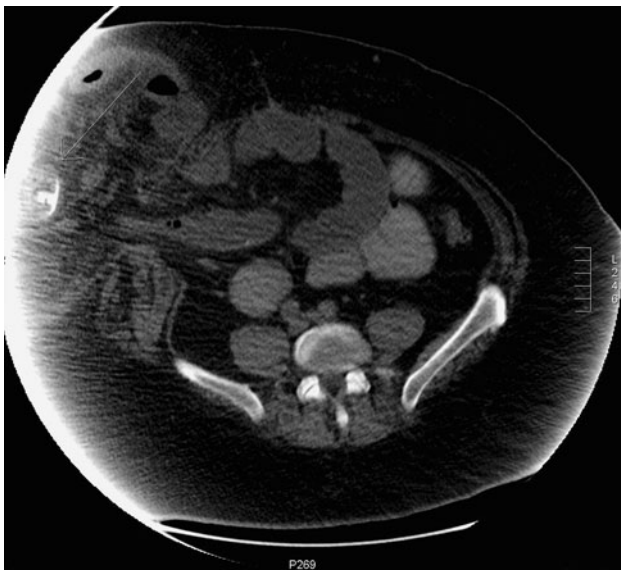


Fig. 3 Abdominal CT scan: deflated intragastric balloon (arrow)

requiring laparoscopic enterotomy has been described [11]. Here, we report the first case of bowel ischemia due to hernia incarceration by balloon migration.

Diagnosis of migrated intragastric balloons is by plain abdominal radiographs [12], ultrasound [13], and CT scans [14]. Since we did not expect a balloon depletion and migration in our preoperative assessment we did not explicitly search for it in the imaging. Only in a retrospect could the balloon be identified in CT scans (Fig. 3).

Almost 80% of bowel obstruction due to balloon migration has happened in patients in whom the balloon was left for more than 6 months [14]. Due to this fact, and as the greatest weight loss occurs within the first 3 months [15], endoscopic removal after 6 months is highly recommended. In our case, however, the balloon had been left in place for more than 3 years. This emphasizes the need for close follow-up of patients with intragastric balloons. Patient

compliance has to be thoroughly evaluated before such an intervention. In patients with an increased risk of bowel obstruction and incarceration, e.g. patients with a known abdominal wall hernia, major complications must be expected in case of balloon migration. For this reason, we strongly warn against its use in such patients. Nevertheless, any surgeon treating patients with an intragastric balloon complaining about bowel obstruction has to be familiar with its specific complications.

Although intragastric balloons might be advantageous in selected cases before metabolic surgery in order to shrink liver volume to allow better intraoperative exposure [16] they are not free of risk. Any indication for intragastric ballooning should be applied with caution.

References

1. Nieben OG, Harboe H (1982) Intragastric balloon as an artificial bezoar for treatment of obesity. *Lancet* 1(8265):198–199
2. Frimberger E, Kuhner W, Weingart J, Ottenjann R (1982) Intragastric appetite-depressor balloon. *Munch Med Wochenschr* 124(2):39–40
3. Levine GM (1988) Intragastric balloons: an unfulfilled promise. *Ann Intern Med* 109(5):354–356
4. Schapiro M, Benjamin S, Blackburn G, Frank B, Heber D, Kozarek R et al. (1987) Obesity and the gastric balloon: a comprehensive workshop. Tarpon Springs, Florida, 19–21 March. *Gastrointest Endosc* 33(4):323–327
5. Wahlen CH, Bastens B, Herve J, Malmendier C, Dallemagne B, Jehaes C et al (2001) The bioenterics intragastric balloon (BIB): how to use it. *Obes Surg* 11(4):524–527
6. Tsemeli N, Coumaros D (2009) Review of endoscopic devices for weight reduction: old and new balloons and implantable prostheses. *Endoscopy* 41(12):1082–1089
7. Imaz I, Martinez-Cervell C, Garcia-Alvarez EE, Sendra-Gutierrez JM, Gonzalez-Enriquez J (2008) Safety and effectiveness of the intragastric balloon for obesity. A meta-analysis. *Obes Surg* 18(7):841–846
8. Genco A, Cipriano M, Bacci V, Cuzzolaro M, Materia A, Raparelli L et al (2006) Bioenterics intragastric balloon (BIB): a short-term, double-blind, randomised, controlled, crossover study on weight reduction in morbidly obese patients. *Int J Obes* 30(1):129–133

9. Sallet JA, Marchesini JB, Paiva DS, Komoto K, Pizani CE, Ribeiro ML et al (2004) Brazilian multicenter study of the intragastric balloon. *Obes Surg* 14(7):991–998
10. Frimberger E, Kuhner W, Weingart J, Waldthaler A, Ottenjann R (1982) Percutaneous decompression of an intractable balloon—case report. *Hepatogastroenterology* 29(1):38–39
11. Kim WY, Kirkpatrick UJ, Moody AP, Wake PN (2000) Large bowel impaction by the BioEnterics Intragastric Balloon (BIB) necessitating surgical intervention. *Ann R Coll Surg Engl* 82(3):202–204
12. Zeman RK, Benjamin SB, Cunningham MB, Nauta RJ, Fleischer DF, Lewis JH et al (1988) Small bowel obstruction due to Garren gastric bubble: radiographic diagnosis. *AJR Am J Roentgenol* 150(3):581–582
13. Francica G, Giardiello C, Iodice G, Cristiano S, Scarano F, Delle Cave M et al (2004) Ultrasound as the imaging method of choice for monitoring the intragastric balloon in obese patients: normal findings, pitfalls and diagnosis of complications. *Obes Surg* 14(6):833–837
14. Matar ZS, Mohamed AA, Abukhater M, Hussien M, Emran F, Bhat NA (2009) Small bowel obstruction due to air-filled intragastric balloon. *Obes Surg* 19(12):1727–1730
15. Mathus-Vliegen EM, Tytgat GN (2005) Intragastric balloon for treatment-resistant obesity: safety, tolerance, and efficacy of 1-year balloon treatment followed by a 1-year balloon-free follow-up. *Gastrointest Endosc* 61(1):19–27
16. Tarnoff M, Kaplan LM, Shikora S (2008) An evidenced-based assessment of preoperative weight loss in bariatric surgery. *Obes Surg* 18(9):1059–1061