

K.O. Lövblad
J. Schneider
K. Ruoss
M. Steinlin
C. Fusch
G. Schroth

Isotropic apparent diffusion coefficient mapping of postnatal cerebral development

Received: 25 October 2002
Accepted: 3 April 2003
Published online: 20 May 2003
© Springer-Verlag 2003

K.O. Lövblad (✉)
Unité de Neuroradiologie,
Département de Radiodiagnostic,
Hôpital Cantonal
Universitaire HUG,
24 rue Micheli-du-Crest, Geneva 14,
Switzerland
E-mail: Karl-Olof.Lovblad@hcuge.ch
Tel.: +41-31-6329812
Fax: +41-31-6324872

K.O. Lövblad · K. Ruoss · G. Schroth
Department of Neuroradiology,
Inselspital, Bern, Switzerland

J. Schneider
MRI Unit, Children's Hospital,
Zurich, Switzerland

M. Steinlin
Neurology Department,
Children's Hospital,
University of Bern,
Bern, Switzerland

C. Fusch
Department of Neonatology,
University of Greifswald,
Germany

Abstract Diffusion-weighted imaging (DWI) allows us to image the motion of tissue water. This has been used to demonstrate acute ischaemia. Diffusion imaging is also sensitive to water movement along neuronal tracts. Our objective was to map brain maturation in vivo using maps of apparent diffusion coefficient (ADC). We studied 22 children without neurological disease aged between 2 and 720 days. MRI was performed at 1.5 tesla. Multislice single-shot echoplanar DWI was performed at b 0 and 1000 s/mm². ADC maps were generated automatically and measurements were performed in the basal ganglia, frontal and temporal white matter and the pons. There was a decrease over time in water diffusion in the areas examined, most marked in the frontal (0.887–1.898×10⁻³ mm²/s) and temporal (1.077–1.748×10⁻³ mm²/s) lobes. There was little change, after an initial decrease, in the basal ganglia (0.690–1.336×10⁻³ mm²/s). There was a difference

in water diffusion between the anterior (0.687–1.581×10⁻³ mm²/s) and posterior (0.533–1.393×10⁻³ mm²/s) pons. These changes correlate well with those observed in progressive myelination: the increased water content probably reflects incomplete myelination and the decrease with time in water motion reflects the increase in myelinated brain.

Keywords Diffusion-weighted imaging · Infant brain · Myelination

Introduction

Brain maturation in newborn and children has been extensively studied using MRI techniques [1, 2]. Maturation has been assessed mainly by looking at T1- and T2-weighted images on which myelin gives high and low signal, respectively. Diffusion-weighted imaging (DWI) allows us to image the motion of tissue water [3] and has

been used to demonstrate acute ischaemia [4]. Another application has been demonstration of normal structures and tracts due to the sensitivity of DWI to the movement of water in different directions. This sensitivity to anisotropic phenomena can therefore be used to map myelin tracts. This has increasingly been used in pediatric neuroradiology [5, 6] where it has been shown to correlate with brain maturation [7] and to be applicable

to disorders of myelination [8]. The apparent diffusion coefficient (ADC), calculated by acquiring DWI with at least two values of b allows quantification of diffusion in tissue. We report the use of ADC parametric maps to investigate the effects of brain maturation on cerebral water diffusion.

Materials and methods

We prospectively studied 22 children without evidence of neurological disease aged between 2 and 720 days. All were referred from the neonatal unit of the women's hospital in Berne. The examinations were performed according to the guidelines of the ethics committee of our institution.

Imaging was performed on a 1.5 tesla imager with a circularly polarised head coil. We first obtained conventional MRI with a three-plane localiser, sagittal T1-weighted, axial T1- and T2-weighted and coronal T2-weighted images as part of our neonatal protocol. Whole-brain multislice single-shot echoplanar DWI in the axial plane was performed at b values of 0 and 1000. Isotropic imaging was performed as previously reported [9]. The ADC were generated on a pixel-to-pixel basis and maps were generated automatically by the imager software; the regions of interest (ROI) and ADC maps had been validated previously [9]. The images were reviewed on a second console where regions of interest were defined manually and the ADC measured. In each child, measurements were performed in the basal ganglia and frontal and temporal white matter; ROI were placed using the software of the console. The ROI were defined by agreement between the two neuroradiologists who then performed one measurement.

Results

Conventional T2-weighted MRI did not reveal any abnormal signal abnormalities when viewed separately by two neuroradiologists separately (K.O.L., J.S.). On DWI and the ADC maps there were no features of ischaemic change.

With advancing age, there was an overall decrease in water diffusion in the areas examined, manifest by decreasing ADC (overall standard deviations being $0.06-0.1$), most markedly in the frontal (range: $0.887-1.898 \times 10^{-3} \text{ mm}^2/\text{s}$) and temporal (range: $1.077-1.748 \times 10^{-3} \text{ mm}^2/\text{s}$) lobes (Fig. 1). There was little change after an initial decrease in the basal ganglia (range: $0.690-1.336 \times 10^{-3} \text{ mm}^2/\text{s}$). There was more water diffusion in the anterior pons (range: $0.687-1.581 \times 10^{-3} \text{ mm}^2/\text{s}$) than in the and posterior portion (range: $0.533-1.393 \times 10^{-3} \text{ mm}^2/\text{s}$) (Fig. 2).

Discussion

While the mechanisms underlying the generation of the DWI image and the ADC are not entirely known and reflect a number of physiological parameters, such as tissue compactness, they probably reflect indirectly the state of myelination of the newborn brain. DWI has

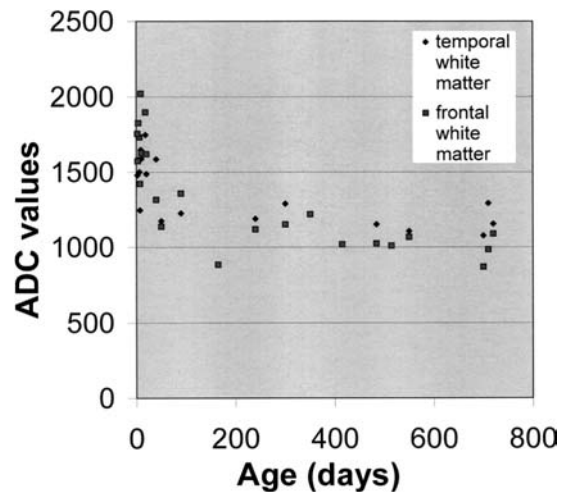


Fig. 1 Apparent diffusion coefficients (ADC) in frontal (*grey squares*) and temporal (*black lozenges*) white matter. After a high peak after birth, there is a decrease over the first few months, which then stabilises

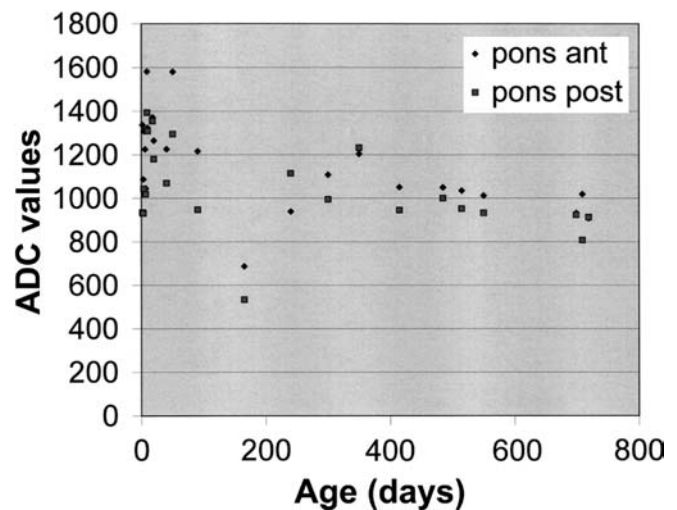


Fig. 2 ADC in the anterior (*black lozenges*) and posterior (*grey squares*) pons. After a high peak after birth, there is a decrease over the first few months, which then stabilises. However ADC in the anterior pons tend to be higher at all stages, indicating differences in myelination

been used in early stroke, where decreased diffusion (high signal on DWI and low ADC) reflects early redistribution of water. Since water moves along white-matter tracts, DWI has been used applied to demonstrate them.

In the children we studied, we saw that, after an initial decrease in the amount of water in the brain, there was homogeneous diffusion in the parenchyma. This confirms previous data as those of Forbes et al. [7], who found an overall decrease in ADC with increasing age during the first year of life. This does not occur at the same rate in all parts of the brain;

there was a marked difference in water diffusion between the anterior and posterior parts of the pons.

Gelal et al. [10] found DWI useful for lesion detection in very young children. Bydder et al. [5] reported the use of DWI and ADC measurements in neonates, showing restricted motion in both myelinated and unmyelinated white-matter tracts. Using Diffusion tensor imaging (DTI), Huppi et al. [11] found no difference, at term, in ADC between preterm infants with or without perinatal white matter lesions. In contrast, the relative anisotropy (RA), the measure of preferred directionality of diffusion and thereby dependent on development of axonal fibres and oligodendroglia, was 25% lower in central white matter, the principal site of the original white-matter injury. However, the RA was unaffected in relatively uninjured white matter areas, such as the temporal, anterior frontal, and occipital regions. RA in the internal capsule, which contains fibres which descend from the injured cerebral white matter, was 20% lower in the infants with white matter injury. Diffusion vector maps showed striking changes in the size, orientation, and organisation of fibre tracts in central white matter and in those descending to the internal capsule.

Using DTI, Klingberg et al. [12] again demonstrated that anisotropy was significantly lower in the frontal white matter in children than in adults, suggesting less myelination in children. Measurement of the coherence of white matter revealed that the right frontal lobe had a more regular organisation of axons than the left in both children and adults.

Morris et al. [13] found that ADC and apparent anisotropy values were directly related to the structural maturity and compactness of the white-matter tracts and changed with ageing in a way that predated early myelination markers such as signal change on T1- or T2-weighted images. This confirms an earlier report by Wimberger et al. [14] that the first evidence of diffusion anisotropy on anisotropy index maps preceded initial myelin as well as neurofibril staining by 5–12 days and T2 shortening by 2 weeks. Vorisek and Sykova reported the evolution of anisotropy with development [15]. We have also observed these phenomena in vivo, confirming the validity of using ADC maps for monitoring brain development. We also observed differences

in regional brain maturation at the same stage: ADC were higher in the anterior pons, indicating less myelination, and underlining the strength of the method for exploration in vivo of brain maturation. In human experiments Toft et al. [16] also found that ADC provided data additional to those given by conventional imaging.

In a recent study, Miller et al. [17] found that ADC increased with age and that anisotropy decreased but bemoaned the fact that normative data are not available. This is the main interest of our paper. While we did not perform DTI, it is clear that this is a further development which could be of great interest for studying the child's brain. However, longer acquisition times are needed to acquire useful DTI data sets, so as to assess the tensor fully, which might not be easy or practical when studying infants. Schmidhorst et al. [18] found, in 33 cases, that DTI indicated that white-matter maturation at different ages involves increases in both density and organisation of white matter during childhood and adolescence. However, their subjects were more than 5 years of age, at which time the main changes in myelination have already occurred.

Boujraf et al. [19] found, in a study of infants, that the data obtained by their anisotropy and volume indices were superior to those of the ADC. This is somewhat surprising, as the ADC and the tensor are directly related. Both rely on a diffusion-sensitised sequence and reflect water motility which is simply processed and displayed differently: the diffusion tensor may show water motion and the ADC provide a direct measurement of this mobility. Mukherjee et al. [20] found that the isotropic diffusion coefficient paralleled the increase in white-matter tracts and diffusion anisotropy had a small linear increase in patients; the first of these confirms our data. They also reported less positive findings when applying DTI to the thalamus [21], but this is to be expected due to the complexity of this structure. We also found little change in ADC in the basal ganglia over time. However, our results, together the literature suggest that ADC maps can be used in clinical practice to assess brain maturation.

Acknowledgements This study was financed by Swiss National Science Foundation Grant 3100-066348.01

References

1. Martin E, Kikinis R, Zuerrer M, et al (1988) Developmental stages of human brain: an MR study. *J Comput Assist Tomogr* 12: 917–922
2. Martin E, Boesch C, Zuerrer M, et al (1990) MR imaging of brain maturation in normal and developmentally handicapped children. *J Comput Assist Tomogr* 14: 685–692
3. Le Bihan D, Breton E, Lallemand D, Grenier P, Cabanis E, Laval-Jeantet M (1986) MR imaging of intravoxel incoherent motions: application to diffusion and perfusion in neurologic disorders. *Radiology* 161: 401–407

4. Lövlblad K, Laubach H, Baird A, et al (1998) Clinical experience with diffusion-weighted MR in patients with acute stroke. *AJNR* 19: 1061–1066
5. Bydder GM, Rutherford MA, Cowan FM (2001) Diffusion-weighted imaging in neonates. *Child's Nerv Syst* 17: 190–194
6. Beaulieu C, D'Arceuil H, Hedehus M, de Crespigny A, Kastrup A, Moseley ME (1999) Diffusion-weighted magnetic resonance imaging: theory and potential applications to child neurology. *Semin Pediatr Neurol* 6: 87–100
7. Forbes KP, Pipe JG, Bird CR. (2002) Changes in brain water diffusion during the 1st year of life. *Radiology* 222: 405–409
8. Engelbrecht V, Scherer A, Rassek M, Witsack HJ, Modder U (2002) Diffusion-weighted MR imaging in the brain in children: findings in the normal brain and in the brain with white matter diseases. *Radiology* 222: 410–418
9. Weber J, Mattle HP, Heid O, Remonda L, Schroth G (2000) Diffusion-weighted imaging in ischaemic stroke: a follow-up study. *Neuroradiology* 42: 184–191
10. Gelal FM, Grant PE, Fischbein NJ, Henry RG, Vigneron DB, Barkovich AJ (2001) The role of isotropic diffusion MRI in children under 2 years of age. *Eur Radiol* 11: 1006–1014
11. Huppi PS, Maier SE, Peled S, et al (1998) Microstructural development of human newborn cerebral white matter assessed in vivo by diffusion tensor magnetic resonance imaging. *Pediatr Res* 44: 584–590
12. Klingberg T, Vaidya CJ, Gabrieli JD, Moseley ME, Hedehus M (1999) Myelination and organization of the frontal white matter in children: a diffusion tensor MRI study. *NeuroReport* 10: 2817–2821
13. Morriss MC, Zimmerman RA, Bilaniuk LT, Hunter JV, Haselgrove JC (1999) Changes in brain water diffusion during childhood. *Neuroradiology* 41: 929–934
14. Wimberger DM, Roberts TP, Barkovich AJ, Prayer LM, Moseley ME, Kucharczyk J (1995) Identification of “premyelination” by diffusion-weighted MRI. *J Comput Assist Tomogr* 19: 28–33
15. Vorisek I, Sykova E (1997) Evolution of anisotropic diffusion in the developing rat corpus callosum. *J Neurophysiol* 78: 912–919
16. Toft PB, Leth H, Peitersen B, Lou HC, Thomsen C (1996) The apparent diffusion coefficient of water in gray and white matter of the infant brain. *J Comput Assist Tomogr* 20: 1006–1011
17. Miller SP, Vigneron DB, Henry RG, et al (2002) Serial quantitative diffusion tensor MRI of the premature brain: Development in newborns with and without injury. *J Magn Reson Imaging* 16: 621–632
18. Schmithorst VJ, Wilke M, Dardzinski BJ, Holland SK (2002) Correlation of white matter diffusivity and anisotropy with age during childhood and adolescence: a cross-sectional diffusion-tensor MR imaging study. *Radiology* 222: 212–218
19. Boujraf S, Luypaert R, Shabana W, De Meirleir L, Sourbron S, Osteaux M (2002) Study of pediatric brain development using magnetic resonance imaging of anisotropic diffusion. *Magn Reson Imaging* 20: 327–336
20. Mukherjee P, Miller JH, Shimony JS, et al (2001) Normal brain maturation during childhood: developmental trends characterized with diffusion-tensor MR imaging. *Radiology* 221: 349–358
21. Mukherjee P, Miller JH, Shimony JS, et al (2002) Diffusion-tensor MR imaging of gray and white matter development during normal human brain maturation. *AJNR* 23: 1445–1456