

Eur Spine J (2009) 18 (Suppl 2):S228–S231
DOI 10.1007/s00586-009-0893-0

CASE REPORT

Lymphocele: a rare and little known complication of anterior lumbar surgery

Constantin Schizas · Noël Foko'o · Maurice Matter ·
Sebastien Romy · Everard Munting

Received: 10 October 2008 / Accepted: 18 January 2009 / Published online: 13 February 2009
© Springer-Verlag 2009

Abstract Lymphocele is a rare and little known complication with only a handful of reports available. We report two cases of lymphocele after anterior lumbar surgery that have occurred in two different centres and discuss diagnosis and management options. The first case is that of a 53-year-old male patient undergoing two level anterior lumbar interbody fusion (ALIF) for disabling back pain due to disc degeneration in the context of an old spondylodiscitis. He developed a large fluid mass postoperatively. Fluid levels of creatinin were low and intravenous urography ruled out a urinoma suggesting the diagnosis of a lymphocele. Following two unsuccessful drainage attempts he underwent a laparoscopic marsupialization. The second case was that of a 32-year-old female patient developing a large fluid mass following a L5 corpectomy for a burst fracture. She was treated successfully with insertion of a vacuum drain during 7 days. Lymphocele is a rare complication but should be suspected if fluid collects postoperatively following anterior lumbar spine procedures. Chemical analysis of the fluid can help in diagnosis. Modern treatment consists of laparoscopic marsupialization. Lymph vessel anatomy should be borne in mind while exposing the anterior lumbar spine.

Keywords Lumbar vertebra · Lymphocele · Surgery · Complications · Anterior lumbar spine approach

Introduction

Exposure of the lumbar spine through an anterior approach is well established in treating various conditions including painful degeneration of the intervertebral disc. The most commonly reported complications are vascular and neurological although other complications such as urological, gastrointestinal, thrombo-embolic events, dural tears and retrograde ejaculation have also been described [13]. Lymphocele formation is a lesser known complication with only a handful of reports available. We report two cases of lymphocele after anterior lumbar surgery that have occurred in two different centres and discuss diagnosis and management options.

Case 1

A 53-year-old male patient underwent L4–5 and L5–S1 anterior lumbar interbody fusion (ALIF) for disabling back pain due to disc degeneration. Eighteen months previously he underwent a L5–S1 discectomy following which he developed an infective spondylodiscitis treated conservatively. The operation was performed through a left retroperitoneal approach. Due to past medical history of recurrent pulmonary emboli he underwent temporary insertion of an inferior vena cava filter for the first postoperative week followed by full dose anticoagulation. On the 10th postoperative day he complained of a painful swelling on the left side of his abdomen. A CT scan showed a 10 × 12 cm collection arising from the left

C. Schizas (✉)
Hôpital Orthopédique de la Suisse Romande,
Centre Hospitalier Universitaire Vaudois,
The University of Lausanne, Avenue Pierre-Decker 4,
1011 Lausanne, Switzerland
e-mail: cschizas@hotmail.com

N. Foko'o · E. Munting
Orthopaedic Department, Clinique St-Pierre, Ottignies, Belgium

M. Matter · S. Romy
Department of General Surgery, Centre Hospitalier Universitaire
Vaudois, The University of Lausanne, Lausanne, Switzerland

reperitoneal space, whereas an intravenous urography showed no extravasation of contrast medium, ruling out a urinoma. Under ultrasound guidance a drain was introduced draining clear yellowish fluid. Biochemical examination showed a creatinin level lower to that of the serum creatinin. Cultures were negative. The diagnosis of a lymphocoele was made and the drain was removed after 5 days. Unfortunately 3 weeks later the symptoms recurred and a repeat CT scan showed reformation of a large fluid collection (Fig. 1). After a second unsuccessful attempt to treat the lymphocoele conservatively a laparoscopic marsupialization was performed. The patient remained symptom free at latest follow up a year later while an abdominal CT scan showed no evidence of fluid collection.

Case 2

A 32-year-old female patient was admitted following a road traffic accident presenting with a femoral fracture, a stable compression injury of L1 and a burst fracture of L5 associated with unilateral motor and sensory foot disturbance.

Following initial open fixation of her femoral fracture she underwent posterior decompression and L4–S1 stabilisation followed a week later by an anterior L5 corpectomy and allograft fusion through a left retroperitoneal approach. One week following surgery she developed a painful swelling of the left lower abdomen. Ultrasound showed a $16 \times 13 \times 8$ cm heterogeneous collection suggesting possible haematoma formation. Computer tomography (Fig. 2) confirmed this collection, in continuity with the operative site, suggesting according to

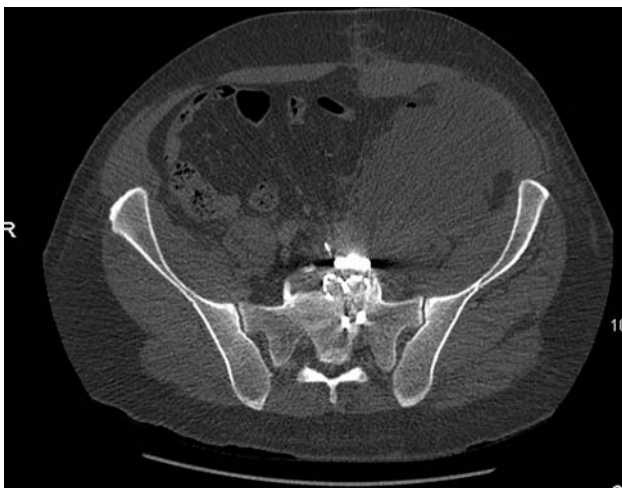

Fig. 1 Pelvic CT scan of case 1 taken 5 weeks following surgery showing recurrence of a left retroperitoneal fluid collection despite drainage

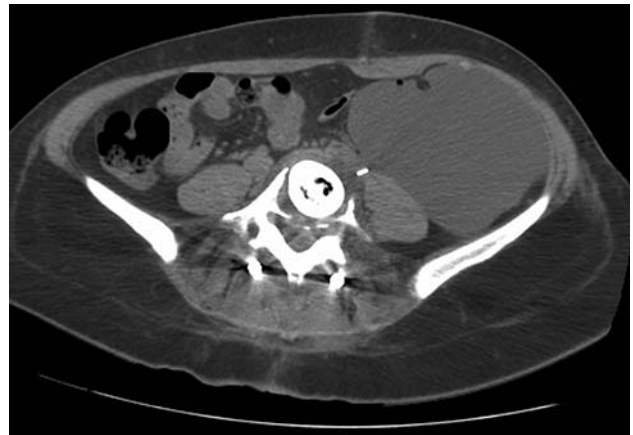

Fig. 2 CT scan of case 2 showing a large fluid collection on the left side

the reporting radiologist—familiar with this complication in urological surgery—a lymphocoele. A vacuum drain was inserted under local anaesthetic draining after 7 days 10 cc/24 h clear yellowish fluid. Cytology and biochemical analysis of the fluid showed no pus cells and a low urea concentration. Following drain removal no recurrence of the painful swelling was noted. At 1 year post surgery an ultrasound of the abdomen showed no further fluid collection while the patient remained asymptomatic.

Illustration of lymph vessels and nodes during anterior lumbar spine surgery

In order to better understand lymphatic anatomy and facilitate dissection we injected on induction of anaesthesia 2 cc of Patent Blue V dye (commonly used for lymph node identification in cancer surgery) subcutaneously in the left foot of a patient undergoing a two level anterior lumbar procedure. The greenish stained lymph vessels and nodes could be clearly seen and avoided (Fig. 3). They were located lateral to the left common iliac artery and could possibly be injured during the dissection of the left ascending lumbar vein while exposing the L4–5 or L3–4 disc space.

Discussion

The lymphatic system at the sub-diaphragmatic level consists of vessels that run parallel to the venous system anterior to the spine. At the level of the first lumbar disc lymphatic vessels from the lower limbs and pelvis coalesce with those arising from the peritoneum, and the gastrointestinal system forming the cisterna chyli, which cranially constitutes the thoracic duct. Injury of the lymphatic

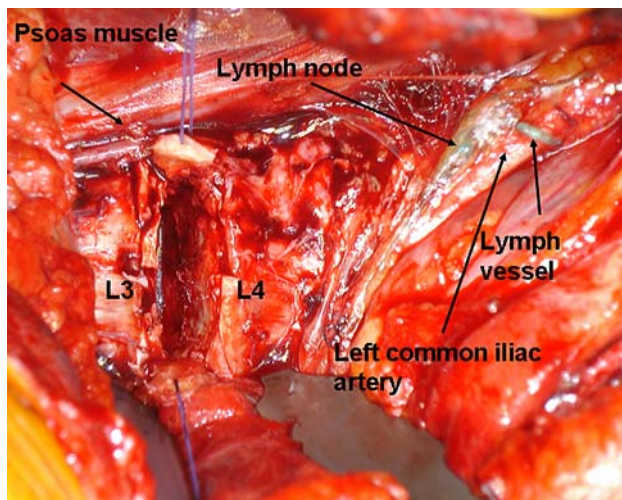


Fig. 3 Intraoperative view of a patient undergoing L3–4 disc arthroplasty through a left retroperitoneal approach 2 h following injection of 2 cc of Patent Blue V dye. The lymph vessels and nodes lateral to the retracted common iliac artery are seen

vessels below the cisterna chyli can result in lymphocele that is a collection of clear yellowish fluid, poor in chylomicrons and therefore devoid of the classical milky appearance of the chyle. The latter is only found at the level of the cisterna chyli and above, explaining why leakage cranial to the L1–L2 level may result in either chyloascites or chylothorax [11]. Chylothorax is a recognized complication following injuries or anterior surgery of the thoracic or thoraco-lumbar spine and several reports have dealt with its management [1, 7, 8, 15].

Lymphocele formation following anterior lower lumbar spine surgery is a rarely reported event. We found only five such cases in the literature [5, 6, 9, 10, 16].

By contrast lymphocele is a well known complication in renal transplant surgery with incidences ranging from 0.6 to 18% [4, 12, 14]. This high incidence could be linked to dissection along the iliac vessels, the use of immunosuppressive medication interfering with soft tissue healing as well as with acute graft rejection, decapsulation or urinary obstruction [3]. Absence of those risk factors might explain a significantly lower incidence in anterior spinal surgery. Increased body mass index has also been linked with the occurrence of lymphocele in renal transplant patients [2].

Differential diagnosis should include urinoma, cerebrospinal fluid (CSF) leak, ascites, seroma and infection. Creatinin levels in the collected fluid can be helpful in ruling out a urinoma (in which case levels higher than the serum creatinin level are recorded). A myelogram or measurement of b2 transferin in the fluid can help rule out a CSF collection. Gram stain and cultures should also be performed in ruling out infection. Lymphangiography could also be used in difficult to diagnose cases. Liver

Table 1 Summary of case reports on lymphocele following anterior lumbar surgery

| Case | Age | Level | Diagnosis | Procedure 1 | Procedure 2 | Approach | Symptoms | Diagnostic tests | Treatment | Outcome | References |
|------|-----|--------|---------------------------------|-----------------------|------------------|----------------------|--------------------|------------------------|-------------------------------|---------------|----------------------|
| 1 | 52 | L4–5 | Isthmic spondylolisthesis | ALIF L4–5 | Posterior fusion | Left retroperitoneal | Abdominal symptoms | CT | Drainage, open surgery | Full recovery | [10] |
| 2 | 73 | L3–4–5 | Degenerative scoliosis stenosis | ALIF L2–5 | Posterior fusion | Left retroperitoneal | Abdominal symptoms | CT and creatinin level | Laparoscopic marsupialization | Full recovery | [9] |
| 3 | 38 | L5–S1 | Iatrogenic spondylolisthesis | ALIF L5–S1 | Posterior fusion | Left retroperitoneal | Urinary symptoms | CT and creatinin level | Povidone Iodine | Full recovery | [6] |
| 4 | 43 | L3–4 | L3–L4 discitis | Corpectomy and fusion | None | Left retroperitoneal | Wound discharge | Lymphangiography | Drainage | Full recovery | [5] |
| 5 | 50 | L4–S1 | Disc arthroplasty failure | ALIF L4–S1 | None | Left retroperitoneal | Pain anorexia | CT and creatinin level | Laparoscopic marsupialization | Full recovery | [16] |
| 6 | 53 | L4–S1 | L5–S1 discitis | ALIF L4–S1 | None | Left retroperitoneal | Abdominal symptoms | CT and creatinin level | Laparoscopic marsupialization | Full recovery | Present study case 1 |
| 7 | 32 | L4–S1 | Fracture | Corpectomy and fusion | Posterior fusion | Left retroperitoneal | Abdominal symptoms | CT | Drainage | Full recovery | Present study case 2 |

function tests can be performed in order to rule out liver dysfunction causing ascites.

Treatment of lymphocele has been by continuous drainage or by aspiration and injection of sclerosing agents such as doxycycline or povidone iodine although both these techniques can have high recurrence rates [2]. Their application in spinal surgery in the presence of implants raises the question of possible secondary infection. The treatment which appears to be favored lately in transplant patients is laparoscopic marsupialization. It consists on internal peritoneal drainage of the lymphocele through a peritoneal window large enough to remain patent and allow reabsorption by the peritoneal tissues of the produced fluid. The failure rate in transplant patients (12%) has been lower than using other techniques such as drainage (25%) alone or sclerotherapy (33%) [2].

It is interesting to note that only one case has been treated using a marsupialization technique from the five reported cases in the literature, the remaining having been treated either by drainage or sclerosis. All seven cases including the two reported here made uneventful recoveries without recurrence of the lymphocele. It is possible that lymph vessel injury occurs more frequently than suspected but leads rarely to lymphocele formation in spinal surgery as opposed to renal transplant or oncological surgery. Compiling the literature cases with the two presented here does not allow drawing conclusions on risk factors for lymphocele development mainly due to the small number of cases reported (Table 1). Based on our results as well as those available from the five reported cases it transpires that lymphocele following anterior lumbar surgery might carry a better prognosis than in renal transplant or urogenital cancer patients with none of the patients having developed recurrence. Finally in difficult cases such as repeat anterior exposures or obese patients, visualization of lymph vessels following injection of Patent Blue V dye might be useful.

Conclusion

Lymphocele is a rare complication but should be suspected if fluid collects postoperatively following anterior lumbar spine procedures. Chemical analysis of the fluid can help in diagnosis. Modern treatment consists of laparoscopic marsupialization this technique carrying the lowest recurrence rate. Lymph vessel anatomy should be borne in mind while exposing the anterior lumbar spine.

Conflict of interest statement None of the authors has any potential conflict of interest.

References

1. Akcali O, Kiray A, Ergur I, Tetik S, Alici E (2006) Thoracic duct variations may complicate the anterior spine procedures. *Eur Spine J* 15(9):1347–1351. doi:10.1007/s00586-006-0082-3
2. Atray NK, Moore F, Zaman F, Caldito G, Abreo K, Maley W, Zibari GB (2004) Post transplant lymphocele: a single centre experience. *Clin Transplant* 18(Suppl 12):46–49. doi:10.1111/j.1399-0012.2004.00217.x
3. Derweesh IH, Ismail HR, Goldfarb DA, Araki M, Zhou L, Modlin C, Krishnamurthi V, Flechner SM, Novick AC (2008) Intraoperative placing of drains decreases the incidence of lymphocele and deep vein thrombosis after renal transplantation. *BJU Int* 101:1415–1419. doi:10.1111/j.1464-410X.2007.07427.x
4. Dubeaux VT, Oliveira RM, Moura VJ, Pereira JM, Henriques FP (2004) Assessment of lymphocele incidence following 450 renal transplantations. *Int Braz J Urol* 30:18–21. doi:10.1590/S1677-55382004000100004
5. Hanson D, Mirkovic S (1998) Lymphatic drainage after lumbar surgery. *Spine* 23(8):956–958. doi:10.1097/00007632-199804150-00023
6. Levi AD (1999) Treatment of a retroperitoneal lymphocele after lumbar fusion surgery with intralesional povidone iodine: technical case report. *Neurosurgery* 45(3):658–660. doi:10.1097/00006123-199909000-00047 (discussion 660–661)
7. Lubicky JP (1998) Chylous leakage after circumferential thoracolumbar fusion for correction of kyphosis resulting from fracture: report of three cases. *Spine* 23(16):1814–1815. doi:10.1097/00007632-199808150-00019 (comment)
8. Nakai S, Zielke K (1986) Chylothorax: a rare complication after anterior and posterior spinal correction. Report on six cases. *Spine* 11(8):830–833. doi:10.1097/00007632-198610000-00018
9. Patel AA, Spiker WR, Daubs MD, Brodke DS, Cheng I, Glasgow RE (2008) Retroperitoneal lymphocele after anterior spinal surgery. *Spine* 33:E648–E652. doi:10.1097/BRS.0b013e31817c6ced
10. Pee YH, Kim KJ, Choi YG, Jeon SH, Park JD, Lee SH (2007) Lymphocele formation after anterior lumbar interbody fusion at L4–5. Case report. *J Neurosurg Spine* 7(5):566–570. doi:10.3171/SPI-07/11/566
11. Propst-Proctor SL, Rinsky LA, Bleck EE (1983) The cisterna chyli in orthopaedic surgery. *Spine* 8(7):787–792. doi:10.1097/00007632-198310000-00017
12. Samhan M, Al-Mousawi M (2006) Lymphocele following renal transplantation. *Saudi J Kidney Dis Transpl* 17:34–37
13. Sasso RC, Best NM, Mummaneni PV, Reilly TM, Hussain SM (2005) Analysis of operative complications in a series of 471 anterior lumbar interbody fusion procedures. *Spine* 30(6):670–674. doi:10.1097/01.brs.0000155423.18218.75
14. Shokeir AA, el-Diasty TA, Ghoneim MA (1993) Percutaneous treatment of lymphocele in renal transplant recipients. *J Endourol* 7:481–485
15. Silen ML, Weber TR (1995) Management of thoracic duct injury associated with fracture-dislocation of the spine following blunt trauma. *J Trauma Inj Infect Crit Care* 39(6):1185–1187. doi:10.1097/00005373-199512000-00033
16. Wagner WH, Regan JJ, Leary SP, Lanman TH, Johnson JP, Rao RK, Cossman DV (2006) Access strategies for revision or explantation of the Charite lumbar artificial disc replacement. *J Vasc Surg* 44(6):1266–1272. doi:10.1016/j.jvs.2006.07.046