

Palliative Portal Vein Stent Placement in Malignant and Symptomatic Extrinsic Portal Vein Stenosis or Occlusion

Sébastien Novellas · Alban Denys · Pierre Bize · Philippe Brunner ·
Jean Paul Motamedi · Jean Gugenheim · François-Xavier Caroli ·
Patrick Chevallier

Received: 3 July 2008 / Accepted: 12 September 2008 / Published online: 28 October 2008
© Springer Science+Business Media, LLC 2008

Abstract This article evaluates the results of portal vein (PV) stent placement in patients with malignant extrinsic lesions stenosing or obstructing the PV and causing symptomatic PV hypertension (PVHT). Fourteen patients with bile duct cancer ($n = 7$), pancreatic adenocarcinoma ($n = 4$), or another cancer ($n = 3$) underwent percutaneous transhepatic portal venous stent placement because of gastroesophageal or jejunal varices ($n = 9$), ascites ($n = 7$), and/or thrombocytopenia ($n = 2$). Concurrent tumoral obstruction of the main bile duct was treated via the transhepatic route in the same session in four patients. Changes in portal venous pressure, complications, stent patency, and survival were evaluated. Mean \pm standard deviation (SD) gradient of portal venous pressure

decreased significantly immediately after stent placement from $11.2 \text{ mmHg} \pm 4.6$ to $1.1 \text{ mmHg} \pm 1.0$ ($P < 0.00001$). Three patients had minor complications, and one developed a liver abscess. During a mean \pm SD follow-up of 134.4 ± 123.3 days, portal stents remained patent in 11 patients (78.6%); stent occlusion occurred in 3 patients, 2 of whom had undergone previous major hepatectomy. After stent placement, PVHT symptoms were relieved in four (57.1%) of seven patients who died (mean survival, 97 ± 71.2 days), and relieved in six (85.7%) of seven patients still alive at the end of follow-up (mean follow-up, 171.7 ± 153.5 days). Stent placement in the PV is feasible and relatively safe. It helped to relieve PVHT symptoms in a single session.

Keywords Bile ducts · Neoplasm · Pancreas ·
Portography · Stents and prostheses · Portal vein stenosis ·
Obstruction

S. Novellas · P. Brunner · J. P. Motamedi · P. Chevallier
Department of Radiology and Interventional Radiology,
Hôpital Archet, 151 route de Saint Antoine de Ginestière,
06202 Nice, France

A. Denys (✉) · P. Bize
Department of Radiology and Interventional Radiology,
Centre Hospitalier Universitaire Vaudois, 1011 Lausanne,
Switzerland
e-mail: Alban.Denys@chuv.ch

P. Bize
e-mail: pierrebize@bluewin.ch

J. Gugenheim
Department of Surgery, Hôpital Archet,
151 route de Saint Antoine de Ginestière, 06202 Nice, France

F.-X. Caroli
Department of Medical Oncology, Hôpital Archet, 151 route de
Saint Antoine de Ginestière, 06202 Nice, France

Introduction

Adults develop prehepatic portal vein obstruction (PHPVO) as a result of various conditions, including hypercoagulable states and alterations of the venous wall that result from inflammation or surgery such as hepatectomy or liver transplantation, and in association with tumors or underlying cirrhosis [1]. Cirrhosis is the leading cause of portal vein (PV) occlusion, followed closely by neoplastic disease. Among neoplasms, hepatocellular carcinoma (HCC), along with pancreatic or bile duct cancer, constitute the majority of cases. PHPVO in these cases occurs as a consequence of direct invasion of the PV by the tumor, extrinsic compression, periportal fibrosis after surgery or radiotherapy, or a hypercoagulable state that results

from malignancy. Malignant PHPVO leads to PV hypertension (PVHT) with complications such as esophageal, gastric, or anorectal varices, hypersplenism, and ascites. The development of these complications is variable and is based in particular on the topography of venous obstruction as well as the possibility for the development of collaterals vessels around the obstructed PV and portocaval communications. Variceal hemorrhage and refractory ascites are the most serious complications. Surgical treatment of these symptoms generally has poor results, and therefore more conservative therapies are advocated.

Multiple sessions of endoscopic variceal obliterations or paracentesis constitute the main therapeutic options. A single session of treatment with PV stent placement may constitute an alternative. Since the early 1990s, only a few case reports or case series addressed stent placement for treatment of benign PV thrombosis [2], stenosis, or occlusion due to chronic or acute pancreatitis [3–7], coagulation disorder [8], or complications related to liver transplantation or other surgeries [9–13]. Stent placement to treat malignant PV lesion has been also evaluated [10, 14–22], mainly by Yamakado et al. [14–16], who published three studies that followed a cohort of patients who presented with biliary or pancreatic neoplasms, and HCC. However, little is known about clinical usefulness of PV stent placement when the portal stenosis is related to a malignant cause other than HCC, with only 31 patients reported [10, 14, 15, 17–22].

The purpose of this study was to evaluate results of our preliminary experience of PV stent placement in patients with malignant PV lesion, excluding patients with intra-portal malignant thrombosis arising from HCC.

Methods

Patients

From November 2002 to February 2005, a total of 27 consecutive patients with malignant PV stenosis or obstruction were depicted with a contrast-enhanced computed tomography (CT) and evaluated for palliative PV stent placement. The diagnosis of malignant PV invasion was presumed when a stenosis or obstruction of the portal system surrounded by tumor was seen. HCC with intra-portal tumoral extension were not considered for this study.

After a multidisciplinary decision was made for each patient, 11 of the patients were not considered because tumoral PV involvement by the cancer was asymptomatic, and 2 patients were not considered because of their dismal prognosis and extremely short life expectancy. In all, 14 consecutive symptomatic patients (10 men, 4 women; mean \pm standard deviation age, 63.8 ± 11.3 years; range, 40–77 years) underwent PV stent placement. The clinical characteristics of these patients are summarized in Table 1. The diagnosis of primary tumor was established by percutaneous biopsy in seven patients and surgically in the remaining seven patients. Seven patients had bile duct cancer, four patients had pancreatic adenocarcinoma, and three patients had a retroperitoneal endocrine tumor, porta hepatitis adenopathy from a gastric adenocarcinoma, or liver metastasis from colonic adenocarcinoma. In six patients, despite primary or secondary tumor resection including right hepatectomy for three patients, recurrent tumors invaded the PV. Primary tumors and metastasis involved the PV in the remaining eight patients.

Table 1 Clinical findings in 14 patients

Patient/Age (years)/Sex	Tumor	Clinical symptoms	Hepatectomy before portal stent placement
1/72/M	Recurrent bile duct adenocarcinoma	Refractory ascites, gastroesophageal varices	Yes
2/76/M	Bile duct adenocarcinoma	Ascites, gastroesophageal varices	No
3/68/M	Recurrent bile duct adenocarcinoma	Gastroesophageal varices	No
4/48/F	Bile duct adenocarcinoma	Refractory ascites	No
5/72/M	Adenopathy from stomach adenocarcinoma	Ascites	No
6/56/M	Retroperitoneal neuroendocrine tumor	Gastroesophageal varices	No
7/77/F	Liver metastasis from colonic adenocarcinoma	Ascites, gastroesophageal varices	Yes
8/73/M	Pancreatic adenocarcinoma	Ascites	No
9/65/F	Recurrent bile duct cancer	Gastroesophageal varices	No
10/73/M	Pancreatic adenocarcinoma	Thrombocytopenia, gastroesophageal varices	No
11/55/M	Recurrent bile duct cancer	Ascites, thrombocytopenia	Yes
12/40/F	Recurrent bile duct cancer	Refractory ascites	No
13/59/M	Pancreatic adenocarcinoma	Gastroesophageal varices	No
14/59/M	Recurrent pancreatic adenocarcinoma	Jejunal varices	No

Portal Hypertensive Symptoms

The most common symptom of malignant PHPVO was gastrointestinal varices, which were observed in nine patients (64.3%). Five of these patients were actively bleeding, and up to three sessions of endoscopic sclerotherapy were necessary. Clinical success was obtained in four cases of disease. The four other patients with esophageal ($n = 1$), gastric ($n = 2$), or jejunal ($n = 1$) varices were not actively bleeding. They did not undergo endoscopic treatment, but risk of rupture was assumed for all of them. Ascites developed in seven patients. Three of them were categorized as having refractory ascites following the criteria of Arroyo et al. [23]. Thrombocytopenia was noted for two patients (mean platelet count, 67,000/ μ L). Finally, five patients had more than one PVHT symptom.

Biliary Symptoms

Before PV stent placement, biliary drainage had been performed for malignant biliary stenosis or occlusion in five patients with biliary–enteric bypass ($n = 2$) or biliary stenting via an antegrade transhepatic route ($n = 1$) or a retrograde endoscopic approach ($n = 2$). At the time of the procedure of PV stent placement, four patients had jaundice related to a tumoral obstruction of the main bile duct ($n = 3$) or to a biliary stent occlusion ($n = 1$), and one patient had mild cholestasis most likely related to malignant invasion of an afferent Roux-en-Y afferent limb after

Whipple resection. The remaining four patients were free of biliary involvement (Table 2).

Procedure of Stent Placement

The nature of the procedure and its possible complications were fully explained to the patients and their families, and informed consent was obtained. All procedures were performed by two radiologists (P.C., A.D.), with the patient under general anesthesia.

For patients with obstruction of the main bile duct, the procedure began by a transhepatic biliary drainage. First, cholangiograms were obtained after puncture an intrahepatic biliary duct with a 22-gauge echo-tip needle under sonographic guidance. Second, an intrahepatic biliary duct was catheterized with a needle catheter under fluoroscopic and sonographic guidance. The main bile duct occlusion was crossed with a 0.035-inch stiff hydrophilic guide wire and dilated with a 10-mm in diameter balloon. Finally, an uncovered 10-mm-diameter self-expandable metallic stent was placed, and a 8.5-F internal–external drain was left in place for 3 to 5 days.

PV stent placement was then started by first puncturing a second-order portal branch with an 18-gauge percutaneous cholangiographic needle under sonographic guidance. For the three patients with refractory ascites and large amount of fluid around the right liver lobe, a paracentesis was performed first and a transhepatic route via the left lobe was chosen. An 8-F sheath was inserted into the PV, and a 4-F Cobra catheter (Terumo, Leuven, Europe) was advanced

Table 2 Characteristics of the procedure

Patient	Involved vessels	Portal venous pressures before stent placement (mmHg)			Portal venous pressures after stent placement (mmHg)			Biliary drainage
		Before stenosis	After stenosis	Gradient	Before stenosis	After stenosis	Gradient	
1	MPV	30	16	14	20	19	1	Yes
2	LPV, MPV	29	15	14	17	17	0	Yes
3	MPV	24	16	8	18	18	0	No
4	MPV	32	13	19	28	25	3	No (prior)
5	LPV, MPV, SV	12	6	6	8	8	0	Yes
6	MPV	28	18	10	21	20	1	No
7	LPV, MPV	25	20	5	22	22	0	Yes
8	MPV, SMV	24	16	8	25	24	1	No (prior)
9	MPV	21	15	6	21	20	1	No
10	MPV, SMV, SV	17	1	16	17	16	1	No (prior)
11	MPV	31	12	19	22	20	2	No
12	MPV	NA	NA	11	NA	NA	3	No (later)
13	SMV	NA	NA	10	NA	NA	2	No (prior)
14	SMV	14	4	10	6	5	1	No (prior)

MPV, main portal vein; LPV, left portal vein; SV, splenic vein; SMV, superior mesenteric vein; NA, not available

beyond the stenotic lesions, first in the superior mesenteric vein (SMV) and second in the splenic vein (SV). Two portograms were performed, each time with a volume of 30 mL of iodine contrast injected at the rate of 4 to 5 mL/s. PV occlusion was defined as complete blockade of contrast medium at the level of the PV lesion even if intrahepatic portal branches were opacified via collateral veins. Afterward, PV pressures were measured across the stenotic lesions by using a device (Eagle 3000, Hellige, Milwaukee, WI) connected to a monitor (Edwards Lifesciences, Irvine, CA). A pressure gradient across the stenosis was calculated and was assumed significant if it was ≥ 5 mmHg, as it is the case for PV stenosis in hepatic transplants [24]. The stenotic lesions were dilated with a balloon catheter 4 cm in length and 10 mm in diameter (Powerflex, Cordis endovascular, Roden, The Netherlands). Uncovered stents (SMART Control, Cordis, Miami, FL) were placed across the stenosis. The diameter and length of the stents were determined according to the diameter and length of involved vessels as measured during balloon dilation with caution to oversize the stent diameter by 1–2 mm. Stents used were typically 10–12 mm in diameter and 4–8 cm in length.

After the stents were deployed, portograms and measurements of PV pressures were repeated. An effective treatment was assumed when control venography showed rapid flow through the PV with absence of flow in the previously observed collaterals. A pressure gradient of 3 mmHg or less was considered a technical success as is the case for treatment of PV stenosis in hepatic transplants [24]. Finally, the sheath was replaced by a 5-F 20-cm catheter, and one to three 5-mm in diameter coils (Cook, Bjaeverskov, Denmark) were placed in the liver

parenchyma tract through this catheter while it was withdrawn. No anticoagulant therapy or antibiotic therapy were initiated before, during, or after stent placement.

Follow-up

Complications related to stent placement were evaluated. Patency of the stents was assessed by performing Doppler ultrasound or contrast-enhanced CT at the first week and every 3 months thereafter, or at any time if the symptoms of PVHT recurred or were judged not to have improved. Endoscopic control of patients with varices was scheduled 7 days after PV stent placement and every 6 months thereafter. The clinical courses after PV stent placement and the causes of death were studied from clinical records until April 1, 2005.

Statistical Analyses

The data were expressed as mean \pm standard deviation. Differences in portal pressures measured before and after stent placement were compared by performing the paired Student *t*-test. A *P* value of less than 0.05 was considered to indicate a statistically significant difference.

Results

Stent Placement

The results of PV stent placement are summarized in Tables 2 and 3. Fifteen stenosis and six occlusions were

Table 3 Clinical courses after portal venous stent placement

Patient	Complications	Resolution of symptoms	Patency/interval (days)	Survival (days)	Cause of death
1	No	Yes ^a	Occlusion/83	178	Cancer
2	No	Yes	Patent/122	122	Cancer
3	No	Yes	Patent/434	434	Alive
4	Minor perihepatic hematoma	Yes	Patent/32	32	Tumoral gastrointestinal bleeding
5	Biological pancreatitis	Yes	Patent/182	182	Cancer
6	No	Yes	Patent/342	342	Alive
7	No	No	Patent/14	14	Cancer
8	Minor portal dissection	Yes	Patent/137	137	Alive
9	Liver abscess	Yes	Patent/31	31	Cancer
10	No	Yes	Patent/92	92	Alive
11	No	No	Occlusion/2	71	Alive
12	No	Yes ^a	Occlusion/113	120	Cancer
13	No	Yes	Patent/96	96	Alive
14	No	Yes	Patent/30	30	Alive

^a Improvement until occlusion of the portal stent

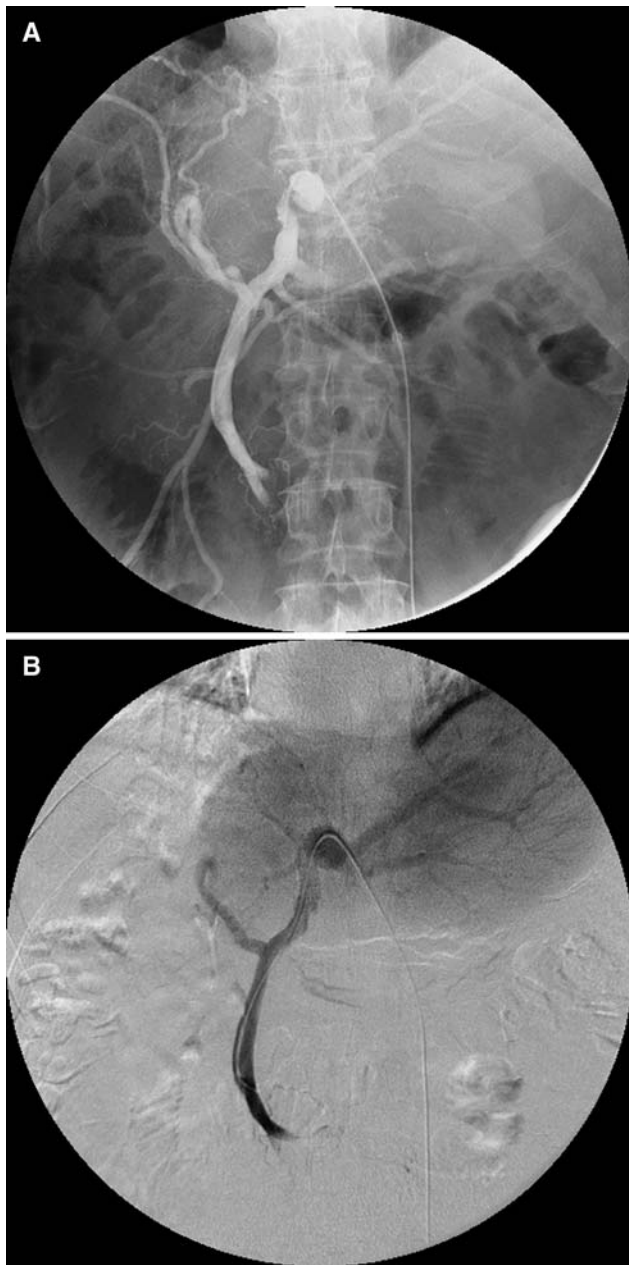


Fig. 1 A 55-year-old man who underwent a right hepatectomy 15 months ago for bile duct cancer (patient 11). Recurrent bile duct cancer responsible for ascites and thrombocytopenia. **A** Initial portography showing a stenosis of the distal part of the main PV leading to a 22 mmHg portal venous pressure gradient. **B** Repeated portography after portal venous stent placement and showing massive opacification of intrahepatic portal branches. The final portal venous pressure gradient was almost normalized (2 mmHg), but stent occlusion occurred 2 days later

found, involving the main PV ($n = 12$) (Figs. 1 and 2), the SMV ($n = 4$), the left PV ($n = 3$) (Fig. 2), or the SV ($n = 2$). All lesions were successfully catheterized and dilated. Two patients had an occlusion of both the main PV and the distal part of the SV, and one of them also had an

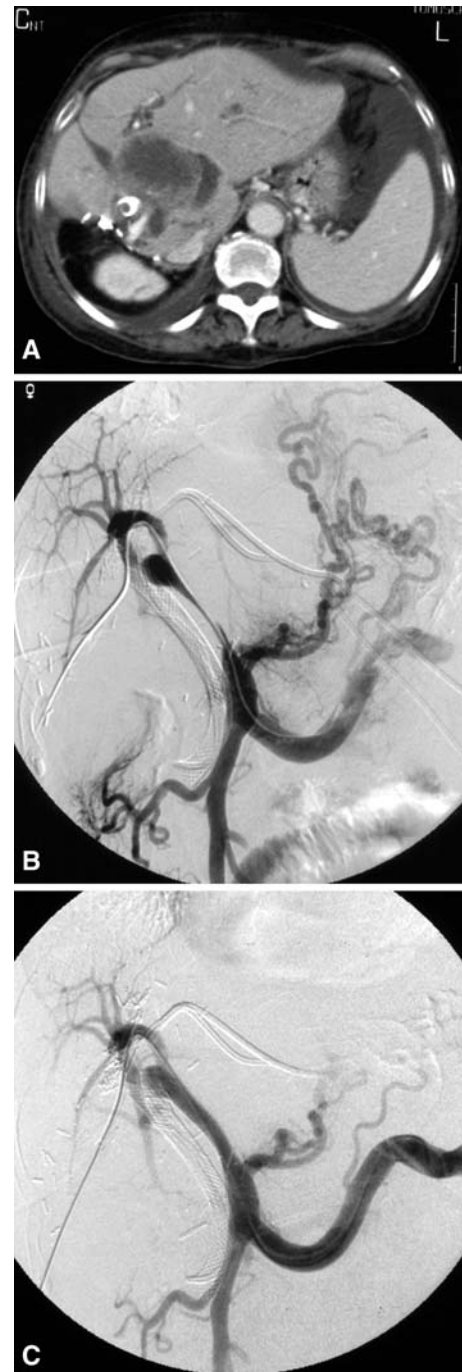


Fig. 2 A 77-year-old woman with liver metastasis from colonic adenocarcinoma leading to biliary malignant obstruction treated via the retrograde endoscopic route 3 months ago (patient 7). Current esophageal varices bleeding and ascites in relation to a malignant venous portal stenosis. **A** Contrast-enhanced computed tomography showing liver hilar metastasis inducing recurrent intrahepatic biliary dilation, stenosis of the main PV, and ascites. **B** Initial superior mesenteric venography showing the stenosis of the main PV extending to the left PV and esophageal varices. **C** Repeated superior mesenteric venography after portal venous stent placement with no residual filling of periesophageal venous collaterals. Ascites had not decreased by the time of the patient's death 14 days later

occlusion of the distal part of the SMV. In these two patients, a stent was initially placed from the distal part of the SMV to the distal part of the main PV, and a second stent was placed through the first one to treat the SV occlusion. The remaining patients had a single stent in the main PV or the SMV (Figs. 1 and 2). Even though it was technically feasible with a single transhepatic approach, we performed any stent placement for associated left intrahepatic PV stenosis by a second left transhepatic approach.

In all patients, repeated portograms showed an efficient treatment. After stent placement, the mean PV pressure decreased significantly ($P < 0.001$), from $23.9 \text{ mmHg} \pm 6.7$ (range, 12–32 mmHg) to $18.7 \text{ mmHg} \pm 6.3$ (range, 6–28 mmHg), and the mean intrahepatic portal pressure increased significantly ($P < 0.01$), from $12.7 \text{ mmHg} \pm 5.9$ (range, 4–20 mmHg) to $17.8 \text{ mmHg} \pm 5.9$ (range, 5–25 mmHg). As a result, the mean gradient of portal venous pressure was almost normalized and significantly decreased ($P < 0.00001$) from $11.2 \text{ mmHg} \pm 4.6$ (range, 5–19 mmHg) to $1.1 \text{ mmHg} \pm 1.0$ (range, 0–3 mmHg) after portal venous stent placement.

Biliary Drainage

Biliary drainage added in mean 33 ± 7.7 minutes (range, 24–42 minutes) to the time procedure. In all the patients, drainage was successfully performed in a single session, and a complete resolution of cholestasis was obtained.

Complications

Pain related to the puncture site was not prospectively evaluated because it was always minor and quickly subsided when treated with nonnarcotic analgesics.

Three patients had minor complications that did not require specific treatment. One patient developed a 2×3 cm subcapsular hematoma at the puncture site while the sheath was withdrawn before embolization of the liver parenchymal tract. Another patient developed a minor dissection of the main PV within 2 cm of length obstruction. The last patient, who had been treated for PV and main bile duct stenosis, developed a transient mild increase in biological pancreatic enzymes without any clinical symptoms.

One major complication occurred in a patient with a slight intrahepatic biliary dilation and a minor biological cholestasis. This patient did not undergo biliary drainage at the time of PV stenting and developed a liver abscess in the vicinity the coils left in the liver. This abscess was drained percutaneously for 5 days, and the patient died 26 days later for reasons related to his cancer and without any evidence of residual or recurrent sepsis.

Stent Patency, Evolution of Symptoms, and Survival

During the mean follow-up period of 134.4 ± 123.3 days (range, 30–434 days), PV stents remained patent in 11 patients (78.6%). Stent occlusion was suspected clinically and confirmed at Doppler ultrasound in two patients who developed sudden abdominal pain after 83 and 113 days, and was depicted at the first ultrasound control in a third asymptomatic patient. These three patients had been treated with PV stent placement for a stenosis ($n = 2$) or occlusion ($n = 1$) of the main PV. Two patients had had right hepatectomy 13 and 15 months before stent placement. In the last patient, contrast-enhanced CT control was consistent with a stent occlusion related to tumor ingrowth and overgrowth.

After stent placement, initial resolution of PVHT symptoms were noted for 12 patients (85.7%) without any residual varices at endoscopic control, ascites on imaging, or thrombocytopenia on laboratory testing. In one patient who had an early occlusion of the portal stent, ascites became refractory. In the last patient who died 14 days later in relation to his cancer, the ascites was not modified even though the stent remained patent, and gastroesophageal varices were not checked by endoscopy.

At the end of the follow-up, 10 patients (71.4%) were free of PVHT symptoms. Seven patients had died at 97.0 ± 71.2 days (range, 14–182 days) after stent placement, mainly as a result of cancer progression ($n = 6$). One patient died as a result of a tumoral gastrointestinal bleeding. Four patients (57.1%) remained asymptomatic until their death. Six (85.7%) of the seven surviving patients were free of symptoms 171.7 ± 153.5 days (range, 30–434 days) after stent placement.

Discussion

Procedures

PV stent placement has been described with a surgical approach via an ileal or jejunal vein [3, 13, 21, 24, 25] or a transjugular intrahepatic portosystemic shunt-type approach [4, 11, 18]. Nevertheless, as in our study, a transhepatic route has been most often used in the past with a very low rate of hemorrhagic complications [5, 6, 14–17, 20–22, 26]. As previously described in a published case report [27], we have had one minor subcapsular hematoma. Hemobilia related to a pseudoaneurysm of the hepatic artery has also been reported [15]. To prevent intraperitoneal hemorrhage, it is crucial to embolize the liver parenchymal tract when the sheath is withdrawn. Gelatin sponges [6, 14–16], biological tissue adhesive [17], and coils [4, 27] have all been used. We use coils instead of

gelatin sponges because their delivery is more precise and is not affected by potential massive bleeding through the liver tract. Although massive ascites also increases the hemorrhagic risk, it does not constitute an absolute contraindication to a transhepatic route. In this situation, a large paracentesis should first be performed with a left hepatic lobe approach used for stent placement because the amount of fluid around it is generally less than around the right lobe.

Synchronous biliary dilation secondary to biliary or afferent loop tumoral involvement has been described only rarely [14, 22]. Nevertheless, in our study, this situation was not unusual, occurring in five patients. Biliary drainage can be safely performed in the same session, adding only few minutes to the procedure. It seems that such a drainage is more important for the prevention of liver abscesses than it is for the prevention of hemobilia. Indeed, one case of liver abscess has been reported [14], and we have had the same experience with one of our patients; both cases involved patients who had undergone undrained intrahepatic biliary dilation with cholestasis.

Occlusion of Stents

To our knowledge, only one study has evaluated factors affecting patency of PV stents [15]. This particular study involved two groups of patients: one group of 17 patients with pancreatic or bile duct tumors stenosing or obstructing main PV, and the other group consisting of 23 patients with HCC extending from intrahepatic veins to main PV. They found a stent occlusion rate of 40% with a mean follow-up period of 11.9 months. Multivariate analysis demonstrated three factors significantly associated with a higher probability of stent occlusion: splanchnic vein involvement, cirrhotic patients classified Child-Pugh class C, and obstruction of the portal venous system. The authors concluded that patients with these characteristics should not be treated with stents. Pathophysiology of PV occlusion and clinical outcome for the two groups of patients included were quite different and this point constitute a major drawback of this study. Nevertheless, these results seem to indicate that there is a strong relationship between stent occlusion and a variety of causes reducing blood flow through the stented vessel, this relation being yet demonstrated experimentally with an animal model [24]. Indeed, liver dysfunction is correlated with a reduction of portal venous blood flow.

Splanchnic involvement can also reduce the mesenteric blood flow: splanchnic veins have a smaller diameter than the main PV, and adjacent arteries can be involved at the same time. We observed that previous major hepatectomy was associated with a higher rate of stent occlusion. This could possibly be explained by a reduction in portal blood

flow after surgery [28]. However the number of cases in our study does not allow for a definitive conclusion. This factor has not been evaluated by Yamakado et al. [15] and was not associated with stent occlusion in two observations found in the literature with previous hepatectomy and stent patency at 3-month and 19-month follow-up [10, 19].

On the other hand, to prevent stent thrombosis, Yamakado et al. [14–16] presume that anticoagulant therapy and/or antiplatelet therapy are essential because the stent itself exhibits thrombogenicity and because stents are not covered by neointima when they are implanted in a PV invaded by neoplasm [14, 15, 29]. In most published observations of venous stent placement for benign or malignant portal lesions, we can find utilization of such therapies without any standardized protocol [4, 6, 8, 11, 12, 17, 28]. However, there is a lack of randomized study to assess the exact usefulness of anticoagulation in case of portal stenting, and despite anticoagulation, half of cases of stent occlusion described by Yamakado et al. [15] were related to thrombus formation. As others [3, 5, 9, 10, 19, 20], we did not administer anticoagulants, and in 91.7% of the patients who had not previously undergone hepatectomy, stents remained patent, with a mean follow-up time of 137.4 days. We think that indication to anticoagulation should be weighted against the risk of gastrointestinal bleeding. In our study, more than half of the patients underwent PV stent placement for hemorrhagic varices, and one woman died in relation to tumoral and hemorrhagic gut ulcerations. Anticoagulation can be proposed when the placement of the portal stent allows a significant decrease in the flow or even embolization of dangerous varices as well as in situations such as when reduced flow through the stented vessels is expected or when an underlying hypercoagulable state is demonstrated [1].

Indications for Portal Venous Stent Placement

The indication for PV stent placement remains an individual decision that takes into consideration patient status, severity of stenosis, and the natural course of the disease [17]. PV stent placement can be one of the useful combined therapies in patients with symptomatic malignant PV stenosis or occlusion [14]. Except in patients with conditions predisposing to stent occlusion, it can allow relief of PVHT symptoms in a single session until patient's death [14–16, 20]. In our study, 71.4% of patients were free of symptoms during a mean follow-up of 134.4 days (range, 30–434 days). Among symptoms developing in a neoplastic context, ascites can be related to PVHT and/or peritoneal carcinosis. For one of our patients with advanced neoplastic status, relief of ascites was not observed in a follow-up of 14 days, despite initial technical success, normalization of PV gradient pressure, and stent patency. This failure may

have been the result of peritoneal carcinomatosis because it occurs in roughly two-thirds of patients with malignancy-related ascites [30]. Although challenging to detect with imaging, cytologic analysis of ascites is 100% sensitive [30]. As a result, if the etiology of ascites is unclear, cytologic analysis of peritoneal liquid should be performed before the decision of portal venous stent placement.

Even though veins occlude earlier than arteries as a result of tumor compression, venous lesions are often asymptomatic because of abundant collateralization. In our experience, this situation is observed in approximately half of patients with malignant venous stenosis or occlusion, especially in cases of pancreatic cancer. PV lesions related to bile duct cancer seem to be more frequently symptomatic because half of the patients included in our study had such primary or recurrent cancer. Decreased venous collateralization resulting from malignant invasion of epi- and parahepatic venous plexus could be an explanation. For patients who develop asymptomatic PV stenosis or occlusion, indication of venous stent placement remains unclear. Given the risk of portal stent occlusion, these patients should not undergo stent placement and must have a careful follow-up in order to intervene early if PVHT symptoms occur.

Study Limitations

As in the case of other published case series [14–16, 20], the main limitation of the present study is the small number of patients, which limits statistical analysis of factors affecting stent patency. The small number of patients having had prior major hepatectomy does not allow us to determine the role of this factor in the occurrence of PV stent occlusion. In addition, the cause of stent occlusion was not demonstrated by pathologic examination. Finally, this retrospective study does not assess objectively post-procedural minor complications such as pain or improvement in the patient's quality of life.

In conclusion, radiologists should keep in mind the option of PV stent placement during imaging follow-up of oncologic patients prone to develop malignant PV stenosis or occlusion, especially those with a bile duct cancer. This single-step therapeutic option most often constitutes an efficient treatment of symptoms related to PVHT.

References

- Sarin SK, Agarwal SR (2002) Extrahepatic portal vein obstruction. *Semin Liver Dis* 22:43–58
- Semiz-Oysu A, Keussen I, Cwikiel W (2007) Interventional radiological management of prehepatic obstruction of the splanchnic venous system. *Cardiovasc Intervent Radiol* 30: 688–695
- Harville LE, Rivera FJ, Palmaz JC, Levine BA (1992) Variceal hemorrhage associated with portal vein thrombosis: treatment with a unique portal venous stent. *Surgery* 111:585–590
- Schaible R, Textor J, Decker P et al (2002) Transjugular portal venous stenting in inflammatory extrahepatic portal vein stenosis. *Cardiovasc Intervent Radiol* 25:530–532
- Dagenais M, Pomier-Layrargues G, Dufresne MP et al (1994) Transhepatic portal vein stenting for treatment of ruptured duodenopancreatic varices in a patient with chronic pancreatitis. *Surgery* 115:669–673
- Maleux G, Vaninbrouckx J, Verslype C et al (2003) Pancreatitis-induced extrahepatic portal vein stenosis treated by percutaneous transhepatic stent placement. *Cardiovasc Intervent Radiol* 26: 395–397
- Nouria K, Bedioui H, Azaiez O et al (2007) Percutaneous drainage of suppurative pylephlebitis complicating acute pancreatitis. *Cardiovasc Intervent Radiol* 30:1242–1244
- Cwikiel W, Solvig J, Schroder H (2000) Stent recanalization of chronic portal vein occlusion in a child. *Cardiovasc Intervent Radiol* 23:309–311
- Hiraoka K, Kondo S, Ambo Y et al (2001) Portal venous dilatation and stenting for bleeding jejunal varices: report of two cases. *Surg Today* 31:1008–1011
- Vogelzang RL, Reddy SG, Braun MA, Nemcek AA (1996) Extrahepatic portal venous stenosis: treatment with percutaneous transhepatic stent placement. *J Vasc Intervent Radiol* 7:269–271
- Funaki B, Rosenblum JD, Leef JA et al (2000) Percutaneous treatment of portal venous stenosis in children and adolescents with segmental hepatic transplants: long-term results. *Radiology* 215:147–151
- Cherukuri R, Haskai ZJ, Naji A, Shaked A (1998) Percutaneous thrombolysis and stent placement for the treatment of portal vein thrombosis after liver transplantation: long-term follow-up. *Transplantation* 65:1124–1126
- McDaniel HM, Johnson M, Pescovitz MD et al (1997) Intraoperative placement of a wallstent for portal vein stenosis and thrombosis after liver transplantation. *Transplantation* 63: 607–608
- Yamakado K, Nakatsuka A, Tanaka N et al (2001) Portal venous stent placement in patients with pancreatic and biliary neoplasms invading portal veins and causing portal hypertension: initial experience. *Radiology* 220:150–156
- Yamakado K, Nakatsuka A, Tanaka N et al (2001) Malignant portal venous obstructions treated by stent placement: significant factors affecting patency. *J Vasc Intervent Radiol* 12:1407–1415
- Yamakado K, Tanaka N, Nakatsuka A et al (1999) Clinical efficacy of portal vein stent placement in patients with hepatocellular carcinoma invading the main portal vein. *J Hepatol* 30:660–668
- Heyne JP, Pfeleiderer SOR, Trebing G et al (2005) Palliative portal vein stent placement for lymphatic recurrence of gastric cancer. *Int J Colorectal Dis* 20:67–71
- Kaneoka Y, Yamaguchi A, Isogai M, Hori A (1998) Intraportal stent placement combined with right portal vein embolization against advanced gallbladder carcinoma. *Surg Today* 28:862–865
- Burger JA, Wirth AO, Berger DP et al (1997) The transjugular stent implantation for the treatment of malignant portal and hepatic vein obstruction in cancer patients. *Ann Oncol* 8:1–3
- Tsukamoto T, Hirohashi K, Kubo S et al (2003) Percutaneous transhepatic metallic stent placement for malignant portal vein stenosis. *Hepatogastroenterology* 50:453–455
- Watanabe Y, Sato M, Abe Y et al (1998) Metallic stents for low invasive recanalization of the portal veins with cancerous invasion: first case report. *Hepatogastroenterology* 45:551–553
- Bilbao JI, Ruza M, Longo JM et al (1994) Percutaneous transhepatic stenting by Wallstents of portal vein and bile duct

- stenoses caused by immunoblastic sarcoma in liver transplantation. *Cardiovasc Intervent Radiol* 17:210–213
23. Arroyo V, Ginès P, Gerbes AL et al (1996) Definition and diagnostic criteria of refractory ascites and hepatorenal syndrome in cirrhosis. *Hepatology* 23:164–176
 24. Denys A, Chevallier P, Doenz F et al (2004) Interventional radiology in the management of complications after liver transplantation. *Eur Radiol* 14:431–439
 25. Schellhammer F, am Esch JS, Hammerschlag S et al (2008) Surgical access to jejunal veins for local thrombolysis and stent placement in portal vein thrombosis. *Cardiovasc Intervent Radiol* 31:S185–S187
 26. Adani GL, Baccarani U, Risaliti A et al (2007) Percutaneous transhepatic portography for the treatment of early portal vein thrombosis after surgery. *Cardiovasc Intervent Radiol* 30:1222–1226
 27. Bhattacharjya T, Olliff SP, Bhattacharjya S et al (2000) Percutaneous portal vein thrombolysis and endovascular stent for management of posttransplant portal venous conduit thrombosis. *Transplantation* 69:2195–2198
 28. Kawasaki T, Moriyasu F, Kimura T et al (1991) Changes in portal blood flow consequent to partial hepatectomy: Doppler estimation. *Radiology* 180:373–377
 29. Richter GM, Palmaz JC, Noeldge G, Tio F (1999) Relationship between blood flow, thrombus, and neointima in stents. *J Vasc Intervent Radiol* 10:598–604
 30. Runyon BA, Hoefs JC, Morgan TR (1988) Ascitic fluid analysis in malignancy-related ascites. *Hepatology* 8:1104–1109