

Transcranial color-coded duplex sonography allows to assess cerebral perfusion pressure noninvasively following severe traumatic brain injury

Giovanna Brandi · Markus Béchir · Susanne Sailer ·
Christoph Haberthür · Reto Stocker · John F. Stover

Received: 17 November 2009 / Accepted: 17 March 2010 / Published online: 9 April 2010
© Springer-Verlag 2010

Abstract

Objective Assess optimal equation to noninvasively estimate intracranial pressure (eICP) and cerebral perfusion pressure (eCPP) following severe traumatic brain injury (TBI) using transcranial color-coded duplex sonography (TCCDS).

Design and setting This is an observational clinical study in a university hospital.

Patients A total of 45 continuously sedated (BIS < 50), normoventilated (paCO₂ > 35 mmHg), and non-febrile TBI patients.

Methods eICP and eCPP based on TCCDS-derived flow velocities and arterial blood pressure values using three different equations were compared to actually measured ICP and CPP in severe TBI patients subjected to standard treatment. Optimal equation was assessed by Bland–Altman analysis.

Results The equations: $ICP = 10.927 \times PI(\text{pulsatility index}) - 1.284$ and $CPP = 89.646 - 8.258 \times PI$ resulted in eICP and eCPP similar to actually measured ICP and CPP with eICP 10.6 ± 4.8 vs. ICP 10.3 ± 2.8 and eCPP 81.1 ± 7.9 vs. CPP 80.9 ± 2.1 mmHg, respectively. The other two equations, $eCPP = (MABP \times EDV) / mFV + 14$ and $eCPP = [mFV / (mFV - EDV)] \times (MABP - RR_{diast})$, resulted in significantly decreased eCPP values: 72.9 ± 10.1 and 67 ± 19.5 mmHg, respectively. Superiority of the first equation was confirmed by Bland–Altman revealing a smallest standard deviations for eCPP and eICP.

Conclusions TCCDS-based equation ($ICP = 10.927 \times PI - 1.284$) allows to screen patients at risk of increased ICP and decreased CPP. However, adequate therapeutic interventions need to be based on continuously determined ICP and CPP values.

Keywords Pulsatility index · Secondary brain damage · Transcranial Doppler

G. Brandi · M. Béchir · S. Sailer · R. Stocker · J. F. Stover
Surgical Intensive Care, University Hospital Zuerich,
Zurich, Switzerland

G. Brandi
Neurosurgical Intensive Care Unit, Department of Anesthesia
and Critical Care Medicine, Fondazione IRCCS Ospedale
Maggiore Policlinico, Mangiagalli e Regina Elena,
Milano, Italy

C. Haberthür
Department of Anesthesiology, Kantonsspital,
Luzern, Switzerland

J. F. Stover (✉)
Chirurgische Intensivmedizin, UniversitätsSpital Zürich,
Rämistrasse 100,
8091 Zurich, Switzerland
e-mail: john.stover@access.unizh.ch

Introduction

Following severe traumatic brain injury (TBI) increased intracranial pressure (ICP) and decreased cerebral perfusion pressure (CPP) aggravate underlying damage and induce further structural and functional impairment. In order to adapt type and extent of therapeutic interventions, ICP and CPP must be determined. In clinical routine, ICP is measured invasively by inserting a special pressure probe in the subdural space, parenchyma, or ventricular system. This, of course, requires a surgical intervention with its surgery-related risks as, e.g., hemorrhage, additional tissue damage, and infection. Based on the continuously deter-

mined ICP and mean arterial blood pressure (MABP) values, CPP is then calculated ($CPP = MABP - ICP$). This requires an ICP probe and arterial cannulation.

Since its introduction in clinical routine, transcranial doppler sonography (TCD) has proven helpful in unmasking pathological perfusion states, i.e., vasospasm and hyperemia which require differential therapeutic interventions. In this context, absolute flow velocities as well as calculated values, e.g., the pulsatility index (PI) and resistance index (RI) allow more specific insight into otherwise occult but important abnormal intracranial alterations [8]. Due to the interaction between ICP and flow velocity within the brain supplying intracranial arteries, ICP as well as CPP values can be estimated using TCD. This is an elegant screening method of noninvasively assessing changes in ICP and CPP. For this, three different mathematical equations have been described [2, 3, 13]. While Bellner et al. determined ICP and CPP based on the calculated PI [2], Schmidt et al. [13] and Edouard et al. [3] estimated CPP according to changes in flow velocities and arterial blood pressure.

To date, however, these three different equations have not yet been compared in the same patients to determine which formula will yield most accurate values compared to invasively measured ICP and CPP calculated on the basis of measured MABP and ICP. For this, transcranial color-coded duplex sonography (TCCDS) performed in a total of 45 patients with severe TBI was used to determine the optimal equation allowing to noninvasively assess ICP and CPP.

Materials and methods

Following prospective assessment of flow velocities of the middle cerebral artery (MCA) as a part of daily routine in 45 continuously sedated (BIS EEG < 50), normoventilated ($paCO_2 > 35$ mmHg), and non-febrile (temperature < 38°C) patients with severe TBI a post hoc analysis was performed. This retrospective analysis was approved by the local ethics committee which waived the need for written informed consent.

Standardized intensive care treatment

Following severe TBI intubated and ventilated patients were treated according to our standardized treatment protocol. Following CT diagnostic and surgical interventions including insertion of an ICP probe (Neurovent®, Raumedic, www.raumedic.de), patients were transferred to our ICU. All Neurovent® probes are pre-calibrated, and the zero value is stored on the implanted chip as a characteristic electronic value. Once the ICP probe is connected to the

“zero point simulator” (NPS2), the interface to the bed side monitor, the ICP probe can be zeroed against ambient air pressure. Zero compensation is performed at least every 8 h at the beginning of the new working shift of the nursing staff. At the same time point, the arterial catheter placed in the radial or femoral artery for invasive blood pressure monitoring is zeroed against ambient air pressure at the level of the heart, providing the patient is maintained flat. Whenever the patient’s head is elevated up to 30° or decreased from an elevated position, the blood pressure transducer is adjusted to correct for the hydrostatic pressure as suggested by the BrainIT Group [1]. In addition, changes in ICP as well as changes in jugular venous oxygen saturation ($SjvO_2$) and $ptiO_2$ are used to unmask cerebral ischemia due to changing of the patient’s position.

Continuous analgesia (fentanyl) and sedation (midazolam) was controlled by BIS EEG (BIS VISTA™, www.aspectmedical.com) tapering drug dosage to maintain a BIS level between 20 and 40. Norepinephrine, dobutamine, and volume were administered to maintain CPP above 70 mmHg. Differentiated CPP management was guided by $ptiO_2$, microdialysis, and transcranial color-coded duplex sonography which allowed to taper CPP to values as low as 60 mmHg or as high as 110 mmHg according to revealed hyperemia or vasospasm. Ventilation was guided by $SjvO_2$ and $ptiO_2$. Transfusion requirement was guided by $ptiO_2$ values maintaining hematocrit $\geq 24\%$ and $ptiO_2 \geq 15$ mmHg. Brain temperature was maintained between 35°C and 36.0°C using cooling blankets or an intravenous cooling system (CoolGard3000®, Alsius, www.alsius.com). Treatment measures were adapted and tapered to maintain ICP < 20 mmHg. Patients received enteral nutrition via gastric or jejunal tube which was started within the first 12 h. Administered calories was adapted according to indirect calorimetry performed at least twice weekly.

Transcranial color-coded duplex sonography

All TCCDS examinations and derived calculations were performed daily by the same investigator (JFS or GB) to maintain the lowest levels of “operator variability” [7]. TCCDS recordings were conducted transtemporally using a 2-MHz transducer (Siemens, Sonoline G40, www.siemens.com). Both MCAs were investigated. Color-coding allows exact identification of the MCA with its characteristic upward pointing and distal Y-shaped appearance. Visual as well as acoustic signals reflecting flow velocity were used to determine optimal depth and angle of insonation. For each daily TCCDS, the average of two flow measurements was used for subsequent calculations.

Calculations

ICP was estimated based on the equation published by Bellner et al. [2]

$$1. \text{ ICP} = 10.927 \times \text{PI} - 1.284.$$

For this, PI was calculated: $\text{PSV} - \text{EDV}/\text{mFV}$ (White) [17]

CPP was estimated based on the equation reported by

2. Bellner et al.: $\text{CPP} = 89.646 - 8.258 \times \text{PI}$
3. Schmidt et al.: $\text{CPP} = \text{MABP} \times \text{EDV}/\text{mFV} + 14$ [13];
4. Edouard et al.: $\text{CPP} = [\text{mFV}/(\text{mFV} - \text{EDV})] \times (\text{MABP} - \text{RRdiast})$; (RRdiast = diastolic arterial blood pressure) [3]

ICP was calculated by subtracting CPP from MABP.

Statistical analysis

eICP and eCPP calculated by three different equations (Bellner et al., Schmidt et al., Edouard et al.) [2, 3, 13] were compared to the continuously measured ICP (real ICP) and CPP (real CPP) values by Bland–Altman analysis for repeated measures. Differences in absolute values were compared by ANOVA on ranks followed by post hoc multiple comparison vs. real ICP and real CPP using the Dunn's test. Graphical and statistical analysis was performed using SigmaPlot11[®] (www.systat.com).

Results

Patients

All investigated patients (37 male, eight female; median age, 37; range 15–70 years) exhibited mixed lesions predominantly consisting of contusions with/without edema, additional subdural hematoma, additional traumatic subarachnoid hemorrhage. Six patients were craniectomized unilaterally. Eight patients died.

TCCDS

A total of 834 measurements were performed. In order to exclude possible confounding factors, only TCCDS data were taken from deeply sedated (BIS EEG < 50), normoventilated ($\text{paCO}_2 > 35$ mmHg), and non-febrile (temperature < 38°C) patients. This resulted in 601 TCCDS measurements, i.e., 72% of the total measurements. On average, seven TCCDS measurements were performed for each patient over time, ranging from 1–18 measurements. On average, two measurements (one on each side) were successfully performed in each patient per day of TCD. The

majority of patients and consequently the majority of TCD measurements were encountered during the first 14 days (Fig. 1).

To assess the impact of interhemispheric pathologies, CPP and ICP were calculated using the three different equations [2, 3, 13] depending on the side of inserted ICP, comparing TCCDS data determined ipsilateral to the ICP probe with TCCDS data obtained contralateral to the ICP probe for elevated as well as normal flow velocities. In addition, the impact of outcome comparing deceased with surviving patients was also investigated. Furthermore, data were compared in craniectomized and non-craniectomized patients. Based on these evaluations, neither side of ICP insertion nor mortality nor craniectomy influenced the calculated CPP and ICP values (data not shown).

Based on the different values (PSV, EDV, mFV, PI, RI, RR_{systolic}, RR_{diastolic}, MABP), estimated ICP and CPP were calculated (Table 1). PI and RI were significantly increased compared to healthy controls [17], reflecting intracranial pathology.

According to these results eICP and eCPP calculated using the equation published by Bellner et al. [2] were similar to the real ICP and CPP values (Fig. 2).

eCPP as well as eICP calculated by the equation published by Schmidt et al. [13] and Edouard et al. [3] was significantly decreased compared to real CPP and real ICP (Fig. 2).

Scatter plot analysis for individual measurements

Based on the different equations, the distribution of all individual eICP and eCPP values showed the least variance when determined by the equation by Bellner et al. [2] compared to the equations published by Schmidt et al. [13] and Edouard et al. [3] (Figs. 3 and 4).

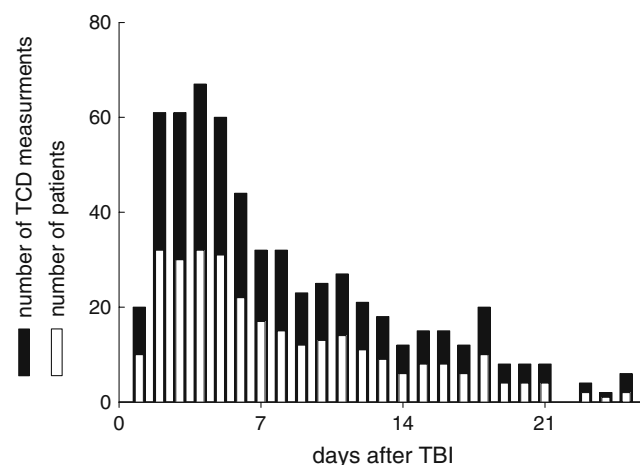


Fig. 1 Total number of TCD measurements (*black bars*) performed daily and the corresponding number of patients investigated daily (*white bars*)

Table 1 Descriptive statistics of raw data and calculated pulsatility index (PI) and resistance index (RI) determined in the mean cerebral artery (MCA) using transcranial color coded Duplex sonography

	Mean ± SEM	Median	Range
PSV [cm/s]	132±57	120	30–338
EDV [cm/s]	52±27	46.	6–174
mFV [cm/s]	79±36	71.4	18.7–220
PI	1.1±0.2	1.1	0.4–2.5
RI	0.6±0.1	0.6	0.3–0.9
RRsystolic [mmHg]	136±15	135	70–182
RRdiastolic [mmHg]	68±8	67	51–90
MABP [mmHg]	91±9	90	63–121
ICP [mmHg]	11±0.3	10	0–32
CPP [mmHg]	81±0.5	80	61–109

Compared to normal PI (0.72±0.075) and RI (0.55±0.042) values determined by Rainov et al. [11], PI and RI were significantly increased in the presently investigated patients reflecting intracranial pathology

Bland–Altman analysis for repeated measures

Using the equation by Bellner et al. [2] eICP and eCPP showed lowest variation when compared to the equations published by Schmidt et al. [13] and Edouard et al: [3] median ICP difference±2-fold SD, -3.2±12.6 mmHg

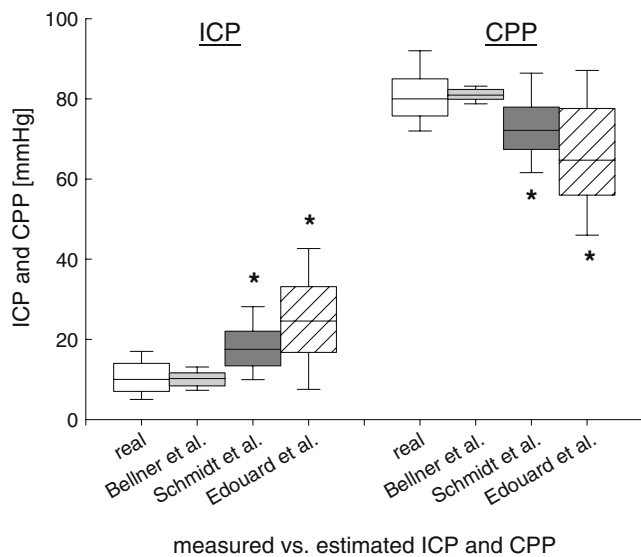


Fig. 2 Changes in ICP and CPP estimated by changes in transcranial color-coded duplex sonography based on the equations published by Bellner et al. (gray box plots), Schmidt et al., (dark gray box plots), and Edouard et al. (cross hatched box plots) compared to real ICP (white box plots). ICP was significantly increased, and CPP was significantly decreased using the equations by Schmidt et al. and Edouard et al. compared to Bellner et al. and real values (* $p < 0.001$; ANOVA, post hoc Dunn's test)

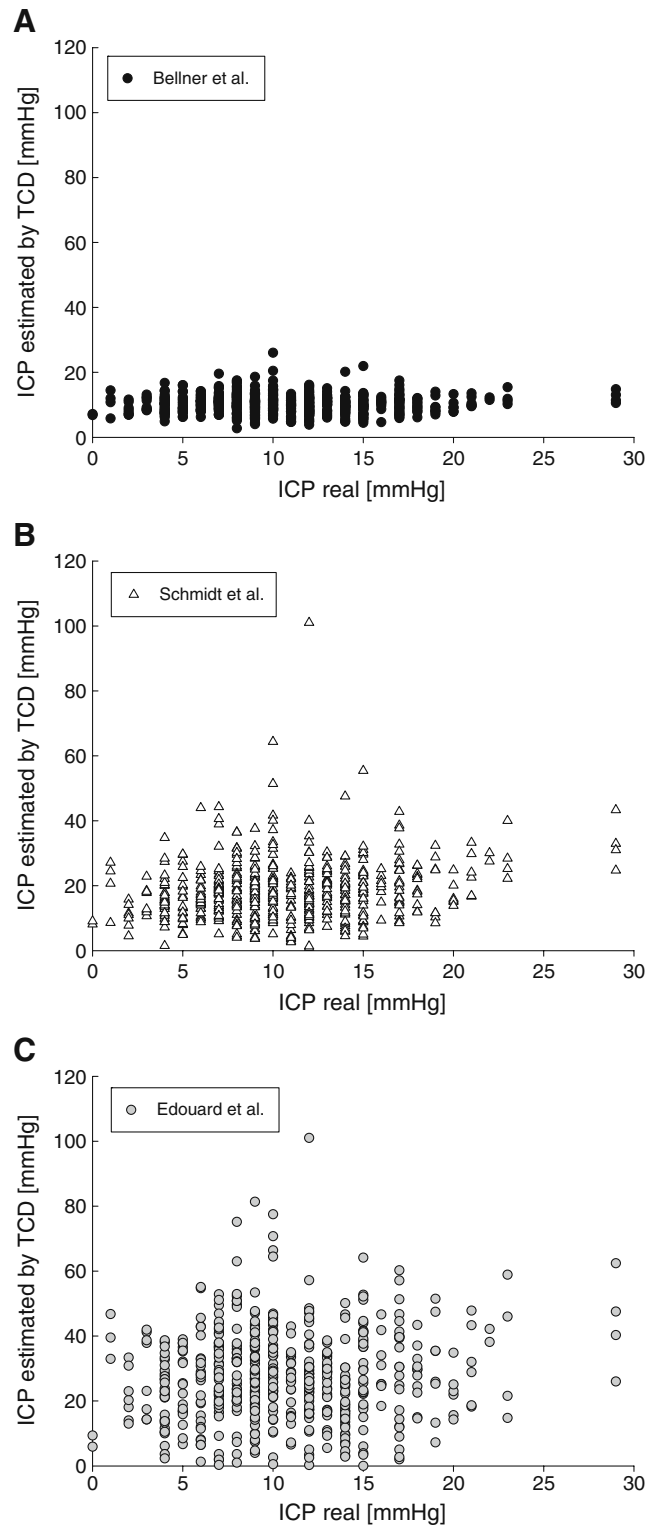


Fig. 3 Distribution of individual estimated ICP values determined by the equation by Bellner et al. (a), Schmidt et al. (b), Edouard et al. (c) compared to the actually measured ICP values. Smallest variance was encountered when calculating ICP using the equation by Bellner et al. (a)

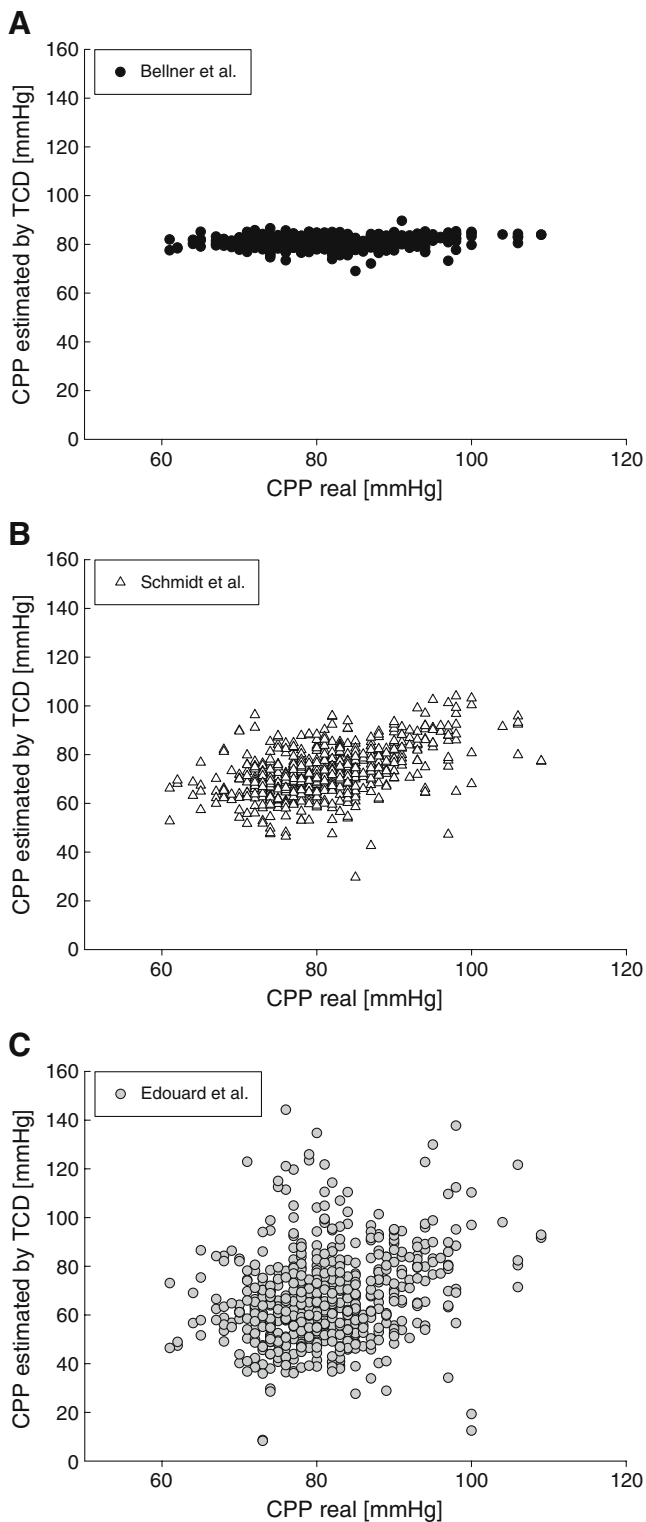


Fig. 4 Distribution of individual estimated CPP values determined by the equation by Bellner et al. (a), Schmidt et al. (b), Edouard et al. (c) compared to the actually measured CPP values. Smallest variance was present when calculating CPP using the equation by Bellner et al. (a)

(Bellner et al. [2]), 5.6 ± 17.4 mmHg (Schmidt et al. [13]), 6.8 ± 19.7 mmHg (Edouard et al. [3]); median CPP difference ± 2 -fold SD, -0.2 ± 18.4 mmHg (Bellner et al. [2]), -5.5 ± 20.6 mmHg (Schmidt et al. [13]), -6.8 ± 45.2 mmHg (Edouard et al. [3]; Figs. 5 and 6).

Discussion

The aim of the study was to compare three different published equations to noninvasively assess CPP and ICP allowing to identify a formula with the most accurate values compared to invasively measured real ICP and CPP.

As shown in the present study, the equation proposed by Bellner et al. [2] for eCPP and eICP proved to be superior compared to equations published by Schmidt et al. [13] and Edouard et al. [3]. The values obtained from these last two equations, in fact, do not allow to reliably estimate ICP and CPP, as clearly highlighted by the large distribution of eICP and eCPP in Figs. 3 and 4.

TCD sonography is used for routine noninvasive diagnosis of cerebrovascular disorders including severe traumatic brain injury [6, 9–12, 15]. Identification of the MCA can be done with high degree of certainty as this artery is seldom confused with neighboring arteries due to its characteristic anatomical structure and position. Furthermore, TCCDS, in contrast to the “blind” TCD, allows outlining of parenchymal structures and visualization of the examined vessel in color [5, 16]. The possibility to noninvasively estimate CPP and ICP based on TCCDS-derived flow velocities and arterial blood pressure values is of interest to treating physicians as this would allow insight into intracranial pathology without having to insert an ICP probe.

In this context, Bellner, Schmidt, and Edouard and colleagues previously demonstrated that it is possible to not invasively estimate CPP [2, 3, 13]. Furthermore, Bellner proposed an equation to also estimate ICP [2]. Using the equations for CPP published by Schmidt and Edouard, it is possible to calculate eICP by subtracting eCPP from measured MABP.

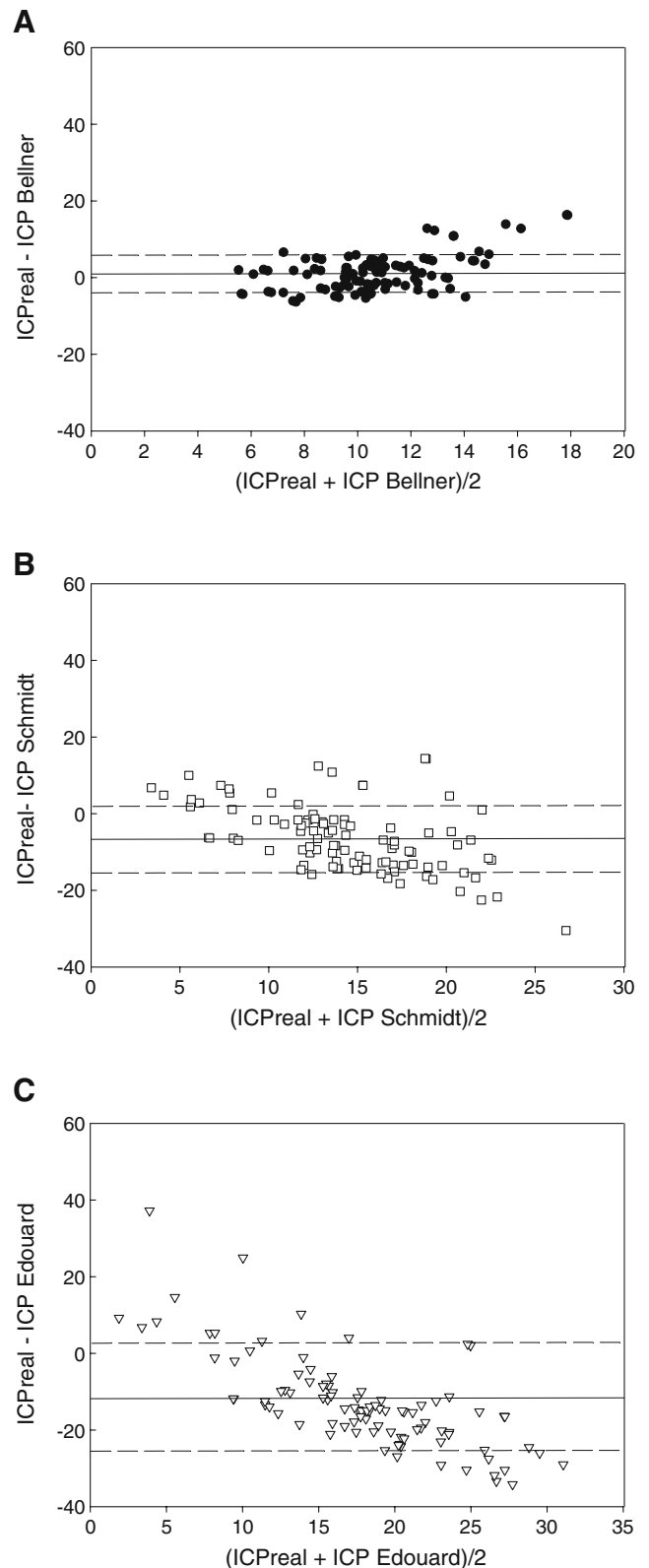
Despite the useful information obtained by TCD, this technique has certain limitations in daily clinical routine. Apart from the initial high acquisition costs TCD does not visualize all intracranial arteries and cannot be used in all patients as bone and dura may interfere with the required insonation depth. While MCA can be identified more easily, it is difficult to visualize ACA and PCA which precludes accurate measurement of flow velocity. Reliable flow values with low inter-operator variability can only be achieved with appropriate training and experience; in addition, repetitive measurements are advocated to reduce the intra-operator variability [7]. Intermittent TCD limits its

Fig. 5 Bland–Altman analysis comparing three different equations with which ICP was estimated based on predefined changes in transcranial color-coded duplex sonography with the actually measured real ICP. The *solid line* depicts median difference in ICP, and the *dashed lines* show the two-fold standard deviation for the equation by Bellner et al. (a), Schmidt et al. (b), and Edouard et al. (c). Best results were obtained using the equation published by Bellner and colleagues

usefulness for continuous decision making in daily routine. Continuous recordings, as reported by others [13–16], would not only be helpful but are also prone to artifacts especially when the position of the patients is changed. While intermittent TCD is acceptable as a complementary screening method as employed in the present study, continuous TCD recordings are indispensable to assess and judge more dynamic changes in terms of disturbed cerebral autoregulation [13–16]. Since TCD can neither be used in all patients nor for the assessment of all intracranial arteries, it is obvious that a wide application of this technique is limited. Thus, TCD can only aid in assessing ICP and CPP values and help to guide ICP- and CPP-dependent therapeutic decision making in a subset of patients.

Importance of noninvasively estimated ICP and CPP

Various diseases and instances other than TBI profit from noninvasive determination of ICP and CPP, e.g., subarachnoid hemorrhage following ruptured aneurysm, liver failure, and obstetrical complications [8]. Especially in hepatic failure and obstetrical complications, insertion of an ICP probe is associated with an increased risk of additional damage due to hemorrhage in case of disturbed coagulation. Thus, noninvasive estimation of ICP and CPP can increase insight into pathologic intracranial alterations which otherwise remain obscured. In this context, noninvasive estimation of ICP and CPP is of importance, e.g., in those trauma patients without any obvious structural lesions on CT scan despite an initial pathologic GCS and a high-velocity injury. This also pertains to those patients who have not yet awoken from anesthesia as well as those TBI patients in whom disturbed coagulation requires correction before an ICP probe can be placed. Thus, this method can be used to screen patients and to guide therapeutic interventions as a bridging procedure until an ICP probe is inserted. As pointed out by Ract and colleagues, TCD can aid in implementing adequate TCD-guided treatment with the aim of restoring cerebral perfusion [4]. For this, however, a simple and accurate formula is needed. Compared to the other two equations [3, 13], the equation published by Bellner et al. [2] only requires values determined by TCD or TCCDS (PSV, EDV, mFV) which



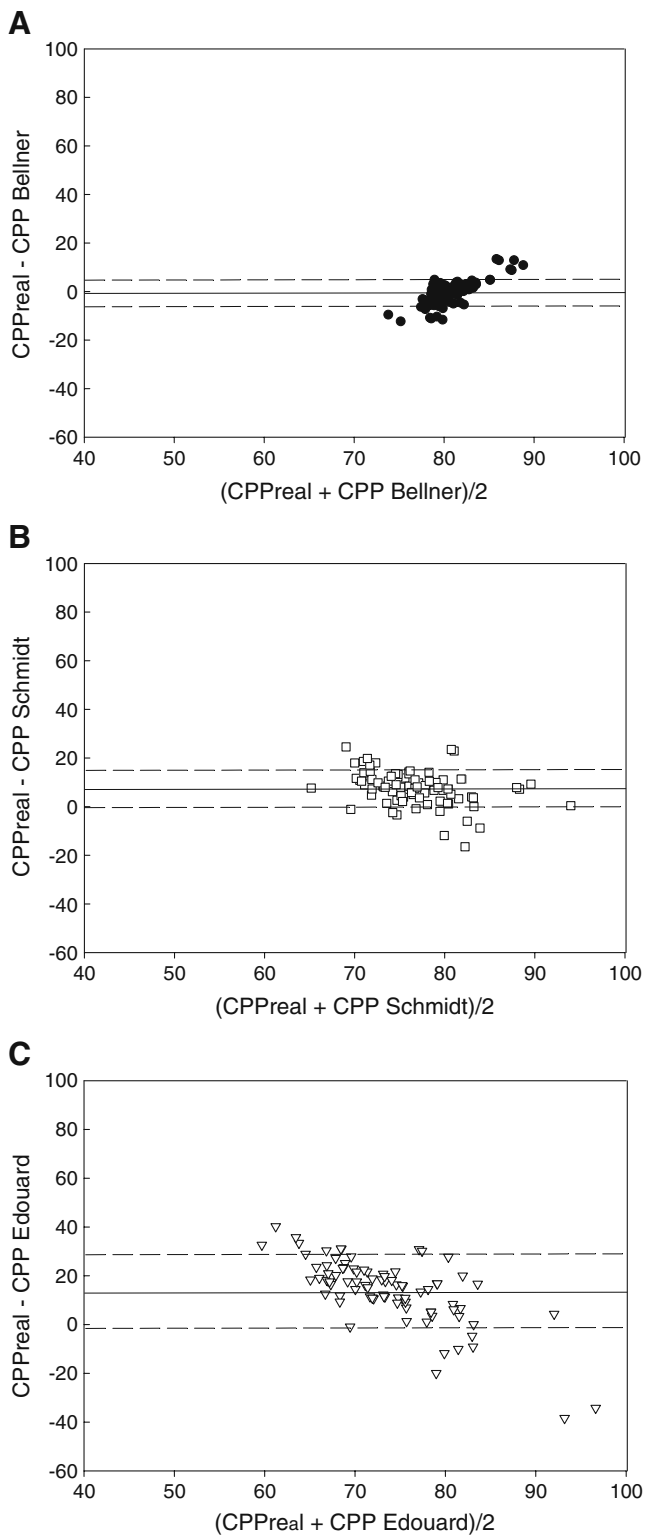


Fig. 6 Bland–Altman analysis comparing three different equations with which CPP was estimated based on predefined changes in transcranial duplex sonography with the actually calculated real CPP. The *solid line* depicts median difference in CPP and the *dashed lines* show the two-fold standard deviation for the equation by Bellner et al. (a), Schmidt et al. (b), and Edouard et al. (c). Best results were obtained using the equation published by Bellner and colleagues

are used to calculate the PI ($PI = PSV - EDV / mFV$) and does not include arterial blood pressure values.

How accurate are estimated ICP and CPP values?

Based on the calculated standard deviation for ICP and CPP determined by the Bland–Altman analysis, it becomes obvious that eICP and eCPP estimated noninvasively are only a crude guidance to detect underlying pathology. This especially pertains to predefined ICP and CPP threshold values which require specific therapeutic interventions to maintain and reach these threshold values. Thus, we are faced with overestimation of ICP as well as underestimation of CPP based on noninvasive assessment using the equations published by Schmidt and colleagues [13] and Edouard and coworkers [3], respectively. Consequently, therapeutic decision making should be based on a safe method which generates continuous data and which is less influenced by the individual investigator.

Limitations of the present study

Unfortunately, the number of patients is insufficient to identify any lesion-specific alterations which might also influence flow velocities, derived PI and RI, and the calculated ICP and CPP values.

Nevertheless, the number of patients taken from clinical routine suffices to determine applicability of different equations as reflected by the significant differences between the different equations. A further limitation is that actually measured ICP was below 40 mmHg. Nevertheless, the results are in line with data obtained by Bellner et al. who described a significant correlation at ICP values ranging from 5 to 40 mmHg. In the present study, intracranial flow velocities were determined once daily while ICP and CPP were assessed continuously. Continuous measurement of flow velocities of the MCA as performed by Soehle et al. [11] requires special equipment and is prone to artifacts in case the transducer head slips out of place. Comparing estimated ICP and CPP to actual values implies that the actually measured ICP values are correct. For this, only patients with an adequately appearing ICP curve were used for the present evaluation.

Conclusion

The equation published by Bellner et al. [2] to non-invasively estimate ICP and CPP is superior to the equations described by Schmidt et al. [13] and Edouard et al. [3]. Thus, this approach is useful in clinical routine and serves as a screening tool in patients at risk. However, to guarantee appropriate treatment and to adequately guide

therapeutic interventions, continuously recorded ICP and CPP are indispensable.

Acknowledgements The help of the ICU nursing staff in collecting clinical data is gratefully acknowledged.

Disclosure/Conflict of interest None.

Funding This study was supported in parts by grants from the Swiss National Research Foundation and the SUVA Fonds to JFS and RS.

References

- BrainIT Standards—Hydrostatic Pressure Gradients and CPP. www.brainit.org/bit2web/faces/Standards_hpg.jsp
- Bellner J, Romner B, Reinstrop P, Kristiansson KA, Ryding E, Brandt L (2004) Transcranial Doppler sonography pulsatility index (PI) reflects intracranial pressure (ICP). *Surg Neurol* 62:45–51
- Edouard AR, Vanhille E, Le Moigno S, Benhamou D, Mazoit JX (2005) Non-invasive assessment of cerebral perfusion pressure in brain injured patients with moderate intracranial hypertension. *Br J Anaesth* 94:216–221
- Kochanowicz J, Krejza J, Mariak Z, Bilello M, Lyson T, Lewko J (2006) Detection and monitoring of cerebral hemodynamic disturbances with transcranial color-coded duplex sonography in patients after head injury. *Neuroradiology* 48:31–36
- Krejza J, Rudzinski W, Pawlak MA, Tomaszewski M, Ichord R, Kwiatkowski J, Gor D, Melhem ER (2007) Angle-corrected imaging transcranial doppler sonography versus imaging and nonimaging transcranial doppler sonography in children with sickle cell disease. *AJNR Am J Neuroradiol* 28:1613–1618
- Lee JH, Kelly DF, Oertel M, McArthur DL, Glenn TC, Vespa P, Boscardin WJ, Martin NA (2001) Carbon dioxide reactivity, pressure autoregulation, and metabolic suppression reactivity after head injury: a transcranial Doppler study. *J Neurosurg* 95:222–232
- McMahon CJ, McDermott P, Horsfall D, Selvarajah JR, King AT, Vail A (2007) The reproducibility of transcranial Doppler middle cerebral artery velocity measurements: implications for clinical practice. *Br J Neurosurg* 21:21–27
- Moppett IK, Mahajan RP (2004) Transcranial Doppler ultrasonography in anaesthesia and intensive care. *Br J Anaesth* 93:710–724
- Oertel M, Kelly DF, Lee JH, McArthur DL, Glenn TC, Vespa P, Boscardin WJ, Hovda DA, Martin NA (2002) Efficacy of hyperventilation, blood pressure elevation, and metabolic suppression therapy in controlling intracranial pressure after head injury. *J Neurosurg* 97:1045–1053
- Ojha BK, Jha DK, Kale SS, Mehta VS (2005) Transcranial Doppler in severe head injury: evaluation of pattern of changes in cerebral blood flow velocity and its impact on outcome. *Surg Neurol* 64:174–179
- Ract C, Le Moigno S, Bruder N, Vigué B (2007) Transcranial Doppler ultrasound goal-directed therapy for the early management of severe traumatic brain injury. *Intensive Care Med* 33:645–651
- Rainov NG, Weise JB, Burkert W (2000) Transcranial Doppler sonography in adult hydrocephalic patients. *Neurosurg Rev* 23:34–38
- Schmidt EA, Czosnyka M, Gooskens I, Piechnik SK, Matta BF, Whitfield PC, Pickard JD (2001) Preliminary experience of the estimation of cerebral perfusion pressure using transcranial Doppler ultrasonography. *J Neurol Neurosurg Psychiatry* 70:198–204
- Soehle M, Czosnyka M, Pickard JD, Kirkpatrick PJ (2004) Continuous assessment of cerebral autoregulation in subarachnoid hemorrhage. *Anesth Analg* 98:1133–1139
- Soehle M, Chatfield DA, Czosnyka M, Kirkpatrick PJ (2007) Predictive value of initial clinical status, intracranial pressure and transcranial Doppler pulsatility after subarachnoid haemorrhage. *Acta Neurochir (Wien)* 149:575–583
- Swiat M, Weigele J, Hurst RW, Kasner SE, Pawlak M, Arkuszewski M, Al-Okaili RN, Swiercz M, Ustymowicz A, Opala G, Melhem ER, Krejza J (2009) Middle cerebral artery vasospasm: transcranial color-coded duplex sonography versus conventional nonimaging transcranial Doppler sonography. *Crit Care Med* 37:963–968
- White H, Venkatesh B (2006) Applications of transcranial Doppler in the ICU: review. *Intensive Care Med* 32:981–994