

Percutaneous iliosacral screw fixation in S1 and S2 for posterior pelvic ring injuries: technique and perioperative complications

Georg Osterhoff · Christian Ossendorf ·
Guido A. Wanner · Hans-Peter Simmen ·
Clément M. L. Werner

Received: 19 July 2010 / Published online: 28 December 2010
© Springer-Verlag 2010

Abstract

Objective Percutaneous iliosacral screw placement allows for minimally invasive fixation of posterior pelvic ring instabilities. The objective of this study was to describe the technique for screws in S1 and S2 using conventional C-arm and to evaluate perioperative complications.

Methods Thirty-eight consecutive patients after percutaneous pelvic ring fixation with cannulated screws in S1 and S2 using conventional C-arm fluoroscopy were analysed. Accuracy of screw placement, neural lesions, need for second surgery, operation time, and time to full weight bearing were assessed postoperatively and during regular follow-up examinations.

Results Twenty-one patients underwent unilateral screw fixation and 17 patients underwent bilateral screw fixation. In total, 83 screws were placed. Mean age of the patients was 52 ± 19 years. Mean operation time was 16 ± 7 min/screw. Mean follow-up was 5 ± 3 months. Time to full weight bearing in 28 patients was 9 ± 4 weeks. Eight patients were still not able to support full weight bearing, partially due to concomitant injuries. Patients without concomitant injuries that affected walking were able to bear full weight after 8 ± 4 weeks ($n = 17$). Two patients had persistent postoperative hypaesthesia. No motor weakness was apparent and no postoperative bleeding was observed. Secondary surgery due to screw malpositioning or loosening had to be performed in four patients. The

presence of a screw in S2 was not indicated for perioperative complications.

Conclusions Percutaneous iliosacral screw fixation is a rapid and definitive treatment for posterior pelvic ring injuries with a low risk of secondary bleeding during posterior pelvic stabilization. The technique using standard C-arm fluoroscopy was also found to be safe for screws placed in S2.

Keywords Iliosacral screw fixation · Pelvic fracture · Pelvic ring injuries · Sacroiliac joint disruption

Introduction

Numerous ways to restore the stability of the posterior pelvic ring were described [7, 10, 11, 18, 21]. With the advent of standardized intraoperative imaging algorithms [3, 5, 15], percutaneous screw placement has gained popularity allowing for minimally invasive early definitive fixation of fractures and disruptions of the posterior pelvic ring. In order to increase precision of screw positioning, various techniques for CT-guided/computer-navigated screw positioning were described [13, 27]. Yet, in the emergency room (ER) with patients in urgent need for early primary care, these time-consuming techniques are unsuitable. In contrast, fluoroscopy provides a straightforward and inexpensive approach to intraoperative visualization. While placing of single screws is usually considered sufficient, two ipsilateral screws were found to provide more biomechanical stability than the one in an experimental setup [24, 25]. However, using conventional fluoroscopy, many orthopedic trauma surgeons limit the placement of iliosacral screws to the pedicles of S1, as those of S2 are narrow and difficult to visualize [6, 8].

G. Osterhoff (✉) · C. Ossendorf · G. A. Wanner ·
H.-P. Simmen · C. M. L. Werner
Department of Surgery, Division of Trauma Surgery,
University Hospital Zurich, Raemistrasse 100,
8091 Zurich, Switzerland
e-mail: georg.osterhoff@usz.ch

Here, we describe a technique using conventional fluoroscopy for simultaneous placement of screws in S1 and S2 and evaluate the peri- and postoperative complications.

Methods

Thirty-eight patients with pelvic ring instabilities who underwent percutaneous iliosacral fixation using cannulated screws (Synthes, Oberdorf, Switzerland) at our institution between 10/2008 and 03/2010 were enrolled in the present study and their data were analyzed. Fracture morphology was classified on three-dimensionally reconstructed pelvic CT-scans as previously described [26]. Indications for surgical treatment were vertical shear (VS) fractures, lateral compression (LC) type II and III, and anteroposterior compression (APC) type III. For APC II fractures, the indication for surgery was restricted to obese patients and/or patients that had to be mobilized quickly (i.e., elderly patients). Patients with LC I fractures were operated when conservative treatment (mobilisation under analgesic medication) was insufficient for more than 1 week.

Surgery was performed with the patient in supine position. Closed reduction was maintained by lateral compression. If this was not sufficient or there was a major vertical displacement, distal femoral traction was applied by means of a supracondylar pin. In some cases, an anterior external fixation device or an anterior symphyseal plate had been inserted already.

Cannulated screws (7.3 mm) were placed using conventional C-arm (BV Libra, Andover, MA, USA) fluoroscopy (inlet, outlet, and lateral view). For S1 this was done as described previously [8, 15].

For S2, the entry point was chosen in the center plane between cranial and caudal endplate, a few millimetres dorsally of the vertebral body's posterior margin in the lateral view. A 2.7 mm K-wire was inserted carefully aiming ventrally. Using the inlet projection, the anterior margin of S2 was brought into sharper focus (Fig. 1) and the K-wire was

placed further dorsally of S2 crossing the median plane. The craniocaudal direction is confirmed in the outlet view and care was taken not to affect the neural foramina.

In patients with comminuted sacral fractures, we used fully threaded screws to avoid additional displacement or neural lesions by compression. Otherwise, threads of 32 mm were placed in terms of a lag screw to improve reduction. In patients with insufficient bone stock, two ipsilateral screws were inserted. One screw each was placed in S1 and S2 if preoperative CT imaging revealed no anatomical variation contraindicating it otherwise; two screws were placed in S1. Operation time, including positioning of both patient and C-arm, and wound closure was recorded.

Postoperatively, patients without concomitant gait affecting injuries were mobilized with 15 kg partial weight bearing for 8 weeks.

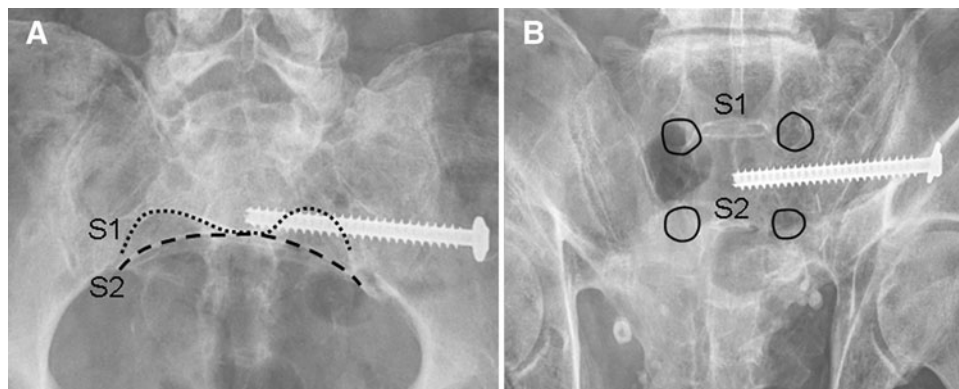
Reduction and accuracy of screw positioning was evaluated postoperatively using CT scans and conventional X-rays. Postoperative CT scans were reconstructed in three planes corresponding to the axes of the first two sacral vertebrae. Fracture and vertical displacement were determined and classified as previously described by Nelson and Duwelius [13]. Fracture displacement was defined as the widest distance between the fragments when measured perpendicular to the fracture line [9]. Vertical displacement was defined as the vertical dislocation of the cranial auricular face of the ilium. In patients with more than one fracture, the widest fracture gap was taken into account.

Complications were evaluated based on follow-up radiographs (pelvic AP) and retrospective chart review of the patients' medical records. The incidence of screw malpositioning, implant failure or neurological deficits, the time to full-weight bearing and the need for second surgery were documented.

Statistical analysis

Statistical analysis of nominal data was done using two-sided Fisher's Exact tests, and correlation analysis of metric data was processed using the Spearman's rho (r) test with

Fig. 1 Placement of screws in S2. The anterior margin of S2 is brought into sharper focus in the inlet view (*left*). In the outlet view (*right*) care is taken not to interfere with the neural foramina or the intervertebral disc space



SPSS for windows 17.0 (SPSS, Chicago, Illinois, USA). Differences were considered significant for values of $p < 0.05$.

Results

In total, 83 screws were placed in 38 patients (male 22, female 16). Seventeen patients underwent unilateral screw fixation and 21 patients underwent bilateral screw fixation (Fig. 2). Sixty-two screws were placed in S1 (26 patients). Twenty-one screws were placed in S2 (16 patients) and in 13 patients this was done in combination with a screw in S1.

Mean age of the patients was 52 ± 19 years. Median operation time including the positioning of C-arm and wound closure was 16 ± 7 min per screw. Median time between trauma and surgery was 2 ± 7 days. Yet, iliosacral screw fixation was performed directly after admittance (i.e., the same day) in 13 patients. The remaining patients were operated on after a rather prolonged primary stabilization in the intensive care unit. Two patients died during their stay at hospital due to unrelated causes and one of them died before a postoperative CT scan was done. In 37 patients, fracture fragment reduction was excellent (displacement

≤ 5 mm) in 24 (65%), good (displacement 5–10 mm) in 11 (30%) and fair (displacement 10–15 mm) in 2 (5%) according to the classification described by Nelson and Duwelius [13]. Vertical reduction was excellent in 31 patients (84%), good in 5 (14%) and fair in 1 (3%). A displacement more than 15 mm was not observed.

Mean follow-up of the remaining 36 patients was 5 ± 3 months. Time to full weight bearing in 28 patients was 9 ± 4 weeks. Eight patients were still not able to put full weight on the operated extremity at the latest follow-up (mean 3 ± 3 months), partially due to concomitant injuries. Patients without concomitant injuries that affected walking were able to bear full weight after 8 ± 4 weeks ($n = 17$). Two patients had persistent postoperative hypaesthesia in the L5/S1 dermatomes. One of these patients, however, had a compartment syndrome of the ipsilateral thigh, making the differentiation of causality difficult. No motor weakness was apparent in any of the patients, and no postoperative bleeding due to the insertion of an iliosacral screw was observed. Secondary surgery due to screw malpositioning or loosening had to be performed in four patients (Table 1). One patient sustained pulmonary embolism and one patient presented with non-union, 13 months after surgery.

Screw malpositioning or loosening was observed in three patients with S2 screws and two needed secondary

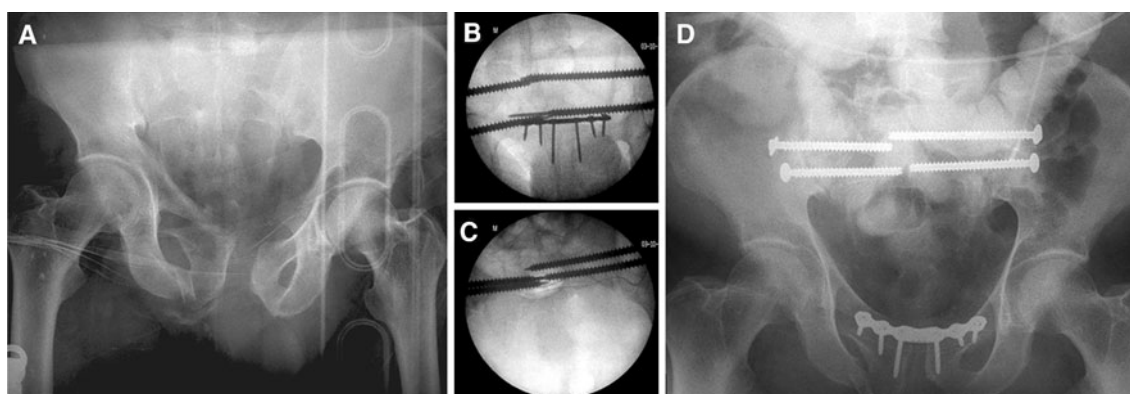


Fig. 2 Radiographs of patient no. 26 (male, 54 years). The patient was admitted to our ER with pelvic ring injury type APC-III with LC III-component of the contralateral right side **a** and blunt abdominal trauma secondary to traumatic entrapment on a construction site. Percutaneous

screws were placed in S1 and S2 bilaterally using the conventional fluoroscopy with outlet **b** and inlet **c** projections. Anterior stability was maintained by a symphyseal plate **d**

Table 1 Postoperative complications and need for secondary surgery

	Type of fracture						VS	Total
	LC I	LC II	LC III	APC I	APC II	APC III		
<i>N</i>	2	26	4	0	5	0	1	38
Screw malpositioning	0	3	1	0	0	0	0	4 (10.5%)
Nerval lesions	0	2	0	0	0	0	0	2 (5.3%)
Non-union	0	0	0	0	0	0	1	1 (2.6%)
Postoperative bleeding	0	0	0	0	0	0	0	0 (0.0%)
Secondary surgery	0	3	0	0	0	0	1	4 (10.5%)

surgery. Two of 16 patients with S2 screws had persistent hypaesthesia in the L5/S1 dermatomes. In one of these patients, it was due to malpositioning of a S1 screw, in others due to malpositioning of S2 screw. The presence of S2 screws was not a significant indicator for the occurrence of neural lesions ($p = 0.17$, Fisher's Exact, two-sided), or other complications (i.e., screw malpositioning, non-union, embolism) ($p = 0.45$) or second surgery ($p = 0.29$).

Furthermore, the placement of S2 screws had no influence on the time to full weight bearing ($r = 0.28$, $p = 0.16$).

Discussion

The purpose of the present study was to describe the technique of iliosacral screw fixation in S1 and S2 using conventional C-arm fluoroscopy and to evaluate perioperative complications. While there are other studies focussing on iliosacral screw fixation, the present study is the first to describe the technique of iliosacral screw placement in S2 in detail. Our data suggest that the insertion of screws in S2 does not increase the risk for malpositioning, neural lesions or secondary surgery. Even though these findings were statistically significant, one has to consider statistical effects associated with the relatively small number of patients.

A key limitation of all studies of pelvic ring fractures is the broad spectrum of concomitant injuries with an impact on postoperative and long-term outcome. Also in the present study, more than half of the patients had injuries affecting the ability to walk (for example: calcaneal fracture, open fractures of the lower extremity, and tetraplegia).

We used the classification introduced by Young and Burgess [26] which has been shown to provide better intra- and interobserver reliability [4, 12] than the one established by Tile [22].

The postoperative reduction was good-to-excellent in most of the cases (95%). Comparable results have been published previously [5, 9]. Previous studies reported screw malpositioning rates of 3–17% [5, 8, 16, 19, 23] and neural lesions in 0–8% [5, 8, 14, 16, 19, 23]. This is consistent with our data, even though the distribution of fracture severity was different or could not be identified due to different applied classification systems. Although various techniques for CT-guided or computer-navigated screw insertion have been described [1, 2, 13, 17, 20, 27], their use in the treatment of trauma patients is controversial. While higher precision of screw placement was described for computer-assisted surgery [2, 20, 27] others found no difference between navigated or CT-guided and conventional screw placement [1, 17, 20]. A difference in the occurrence of neural lesions, however, was observed in none of these studies.

Especially, CT-guided placement is time consuming and associated with problems resulting of operating in a CT suite [1]. In some studies, operation time could be reduced by the usage of computer-assisted systems [27], others reported an increased or comparable time of the procedure [2, 17, 27]. Additionally, preparing the setup for the navigation system takes additional time. When navigation is based on a preoperative CT, potential fracture displacements between CT and surgery are not accommodated. Clearly, navigated-systems have the advantage of reduced fluoroscopy time [1, 2, 17, 27] and will improve operation time in the future. Yet, one-third of the patients in this study were operated on directly after their admittance into the trauma room in terms of primary stabilization. This suggests the need for a rapid and immediately available technique for posterior pelvic ring stabilization in certain patients. Thus, the conventional technique of screw insertion remains relevant in the trauma setup.

Conclusion

Percutaneous iliosacral screw fixation using conventional fluoroscopy is a rapid treatment with a low risk of secondary bleeding during posterior pelvic stabilization in patients with pelvic ring injuries. The placement of screws in S2 seems not to increase the risk for screw malpositioning, neural lesions or secondary surgery. In the present study, the procedure using standard C-arm fluoroscopy was found to be safe in the hands of surgeons acquainted with knowledge of the pelvic anatomy and its fluoroscopic correlations.

Conflict of interest The authors declare that they have no conflict of interest.

References

1. Briem D, Rueger J, Begemann P et al (2006) Computerassistierte Verschraubung des hinteren Beckenrings. *Unfallchirurg* 109(8): 640–646
2. Briem D, Windolf J, Rueger JM (2007) Perkutane, 2D-fluoroskopisch navigierte Sakrumverschraubung in Rückenlage. *Der Unfallchirurg* 110(5):393–401
3. Farrell EDMD, Gardner MJMD, Krieg JCMD, Chip Routt ML-JMD (2009) The upper sacral nerve root tunnel: an anatomic and clinical study. *J Orthop Trauma* 23(5):333–339
4. Furey AJMDF, O'Toole RVMD, Nascone JWMD, Sciadini MFMD, Copeland CEMD, Turen CMD (2009) Classification of pelvic fractures: analysis of inter and intraobserver variability using the Young-Burgess and Tile classification systems. *Orthopedics* 32(6):401–406
5. Gänsslen A, Hüfner T, Krettek C (2006) Percutaneous iliosacral screw fixation of unstable pelvic injuries by conventional fluoroscopy. *Oper Orthop Traumatol* 18(3):225–244

6. Gautier E, Bächler R, Heini PF, Nolte LP (2001) Accuracy of computer-guided screw fixation of the sacroiliac joint. *Clin Orthop Relat Res* 393:310–317
7. Gunterberg B, Goldie I, Slätis P (1978) Fixation of pelvic fractures and dislocations. An experimental study on the loading of pelvic fractures and sacro iliac dislocations after external compression fixation. *Acta Orthop Scand* 49(3):278–286
8. Hilgert RE, Finn J, Egbers HJ (2005) [Technique for percutaneous iliosacral screw insertion with conventional C-arm radiography]. *Unfallchirurg* 108(11):954, 956–960
9. Jacob AL, Messmer P, Stock KW et al (1997) Posterior pelvic ring fractures: closed reduction and percutaneous CT-guided sacroiliac screw fixation. *Cardiovasc Intervent Radiol* 20(4):285–294
10. Josten C, Schildhauer TA, Muhr G (1994) [Therapy of unstable sacrum fractures in pelvic ring. Results of osteosynthesis with early mobilization]. *Chirurg* 65(11):970–975
11. Käch K, Trentz O (1994) [Distraction spondylodesis of the sacrum in “vertical shear lesions” of the pelvis]. *Unfallchirurg* 97(1):28–38
12. Koo HMDF, Leveridge MMD, Thompson CMD et al (2008) Interobserver reliability of the Young-Burgess and Tile classification systems for fractures of the pelvic ring. *J Orthop Trauma* 22(6):379–384
13. Nelson DW, Duwelius PJ (1991) CT-guided fixation of sacral fractures and sacroiliac joint disruptions. *Radiology* 180(2):527–532
14. Peng KT, Huang KC, Chen MC, Li YY, Hsu RW (2006) Percutaneous placement of iliosacral screws for unstable pelvic ring injuries: comparison between one and two C-arm fluoroscopic techniques. *J Trauma* 60(3):602–608
15. Routt ML Jr (2006) Posterior pelvic-ring disruptions: iliosacral screws. In: *Wiss DA (ed) Fractures*. Lippincott Williams & Wilkins, Philadelphia, pp 649–667
16. Routt ML Jr, Simonian PT, Mills WJ (1997) Iliosacral screw fixation: early complications of the percutaneous technique. *J Orthop Trauma* 11(8):584–589
17. Schep NW, Haverlag R, van Vugt AB (2004) Computer-assisted versus conventional surgery for insertion of 96 cannulated iliosacral screws in patients with postpartum pelvic pain. *J Trauma* 57(6):1299–1302
18. Schildhauer TA, Josten C, Muhr G (2006) Triangular osteosynthesis of vertically unstable sacrum fractures: a new concept allowing early weight-bearing. *J Orthop Trauma* 20(1 Suppl):S44–S51
19. Schweitzer D, Zylberberg A, Cordova M, Gonzalez J (2008) Closed reduction and iliosacral percutaneous fixation of unstable pelvic ring fractures. *Injury* 39(8):869–874
20. Smith HEMD, Yuan PSMD, Sasso RMD, Papadopolous SMD, Vaccaro ARMD (2006) An evaluation of image-guided technologies in the placement of percutaneous iliosacral screws. *Spine* 31(2):234–238
21. Suzuki T, Hak DJ, Ziran BH et al (2009) Outcome and complications of posterior transiliac plating for vertically unstable sacral fractures. *Injury* 40(4):405–409
22. Tile M (1988) Pelvic ring fractures: should they be fixed? *J Bone Joint Surg Br* 70(1):1–12
23. van den Bosch EWMD, van Zwielen CMAMD, van Vugt ABMD (2002) Fluoroscopic positioning of sacroiliac screws in 88 patients. *J Trauma* 53(1):44–48
24. van Zwielen CMAM, van den Bosch EWMDP, Snijders CJP, Kleinrensink GJP, van Vugt ABMDP (2004) Biomechanical comparison of sacroiliac screw techniques for unstable pelvic ring fractures. *J Orthop Trauma* 18(9):589–595
25. Yinger K, Scalise J, Olson SA, Bay BK, Finkemeier CG (2003) Biomechanical comparison of posterior pelvic ring fixation. *J Orthop Trauma* 17(7):481–487
26. Young JW, Burgess AR, Brumback RJ, Poka A (1986) Pelvic fractures: value of plain radiography in early assessment and management. *Radiology* 160(2):445–451
27. Zwingmann J, Konrad G, Kotter E, Sudkamp NP, Oberst M (2009) Computer-navigated iliosacral screw insertion reduces malposition rate and radiation exposure. *Clin Orthop Relat Res* 467(7):1833–1838