

Journal of NeuroVirology, 14: 78–84, 2008

© 2008 Journal of NeuroVirology

ISSN: 1355-0284 print / 1538-2443 online

DOI: 10.1080/13550280701793940

informa
healthcare

Case Report

Adaptation of antiretroviral therapy in human immunodeficiency virus infection with central nervous system involvement

Matthias Mehling,¹ Henning Drechsler,^{2,3} Jens Kuhle,¹ Martin Hardmeier,¹ Ruediger Doerries,⁴ Stephan Ruegg,¹ and Achim Gass¹

¹Department of Neurology and ²Department of Internal Medicine, University Hospital of Basel, Switzerland

³Division of Infectious Diseases, University of Texas Southwestern, Dallas, Texas, USA

⁴Department of Virology, University Hospital of Mannheim, Germany

The authors describe a patient with known human immunodeficiency virus (HIV)-1 infection who presented with two generalized seizures and was found to have extensive white matter disease and a left/bilateral temporo-occipital focal slowing on electroencephalography (EEG). There were no magnetic resonance imaging (MRI) or cerebrospinal fluid (CSF) indications for opportunistic infection. Plasma viremia was controlled, whereas viral replication was uncontrolled in CSF. CSF-specific genotype-guided adaptation of the antiretroviral therapy in order to optimize central nervous system (CNS) penetration resulted in clinical improvement and normalization of MRI and EEG. Our case report illustrates the importance of individualized antiretroviral therapy in HIV infected patients with neurological complications. *Journal of NeuroVirology* (2008) 14, 78–84.

Keywords: antiretroviral therapy CNS; CNS infection; HAART; HIV; HIV CNS; HIV epilepsy

Case report

In August 2003, a 40-year-old man with longstanding human immunodeficiency virus (HIV)-1 infection presented with a first-generalized tonic-clonic seizure. HIV-infection was known since 1987 and the patient was enrolled in a methadone program since 1986. He took zidovudine monotherapy from 1993 to 1997, and was on highly active antiretroviral therapy (HAART) since 1997. From 1997 to 2003 he was treated with lamivudine and stavudine complemented with indinavir from 1997 to 1999, and nelfinavir from 1999 to 2003 (Figure 1). He also had a brief exposure to efavirenz, which was stopped because of neuropsychiatric side effects. The patient's nadir CD4+ T-cell count was 166/ μ l (11%) before HAART initiation; but his CD4+ T cells rose

rapidly and remained $>400/\mu$ l since 1998 whereas his viremia remained only partially controlled (always <1000 copies/ml from 1997 to 2004). He never experienced any opportunistic infection or malignancy. HIV plasma genotyping in 2003 revealed the presence of the D30N and N88D/N mutation, which mediate resistance to nelfinavir and the M184V and T215Y mutation conferring resistance to lamivudine and partial resistance to stavudine. However, because his viral load was always <1000 copies, the patient chose to remain on his HAART regimen. At the time of the first seizure, the patient's CD4+ T-cell count was 794/ μ l (14%) and his plasma viral load was 281 copies/ml. Magnetic resonance imaging (MRI) revealed diffuse frontal and temporal white matter T2-hyperintensities. Contrast-enhanced studies were negative. These findings were consistent with HIV-1-associated encephalopathy and not suggestive for opportunistic infection. The patient remained otherwise asymptomatic and did not show any signs of cognitive impairment. Twelve months later his HAART regimen was changed for more convenient dosing to once-daily ritonavir/atazanavir,

Address correspondence to Matthias Mehling, MD, Department of Neurology, University Hospital Basel, Petersgraben 4, CH-4031 Basel, Switzerland. E-mail: mehlingm@uhbs.ch

Received 23 July 2007; revised 17 September 2007; accepted 10 October 2007.

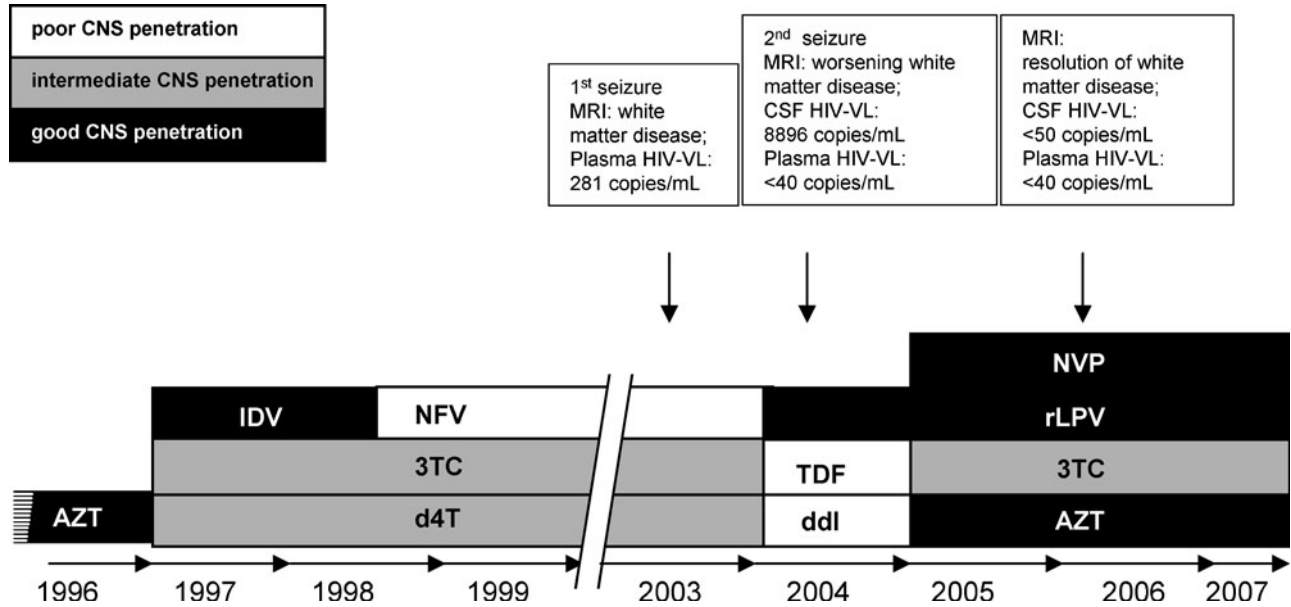


Figure 1 Chronology of antiretroviral therapy with quantification of CNS penetration. VL: viral load. AZT = zidovudine; d4T = stavudine; 3TC = lamivudine; IDV = indinavir; NFV = nelfinavir; rATV = ritonavir-boosted atazanavir; TDF = tenofovir; ddl = didanosine; LPV = ritonavir-boosted lopinavir; NVP = nevirapine.

with didanosine and tenofovir. His plasma viral load now became undetectable (<40 copies/ml). Two months later he experienced another generalized seizure, which prompted a neurological evaluation, which was unremarkable without signs of cognitive or memory impairment. Repeat MRI showed moderate progression of the diffuse white matter disease (Figure 2A). Electroencephalography (EEG) revealed subtle background alterations with a bilateral temporo-occipital focal slowing (Figure 3A).

Cerebrospinal fluid (CSF) analysis revealed pleocytosis ($32 \times 10^6/L$), elevated protein (917 mg/L), and immunoglobulin G (IgG) (527 mg/L) and oligoclonal bands. Serologic assays for borreliae, syphilis, herpes simplex virus, and varicella zoster virus (VZV) were negative as well as polymerase chain reaction (PCR) assays for *Toxoplasma gondii*, JC virus, Epstein Barr virus, cytomegalovirus, and VZV. The cerebrospinal fluid (CSF) HIV viral load was 8896 copies/ml, whereas plasma viremia remained undetectable (<40 copies/ml). Genotyping of the CSF virus revealed thymidine-analogue mutations M41L and T215Y, conferring intermediate resistance to zidovudine and low-level resistance to didanosine and tenofovir, the A98G polymorphism on the reverse transcriptase gene, and L63P polymorphism on the protease gene. Attempting to adapt the patient's HAART for higher efficacy against the HIV quasispecies in central nervous system (CNS) and for optimal CSF penetration, his regimen was now changed to nevirapine, zidovudine and lamivudine, and lopinavir/ritonavir. The patient was also started on antiepileptic therapy with levetiracetam, which he discontinued after 4 months. He has remained

seizure free for almost 3 years to date and still shows no sign of cognitive impairment. A follow-up MRI demonstrated normalization of previous T2-hyperintensities with some widening of the lateral ventricles probably indicating resolution of edema, possibly unmasking some degree of subcortical brain atrophy (Figure 2B). A follow-up EEG after 19 months had also almost normalized (Figure 3B). CSF analysis 12 months after switching to CNS-adapted HAART showed resolution of pleocytosis and reduction in total protein (679 mg/L) and IgG (345 mg/L). The CSF HIV viral load was now undetectable (<50 copies/ml).

Discussion

Epileptic seizures are a frequent event in HIV-infected patients. Before the ART-era, their annual incidence was estimated up to 11% and in one study even up to 17%, whereas a reduced frequency with a prevalence of up to 6% was reported in the ART-era (Dore *et al*, 1999; Kellinghaus *et al*, 2007; Levy and Bredesen, 1988; Pascual-Sedano *et al*, 1999). In almost 50% of cases, no causal opportunistic disease was identified, suggesting a HIV-related pathogenesis (Langford *et al*, 2003). The differential diagnosis in HIV-infected patients with seizures comprises infections such as toxoplasmosis, cryptococcal or tuberculous meningitis, and progressive multifocal leukoencephalopathy (PML) (Price, 1996). Furthermore, CNS lymphoma and drugs used for treatment of the HIV infection and metabolic alterations such as renal or hepatic failure may predispose

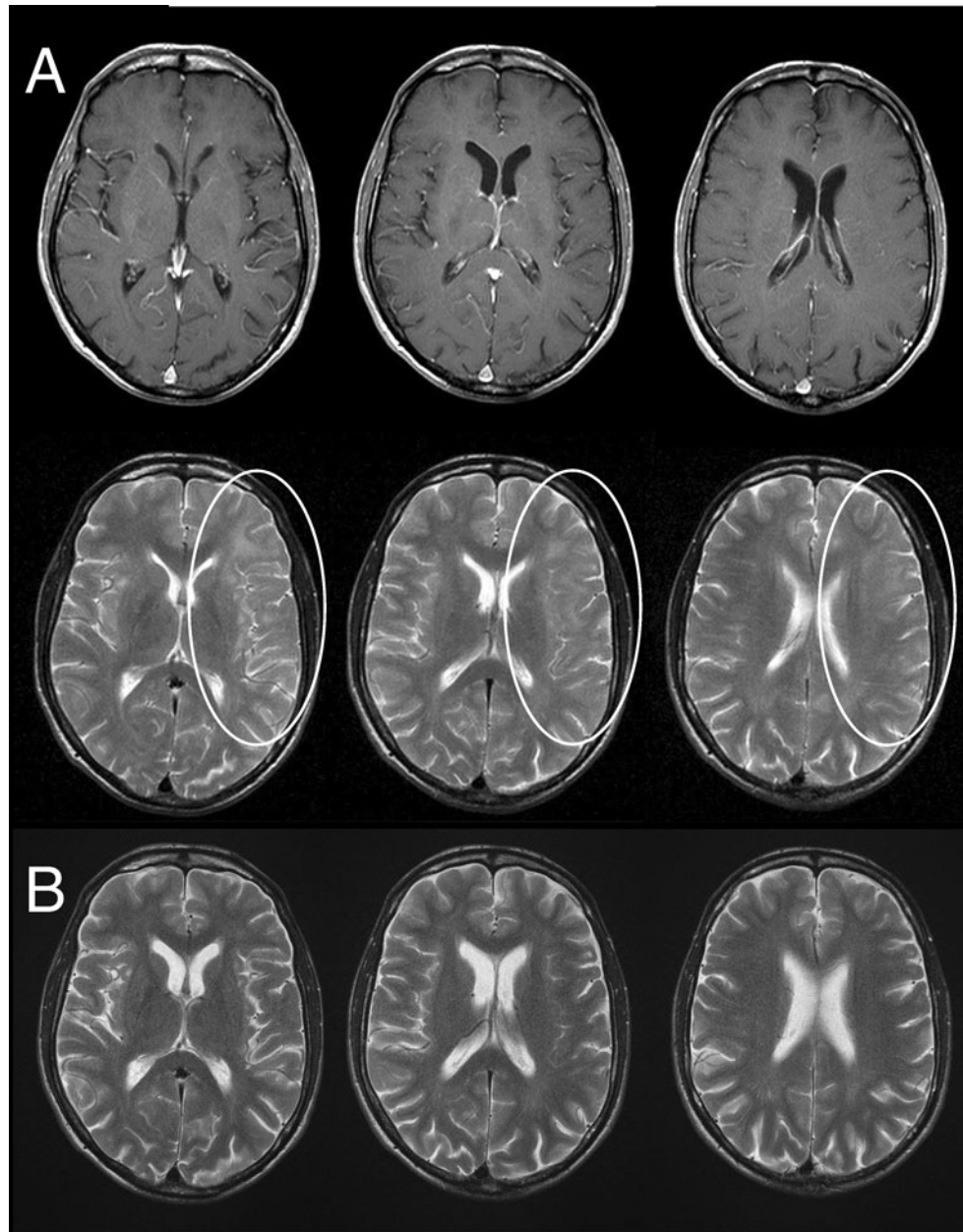


Figure 2 T2-weighted MRI after the second seizure (**A**) and at 19-month follow-up (**B**). (**A**) No contrast-enhancing lesions are detected on T1-weighted images (*upper row*), whereas mainly subcortical T2-hyperintense white matter abnormality is noted most prominently in left frontal areas (*white ellipse; lower row*). Normalization of white matter signal intensity and improved differentiation of grey and white matter is demonstrated on follow-up (**B**).

for seizures (Barton *et al*, 1992; D'Silva *et al*, 1995). As the second seizure occurred in our patient after changing the antiretroviral therapy, an immune reconstitution syndrome might have also triggered it. However, no increase of lymphocyte counts was detected after modification of the therapy and the MRI showed no contrast-medium enhancement, both of which argue against the possibility of seizures caused by an immune reconstitution inflammatory syndrome in the CNS (Venkataramana *et al*, 2006).

We therefore considered the seizures as secondary manifestation of the HIV infection in CNS and initiated an antiepileptic treatment with levetiracetam. Levetiracetam has been reported to be efficacious in HIV-positive patients with HAART treatment (Liedtke *et al*, 2004). It undergoes minor metabolism by plasma hydrolases, but not by the liver, as it does not interact with the hepatic cytochrome P450 (CYP450) enzyme function by which most protease inhibitors and non-nucleoside reverse transcriptase

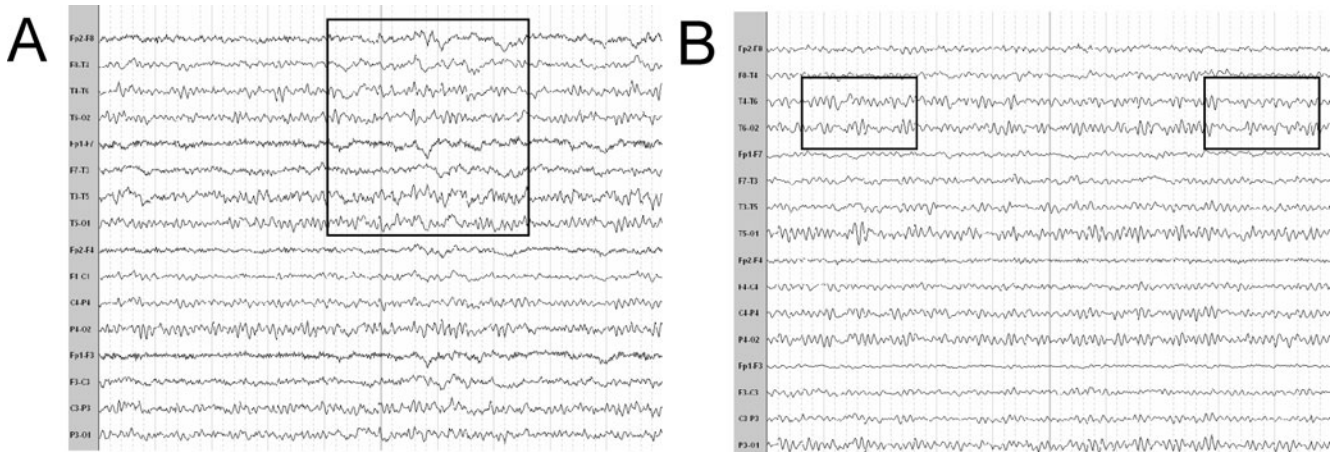


Figure 3 Electroencephalogram after the second seizure (A) and at 19-month follow-up (B). (A) Electroencephalogram (EEG) with modest background alterations and intermittent focal slowing in both temporo-occipital regions, spreading also to the frontal regions (*box*). (B) Follow-up EEG after adaptation of HAART, which showed almost complete resolution of background alterations and of the left-sided focal slowing whereas a minor slowing still persists on the right temporo-occipital region (*boxes*).

inhibitors are metabolized. Interactions of antiretroviral agents and the well-known antiepileptic drugs carbamazepine, phenytoin, and phenobarbital have been described in HAART-treated patients, especially when protease inhibitors are given (Liedtke *et al*, 2004; Bates *et al*, 2006). Valproic acid has been discussed to have a potential neuroprotective effect in HIV-associated cognitive impairment (Dou *et al*, 2003; Schifitto *et al*, 2006). It is metabolized by the hepatic CYP450 system (mainly the 2C9 isoform) and is conjugated by the uridyl-glucuronyl transferase, but has been reported to be safe when given in combination with the non-nucleoside reverse transcriptase inhibitor efavirenz and the protease inhibitor lopinavir (DiCenzo *et al*, 2004). In contrast, valproic acid acts as a modest inhibitor of several CYP450 isoforms and might thereby prolong the elimination half-time of antiretroviral drugs metabolized by this system. Conflicting results regarding a positive effect of valproic acid on the eradication of latent virus reservoirs have been reported (Lehrman *et al*, 2005; Siliciano *et al*, 2007). Table 1a comprehensively summarizes the properties of antiepileptic drugs for the treatment of HIV-related seizures with special emphasis given to their potential of interaction with antiretroviral drugs. The hepatic CYP450 metabolism of antiretroviral drugs and their influence on this enzyme system is presented in Table 1b, which also displays the interaction profile of antiretroviral drug with the currently used antiepileptic drugs.

In HIV-infected patients, imaging studies after seizures have often been reported as negative with respect to structural alterations (McArthur *et al*, 2005). Clonal expansion of HIV quasisppecies in the CNS may account for distinct manifestation of CNS disease and HIV replication in the CNS may be independent from other body compartments as drug mutations distinct from plasma virus can be

detected in CSF (Antinori *et al*, 2005; Temesgen *et al*, 2006). Furthermore, antiretroviral drug penetration into the CNS varies greatly between different drugs and shows significant interindividual variability (Antinori *et al*, 2005; McGee *et al*, 2006). Our patient had been on partially suppressive HAART for 7 years, the last 5 of which he was taking a regimen with overall suboptimal CNS penetration (neftravir/stavudine/lamivudine). Even though he had achieved complete suppression of plasma viremia at time of his second seizure after switching his antiretrovirals to a more “modern” regimen, lumbar puncture revealed poorly controlled HIV replication in the CNS. Genotypic resistance testing of the HIV variant isolated from the CSF virus revealed a resistance pattern distinct from plasma virus. We decided to adapt the patient’s HAART to specifically target CSF variants, using drugs with optimal CSF/CNS penetration (nevirapine, zidovudine) or proven efficacy in reducing HIV CNS replication (lopinavir/ritonavir), accounting for results of genotypic resistance testing of the patient’s HIV CSF variant (Antinori *et al*, 2005; Thomas, 2004; Van Den Brande, 2006). This was followed by resolution of white matter abnormality on MRI and normalization of EEG. Follow-up CSF studies demonstrated resolved CSF pleiocytosis and undetectable CSF viral load.

This case report highlights the importance of individualizing HAART in patients with HIV associated neurological disease. It also underlines the potential usefulness of measuring CSF viral load with the option of genotyping distinct HIV variants. This diagnostic approach should be considered in all HIV-positive patients who undergo lumbar puncture for CNS disease. It may be of particular interest in patients taking HAART with suboptimal or poor CSF penetration.

Table 1a Pharmacologic profile of currently used antiepileptic drugs with respect to the use in HIV-infected patients under HAART treatment

<i>Antiepileptic drug*</i>	<i>CYP450 metabolism</i>	<i>Glucuronidation</i>	<i>Protein-binding</i>	<i>Risk of interaction</i>	<i>Advantages/disadvantages</i>	<i>Use in HIV-patients under HAART</i>
Clobazam	2C19 ≫ 3A4	None	85%	Modest	Less sedation than other BD/dependence	Short term: yes
Clonazepam	3A4; inhibits 2B family	None	86%	Modest	Fast + sustained action/dependence	Emergency use
Diazepam	2C19 ≫ 3A4	None	97–99%	Modest	Fast + sustained action/dependence; several active metabolites	Emergency use
Lorazepam	None	Extensive	93%	Low	Fast + sustained action/dependence	Emergency and short-term use
Midazolam	3A4/3A5	45–57%	97%	Substantial	Very fast, but short action; 1:1 antagonist (flumazenil dependence)	Emergency use
Phenobarbital	2C9 ≫ 2C19 and 2E1; substantial CYP induction: 2B6, 2B8, 2B9, 3A4; induction of UGTs	33%	55%	Substantial	Broad spectrum; efficacious extremely cheap/cognitive impairment; altered mood and behavior; hepatotoxicity	Not recommended
Phenytoin	2C9 > 2C19 ≫ 3A4 substantial CYP induction; induction of UGTs	1%	90%	Substantial	Broad spectrum; efficacious cheap/hepatic, bone, and neurological toxicity; non-linear pharmacokinetics	Not recommended
Carbamazepine	3A4 > 1A2 and 2C8 substantial CYP induction; induction of UGTs	~50%	70–80%	Substantial	Very efficacious for focal seizures; cheap/neurological side effects; liver, bone, blood toxicity	Not recommended
Valproic acid	2A6, 2B6, 2C9, 2C19; substantial inhibitor of hepatic CYP enzymes; inhibition of glucuronidation	10–70%	85–90%	Modest	Very broad spectrum; efficacious; modest price/hepatic toxicity; hyperammonemia; thrombocytopenia; pancreatitis teratogenicity	Recommended; additional ant-retroviral effect
Lamotrigine	None	70–80%	55%	Low	Broad spectrum; efficacious; strong mood stabilizer/long titration phase; skin rashes; insomnia	Recommended as second-line drug
Gabapentin	None	None	None	None	No interaction; anxiolytic; effective for neuropathic pain/restricted antiepileptic spectrum and efficacy; elimination exclusively dependent on renal function	Recommended
Topiramate	Slightly metabolized; weak inhibition of 2C19; weak induction of 3A4	40–70%	9–17%	Low	Broad spectrum; highly efficacious/cognitive effects (memory, language); weight loss; slow titration scheme	Recommended as second-line drug (cave: weight loss and cognitive decline in HIV patients)
Tiagabine	Extensively by 3A4; neither induction nor inhibition of CYP	<10%	95%	Substantial	Few adverse effects/narrow antiepileptic spectrum; modest efficacy; may cause NCSE	Recommended as third-line drug
Oxcarbazepine	Weak secondary CYP-dependent metabolism; mainly CYP-independent reductases	~70%	40%	Low	Efficacious; also effective for neuralgia/hyponatremia	Recommended
Pregabalin	None	None	None	None	No interaction; anxiolytic; effective for neuropathic pain/restricted antiepileptic spectrum and efficacy; elimination exclusively dependent on renal function	Recommended; slightly more effective than gabapentin; easier dosage schedule; for HIV pat.: weight gain

(Continued on next page)

Table 1a Pharmacologic profile of currently used antiepileptic drugs with respect to the use in HIV-infected patients under HAART treatment (*Continued*)

<i>Antiepileptic drug*</i>	<i>CYP450 metabolism</i>	<i>Glucuronidation</i>	<i>Protein-binding</i>	<i>Risk of interaction</i>	<i>Advantages/disadvantages</i>	<i>Use in HIV-patients under HAART</i>
Levetiracetam	None (modest metabolism by plasma hydrolases)	None	None	None	Broad spectrum; efficacious; fast titration; significant first-dose effect; almost no adverse effects/dosage adaptation required for impaired kidney function	Recommended
Zonisamide	Metabolized by 3A4 > 2D6 > 3A5, 2C19; neither induction nor inhibitor!	~15%	40–60%	Modest	Broad spectrum; efficacious/slow titration	Recommended as second-line drug

*Felbamate and vigabatrin not listed because of restricted approval due to their serious side-effect profile.

Abbreviations: CYP: cytochrome P450; HIV: human immunodeficiency virus; NCSE: nonconvulsive status epilepticus; UGT: uridylglucuronid transferase.

Table 1b CYP metabolism of antiretroviral drugs and potential interactions with antiepileptic drugs

<i>Antiretroviral drug</i>	<i>CYP450 enzymes involved in metabolism</i>	<i>Induction/inhibition</i>	<i>Interaction with AED</i>	<i>No interaction to expect with</i>
NRTIs				
Zidovudine	None (glucuronidation)	None	CBZ, LZP, PB, PHT, VPA, (DZP, LTG, TPM)	CLB, CLN, GBP, LEV, MDL, OXC, PGB, TGB, ZOS
Abacavir	None (glucuronidation, alcohol; dehydrogenase)	None	CBZ, LZP, PB, PHT, VPA, (DZP, LTG, TPM)	CLB, CLN, GBP, LEV, MDL, OXC, PGB, TGB, ZOS
Lamivudine	None	None	CBZ, PHT, PB	CLB, CLN, DZP, GBP, LEV, LTG, MDL, OXC, PGB, TGB, TPM, VPA, ZOS
Stavudine	None	None	Like lamivudine	Like lamivudine
Didanosine	None	None	Like lamivudine	Like lamivudine
Zalcitabine	None	None	Like lamivudine	Like lamivudine
Tenofovir	None	Very weak 1A2	Like lamivudine	Like lamivudine
NNRTIs				
Delavirdine	3A4, 2D6	3A4, 2C9, 2C19/3A4, 2C9, 2C19	CBZ, CLB, CLN, DZP, MDL, PB, PHT, TGB, VPA, ZOS, (OXC, TPM)	GBP, LEV, LTG, LZP, PGB
Efavirenz	3A4, 2B6	3A4, 2B6/2B6, 2C9, 2C19, (3A4)	CBZ, CLB, CLN, DZP, MDL, PB, PHT, TGB, VPA, ZOS, (OXC, TPM)	GBP, LEV, LTG, LZP, PGB
Nevirapine	3A4, 2B6	3A4, 2B6/None	CBZ, CLN, MDL, PB, PHT, TGB, ZOS, (CLB, DZP, OXC, TPM, VPA)	GBP, LEV, LTG, LZP, PGB
PIs				
Ritonavir	3A4 ≫ 2D6	1A2, UGTs, (3A4)/3A4 ≫ 2D6 > 2C9 > 2C19”2A6 > 2E1 (2B6), 3A5	CBZ, CLB, CLN, DZP, LTG, LZP, MDL, OXC, PB, PHT, TGB, TPM, VPA, ZOS	GBP, LEV, PGB
Nelfinavir	3A4	None/3A4, 2B6, 3A5	CBZ, CLN, MDL, PB, PHT, TGB, VPA, ZOS, (CLB, DZP, OXC, TPM)	GBP, LEV, LTG, LZP, PGB
Tipranavir	3A4	(3A4)/(3A4)	CBZ, CLN, MDL, PB, PHT, TGB, ZOS (CLB, DZP, OXC, TPM, VPA)	GBP, LEV, LTG, LZP, PGB
Amprenavir	3A4	None/3A4, 3A5, 2C19	CBZ, CLB, CLN, DZP, MDL, PB, PHT, TGB, VPA, ZOS, (OXC, TPM)	GBP, LEV, LTG, LZP, PGB

Table 1b CYP metabolism of antiretroviral drugs and potential interactions with antiepileptic drugs (*Continued*)

Antiretroviral drug	CYP450 enzymes involved in metabolism	Induction/inhibition	Interaction with AED	No interaction to expect with
Atazanavir	3A4	None/3A4, UGT1A1	CBZ, CLN, LTG, LZP, MDL, PB, PHT, TGB, VPA, ZOS, (CLB, DZP, OXC, TPM)	GBP, LEV, PGB
Indinavir	3A4	None/(weak) 3A4	Like tipranavir	Like tipranavir
Saquinavir	3A4	None/(weak) 3A4, 3A5	Like tipranavir	Like tipranavir
Lopinavir	3A4	None/3A4	Like tipranavir	Like tipranavir
Darunavir	3A4 (/5)	?	Like tipranavir (?)	Like tipranavir (?)
FIs				
Enfuvirtide	None	None/None	None (?)	All antiepileptic drugs

Abbreviations: NRTIs: nucleoside/tide reverse transcriptase inhibitors; NNRTIs: non-nucleoside reverse transcriptase inhibitors; PIs: protease inhibitors; FIs: fusion inhibitors.

Antiepileptic drugs: CBZ: carbamazepine; CLB: clobazam; CLN: clonazepam; DZP: diazepam; GBP: gabapentin; LEV: levetiracetam; LTG: lamotrigine; LZP: lorazepam; MDL: midazolam; OXC: oxcarbazepine; PB: phenobarbital; PHT: phenytoin; PGB: pregabalin; TGB: tiagabine; TPM: topiramate; VPA: valproic acid; ZOS: zonisamide.

References

- Antinori A, Perno CF, Giancola ML, Forbici F, Ippolito G, Hoetelmans RM, Piscitelli SC (2005). Efficacy of cerebrospinal fluid (CSF)-penetrating antiretroviral drugs against HIV in the neurological compartment: different patterns of phenotypic resistance in CSF and plasma. *Clin Infect Dis* **41**: 1787–1793.
- Barton TL, Roush MK, Dever LL (1992). Seizures associated with ganciclovir therapy. *Pharmacotherapy* **12**: 413–415.
- Bates DE, Herman RJ (2006). Carbamazepine toxicity induced by lopinavir/ritonavir and nelfinavir. *Ann Pharmacother* **40**: 1190–1195.
- DiCenzo R, Peterson D, Cruttenden K, Morse G, Riggs G, Gelbard H, Schifitto G (2004). Effects of valproic acid coadministration on plasma efavirenz and lopinavir concentrations in human immunodeficiency virus-infected adults. *Antimicrob Agents Chemother* **48**: 4328–4331.
- Dore GJ, Correll PK, Li Y, Kaldor JM, Cooper DA, Brew BJ (1999). Changes to AIDS dementia complex in the era of highly active antiretroviral therapy. *AIDS* **13**: 1249–1253.
- Dou H, Birusingh K, Faraci J, Gorantla S, Poluektova LY, Maggirwar SB, Dewhurst S, Gelbard HA, Gendelman HE (2003). Neuroprotective activities of sodium valproate in a murine model of human immunodeficiency virus-1 encephalitis. *J Neurosci* **23**: 9162–9170.
- D'Silva M, Leibowitz D, Flaherty JP (1995). Seizure associated with zidovudine. *Lancet* **346**: 452.
- Kellinghaus C, Engbring C, Kovac S, Moddel G, Boesebeck F, Fischera M, Anneken K, Klonne K, Reichelt D, Evers S, Husstedt IW (2008). Frequency of seizures and epilepsy in neurological HIV-infected patients. *Seizure* 2007 Jul 5; **17**: 27–33.
- Langford TD, Letendre SL, Larrea GJ, Masliah E (2003). Changing patterns in the neuropathogenesis of HIV during the HAART era. *Brain Pathol* **13**: 195–210.
- Lehrman G, Hogue IB, Palmer S, Jennings C, Spina CA, Wiegand A, Landay AL, Coombs RW, Richman DD, Mellors JW, Coffin JM, Bosch RJ, Margolis DM (2005). Depletion of latent HIV-1 infection in vivo: a proof-of-concept study. *Lancet* **366**: 549–555.
- Levy RM, Bredeisen DE (1988). Central nervous system dysfunction in acquired immunodeficiency syndrome. *J Acquir Immune Defic Syndr* **1**: 41–64.
- Liedtke MD, Lockhart SM, Rathbun RC (2004). Anticonvulsant and antiretroviral interactions. *Ann Pharmacother* **38**: 482–489.
- McArthur JC, Brew BJ, Nath A (2005). Neurological complications of HIV infection. *Lancet Neurol* **4**: 543–555.
- McGee B, Smith N, Aweeka F (2006). HIV pharmacology: barriers to the eradication of HIV from the CNS. *HIV Clin Trials* **7**: 142–153.
- Pascual-Sedano B, Iranzo A, Marti-Fabregas J, Domingo P, Escartin A, Fuster M, Barrio JL, Sambeat MA (1999). Prospective study of new-onset seizures in patients with human immunodeficiency virus infection: etiologic and clinical aspects. *Arch Neurol* **56**: 609–612.
- Price RW (1996). Neurological complications of HIV infection. *Lancet* **348**: 445–452.
- Schifitto G, Peterson DR, Zhong J, Ni H, Cruttenden K, Gaugh M, Gendelman HE, Boska M, Gelbard H (2006). Valproic acid adjunctive therapy for HIV-associated cognitive impairment: a first report. *Neurology* **66**: 919–921.
- Siliciano JD, Lai J, Callender M, Pitt E, Zhang H, Margolick JB, Gallant JE, Cofrancesco J Jr, Moore RD, Gange SJ, Siliciano RF (2007). Stability of the latent reservoir for HIV-1 in patients receiving valproic acid. *J Infect Dis* **195**(6): 833–6.
- Temesgen Z, Cainelli F, Poeschla EM, Vlahakis SA, Vento S (2006). Approach to salvage antiretroviral therapy in heavily antiretroviral-experienced HIV-positive adults. *Lancet Infect Dis* **6**: 496–507.
- Thomas SA (2004). Anti-HIV drug distribution to the central nervous system. *Curr Pharm Des* **10**: 1313–1324.
- Van den Brande G (2006). Kaletra independently reduces HIV replication in cerebrospinal fluid. Presented at the 13th Conference on Retroviruses and Opportunistic Infections 2006, Denver, CO, USA.
- Venkataramana A, Pardo CA, McArthur JC, Kerr DA, Irani DN, Griffin JW, Burger P, Reich DS, Calabresi PA, Nath A (2006). Immune reconstitution inflammatory syndrome in the CNS of HIV-infected patients. *Neurology* **67**: 383–388.