

# Valaciclovir for Chronic Hepatitis B Virus Infection after Lung Transplantation

I. Laube, A. Boehler, E.L. Renner, R. Speich

## Abstract

We report on a chronic asymptomatic hepatitis B surface antigen (HBsAg) carrier who developed an increase in aminotransferase and HBsAg levels 1 year after lung transplantation. During treatment for cutaneous herpes simplex virus (HSV) infection with oral valaciclovir there was a marked decrease in replicating hepatitis B virus (HBV)-DNA and aminotransferase levels, which was sustained for 9 months by continuing low-dose valaciclovir. A second rise in aminotransferase levels again responded to a valaciclovir dose increase and the HBV-DNA levels declined further. Although we cannot exclude a spontaneous variation of the serologic parameters, our observation suggests that valaciclovir may represent a valuable therapeutic option in the treatment of chronic hepatitis B after lung transplantation.

Infection 2004; 32: 51–53  
DOI 10.1007/s15010-003-3094-5

## Introduction

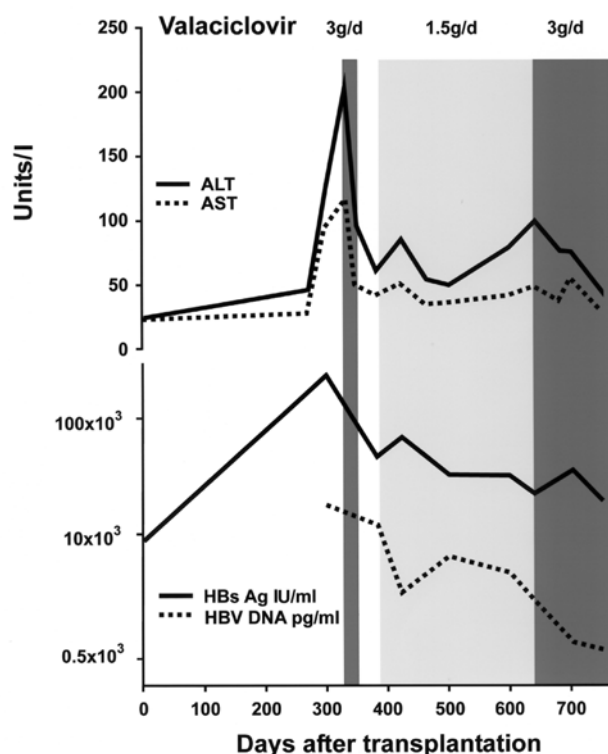
Hepatitis B surface antigen (HBsAg) carrier status is not an absolute contraindication for solid organ transplantation [1, 2]. However, post-transplant immunosuppressive therapy puts patients at risk for hepatitis B virus (HBV) infection recurrence [3] and survival of these patients may be limited by a fibrosing cholestatic hepatitis with rapidly progressive liver failure [4]. Different treatment modalities have been evaluated to decrease viral replication. IFN- $\alpha$  has produced favorable results, however, its use in organ transplant recipients is limited by its potential for precipitating graft rejection [5]. Recently, the nucleoside analogue lamivudine has been shown to be a potent inhibitor of HBV [6]. It is highly effective, unless resistance develops and approved for therapy of HBV infection. Ganciclovir [7] and famciclovir [8] have been studied with only very moderate effect and are not approved. To our knowledge, oral valaciclovir, a prodrug of aciclovir with substantially improved bioavailability, has not been studied in patients with active HBV infection.

## Case Report

The 46-year-old female HBsAg carrier underwent bilateral lung transplantation for idiopathic bronchiectasis. The pre-transplantation HBsAg titer was 8,780 IU/ml, anti-HBe was positive and the liver function tests were normal. She received the organs from a donor who was negative for HBsAg, anti-HBs and anti-HBc IgG/IgM. Post-transplant immunosuppressive therapy included cyclosporine, prednisone and azathioprine. On postoperative day 300 an asymptomatic increase in aspartate and alanine aminotransferase levels was recorded (Figure 1). HBsAg titer and viral DNA replication rate were increased, suggesting reactivation of HBV infection. Anti-HBc IgM, anti-HBs and HBeAg were negative; anti-HBe was positive. Concurrently, a cutaneous herpes simplex virus (HSV) infection was diagnosed and treated with valaciclovir (3 g/day for 2 weeks). After cessation of therapy, HSV infection relapsed and therefore, long-term suppressive therapy with valaciclovir (1.5 g/day) was initiated. During valaciclovir treatment, HBsAg titers and the viral DNA replication rate significantly decreased from 227,000 IU/ml to 19,040 IU/ml and from 17,610 pg/ml to 966 pg/ml, respectively (HBsAg determined by MEIA, Abbott, North-Chicago, USA; quantitative detection of HBV-DNA by a commercial standardized assay: hybrid capture system HBV-DNA; Digen Murex Diagnostic Chatillon, France). Daily dosage of regular immunosuppressive therapy consisting of prednisone 7.5 mg, azathioprine 75 mg and cyclosporine 50–75 mg (serum trough levels between 150–200  $\mu$ g/l) was not changed at this time. After aminotransferase values had normalized around postoperative day 500, there was another increase in alanine aminotransferase levels on postoperative day 600. After the valaciclovir dose had been increased again to 3 g/day, the liver enzyme levels definitively normalized. At the same time anti-HBe disappeared and HBe became detectable. A liver biopsy showed only minimal inflammatory infiltrates without evidence of cirrhosis. The patient has been well for more than 6 years after lung transplantation. He had only one other short-term increase in liver enzyme values at around postoperative day 2000.

**Irène Laube, Anette Boehler, E.L. Renner, R. Speich** (corresponding author)  
Dept. of Internal Medicine, University Hospital Zurich, Raemistr. 100,  
CH- 8091 Zurich, Switzerland; Phone: (+41/12) 55-2220, Fax: -4451,  
e-mail: [kliinspr@usz.unizh.ch](mailto:kliinspr@usz.unizh.ch)

Received: June 10, 2002 • Revision accepted: May 12, 2003



**Figure 1.** Serial measurements of liver enzymes, HBsAg and HBV-DNA hybridization during therapy with valaciclovir in a lung transplant recipient. Titers of HBsAg and HBV replication decreased and liver enzymes normalized during long-term therapy with valaciclovir, which was given to treat a cutaneous HSV infection.

## Discussion

The most important finding in the present case report is the immediate rapid regression of the serological parameters of active HBV infection after the initiation of the treatment with valaciclovir for concurrent acute HSV infection.

The etiology of the increase of HBV parameters and transaminases after transplantation remains unclear. It was most probably due to a reactivation of silent infection as a consequence of the immunosuppression [9]. It is unknown whether such episodes had previously occurred in this patient. The negative serology of the donor makes a transmission by the transplant highly improbable. However, despite the lack of pertinent risk factors, a superinfection of the asymptomatic HBsAg carrier with a new HBV strain cannot be excluded. Comparisons of DNA sequences were not available.

Valaciclovir consists of L-valyl ester of aciclovir. After oral administration, valaciclovir is converted rapidly and almost completely into aciclovir by valaciclovir hydrolase in the intestinal wall and liver [10]. This process leads to a three to five times higher bioavailability than achieved by oral aciclovir and serum trough levels, approximating those of intravenous aciclovir. Aciclovir is activated to aciclovir triphosphate, the active antiviral form, and competitively

inhibits viral DNA polymerase. It terminates the viral chain elongation and consecutively prevents replication of viral DNA. Drug resistance to valaciclovir is rare and occurs as a result of deficiency in thymidine kinase, an enzyme that converts aciclovir into aciclovir monophosphate.

IFN- $\alpha$  and lamivudine are currently the only well-established treatment modalities for chronic hepatitis B [6, 11]. The use of IFN in organ transplant recipients is limited by its potential to precipitate graft rejection [5]. Lamivudine, an oral nucleoside analogue, inhibits viral DNA replication [6]. It reduces necrosis, inflammation and hepatic fibrosis and increases the rate of HBeAg seroconversion. This treatment blocks but does not eliminate the source of replication and therefore after discontinuation drug recurrence is common [12]. Our observation suggests that the same is the case for valaciclovir.

10% of HBsAg carriers with anti-HBe antibodies shows persistent hepatic inflammation and each year 1.3% of this subgroup of patients develops cirrhosis [13]. Hepatitis activity can be monitored by liver enzyme levels. Aspartate aminotransferase has been shown to be superior to alanine aminotransferase in predicting hepatitis activity index and serum concentrations of HBV-DNA hybridization correlate with hepatic inflammation [13]. In our patient normalization of liver enzymes and reduction of HBV-DNA hybridization suggest decreased hepatitis activity. Although HBsAg did not reach the low values existing at the time of transplantation, except for one short-termed rebound, liver enzymes remained within the normal range for more than 5 years after the initiation of valaciclovir treatment and a liver biopsy showed only minimal inflammatory changes without evidence of cirrhosis.

In conclusion, our observation might indicate a possible therapeutic action of valaciclovir against chronic hepatitis B in solid organ transplant recipients. However, we cannot exclude a spontaneous variation of the serologic parameters. Current knowledge strongly supports the concept that all transplant recipient patients with inactive HBV infection before transplantation should be closely monitored and treated at the first sign of HBV reactivation with the most effective drug lamivudine [14]. The beneficial effect of valaciclovir suggests that combination therapy with lamivudine or treatment after lamivudine resistance has developed appear worthy of study.

## References

1. Agarwal SK, Dash SC, Tiwari SC, Mehta SN, Saxena S, Malhotra KK: Clinicopathologic course of hepatitis B infection in surface antigen carriers following living-related renal transplantation. *Am J Kidney Dis* 1994; 24: 78–82.
2. Steinman TI, Becker BN, Frost AE, Olthoff KM, Smart FW, Suki WN, Wilkinson AH: Guidelines for the referral and management of patients eligible for solid organ transplantation. *Transplantation* 2001; 71: 1189–1204.
3. Marcellin P, Giostra E, Martinot-Peignoux M, Lioriot MA, Jaegle ML, Wolf P, Degott C, Degos F, Benhamou JP, Parfrey PS, Forbes

- RD, Hutchinson TA, Kenick S, Farge D, Dauphinee WD, Seely JF, Guttman RD, Olthoff KM, Smart FW, Suki WN, Wilkinson AH: Redevelopment of hepatitis B surface antigen after renal transplantation. *Gastroenterology* 1991; 100: 1432–1434.
4. Parfrey PS, Forbes RD, Hutchinson TA, Kenick S, Farge D, Dauphinee WD, Seely JF, Guttman RD, Olthoff KM, Smart FW, Suki WN, Wilkinson AH: The impact of renal transplantation on the course of hepatitis B liver disease. *Transplantation* 1985; 39: 610–615.
  5. Munoz de Bustillo E, Ibarrola C, Andres A, Colina F, Morales JM, Perry CM, Faulds D: Hepatitis-B-virus-related fibrosing cholestatic hepatitis after renal transplantation with acute graft failure following interferon-alpha therapy. *Nephrol Dial Transplant* 1998; 13: 1574–1576.
  6. Lai CL, Chien RN, Leung NW, Chang TT, Guan R, Tai DI, Ng KY, Wu PC, Dent JC, Barber J, Stephenson SL, Gray DF: A one-year trial of lamivudine for chronic hepatitis B. *Asia Hepatitis Lamivudine Study Group. N Engl J Med* 1998; 339: 61–68.
  7. Gish RG, Lau JY, Brooks L, Fang JW, Steady SL, Imperial JC, Garcia-Kennedy R, Esquivel CO, Keeffe EB, Olthoff KM, Smart FW, Suki WN, Wilkinson AH: Ganciclovir treatment of hepatitis B virus infection in liver transplant recipients. *Hepatology* 1996; 23: 1–7.
  8. de Man RA, Marcellin P, Habal F, Desmond P, Wright T, Rose T, Jurewicz R, Young C: A randomized, placebo-controlled study to evaluate the efficacy of 12-month famciclovir treatment in patients with chronic hepatitis B e antigen-positive hepatitis B. *Hepatology* 2000; 32: 413–417.
  9. Nagington J, ter Borg F, ten Kate FJ, Cuypers HT, Leentvaar-Kuijpers A, Oosting J, Wertheim-van Dillen PM, Honkoop P, Rasch MC, de Man RA, van Hattum J, Chamuleau RA, Reesink HW, Jones EA: Reactivation of hepatitis B after transplantation operations. *Lancet* 1977; 1: 558–560.
  10. Perry CM, Faulds D: Valaciclovir: A review of its antiviral activity, pharmacokinetic properties and therapeutic efficacy in herpesvirus infections. *Drugs* 1996; 52: 754–772.
  11. Wong DK, Cheung AM, O'Rourke K, Naylor CD, Detsky AS, Heathcote J: Effect of alpha-interferon treatment in patients with hepatitis B e antigen-positive chronic hepatitis B. A meta-analysis. *Ann Intern Med* 1993; 119: 312–323.
  12. Lai CL, Ching CK, Tung AK, Li E, Young J, Hill A, Wong BC, Dent J, Wu PC: Lamivudine is effective in suppressing hepatitis B virus DNA in Chinese hepatitis B surface antigen carriers: a placebo-controlled trial. *Hepatology* 1997; 25: 241–244.
  13. Liaw YF, Tai DI, Chu CM, Chen TJ: The development of cirrhosis in patients with chronic type B hepatitis: a prospective study. *Hepatology* 1988; 8: 493–496.
  14. Gane E, Pilmore H: Management of chronic viral hepatitis before and after renal transplantation. *Transplantation* 2002; 74: 427–437.