

## OTOLOGY

A. Baumann · A. Helbling · S. Oertle · R. Häusler  
D. Vibert**Cogan's syndrome: clinical evolution of deafness and vertigo  
in three patients**Received: 30 June 2003 / Accepted: 11 December 2003 / Published online: 5 March 2004  
© Springer-Verlag 2004

**Abstract** The aim of this study was to evaluate the clinical symptoms, the otoneurological examinations, the treatment and the clinical course of three patients suffering from Cogan's syndrome, a rare disease based on the clinical association of a non-syphilitic interstitial keratitis with a cochleo-vestibular deficit. This case series involved three patients with follow up. The clinical course of the three patients (aged 30, 48 and 49 years) with Cogan's syndrome during a follow-up period of 2 to 6 years is reported. All patients underwent complete otoneurological, ophthalmologic and rheumatologic examinations and were treated with immunosuppressive therapy such as glucocorticoids and cyclophosphamide in two and glucocorticoids and methotrexate in one patient. Using immunosuppressive therapy, ophthalmologic symptoms disappeared rapidly in two patients. Hearing improved only in one and stabilized in a second patient. One patient died after 6 years of treatment because of complications of generalized vasculitis. Early diagnosis and rapid initiation of a combined immunosuppressive therapy such as corticosteroids and cyclophosphamide seem to be important in controlling the disease and avoiding persistent deafness. Whether systemic complications and a fatal outcome also can be prevented is still questionable.

**Keywords** Cogan's syndrome · Hearing loss · Vertigo · Keratitis · Autoimmune disease · Therapy

This paper was presented at the 35th Congress of the International Society of Otolaryngology, Paris, France, 25 May 2001.

A. Baumann · R. Häusler · D. Vibert (✉)  
Department of ENT and Head and Neck Surgery,  
University Hospital Inselspital, 3010 Berne, Switzerland  
Tel.: +41-31-6323321, Fax: +41-31-6328808,  
e-mail: dominique.vibert@insel.ch

A. Helbling · S. Oertle  
Clinic of Rheumatology and Policlinic  
of Clinical Immunology and Allergology,  
University Hospital Inselspital, Berne, Switzerland

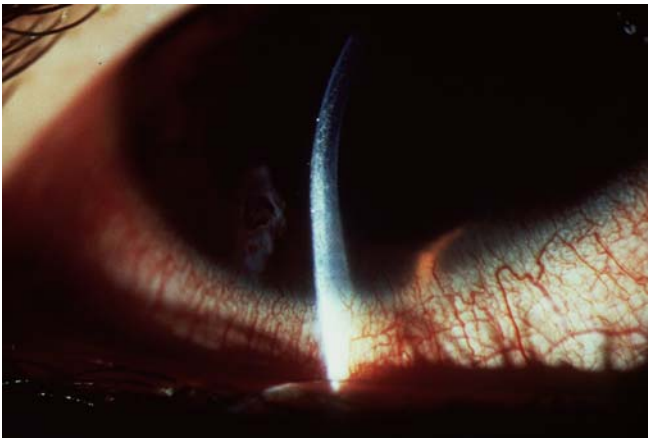
**Introduction**

Cogan's syndrome was first defined as a clinical entity by the ophthalmologist David Cogan in 1945 based on his observations of four patients [1]. It is defined as the association of a non-syphilitic interstitial keratitis with a cochleo-vestibular deficit. In general, the hearing loss is bilateral, rapidly progressive and often combined with tinnitus, vertigo, dizziness or ataxia. The term "atypical Cogan's syndrome" refers to non-specific ocular inflammations such as episcleritis, scleritis, iritis or uveitis, or to the delay of occurrence of the cardinal symptoms for more than 2 years [2, 3]. Cogan's syndrome is rare and usually occurs in adults between the 2nd and 4th decades [2, 4], but some cases have also been reported in childhood [5]. In this article, we report the clinical observations and the course of three patients, two of them suffering from a typical and one from an atypical Cogan's syndrome.

**Subjects and methods****Patients**

Between 1991 and 2001, three patients (two men aged 33 and 49 years and one woman aged 48 years) with Cogan's syndrome were treated at the ENT Clinic of the University Hospital of Berne. A complete otoneurological examination was performed, including pure-tone audiometry (PTA), impedance audiometry with measurements of reflex decay, brainstem-evoked auditory potentials (BEAPs) and electronystagmography (ENG). All patients underwent a full clinical ophthalmologic examination, including a biopsy from the conjunctiva.

A chest X-ray, kidney ultrasonography and cerebral MRI were performed to determine possible systemic organ involvement. Systemic vasculitic components were researched using clinical and laboratory examinations like C-reacting protein (CRP), erythrocyte sedimentation rate (ESR), antinuclear antibody (ANA) and antineutrophilic cytoplasmic antibody assays (p-ANCA), rheumatoid factor and complement factors C1q, C3 and C4. Furthermore, the patients underwent serological tests for various infectious agents (treponema, borrelia, herpes simplex/varicella zoster, HIV, Epstein-Barr virus, cytomegalovirus, mumps virus, flavivirus and *Toxoplasma gondii*).



**Fig. 1** Ophthalmological picture of the interstitial keratitis of case 1 with corneal cell inclusions in the slit-lamp examination (typical Cogan's syndrome)

Case reports

Case 1

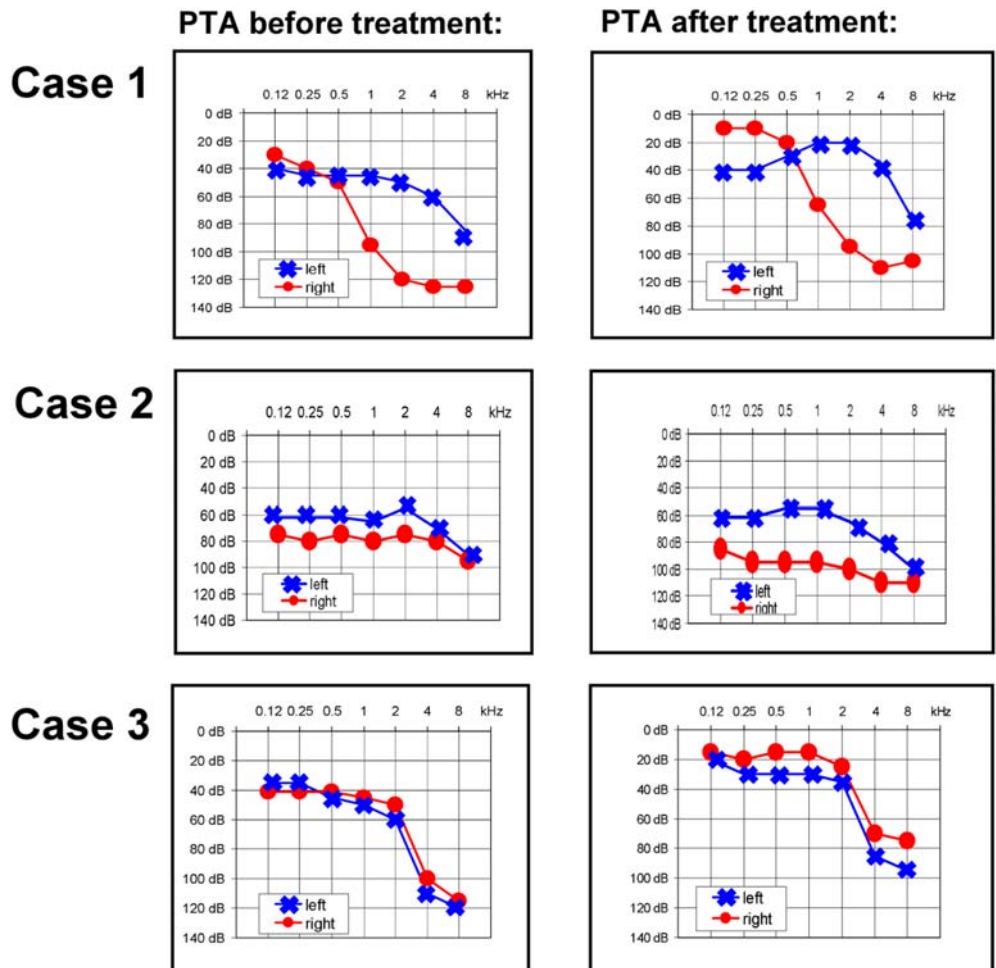
Ten days after a viral infection with fever and symptoms of a common cold, a 33-year-old man suffered from a rapidly progressive bilateral hearing loss and tinnitus. He also complained of photo-

phobia, continuous tearing and sensation of an ocular foreign body. The ophthalmologic examination demonstrated bilateral interstitial keratitis (Fig. 1). Corneal biopsy showed no signs of vasculitis or deposits of immunoglobulins or complements. The otoneurological examination revealed a moderate to severe bilateral sensorineural hearing loss with normal BEAP latencies at supra-threshold levels on the left side as well as a bilateral peripheral vestibular deficit with bilateral caloric areflexia as determined by the ENG results (Fig. 2). Laboratory analysis showed an increased ESR (30 mm/h), increased complement factors C3 [1.95 g/l (norm: 0.74–1.3 g/l)] and C4 [0.47 g/l (norm: 0.10–0.34 g/l)]. All serological tests for neutrophic antigens were negative. Systemic organ involvement was excluded by chest X-ray, kidney ultrasonography and cerebral MRI.

After the diagnosis of typical Cogan's syndrome was made, treatment with corticoids was instituted, topically for ocular inflammation and systemic (2 mg/kg per day) for vestibulocochlear symptoms. Under this treatment, fever and interstitial keratitis disappeared rapidly within days. Hearing loss and equilibrium, however, became continuously worse.

Because the patient first declined a supplementary therapy with cyclophosphamide, azathioprine 150 mg/day was started. When hearing on the left side deteriorated further, the patient finally consented to the therapy with cyclophosphamide, which was given intravenously at a dose of 1 g per session monthly for 6 months. This treatment was tolerated well without any side effects. Clinically and objectively documented by audiometric testing, hearing on the right side became much better in the low frequencies and partially improved and stabilized on the left side (Fig. 2). Dizziness practically disappeared after an intensive vestibular physiotherapy. At the last visit, 30 months after the onset of symptoms, the patient

**Fig. 2** Pure tone audiogram (PTA) before and after treatment



continued on a daily regimen of 5 mg oral prednisone; the hearing threshold remained stable and the patient was fitted for hearing aids on both sides. He no longer complained of symptoms, including dizziness or ocular discomfort.

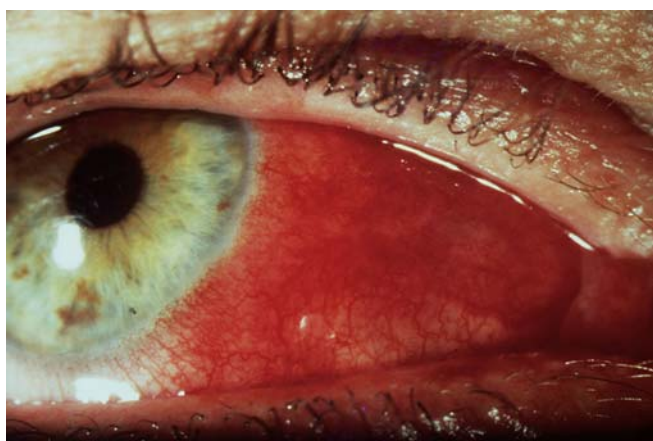### Case 2

A 48-year-old woman complained of progressive bilateral sensorineural hearing loss and dizziness, associated with recurrent fever and polyarthralgia. Seven weeks later, she developed a clinically severe keratitis and conjunctivitis in the right eye; these symptoms motivated the patient to consult a doctor for the first time. The otoneurological examination revealed a bilateral sensorineural hearing loss with normal BEAP latencies at suprathreshold levels and a left caloric hyporeflexia on ENG (Fig. 2). Laboratory analysis showed increased ESR (125 mm/h), CRP (98 mg/l) and a strongly increased complement factor C3 (2.41 g/l). Serological tests for viral antigens were negative.

Treatment with oral corticosteroids (100 mg, 75 mg and 50 mg for 7 consecutive days each) was started 8 weeks after the onset of the symptoms. Arthralgias, fever and the keratitis disappeared, but the hearing threshold improved only a little. One month later, she complained again of hearing loss and arthralgias. Therefore, cyclophosphamide (1 g per month intravenously) was added to the corticoid treatment for the long term because of recurrent arthralgia and fever. Despite this combined therapy, bilateral hearing loss and ataxia basically remained unchanged and within 2 years the patient developed cardiac vasculitis with a severe cardiac infarction and cerebral vasculitis with ischemia of the thalamus, clinically manifested by a sensomotoric paresis. Cyclophosphamide was replaced by methotrexate (20 mg per week). Nevertheless the clinical evolution continued to deteriorate with the development of a severe aortic valve insufficiency. Moreover, as side effects of corticosteroid therapy, diabetes mellitus, osteoporosis and cataract occurred. Six years after starting immunosuppressive treatment, the patient died of cardiac failure.

### Case 3

A 49-year-old man complained of a sudden bilateral hearing loss within a few weeks, but without vertigo or dizziness. Nine months later, the patient suffered from repeated fever episodes, arthralgia, loss of weight and a severe bilateral nodular scleritis, resistant to a 2-month locally administered steroid therapy (Fig. 3). Because of additional progressive hearing loss, an otoneurological examination was performed. This revealed a bilateral sensorineural hearing loss in the high frequencies with normal BEAP latencies as well as



**Fig. 3** Ophthalmological picture of the episcleritis of case 3 (atypical Cogan's syndrome)

a unilateral peripheral vestibular deficit with a left caloric hyporeflexia (Fig. 2). Laboratory analysis showed an increased ESR (60 mm/h), CRP (70 mg/l) and complement factor C1q [65 ug/ml (norm: <35 ug/m)]. All serological tests for neutrophilic antigens were negative. On echocardiography, the patient showed a mild aortic valve insufficiency.

Only when the ocular symptoms (scleritis and episcleritis with photophobia and pains) had appeared was the diagnosis of an atypical Cogan's syndrome made and systemic corticosteroid treatment (2 mg/kg per day) started. Under this treatment, hearing thresholds improved markedly, but the episcleritis and scleritis became worse, together with recurring fever. Because after 4 weeks increasing doses of systemic corticosteroids had been ineffective, cyclophosphamide at a dose of 100 and later 150 mg/day was added. With this treatment, the ocular manifestations disappeared within a few weeks. Therapy with cyclophosphamide was continued for 12 months, whereas oral corticosteroids could be tapered off within 3 months to 5 mg. During an examination 3 years after the onset of the first hearing symptoms, hearing thresholds remained stable and the patient was fitted with hearing aids.

## Discussion

The present study describes the clinical evolution and long-term follow-up of three patients suffering from Cogan's syndrome. Although this syndrome has been known for more than 50 years and more than 150 case reports have been published, there are still no specific and accurate tests for diagnosis [2, 6, 7], and with respect to treatment, many questions remain unanswered. In our patients, elevated ESR, CRP as well as some non-specific alterations of the complement system were the only notable abnormal laboratory parameters. These findings, often noticed in inflammatory processes, however, are non-specific.

Only when both cardinal symptoms (cochleovestibular and eye disease) are present does the clinical diagnosis of Cogan's syndrome become obvious. The diagnostic mainstay is to verify the presence of interstitial keratitis. However, prolonged prodromal phases or staggered occurrence of the cardinal symptoms may render the diagnosis difficult, as demonstrated by case 3. In a retrospective study of 98 patients originating from ten countries in Western Europe, Majoor [8] redefined the typical and atypical Cogan's syndromes. He included obligatorily an interstitial keratitis in addition to another significant inflammatory eye lesion. According to the definition of Cody et al. [9] and Haynes et al. [2], we considered that patient 3 might have an atypical Cogan's syndrome, despite the absence of interstitial keratitis.

Hearing loss is usually bilateral and progressive and leads to total deafness in 40–60% of reported cases [2, 4]. The course with hearing fluctuation, tinnitus and vertigo attacks may resemble Meniere's disease. Attacks of dizziness are commonly severe and usually accompanied by ataxia, caused by the bilateral progressive peripheral vestibular deficit. The initial symptoms are ophthalmological in 37% of typical Cogan's syndrome and in 45% of atypical Cogan's syndrome. The cochleo-vestibular symptoms present themselves initially in only about 30% of the patients [8].

In addition, systemic symptoms like fever, headache, arthralgias, myalgias and weight loss may occur. Known



systemic complications of Cogan's syndrome are vasculitis of the coronary, intestinal or cerebral vessels. Aortic insufficiency in particular indicates a poor prognosis, as illustrated by case 2 in our series. In approximately half of the cases in the literature, systemic manifestations occur, mostly associated with atypical Cogan's syndrome [2, 4, 10]. Depending on the organ systems involved, mortality is estimated at 10%.

The etiology of Cogan's syndrome is still not completely understood. Based on the demonstration of antibodies against inner ear and corneal tissue as well as cell-mediated immune phenomena, there is evidence that Cogan's syndrome may be an autoimmune disease [11, 12, 13, 14]. However, it is not clear whether humoral or cellular mechanisms induce the process and progression of the disease. Although Arnold et al. demonstrated IgG and IgA antibodies from sera of patients with Cogan's syndrome directed against epithelial cells of healthy corneas and against membranous labyrinth structure [11, 15], infiltration of lymphocytes and plasma cells in the cochlea and general thickening of the membranous labyrinth have been found, suggesting a cell-mediated response [2, 6]. The significance of the serum antibodies is not clear, since they do not correlate well with the clinical course and the activity of the disease [6]. Very recently, Lunardi et al. [12] identified an immunodominant peptide in the sera of patients suffering from Cogan's syndrome. This Cogan peptide shares homology with the cell-density-enhanced protein tyrosine phosphatase-1 (DEP-1/CD148), which is expressed on the sensory epithelia of the inner ear and on endothelial cells. The IgG antibodies against this peptide, purified from the patient's sera, recognized autoantigens and DEP-1/CD148 protein bound human cochlea.

These antibodies bound connexin 26 and were able to induce the features of Cogan's disease in mice. Our patients did not have tests for this specific peptide. A foregoing viral infection, as observed in case 1, is reported in 40% of the patients with Cogan's syndrome [2, 4, 10]. These observations suggested that an autoimmune process could be initiated in some cases by a viral infection. Lunardi et al. [12] found a homology between the Cogan peptide and autoantigens such as SSA/Ro as well as the reovirus III major core protein lambda 1. These findings tend to confirm the hypothesis of an autoimmunological mechanism induced by a previous viral infection.

The histopathological examinations of the temporal bones of patients with Cogan's syndrome show the typical findings of endolymphatic hydrops. In addition, atrophy of the hair cells and the supporting cells, focal and diffuse proliferation of fibrous tissue and bone ("neo-osteogenesis") as well as retrograde neuronal degeneration are also observed [16, 17]. Based on MRI findings of inner ears of patients suffering from Cogan's syndrome, Majoor et al. hypothesized that its physiopathology might be due to an obstructive vasculitis [18].

Since the etiopathology is still not completely understood, there is no agreement concerning the therapy regimen. Systemic corticosteroids are considered as the primary and standard treatment of Cogan's syndrome [2, 10].

From the ophthalmological side, ocular symptoms usually respond well even to topically applied corticosteroids [3, 19]. Atypical Cogan's syndrome with panuveitis as well as scleritis/episcleritis, however, tends to produce a chronic course that may require a more aggressive systemic treatment, as illustrated by case 3 with the atypical Cogan's syndrome [3]. In the literature, prednisone is recommended at a dose of 2 mg/kg per day initially [2, 10]. In several reports in which treatment with corticosteroids failed, various immunosuppressants such as cyclophosphamide (1–2 mg/kg per day), cyclosporin A (1–2 mg/kg per day) [2, 5, 20] or methotrexate (7.5–10 mg per week) have been introduced with favorable results [21, 22]. In our cases, we primarily used cyclophosphamide, which previously has been demonstrated to be effective in eradicating B-cell clones producing autoantibodies in a variety of diseases [23].

Based on a study of 15 patients and a literature review of 111 cases, Haynes suggested that treatment should begin as early as possible, e.g., within the first 2 weeks after the appearance of the cochleo-vestibular symptoms [2]. But even in cases with early treatment, hearing improvements are variable and often only partial, as seen in case 1. A long delay between the onset of symptoms and the initiation of treatment can issue an irreversible atrophy and degeneration of inner ear structures with the typical picture of an endolymphatic hydrops in the advanced stage of the disease. At this late stage with endolymphatic hydrops, treatment can only improve hearing fluctuations and attempt to inhibit further hearing loss. Furthermore, current dosage of the systemic immunosuppressive therapy seems not to be high enough, because concentrations of corticosteroids in the perilymph and cerebrospinal fluid are much lower than in the plasma [24]. High levels of corticoids in the endo- and perilymph are very important in treating inflammatory inner ear disorders, since the end organs are bathed in these liquids [25]. Furthermore, the endolymphatic sac is probably the source of the inner ear immune response [15]. For this reason, local intratympanic corticosteroid applications have been used in different studies with encouraging results [24, 25, 26]. However, the number of these cases is still too small to confirm the efficacy of this treatment.

---

## Conclusions

Cogan's syndrome should always be considered in patients presenting a progressive hearing loss associated with ocular inflammations. According to the findings of this study, early recognition of Cogan's syndrome and rapid initiation of combined immunosuppressive therapy, such as corticosteroids and cyclophosphamide, seem to be important in preventing persistent deafness. Whether systemic complications and a fatal outcome also can be prevented still remains unanswered.

**Acknowledgements** We thank C. Hirsch-Hoffmann, MD, at the Department of Ophthalmology, University Hospital, Inselspital, in Berne for his kind contribution to the acquisition of ophthalmological data.

## References

1. Cogan DG (1945) Syndrome of nonsyphilitic interstitial keratitis and vestibuloauditory symptoms. *Arch Ophthalmol.* 33:144
2. Haynes BF, Kaiser-Kupfer MI, Mason P, Fauci AS (1980) Cogan syndrome: studies of 13 patients, long-term follow-up and review of the literature. *Medicine (Baltimore)* 59:426–439
3. Zierhut M, Schlote T, Stübiger N, Daikeler T, Kötter I, Bless D, Koitschev A (2000) Cogan I-Syndrom: Klinik, Therapie und Prognose. *Ophthalmologe* 97:197–202
4. Vollertsen RS, McDonald TJ, Younge BR, Banks PM, Stanson AW, Ilstrup DM (1986) Cogan's syndrome: 18 cases and a review of the literature. *Mayo Clin Proc* 61:344–361
5. Kasapcopur Oe, Ashraf M, Caliskan S, Arisoy N (2000) Cogan's Syndrome: a rare vasculitis in childhood. *J Rheumatol* 27:1824–1825
6. Helmchen C, Arbusow V, Jäger L, Strupp M, Stöcker W, Schulz P (1999) Cogan's syndrome: clinical significance of antibodies against the inner ear and cornea. *Acta Otolaryngol [Stockh]* 119:528–537
7. Majoor MHJM, Albers FWJ, Van der Gaag R, Gmelig-Meyling F, Huizing EH (1992) Corneal autoimmunity in Cogan's syndrome? Report of two cases. *Ann Otol Rhinol Laryngol* 101:679–684
8. Majoor MHJM (1994) Cogan's syndrome. A clinical and experimental study. Thesis, Utrecht University
9. Cody DT, Williams HL (1960) Cogan's syndrome. *Laryngoscope* 70:447–478
10. St. Clair EW, McCallum RM (1999) Cogan's syndrome. *Curr Opin Rheumatol* 11:47–52
11. Arnold W, Gebbers JO (1984) Serum-Antikörper gegen Kornea und Innenohrgewebe beim Cogan-Syndrom. *Laryngol Rhinol Otol [Stuttg]* 63:428–432
12. Lunardi C, Bason C, Leandri M, Navone R, Lestani M, Millo E, et al (2002) Autoantibodies to inner ear and endothelial antigens in Cogan's syndrome. *Lancet* 360:915–921
13. Stone JH, Francis HW (2000) Immune-mediated inner ear disease. *Curr Opin Rheum* 12:32–40
14. Harris JP (1983) Immunology of the inner ear: response of the inner ear to antigen challenge. *Otolaryngol Head Neck Surg* 91:18
15. Arnold W, Pfaltz CR, Altermatt HJ (1985) Evidence of serum antibodies against inner ear tissues in the blood of patients with certain sensorineural hearing disorders. *Acta Otolaryngol [Stockh]* 99:437–444
16. Schuknecht HF, Nadol JB (1994) Temporal bone pathology in a case of Cogan's syndrome. *Laryngoscope* 104:1135–1142
17. Rarey KE, Bicknell JM, Larry ED (1986) Intralabyrinthine osteogenesis in Cogan's syndrome. *Am J Otolaryngol* 7:387–390
18. Majoor MHJM, Albers FWJ, Casselman JW (1993) Clinical relevance of magnetic resonance imaging and computed tomography in Cogan's syndrome. *Acta Otolaryngol [Stockh]* 113:625–631
19. Cobo LM, Haynes BF (1984) Early corneal findings in Cogan's syndrome. *Ophthalmology* 91:903–907
20. Allen NB, Cox CC, Cobo M, Kisslo J, Jacobs MR, McCallum RM, Haynes BF (1990) Use of immunosuppressive agents in the treatment of severe ocular and vascular manifestations of Cogan's syndrome. *Am J Med.* 88:296–301
21. Matteson EL, Tirzaman O, Facer GW, Fabry DA, Kasperbauer J, Beatty CW, McDonald TJ (2000) Use of methotrexate for autoimmune hearing loss. *Ann Otol Rhinol Laryngol* 109:710–714
22. Riente L, Taglione E, Berrettini S (1996) Efficacy of methotrexate in Cogan's syndrome. *J Rheumatol* 23:1830–1831
23. Backhaus M, Hiepe F (1997) Cyclophosphamidtherapie beim systemischen Lupus erythematodes (SLE). *Z.Rheumatol* 56:178–189
24. Bachmann G, Su J, Zumegen C, Wittekindt C, Michel O (2001) Permeabilität der runden Fenstermembran für Prednisolon-21-Hydrogensuccinat. *HNO* 49:538–542
25. Parnes LS, Sun AH, Freeman DJ (1999) Corticosteroid pharmacokinetics in the inner ear fluids. An animal study followed by clinical applications. *Laryngoscope* 109:1–18
26. Arriaga MA, Goldman S (1998) Hearing results of intratympanic steroid treatment of endolymphatic hydrops. *Laryngoscope* 108:1682–1685