

# Ten-year results with the Morscher press-fit cup: an uncemented, non-modular, porous-coated cup inserted without screws

Guido Garavaglia · Anne Lübbecke · Christophe Barea · Constantinos Roussos · Robin Peter · Pierre Hoffmeyer

Received: 29 March 2010 / Revised: 19 May 2010 / Accepted: 19 May 2010 / Published online: 4 June 2010  
© Springer-Verlag 2010

**Abstract** Total hip arthroplasty (THA) with well designed cementless acetabular implants has shown excellent results. The purpose of this study was to assess our clinical and radiological outcomes using an uncemented cup. We conducted a prospective cohort study including all consecutive primary THAs performed with the Morscher press-fit cup, an uncemented non-modular acetabular component, between March 1996 and December 1998. Patients were evaluated at ten years with clinical and radiological follow-up, patient satisfaction and questionnaire assessment using the Harris hip score (HHS), Merle d'Aubigné and Postel score, the UCLA score, the 12-item short-form health survey (SF-12) and a visual analog scale. Five hundred sixty-one THAs were performed in 518 patients. At 120 months ( $\pm$  7.3 months), 303 patients with 335 THAs were still available for follow-up. None of the patients had required cup revision for aseptic loosening. At ten years, the cup survivorship was 98.8% (95% CI 97.4–99.5) with cup revision for any cause as an endpoint. No radiolucencies were seen around the cups, but osteolytic defects involved 21 stems (8.3%). Mean total linear polyethylene wear was 0.9 mm. The Morscher acetabular replacement cup provides excellent results at ten years. There were no revisions

for aseptic loosening of the cup, and no osteolytic defects were found around the cup. Patient satisfaction was high and the clinical results were very good.

## Introduction

Several studies have reported excellent early, intermediate and long-term results associated with uncemented acetabular components [1, 2], mainly because of their lower rate of loosening and revision when compared with some cemented acetabular components [3–5]. Press-fit fixation of uncemented acetabular components is increasingly being used for acetabular replacement in all age groups [6–8]. Despite the good results obtained in terms of implant survival, there has been some concern about high rates of pelvic osteolysis associated with polyethylene (PE) wear [9]. Furthermore, higher rates of pelvic osteolysis have been reported to be associated with uncemented modular cups inserted with screws [1].

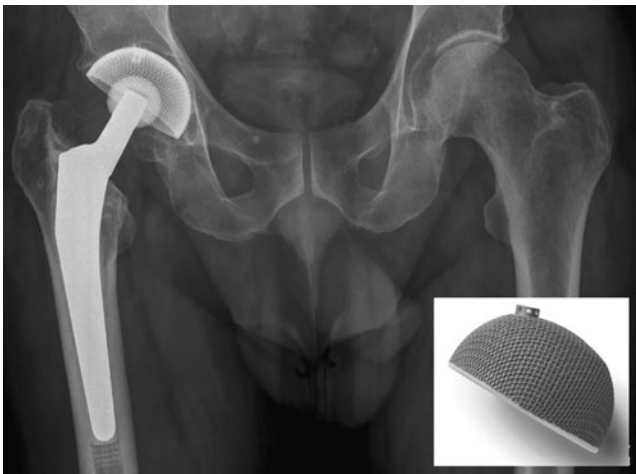
Up to now only the inventor's group, the Australian National Joint Replacement Registry and very recently a group from New Zealand have published outcome data of this acetabular cup [10–13]. The objective of this study was to assess our clinical and radiological outcomes, patient satisfaction and complications at ten years in a larger cohort.

## Material and methods

We conducted a prospective cohort study including all consecutive primary total hip arthroplasties (THA) using the Morscher press-fit cup with porous coating (Zimmer Ltd, Winterthur, Switzerland) (Fig. 1), performed between

G. Garavaglia · A. Lübbecke (✉) · C. Barea · C. Roussos · R. Peter · P. Hoffmeyer  
Division of Orthopaedics and Trauma Surgery,  
Geneva University Hospitals,  
4, rue Gabrielle-Perret-Gentil,  
1211 Geneva 14, Switzerland  
e-mail: anne.lubbekewolff@hcuge.ch

G. Garavaglia  
Orthopaedic Surgery Service, ORBV,  
Bellinzona, Switzerland



**Fig. 1** The Morscher press-fit cup (Zimmer Ltd., Winterthur, Switzerland)

March 1996 and December 1998 by different surgeons at a University Hospital.

The Morscher press-fit cup is an uncemented, non-modular, flexible, porous-coated acetabular component. The cup is designed with a flattened pole geometry with bi-radial eccentricity, providing optimal press-fit fixation and achieving intrinsic primary stability without the use of additional screw fixation [10, 11]. The porous surface is achieved by using titanium mesh layers bonded directly to the outer polyethylene (PE) surface, thus eliminating modularity and favouring bony in-growth. The polyethylene is an ultra-high molecular weight polyethylene (UHMWPE) and cups are sterilised by gamma irradiation in inert atmosphere.

The operation was performed with the patient in the lateral decubitus position using a direct lateral transgluteal approach without osteotomy of the greater trochanter. Under-reaming of the acetabulum by 1.5 mm is system-inherent and care was taken to obtain a bleeding cancellous bone surface. Using a 500-g hammer, the cup was impacted at 45° of abduction with anteversion between 10° and 15° corresponding to individual acetabular morphology.

All heads were ceramic and 28 mm in diameter. All stems were cemented (Müller CoCr straight stem; Zimmer Ltd., Winterthur, Switzerland) using a third generation technique with pulsed lavage and an intramedullary plug, apart from 25 hips (4.5%). These were 19 CLS stems and six Wagner Cone stems (both Zimmer Ltd., Winterthur, Switzerland). Gentamycin-loaded bone cement was employed in all cases with cemented stem implants.

All patients received a single-dose second generation cephalosporin before induction and standard thromboprophylaxis. The procedures were performed in an ultraclean air laminar flow operating room using hooded gowns and an outflow exhaust system.

## Clinical and radiological outcome assessment

Patients were evaluated at 120 months with clinical and radiological follow-up, questionnaire and patient satisfaction assessment using the following instruments:

1. Harris hip score (HHS): a hip-specific physician-assessed instrument [14]
2. Merle d'Aubigné and Postel score: a hip-specific physician-assessed instrument [15], evaluated also preoperatively
3. 12-item short-form health survey (SF-12): a general health status instrument [16], which is a self-administered 12-item questionnaire comprising two summary measures, the physical and the mental health component score
4. University of California Los Angeles (UCLA) activity scale: an outcome measure for activity assessment in THA patients, which has proven to be both reliable and valid [17, 18]
5. Visual analogue scale (1–10) to evaluate patient satisfaction scaled between 0 (lowest satisfaction) and 10 (highest satisfaction).

Radiological evaluation was performed on digitised radiographs and measurements were performed using DICOMeasure™ software (ViewTec; Maison-Alfort, France). The immediate postoperative standardised anteroposterior and lateral view radiographs were compared to the radiographs taken at ten years follow-up.

Qualitative evaluation of the acetabular component involved the analysis of the periacetabular zones described by DeLee and Charnley [19], thus recording the presence or absence of linear or focal osteolysis at the bone-cup interface.

Computer-assisted quantitative measurements (DICO-Measure™) used specific templates, with the diameter of the femoral head (28 mm) used for calibration. Cup migration was measured as the distance between a line joining the inferior aspect of the teardrop and the highest point of the cup. Polyethylene wear was measured using the dual-circle technique based on vector analysis as described by Martell and Berdia [20]. Since the Morscher cup has a bi-radial eccentricity, this technique had to be adapted by finding the circles that best fit the prosthetic femoral head and the superior hemisphere of the cup. The position of the cup was obtained by measuring the angle at the intersection of the line joining the inferior aspect of the teardrop and the line joining the highest and the lowest point of the ellipse projected on the radiograph, as described by Sutherland et al. [21].

Criteria for acetabular loosening included continuous radiolucencies around the cup in zones 1 to 3 according to DeLee and Charnley [19], a superior migration of greater than 4 mm, severe protrusion, and a progressive tilt of the cup [22].

For the stem, we recorded the presence of radiolucent lines of greater than 1 mm in width at the bone–cement interface or focal osteolysis, noting their dimension and location according to the zones of Gruen et al. [23]. However, radiolucent lines of 2 mm or less in the proximal one centimetre of Gruen zones 1 and 7 on the anteroposterior view and 8 and 14 on the lateral view were considered to be normal [24, 25].

Osteolysis at both femoral and pelvic locations was defined as an area of endosteal, intra-cortical or cancellous bone loss that was scalloped, or had the appearance of destruction of bone rather than osteopenia [24, 25].

Radiographic analysis was performed by the first author (GG). In order to assess the intra and inter-rater repeatability of the wear measurement, one of the co-authors (CB) repeated them independently twice at two different occasions among a random sample of 50 radiographs. For the inter-observer repeatability, the mean difference between the two wear measurements was 0.07 mm (95% CI –0.08 to 0.21), and for the intra-rater repeatability the mean difference was 0.01 mm (95% CI –0.16 to 0.14).

#### Data collection

Information about the patient's baseline characteristics and the surgical intervention was systematically documented by the operating surgeon on specifically designed data collection forms. The data were checked by a trained medical secretary and one of the investigators. All patients were contacted at ten years to arrange for a follow-up visit including a clinical and radiological examination and questionnaire assessment. Information about complications and/or revisions which were not treated at our institution was obtained either during the follow-up visit or by phone. Follow-up examinations were done by three trained physicians who had not performed the operations.

#### Statistical analysis

We used Kaplan-Meier survival analysis to calculate the ten-year survivorship with cup revision for any reason as endpoint. Censoring was performed at time of death, loss to follow-up or cup replacement. The 95% confidence intervals (95% CI) were presented.

To investigate a potential age-related linear trend within the HHS and UCLA scores, we used linear regression models including age as a continuous variable.

In order to evaluate inter-rater repeatability, the mean difference between the two wear measurements and the 95% confidence limits of agreement were calculated. SPSS version 15.0 (SPSS, Chicago, IL) and STATA version 8.1 (STATA Corporation, TX) were used for the analyses.

## Results

There were 561 THAs performed in 518 patients. The mean age was 69.3 years (range, 24–98 years), 54.6% of patients were women, and the mean body mass index (BMI) was 26.6 kg/m<sup>2</sup> ( $\pm$  4.4). With respect to preoperative Charnley categories, 39% of the THAs were performed in patients in category A, 40% in category B, and 21% in patients in category C. The mean preoperative Merle d'Aubigné and Postel score was 9.8 ( $\pm$ 1.6). In 82% of the interventions the diagnosis was primary osteoarthritis.

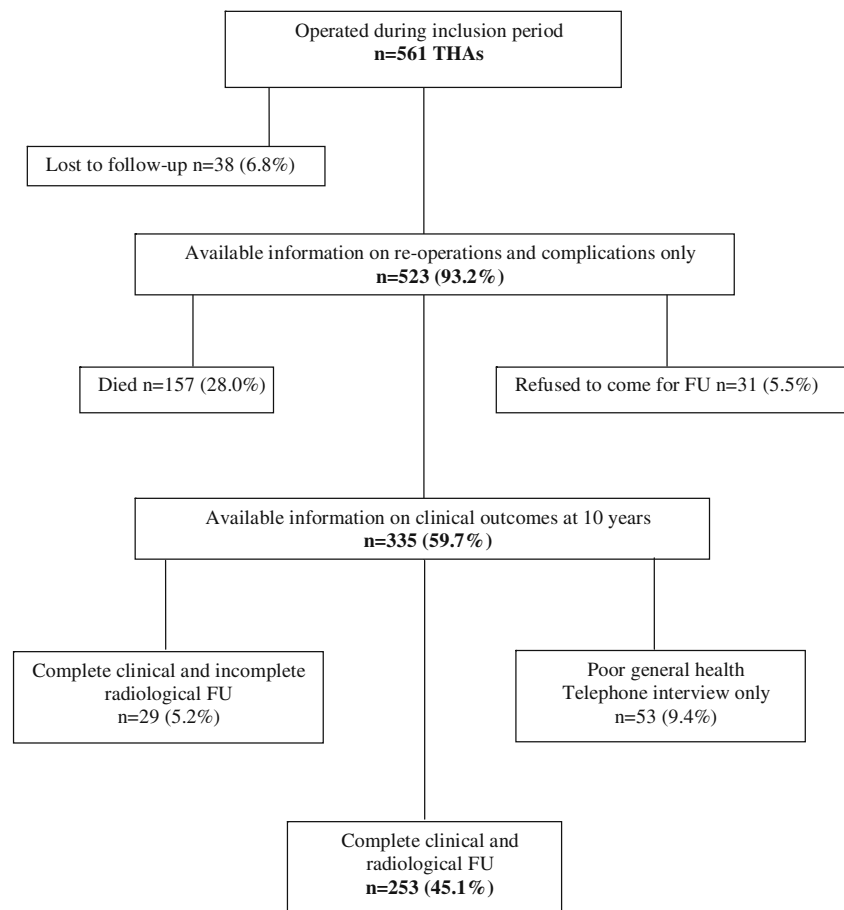
At 120 ( $\pm$ 7.3) months after operation, 157 (28.0%) patients had died, 38 (6.8%) were lost-to follow-up, and 31 (5.5%) patients refused to attend the follow-up visit. Fifty-three (9.4%) patients were unable to attend because of poor general health. Among these, 29 patients (5.2%) agreed to a telephone interview and questionnaire, and for the remaining 24 cases (4.3%) information was obtained from family members or caregivers. Overall, information on complications and clinical outcomes was available for 335 THAs (59.7%). Complete clinical evaluation was obtained in 282 THAs (50.3%), and complete radiographic follow-up was available for 253 interventions (45.1%) (Fig. 2).

The clinical outcome including scores and questionnaires at ten years is presented for all patients taken together and separately for the age categories <60, 60–79 and  $\geq$ 80 years (Table 1). Almost all of the patients (93%) were satisfied or very satisfied with the intervention. Patients over 80 years of age reported the highest satisfaction scores and a lower frequency of trochanteric pain, but the observed differences were small. The Harris hip and UCLA scores were highest among the youngest patients and decreased with advancing age.

None of the cups showed signs of loosening. Mean linear total wear was 0.9 mm ( $\pm$  0.5) (Table 2). Mean total wear was less than 1 mm in 172 hips, between 1 and 2 mm in 75, and between 2 and 2.5 mm in six hips. Cups with an inclination  $\geq$ 45° had a significantly higher mean linear total wear compared to those with an inclination <45° (1.1 mm vs. 0.9 mm). The mean difference was 0.2 mm (95% CI 0.04–0.40). In 21 cases, osteolytic defects were noted around the stem, but no radiolucencies were observed around the cup.

## Discussion

Uncemented acetabular fixation is a frequently used technique, not only in primary THA but also in revision surgery with acetabular defects [26, 27]. However, several studies have reported relatively high rates of pelvic osteolysis with uncemented cups [8, 9, 28]. Furthermore, in many of these cases, supplementary

**Fig. 2** Patient flowchart

screw fixation was used and the cups were mostly metal-backed modular systems with inherently higher PE-wear rates [20, 29].

Udomkiat et al. [8] reported the ten-year results of 110 THAs with a cementless porous-coated modular cup,

implanted using a press-fit technique without the use of screws. There was a 0.9% rate of aseptic loosening of the cups, but 18 of 110 hips (16%) had to be revised because of excessive wear of the polyethylene insert. The authors attributed this complication to the modularity of their cup.

**Table 1** Ten-year clinical outcomes and questionnaire results for all patients and according to three age categories

Evaluation	All patients( <i>n</i> =282)	Age <60years( <i>n</i> =62)	Age 60–79years( <i>n</i> =191)	Age ≥80years( <i>n</i> =29)
Merle d'Aubigné, mean (±SD)				
Preoperative	9.8 (1.6)	10.2 (1.7)	9.7 (1.6)	9.7 (1.4)
At follow-up	15.6 (2.3)	16.6 (1.8)	15.4 (2.2)	14.0 (3.1)
Harris hip score, mean (±SD)	85.7 (14.1)	91.0 (12.5)	85.4 (12.8)	76.1 (19.6)
Activity (UCLA) score, mean (±SD)	5.3 (2.1)	6.6 (1.9)	5.1 (1.9)	3.6 (1.8)
Patients satisfied/ very satisfied	93.4%	91.5%	93.6%	95.8%
Pain greater trochanter	13.8%	16.1%	14.1%	6.9%
Occasional	9.6%			
Mild	3.2%			
Moderate / strong	1.0%			
SF-12, mean (±SD)	<i>n</i> =192	<i>n</i> =43	<i>n</i> =134	<i>n</i> =15
Physical component score	39.7 (9.4)	42.4 (8.8)	38.9 (9.6)	39.7 (9.5)
Mental component score	45.7 (10.7)	41.6 (9.6)	47.0 (10.5)	45.3 (13.2)

SD standard deviation, SF-12 12-item short-form health survey

**Table 2** Ten-year radiological outcomes for all patients

Outcome	All patients( <i>n</i> =253)
Osteolysis cup, <i>n</i> (%)	–
Osteolysis stem, <i>n</i> (%)	21 (8.3)
Mean cup migration, mm ( $\pm$ SD)	2.5 ( $\pm$ 1.1)
Mean cup inclination ( $\pm$ SD)	39.9° ( $\pm$ 6.4)
Mean wear, mm ( $\pm$ SD)	0.9 ( $\pm$ 0.5)
Cup inclination $>45^\circ$	1.1 ( $\pm$ 0.6)
Cup inclination $\leq 45^\circ$	0.9 ( $\pm$ 0.5)

SD standard deviation

In addition, four hips needed revision because the polyethylene liner had dissociated from the cup. The reported rate of radiolucent lines around their cups was 7% and focal osteolysis was present in 4%. Young et al. [29] compared the results in terms of wear and osteolysis in two matched groups of patients, one having been treated with a non-modular, porous-coated cup and the other group with a modular cup. Although there was no significant difference in wear rate, the rate of osteolysis was significantly lower with the non-modular cups (2%) compared to the modular cups (22%). The authors concluded that non-modular acetabular components might be a partial solution to problems of wear and osteolysis, but considered non-modularity to be a disadvantage in those cases where the liner might need to be exchanged and the acetabular cup was stable.

To our knowledge, results on the use of the Morscher press-fit cup have so far been reported only by the inventor, very recently by Gwynne et al., and in the 2009 Annual Report of the Australian National Joint Replacement Registry [10–13]. In the study by Berli et al. [10], the authors reviewed 280 THAs in the first 261 patients operated upon. Complete radiological and clinical follow-up was available for 101 cases at a mean follow-up of 14.7 years, where mean age was 71 years. The overall survival of the cup was 95.3% and 97.5% using only aseptic loosening as an endpoint. Revision for aseptic loosening of the cup was performed in two cases and revision for aseptic loosening of both components in five cases. Additionally, osteolysis was found in two and radiolucencies around the cup in three cases. Similar results were recently reported by Gwynne et al. [12]. They reviewed 108 THAs at a mean follow-up of 11.2 years, with an overall survival of the cup of 95.7% (95% CI 88.6–98.4) and a 100% cup survival with aseptic loosening as an endpoint. The patients' mean age was 56.9 years. No radiolucencies were found around the cup, but 4.6% of the cases had developed acetabular osteolytic lesions.

In comparison, in our study we obtained a complete radiological and clinical follow-up for 253 THA at a mean

follow-up of ten years. Cup survival was similar with a 98.8% (95% CI 97.4–99.5) overall survivorship and a 100% survivorship with aseptic loosening as an endpoint. However, due to the greater sample size of our study the survival estimates are more precise. The revision rate for aseptic loosening was very low in all three studies, i.e. 0% in the study by Gwynne et al. [12] and in our study, 2.5% in the study by Berli et al. [10]. As for osteolytic defects around the cup, again very low incidences were reported, with 4.6% in the study by Gwynne et al. [12], 1.5% in the study by Berli et al. [10] and no cases of osteolysis in our study. Our patients' age (mean 69.3 years) was rather similar to that of Berli et al. [10] (mean 71 years); however, the patients included in the study by Gwynne et al. [12] (mean 56.9 years) were on average substantially younger.

Revision rates for Morscher cup used in combination with an uncemented stem are also reported from the Australian National Joint Replacement Registry (Annual Report 2009). The revision rate was 0.6 revisions (for all causes) per 100 observed years. Although the rate for the Morscher cup alone is not given in the registry report, this result figures among the lowest revision rates reported for cementless fixation [13].

In our study with the ceramic-PE pairing the mean linear total wear was 0.9 mm, which is comparable with the results of other reports [30–32]. We did not find any association between age and wear or between BMI and wear, but cups with an inclination  $\geq 45^\circ$  generated more wear than cups with a more horizontal position. The association between rate of wear and cup inclination has also been reported in the studies by Berli et al. [10] and Gwynne et al. [12] as well as by authors evaluating other types of cups [8, 14, 30].

Revision of the cup in our series was necessary in five cases—three for infection and two for recurrent dislocation. There were no revisions for failure of the polyethylene liner, and thus we believe that the theoretical disadvantage of non-modular cups is largely outweighed by reduction of the rate of wear and osteolysis. As previously noted by Berli et al. [10], we believe our good results with no radiolucencies around the cup at a ten-year follow-up are attributable to two main characteristics of the Morscher press-fit cup: a highly stable and reproducible press-fit fixation relying only on a bi-radial eccentricity, and a non-modular system reducing PE wear.

Osteolysis around the stem was present in 21 of 253 cases (8.3%). The rate of femoral osteolysis observed in our study was about the same as the rates reported by Mulroy et al. [25] (9 of 102 hips; 9%), Zicat et al. [9] (6 of 51 hips; 12%) and Kim et al. [30] (6 of 64 hips; 9%).

Among the complications we observed were 18 dislocations (3.2%), two of which required revision of the cup. Considering that the interventions were performed by a

mixed skill group of surgeons, the relatively low dislocation rate at ten-year follow-up is most likely attributable to the transgluteal surgical approach, which has as its consequence some degree of persistent lateral pain, noted to be 13.8% in our series. The pain was mostly reported to be occasional or mild and only 1% of patients complained of moderate pain.

Overall we found very good clinical results on the HHS score, with a deterioration in the older age category. Ritter et al. [33] reported that the decline in functional scores following total joint arthroplasty suggests deterioration in the functional capacity of the ageing population rather than an implant related problem, and our findings confirm this assumption. The opposite however was noted for the level of patient satisfaction, which was seen to be greater with increasing age.

This study is the largest series of patients with a Morscher press-fit cup acetabular replacement, and it confirms previously reported excellent clinical and radiological results at ten-years after operation.

**Source of funding** This work was supported by grants from Zimmer and Johnson & Johnson. However, they were not involved with the collection and analysis of data or the preparation of the manuscript.

## References

- Latimer HA, Lachiewicz PF (1996) Porous-coated acetabular components with screw fixation. Five to ten-year results. *J Bone Joint Surg Am* 78(7):975–981
- Smith SE, Harris WH (1997) Total hip arthroplasty performed with insertion of the femoral component with cement and the acetabular component without cement. Ten to thirteen-year results. *J Bone Joint Surg Am* 79(12):1827–1833
- Barrack RL, Mulroy RD Jr, Harris WH (1992) Improved cementing techniques and femoral component loosening in young patients with hip arthroplasty. A 12-year radiographic review. *J Bone Joint Surg Br* 74:385–389
- Sullivan PM, MacKenzie JR, Callaghan JJ, Johnston RC (1994) Total hip arthroplasty with cement in patients who are less than fifty years old. A sixteen to twenty-two-year follow-up study. *J Bone Joint Surg Am* 76:863–869
- Schulte KR, Callaghan JJ, Kelley SS, Johnston RC (1993) The outcome of Charnley total hip arthroplasty with cement after a minimum twenty-year follow-up. The results of one surgeon. *J Bone Joint Surg Am* 75:961–975
- Dorr LD, Wan Z, Cohen J (1998) Hemispheric titanium porous coated acetabular component without screw fixation. *Clin Orthop* 351:158–168
- Morscher E, Berli B, Jockers W, Schenk R (1997) Rationale of a flexible press fit cup in total hip replacement. 5-year followup in 280 procedures. *Clin Orthop* 341:42–50
- Udomkiat P, Dorr LD, Wan Z (2002) Cementless hemispheric porous-coated sockets implanted with press-fit technique without screws: average ten-year follow-up. *J Bone Joint Surg Am* 84-A(7):1195–1200
- Zicat B, Engh CA, Gokcen E (1995) Patterns of osteolysis around total hip components inserted with and without cement. *J Bone Joint Surg Am* 77:432–439
- Berli BJ, Ping G, Dick W, Morscher EW (2007) Nonmodular flexible press-fit cup in primary total hip arthroplasty: 15-year followup. *Clin Orthop Relat Res* 461:114–121
- Morscher E (1992) Current status of acetabular fixation in primary total hip arthroplasty. *Clin Orthop Relat Res* 274:172–193
- Gwynne-Jones DP, Garneti N, Wainwright C, Matheson JA, King R (2009) The Morscher press fit acetabular component: a nine- to 13-year review. *J Bone Joint Surg Br* 91(7):859–864
- Australian National Joint Replacement Registry (2010) Annual report 2009. [http://www.dmac.adelaide.edu.au/aoanjrr/documents/aoanjrrreport\\_2009.pdf](http://www.dmac.adelaide.edu.au/aoanjrr/documents/aoanjrrreport_2009.pdf). Accessed 4 May 2010
- Harris WH (1969) Traumatic arthritis of the hip after dislocation and acetabular fractures: treatment by mold arthroplasty. An end-result study using a new method of result evaluation. *J Bone Joint Surg Am* 51(4):737–755
- Merle d'Aubigné RM, Postel M (1954) Functional results of hip arthroplasty with acrylic prosthesis. *J Bone Joint Surg Am* 36-A:451–475
- Ware J Jr, Kosinski M, Keller SD (1996) A 12-item short-form health survey: construction of scales and preliminary tests of reliability and validity. *Med Care* 34(3):220–233
- Beaulé PE, Dorey FJ, Hoke R, Leduff M, Amstutz HC (2006) The value of patient activity level in the outcome of total hip arthroplasty. *J Arthroplasty* 21(4):547–552
- Naal FD, Impellizzeri FM, Leunig M (2009) Which is the best activity rating scale for patients undergoing total joint arthroplasty? *Clin Orthop Relat Res* 467(4):958–965
- DeLee JG, Charnley J (1976) Radiological demarcation of cemented sockets in total hip replacement. *Clin Orthop Relat Res* 121:20–32
- Martell JM, Berdia S (1997) Determination of polyethylene wear in total hip replacements with use of digital radiographs. *J Bone Joint Surg Am* 79:1635–1641
- Sutherland CJ, Wilde AH, Borden LS, Marks KE (1982) A ten-year follow-up of one hundred consecutive Müller curved-stem total hip-replacement arthroplasties. *J Bone Joint Surg Am* 64(7):970–982
- Hodgkinson JP, Shelley P, Wroblewski BM (1988) The correlation between the roentgenographic appearance and operative findings at the bone-cement junction of the socket in Charnley low friction arthroplasties. *Clin Orthop Relat Res* 228:105–109
- Gruen TA, McNeice GM, Amstutz HC (1979) “Modes of failure” of cemented stem-type femoral components: a radiographic analysis of loosening. *Clin Orthop Relat Res* 141:17–27
- Clohisey JC, Harris WH (1999) Primary hybrid total hip replacement, performed with insertion of the acetabular component without cement and a precoat femoral component with cement. An average ten-year follow-up study. *J Bone Joint Surg Am* 81(2):247–255
- Mulroy RD, Estok DM, Harris WH (1995) Total hip arthroplasty with use of so-called second-generation cementing techniques. A fifteen-year-average follow-up study. *J Bone Joint Surg Am* 77:1845–1852
- Elke R, Berli B, Wagner A, Morscher EW (2003) Acetabular revision in total hip replacement with a press-fit cup. *J Bone Joint Surg Br* 85:1114–1119
- Morscher E, Elke R, Berli B (2000) Classification and treatment methods of acetabular deficiencies. In: Duparc J (ed) *Surgical techniques in orthopedics and traumatology*. Elsevier, Paris, France, p 55

28. Barrack RL, Folgueras A, Munn B, Tvetden D, Sharkey P (1997) Pelvic lysis and polyethylene wear at 5–8 years in an uncemented total hip. *Clin Orthop* 335:211–217
29. Young AM, Sychterz CJ, Hopper RH Jr, Engh CA (2002) Effect of acetabular modularity of polyethylene wear and osteolysis in total hip arthroplasty. *J Bone Joint Surg Am* 84:58–63
30. Kim YH, Kook HK, Kim JS (2002) Total hip replacement with a cementless acetabular component and a cemented femoral component in patients younger than fifty years of age. *J Bone Joint Surg Am* 84-A(5):770–774
31. García-Rey E, García-Cimbrelo E (2008) Clinical and radiographic results and wear performance in different generations of a cementless porous-coated acetabular cup. *Int Orthop* 32(2):181–187
32. Zichner LP, Willert HG (1992) Comparison of alumina-polyethylene and metalpolyethylene in clinical trials. *Clin Orthop* 282:86–94
33. Ritter MA, Thong AE, Davis KE, Berend ME, Meding JB, Faris PM (2004) Long-term deterioration of joint evaluation scores. *J Bone Joint Surg Br* 86(3):438–442