

CASE REPORT

G. Ulrich Exner · Charles E. Dumont
Theodore I. Malinin · Arthur R. von Hochstetter**Recurrent aggressive chondrosarcoma of the middle phalanx of the index finger: excision and reconstruction with an osteocartilaginous allograft**Received: 26 August 2002 / Published online: 13 June 2003
© Springer-Verlag 2003

Abstract *Introduction:* Chondrosarcomas are malignant tumours and need to be treated aggressively including ablative surgery. Bovée et al. and Mankin have recently drawn attention to a less aggressive behaviour of chondrosarcomas of the phalanges compared with those of other localizations including the metacarpals. *Materials and methods:* An 12 year follow-up of a patient with a chondrosarcoma of the middle phalanx of the index finger is presented. The lesion was curetted initially, and a repeat curettage was performed 4 years later. Finally, 8 years later the phalanx was excised and reconstructed with an osteocartilaginous allograft. Histologically, the lesion changed from a chondrosarcoma grade I to grade II. *Result:* The patient continues to be free of recurrence and metastases 4 years after the final resection. *Conclusion:* The potential for systemic disease of chondrosarcomas of the phalanges is probably much lower than in chondrosarcomas of other localizations, and therefore digit-sparing techniques may be considered rather than ablative procedures.

Keywords Chondrosarcoma · Phalanges**Introduction**

Recently, Mankin [6] stated, ‘it is clear that chondrosarcoma of the hand and foot digits are not only rare but, by standards of other sites, are benign. They can and should be treated differently from chondrosarcomas of the pelvis or scapula, and amputative or disabling surgery rarely

should be necessary’. This is challenging and may seem very controversial when not too long before an analysis of 111 patients with chondrosarcoma of small bones of the hands and feet collected at the Mayo Foundation by Ogose et al. [7] led to the conclusion and publication in the same journal that ‘chondrosarcoma of small bones of the hands and feet has the potential to be fatal’.

We wish to present the observation of a recurring high-grade chondromatous lesion of the middle phalanx of the left index finger of a flutist followed at our institution over a period of 12 years; to discuss the treatment recommendations found in the recent literature; and to demonstrate the digit-sparing procedure used in the present case.

Case report

Our patient, a professional flutist, presented at age 60 years because of swelling and mild discomfort of the middle phalanx of the left index finger. The initial X-ray (Fig. 1a) showed an osteolytic process with moderate expansion of the middle phalanx. The lesion was curetted and filled with autologous bone in December 1990. The situation 9 months postoperatively is documented in Fig. 1b. The patient was seen annually, and the X-rays taken looked unremarkable. In November 1994 the patient complained again of pain, and a destructive process with expansion of the bone was again documented (Fig. 1c). Amputation was discussed, but the patient being a professional flutist strongly refused amputation. The lesion was therefore curetted again and the cavity filled with liquid nitrogen as adjuvant therapy. To achieve reduction, the phalanx was squeezed manually and filled again with autologous bone from the pelvis.

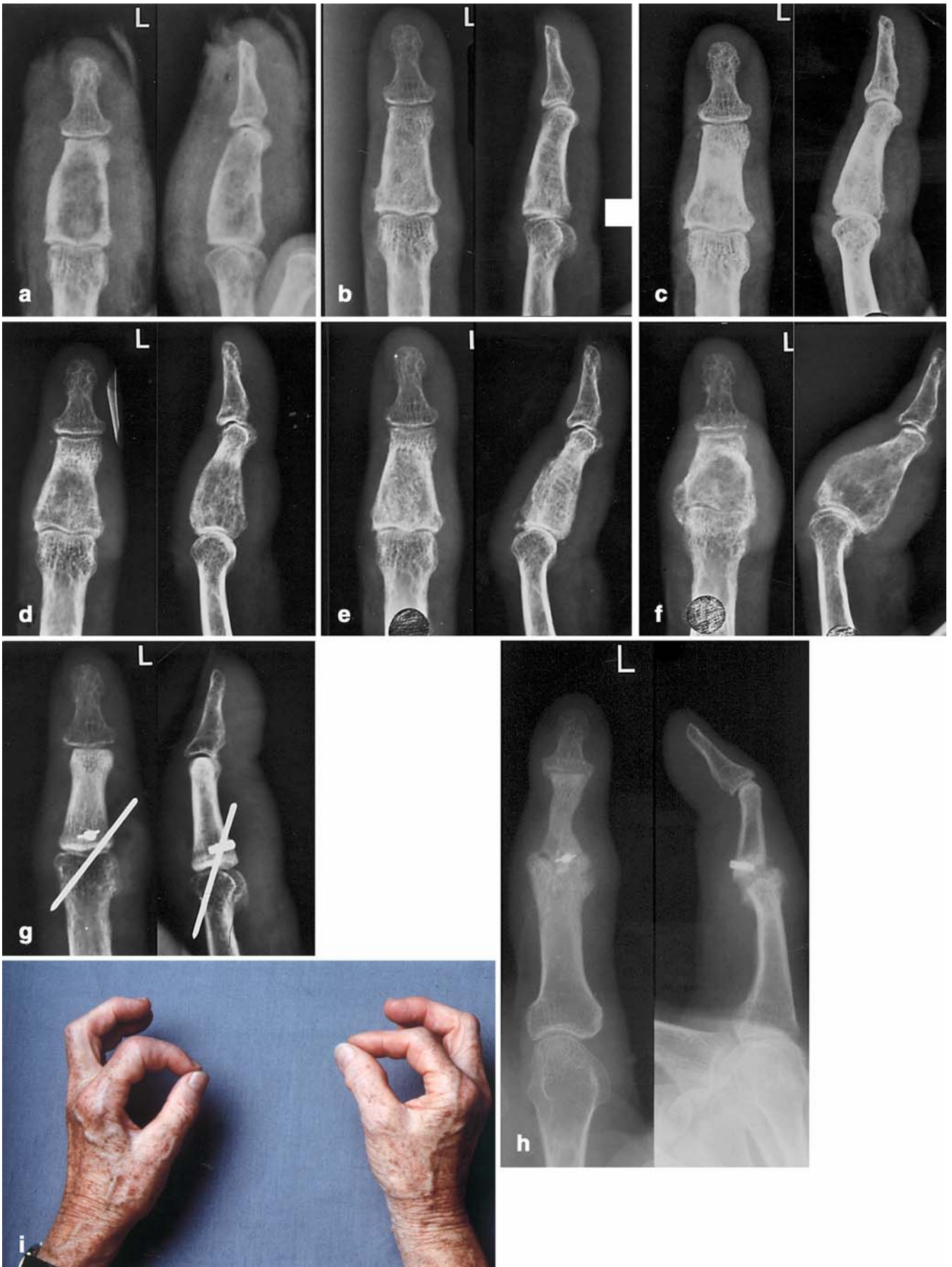
Fig. 1d shows the phalanx 7 months postoperatively. From 1 year after surgery onwards, the lesion appeared to be growing slowly again (Fig. 1e), and ablative surgery was discussed repeatedly with the patient. Finally, continuing growth of the lesion (Fig. 1f) bothered the patient sufficiently that a total en bloc excision of the middle phalanx was undertaken, 8 years after the original surgery, and reconstruction with a fresh-frozen allograft with tendons was performed. Temporary K-wire fixation was placed through the proximal interphalangeal joint, and the superficial flexor tendon was fixed with an anchor as shown in Fig. 1g; the volar plate, the collateral ligaments and the extensor hood were also reconstructed.

One and a half years following the last surgery, the patient is playing the flute. At follow-up 2 years after surgery, there is some Charcot-joint-like destruction (Fig. 1h); at the last follow-up 3 years after surgery, the patient continues to be free of local recurrence and metastases.

G. U. Exner (✉) · C. E. Dumont
BALGRIST, Department of Orthopaedics, University of Zürich,
Forchstr. 340, 8008 Zürich, Switzerland
Tel.: +41-1-3863090, Fax: +41-1-3863099,
e-mail: guexner@balgrist.unizh.ch

T. I. Malinin
Department of Orthopedics, University of Miami,
Miami, Florida, USA

A. R. von Hochstetter
Pathologie Enge, Zürich, Switzerland



◀ **Fig. 1** **a** Expansion of the middle phalanx of the left index finger with a central osteolysis and irregular margins. **b** Nine months after curettage and filling with autologous bone, the phalanx appears to have a somewhat normal trabecular bone structure. The outlines are narrower, evidently caused by subperiosteal resorption of the hypertrophic cortices. **c** At 3 years and 7 months after the primary procedure, the bone appears more sclerotic, but otherwise unchanged. **d** Four months after the X-ray in **c**, marked osteolysis has developed, and the cortical outlines are widened. The lesion was curetted and again filled with autologous bone. **e** Two months following the second curettage and bone plasty, the trabecular structure has remodelled. **f** X-ray shows significant osteolysis of the expanded middle phalanx. **g** Documentation immediately following the excision of the middle phalanx and reconstruction with an osteochondral allograft. The subcutaneous K-wire was removed 6 weeks postoperatively. **h** At 2 years after reconstruction with the allograft at PIP level, a Charcot joint has developed proximally, while the DIP functions well. **i** Clinical photograph taken 3 years after reconstruction

Pathologic findings

Originally interpreted as enchondromatous neoplasia, the original curettings revealed the hallmarks of an aggressive chondromatous lesion (Fig. 2a): confluent lobules of neoplastic cartilage with loss of grouping of markedly atypical chondrocytes. In addition, there was infiltration of the cortical compartment with irregular expansion

of the Haversian systems; as well as shearing growth along endosteal planes of spongy trabeculae, causing foci of bone necrosis and destruction.

In the resection specimen, these alterations are more pronounced, cortical destruction being grossly appreciable (Fig. 2b). In addition, there was a considerable subperiosteal soft-tissue mass (Fig. 2c). Cytologic atypia, on the whole, is comparable to the primary specimen. These morphologic findings were deemed to be consistent with those of an aggressive cartilaginous neoplasm, or chondrosarcoma, grade II (of III).

Discussion

The recommendations for the treatment of chondrosarcomas of the digits span a wide range from ablative surgery to very conservative approaches. Good results with ablative surgery for low grade (I of III) chondrosarcoma of the digits were reported by Kocher and Jupiter[5] in one patient as the primary procedure, by Bonnet et al. [1] in two patients, and by Hernández-Vaquero et al. [4] in one patient and for a grade II chondrosarcoma in a second patient. Ray resection as well is recommended by Cawte et al. [3] on the basis of good experience with this procedure in a review of 12 patients including metatarsal and metacarpal ones.

In contrast, in a review by Bovée et al. [2] of 35 patients with chondrosarcomas grade I to III exclusively of the phalanges of the hand and feet, of whom 16 were treated by local curettage and 19 by amputation and where follow-up was available for 28, none had developed metastases in either group. However, of the 15 patients locally treated, 10 developed a recurrence. The conclusion was 'that given the excellent survival data, curettage with adequate follow-up should be considered as the treatment of choice if technically feasible, especially in those cases in which amputation would lead to a significant loss of hand function'.

It is particularly important to consider chondromatous lesions of the phalanges as a distinct group since they seem to behave differently to those of the other bones of the hands and feet. In the series of Ogose et al. [7], 1 patient among 28 with involvement of the phalanges developed metastases, while of 48 patients with involvement of the metacarpal and metatarsal and other bones, 11 went on to develop metastases.

In accordance with this, our patient shows that even in the face of a relatively high-grade chondrosarcoma, local treatment can be performed and a good long-term prognosis achieved.

Reconstruction using a total allograft replacement of the phalanx as the primary procedure is an option when confronted with extensive lesions or other situations with a high risk of local recurrence, considering that removal of the total bone probably offers a higher chance for local cure.

Chondrosarcomas of the phalanges behave less aggressively than those of other localizations and need to be separated from those of the metacarpals and metatarsals. To achieve local control in patients with a high risk for local recurrence, complete excision of a phalanx and its replacement with an allograft is an option to be considered.

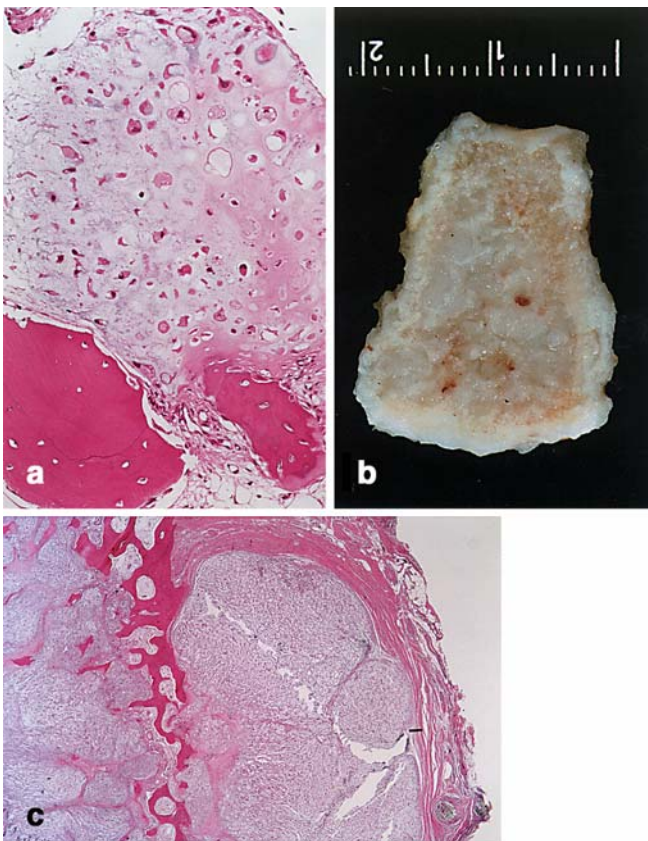


Fig. 2 **a** The first curettage shows confluent lobules of neoplastic cartilage with loss of grouping of markedly atypical chondrocytes. **b** In the resection specimen expansion and cortical destruction are grossly appreciable. **c** In addition, there is now a considerable subperiosteal soft-tissue mass. Cytologic atypia, on the whole, is comparable to the primary specimen

References

1. Bonnet C, Rochet N, Arnaud M, Martchenko, A, Traore A, Bertin Ph, Treves R, Desproges-Gotteron R (1990) Chondrosarcome des doigts. A propos de 2 observations. *Rev Rhum* 57:427–429
2. Bovée JVMG, Heul RO van der, Taminiau AHM, Hogendoorn PCW (1999) Chondrosarcoma of the phalanx: a locally aggressive lesion with minimal metastatic potential. A report of 35 cases and a review of the literature. *Cancer* 86:1724–1732
3. Cawte TG, Steiner GC, Beltran J, Dorfman HD (1998) Chondrosarcoma of the short tubular bones of the hands and feet. *Skeletal Radiol* 27:625–632
4. Hernández-Vaquero D, Cima-Suarez M, Garcia-Pravia C (1991) Chondrosarcoma of the bones of the hand. Report of two cases. *Arch Orthop Trauma Surg* 110:265–268
5. Kocher MS, Jupiter JB (2000) Enchondroma versus chondrosarcoma of the phalanx. *Orthopaedics* 23:493–494
6. Mankin HJ (1999) Chondrosarcoma of digits. Are they really malignant? *Cancer* 86:1724–1732
7. Ogose A, Unni KK, Swee RG, May GK, Rowland CM, Sim FH (1997) Chondrosarcoma of small bones of the hands and feet. *Cancer* 80:50–59