

D. Egli
O. Hausmann
M. Schmid
N. Boos
V. Dietz
A. Curt

Lumbar spinal stenosis: Assessment of cauda equina involvement by electrophysiological recordings

Received: 27 February 2006
Received in revised form: 20 September 2006
Accepted: 28 September 2006
Published online: 11 April 2007

D. Egli · V. Dietz (✉) · A. Curt
Spinal Cord Injury Center
University Hospital Balgrist
Forchstrasse 340
8008 Zürich, Switzerland
Tel.: +41-79/779-0615
E-Mail: eglidoris@bluewin.ch

O. Hausmann · N. Boos
Center for Spinal Surgery
University Hospital Balgrist
Zürich, Switzerland

M. Schmid
Radiology
University Hospital Balgrist
Zürich, Switzerland

A. Curt
ICORD and Division of Neurology
The University of British Columbia
Vancouver, Canada

■ **Abstract** The objective of this study was to investigate the relationship between electrophysiological recordings and clinical as well as radiological findings in patients suggestive to suffer from a lumbar spinal stenosis (LSS). We hypothesise that the electrophysiological recordings, especially SSEP, indicate a lumbar nerve involvement that is complementary to the neurological examination and can provide confirmatory information in less obvious clinical cases. In a prospective cohort study, 54 patients scheduled for surgery due to LSS were enrolled in an unmasked, uncontrolled trial. All patients were assessed by neurological examination, electrophysiological recordings, and magnetic resonance imaging (MRI) of the lumbar spine. The electrophysiological recordings focused on spinal lumbar nerve involvement. **Results** About 88% suffered from a multisegmental LSS and 91% of patients respectively complained of chronic lower back pain and/or leg pain for more than 3 months, combined

with a restriction in walking distance. The neurological examination revealed only a few patients with sensory and/or motor deficits while 87% of patients showed pathological electrophysiological recordings (abnormal tibial SSEP in 78% of patients, abnormal H-reflex in 52% of patients). **Conclusions** Whereas the clinical examination, even in severe LSS, showed no specific sensory-motor deficit, the electrophysiological recordings indicated that the majority of patients had a neurogenic disorder within the lumbar spine. By the pattern of bilateral pathological tibial SSEP and pathological reflexes associated with normal peripheral nerve conduction, LSS can be separated from a demyelinating polyneuropathy and mono-radiculopathy. The applied electrophysiological recordings, especially SSEP, can confirm a neurogenic claudication due to cauda equina involvement and help to differentiate neurogenic from vascular claudication or musculo-skeletal disorders of the lower limbs. Therefore, electro-

physiological recordings provide additional information to the neurological examination when the clinical relevance of a radiologically-suspected LSS needs to be confirmed.

■ **Key words** lumbar spinal stenosis · electrophysiological recordings · somatosensory evoked potentials · cauda equina involvement · lumbar nerve involvement · neurogenic claudication

Introduction

The syndrome of a lumbar spinal stenosis (LSS) was not widely diagnosed until Verbiest's clinical description in 1954 [48]. The cardinal symptom is neurogenic claudication (spinal claudication), defined as diffuse buttock and leg pain, paresthesias and cramping of one or both lower extremities induced by walking, and which is relieved when sitting and forward bending [40]. Walking ability can become substantially limited because of neurogenic claudication, driving the patients to seek medical help. Typically, the neurological examination of the lower limbs does not reveal any major deficit.

LSS is defined as a degenerative disorder showing a narrowing of the lumbar spinal canal. It is often combined with instability in one or several segments of the lumbar spine. LSS can be classified based on the anatomical location of the narrowing of the spinal cord (central spinal stenosis versus lateral recess stenosis), or based on the aetiology (primary or acquired) [41]. The stenosis most commonly results from degenerative changes such as facet joint degeneration, hypertrophic ligamenta flava, degenerative spondylolisthesis or lumbar intervertebral disc protrusion or a combination of these conditions [3].

There has been a substantial increase in the number of spinal decompression surgeries to treat patients with LSS [12]. LSS is presently the most common diagnosis for individuals older than 65 years undergoing spinal surgery [47]. Katz et al. (1996) published a statistical analysis [28] revealing that in the United States during 1994 more than 30,000 surgical procedures were performed for LSS, at a cost of almost US\$1 billion. Reasons cited for the rapid expansion in surgical rates include improved diagnostic imaging, improved surgical techniques and the aging of the population.

The advent of computed tomography (CT) and magnetic resonance imaging (MRI) enables a non-invasive visualization of both the bony structures (spinal canal and lateral recess) and neural tissue by sagittal and axial images [31]. Although the extent and type of the stenosis can exactly be described with

the current imaging studies, the extent of neural impairment and its functional effects cannot be derived by radiological means [3].

In cases with typical neurogenic claudication symptoms and unequivocal imaging findings the diagnosis is straightforward. However, not all patients present with typical symptoms and there is obviously no correlation between the severity of stenosis (CT and MRI) and clinical complaint. Recent MRI studies have shown that mild to moderate stenosis can also be found in asymptomatic individuals [7]. The clinical presentation in these typically elderly patients is often confused with symptoms of peripheral neuropathy or additional musculo-skeletal pain. In these cases, it is often difficult to decide whether the stenosis does indeed induce the painful symptoms. However, this issue is crucial when surgery is being considered for these patients.

The objective of this study was to investigate the relationship between electrophysiological recordings and clinical as well as radiological findings in patients suggestive to suffer from a LSS. We hypothesise that the electrophysiological recordings, especially SSEP, indicate a lumbar nerve involvement complementary to the neurological examination and can provide confirmatory information in less obvious clinical cases.

Materials and methods

■ Study population

In a prospective cohort study, 54 patients scheduled for surgery due to LSS were enrolled in an unmasked, uncontrolled trial. Only patients suffering from a typical neurogenic claudication in combination with a MRI-based confirmation of the LSS were included. Patients were excluded if clinical evaluations revealed signs or history of peripheral neuropathy (diabetes mellitus, hereditary neuropathy, alcoholism), pyramidal tract affection (spinal or cortical trauma) or peripheral vascular disease. Patients with pacemakers were excluded due to incompatibility with MRI examination. Patients with a history of disc herniation or any previous spine or brain surgery were also excluded. The study was approved by the local institutional review board and the patients gave informed consent to participate in the study.

■ Patient assessment

All examiners were staff members of the University Hospital Balgrist, Zurich. However, they were not involved in the decision making process. The tests were performed independently and the data provided to the attending surgeon. Clinical examination was performed by an orthopaedic spine surgeon, neurological and electrophysiological recordings were assessed by a neurologist, and the spinal MRI was reviewed by a staff spine radiologist. The retrieved data were compared with established reference values from the literature without comparison to a control group.

■ Neurological examination

The neurological examination of the lower limbs of all patients was performed according to the protocol of the American Spinal Injury Association (ASIA) to define the extent and severity of neurological deficits of the lower limbs based on motor and sensory scores [17]. The reliability and validity of the applied ASIA motor and sensory testing in tetra- and paraplegic patients has been shown in several psychometric studies with high Kappa values and Intra Class Correlations [13, 21, 36]. The following muscles were tested: iliopsoas, quadriceps femoris, tibialis anterior, extensor hallucis longus, and ankle plantar flexors. The results were graded as: 0 = total paralysis, 1 = palpable or visible contraction, 2 = active movement, gravity eliminated, 3 = active movement, against gravity, 4 = active movement, against some resistance, 5 = active movement, against full resistance. The light touch testing was performed by touch sensation while pin prick was assessed using needle tip of a safety pin. The tested dermatomes were: L1, L2, L3, L4, L5, S1, S2, S3, S4–5 and the result of each quality was graded as 0 = absent, 1 = impaired, 2 = normal.

We then summarized the motor-sensory scores and formed three groups with none, minor or major deficits, separately: (1) ASIA motor score (no deficit = 50; minor = 48–49; major < 48); (2) ASIA pin-prick score (no deficit = 36; minor = 34–35; major < 34); and (3) ASIA light touch score (no deficit = 36; minor = 34–35; major < 34).

The lower limb reflexes (Patellar tendon reflex, Achilles tendon reflex) were rated as 0 = absent, 1 = diminished or 2 = normal.

■ Functional assessment

The functional assessment was achieved by testing the patients walking ability during the clinical examination and by a written questionnaire. In the clinical examination, the regular use of a stick or other walking aid was noted. Each patient was asked to perform a tip toe and heel gait for a distance of about 10 m. The aim of the functional assessment of the ability to perform tiptoe and heel gait was to expose a minor motor weakness or postural instability that could have been missed by the isolated motor testing. The patient was allowed to use his/her regular walking aids but had to succeed in walking the distance without personal assistance. As these gait patterns represent challenging motor functions they allow for an assessment of the integrity of complex sensory-motor interactions. Furthermore, the patients were asked about the maximal distance they felt comfortable walking (≤ 100 m, ≤ 500 m, ≤ 1 km or > 1 km) until they were forced to stop because of severe symptoms.

■ Pain questionnaire

The patients were asked to fill in a questionnaire focussing on the patients' complaint of pain, aimed at estimating the extent of pain symptoms induced by walking. Pain duration was assessed with a five-point Likert-scale (i.e. less than 1 week; more than 1 week;

more than 7 weeks; more than 3 months; more than 6 months). Pain intensity in the lower back and leg was assessed by using a visual analogue scale (VAS). Patients were asked to localize their typical pain (i.e. only back pain, predominantly back pain (>75%), back and leg pain equally, predominantly leg pain (>75%), only leg pain). Patients were asked to grade their current quality of life also by using a VAS, with 10 being the best imaginable quality of life.

■ Electrophysiological recordings

Somatosensory evoked potentials (SSEP)

Electrical stimulation (square wave of 0.2 ms duration applied at 3 Hz) of the tibial nerves of both legs (DANTEC, EMG 12 electromyograph Medical A/S, Skovlunde, Denmark) was used to elicit SSEPs. The stimulation was applied at the medial ankle with the cathode placed 2–3 cm proximal to the anode. The stimulus intensity (up to a maximum of 40 mA) was adjusted to produce a clear muscle contraction or sensation. Patients were lying prone at ambient room temperature. The scalp recording electrodes (conventional 0.5 cm gold cup electrodes) were positioned at Cz'-Fz (international 10/20 electrode system). The electrode impedance was maintained at < 5 k Ω . The amplifier was set at 5 μ V/division and the time of analysis at 60 ms. Two sets of 500 responses were averaged and superimposed to ensure consistency. Body height-matched reference values of SSEP for healthy control subjects were based on Hausmann et al. (2003) [24].

Nerve conduction studies (NCS)

A conventional EMG device (DANTEC, EMG 12 electromyograph Medical A/S, Skovlunde, Denmark) was used to perform the nerve conduction studies (NCS) including F-wave and H-reflex recordings from temperature-controlled skin. Supramaximal, rectangular wave stimuli of 0.2 ms duration were applied to the tibial nerve distally at the ankle and proximally at the knee. The muscle responses were recorded via surface electrodes (Dantec Silver Chlor Disc Electrode) placed over the abductor hallucis brevis muscle. The signals were bandpass-filtered between 10 Hz and 10 kHz. The compound muscle action potential (CMAP) (baseline to peak) and the motor nerve conduction velocity (NCV) of the tibialis muscle were calculated. Normal values were set as follows, in accordance with previous studies. The tibial CMAP was classified as pathological below 5.7 mV [29]. Age and height-matched reference values of NCV for healthy control subjects were based on Buschbacher (1999) [11].

The F-wave responses of the tibial nerve were recorded with the same installation used for the NCS recordings. Consecutive F-wave responses ($n = 20$) to supramaximal stimulation of the tibial nerve were analyzed. The excitability of F-waves (if any F-wave could be recorded) and the persistence of F-waves (occurrence in percent of F-wave responses to 20 stimuli) were assessed. F-wave latencies were measured from the stimulus artefact to the onset of the F-wave (F-min-response). F-wave responses with amplitude greater than 20 μ V and reproducible responses within latency between 40 and 85 ms were accepted. Age and height-matched reference values of F-wave responses for healthy control subjects were based on Buschbacher (1999) [10].

The H-reflex of the soleus muscle was recorded by using the following equipment settings: sensitivity 500 μ V/division; low frequency filter 2–3 Hz; high frequency filter 10 kHz; and sweep speed 10 ms/division. The active electrode was placed over the soleus muscle in the apex of the hollow formed by the heads of the gastrocnemius muscles, with the second electrode 3–5 cm distally. The stimulus duration was 1 ms with an inter-stimulus interval of at least 10 s. Stimuli were applied by surface elec-

trodes (cathode proximal) to the tibial nerve in the popliteal fossa. The ground electrode was placed proximal to the active electrode. The maximal H response was recorded first, followed by the maximal M response. All latency measurements were done off line from the records on PC storage. Latencies were measured from the beginning of the stimulus to the initial deflection of the response. The H-reflex and the HM-interval (latency max H-latency max M) were calculated both for the right and the left leg [8]. Age and height controlled reference values were used by Burke (1999) for the H-reflex [9] and by Visser (1983) for the HM-interval [50].

■ Magnetic resonance imaging

The MRI scans were performed using a 1.0 T MR unit (Expert, Siemens Medical Solutions, Erlangen, Germany) and a dedicated receive-only spine coil. The imaging protocol of these examinations consisted of a sagittal T1-weighted spin-echo (TR/TE 700 ms/12 ms, section thickness 4 mm, intersection gap 0.8 mm; FOV 300 mm, Matrix 512 × 512, 4 acquisitions), a T2-weighted turbo spin-echo (TR/TE 5000 ms/130 ms, section thickness 4 mm, intersection gap 0.8 mm; echo train length 15; 4 acquisitions) sequences, and an axial T2-weighted turbo spin-echo sequence (TR/TE 4000 ms/96 ms; section thickness 4 mm, intersection gap 0.8 mm; FOV 300 mm, Matrix 512 × 512, echo train length 7; FOV 150 mm, Matrix 256 × 256, 2 acquisitions).

Quantitative assessment: All axial T2-weighted images were digitized using a 12-bit scanner (VXR-12 plus[®] film digitizer, Vidar Systems Corp., Herndon, VA). Cross sectional areas were measured at the level of the intervertebral disk using Image Access[®] (Imagic Imaging Solutions, Switzerland) software. On axial MRI scans, the following three of cross sectional areas were measured in each patient: (1) the area defined by the bony structures of the spinal canal, (2) the area within the spinal canal defined by the ligamentous structures, and (3) the intra-dural area defined by the dura mater. As shown in previous studies by Coulier (2003) [13] the measurement of the dural cross-sectional area is considered the best method for defining central spinal canal stenosis. Therefore, the intradural cross-sectional area was chosen selectively for further statistical calculation. We divided all patients into two groups depending on the degree of the stenosis: most stenotic level of the dural cross-sectional area $\geq 1.6 \text{ cm}^2$ was regarded as not stenotic, area $\geq 0.8 \text{ cm}^2$ and $< 1.6 \text{ cm}^2$ as mild stenosis, and area $< 0.8 \text{ cm}^2$ as severe stenosis.

■ Statistics

Statistical evaluations were performed using an SAS software package. Parametric Correlations with Pearson coefficient and significance were calculated to compare the electrophysiological recordings (SSEP), the morphological measures (most stenotic segment/number of stenotic levels), the neurological deficit (Motor/Pin prick/Light touch score) and clinical findings (pain intensity). The level of statistical significance was set to $p < 0.05$ (two-tailed).

Results

Fifty-four patients suffering from LSS and undergoing decompressive spinal surgery (22 men, 32 women; mean age 70 years, range 49–86 years) were enrolled. The average height of the patients was 167 cm (range 150–180 cm).

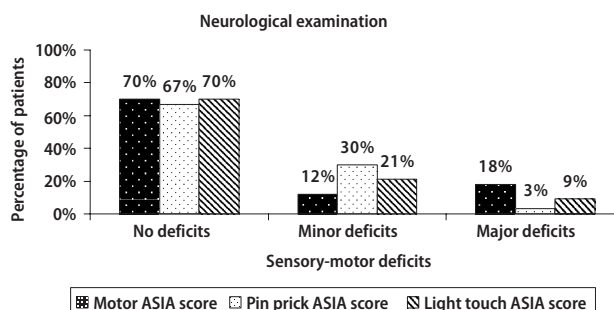


Fig. 1 Outcome of the neurological examination based on the sensory-motor scoring in no, minor or major deficits. Data are given as percentage of patients

■ Neurological examination and functional assessment

In 70% of patients the motor and/or sensory (pin prick and light touch) scores were normal (Fig. 1). Minor deficits in motor, pin prick and light touch could be found in 12%, 30% and 21% of patients, respectively, while major deficits were found in 18%, 3% and 9%. A detailed list of sensory-motor and reflex results is presented in Table 1. The most sensory and motor deficits were found at the level L4–L5 which correlates with the radiologically confirmed level of stenosis. The sensory-motor deficit was independent of the degree of stenosis. Examination of lower limb reflexes showed an absent Achilles tendon reflex in 42% of patients, mostly (87%) bilateral, whereas the patellar tendon reflex was responsive in 91%. Tiptoe gait and heel gait could be performed bilaterally by 95% and 89% of patients, respectively. In patients successfully performing the tiptoe and heel gait, there was no evidence of a clinically relevant postural instability. Only one patient in the whole study group regularly used a stick as a walking aid, while none of the subjects needed a walking frame or a wheelchair. Since over 90% of patients were able to perform tiptoe and/or heel gait, motor weakness was estimated to be of minor relevance in most cases. However, 68% of patients indicated suffering from a severe reduction of walking distance limited to 500 m or less (maximal preoperative walking distance ≤ 100 m in 28%, ≤ 500 m in 40%, ≤ 1 km in 15%, > 1 km in 17% of patients) (Table 2).

■ Pain questionnaire

The vast majority of patients (91%) experienced chronic pain for more than 3 months, while 73% of patients experienced it for more than 6 months. Pain induced by walking was indicated to be moderate, strong and severe in 6%, 33% and 61%, respectively. The mean pain intensity was 7.9/10 VAS (range 2–10).

Table 1 Outcome of the neurological examination of the lower limbs according to the ASIA protocol. Data are given as percentage of patients with normal scores at the specific muscle or dermatomal level and including the reflex status

	Normal in %	Normal in %
<i>Motor ASIA score</i>	Right side	Left side
L2 (M.iliopsoas)	100%	100%
L3 (M.quadriceps femoris)	97%	97%
L4 (M.tibialis anterior)	85%	94%
L5 (M.extensor hallucislongus)	85%	85%
S1 (Ankle plantar flexors)	97%	97%
<i>Sensory ASIA score</i>		
<i>Light touch</i>	Right side	Left side
L1	97%	100%
L2	97%	100%
L3	94%	100%
L4	94%	97%
L5	91%	88%
S1	88%	94%
S2	100%	100%
S3	100%	100%
S4-5	100%	100%
<i>Pin prick</i>	Right side	Left side
L1	100%	100%
L2	100%	100%
L3	100%	100%
L4	100%	97%
L5	88%	85%
S1	91%	97%
S2	100%	100%
S3	100%	100%
S4-5	100%	100%
<i>Reflexes</i>	Right side	Left side
Patellar tendon reflex	91%	91%
Achilles tendon reflex	58%	58%

Most patients (85%) suffered from both back/buttock and leg pain, while only 6% had only back pain and 9% only leg pain. Quality of life was substantially limited in almost all patients (97%) with the VAS averaged 3.9/10 (range 0–10) (Table 2).

■ Electrophysiological recordings

The evaluation of the electrophysiological recordings is based on established reference values from the literature without comparison to a control group (Table 3). In total, 47/54 patients (87%) exhibited abnormal electrophysiological recordings.

Somatosensory evoked potentials (SSEP)

In 78% of patients the tibial SSEP recordings were pathologically delayed according to the body height-corrected reference values. In 90% of these patients, both sides were symmetrically affected, while unilateral SSEP impairment was found in four cases (10%). In one patient the SSEP were completely abolished. 21% of patients showed normal SSEP (Table 4).

Table 2 Questionnaire to assess the duration of preoperative pain, intensity and distribution of lower back/leg pain, as well as the perceived quality of life and the preoperative walking ability. The patients answered a written questionnaire and the results are tabulated below in percentage values

	% of patients
<i>Preoperative duration of pain</i>	
<1 week	0
>1 week	6
>7 weeks	3
>3 months	18
>6 months	73
<i>Intensity of back and leg pain (mean VAS = 7.9)</i>	
0–1 (no pain)	0
2–4 (moderate pain)	6
5–7 (strong pain)	33
8–10 (very severe pain)	61
<i>Distribution of pain</i>	
Only back pain	6
Mostly back pain	12
Back and leg pain equal	33
Mostly leg pain	39
Only leg pain	9
<i>Quality of life (mean VAS = 3.9)</i>	
0–3 (poor)	52
4–7 (moderate)	45
8–10 (good)	3
<i>Preoperative walking ability</i>	
100 m	28
500 m	40
1000 m	15
>1000 m	17

Nerve conduction studies (NCS)

Pathological reduction of the CMAP could be found in 39% of patients as compared to age and height-matched control values. About 9% of the patients showed a minor slowing of motor NCV (unilateral in 4 patients, bilateral in 1 patient) without any other signs of peripheral neuropathy.

F-wave responses could be determined for all patients. 15% of patients showed pathologically delayed recordings as compared to age and height-matched control values. The F-wave persistence was usually normal, with an average F-wave persistence of 89%. Only in 2 patients was the persistence reduced to less than 50% unilaterally.

Pathologically prolonged H-reflex was found in 52% of patients as compared to age and height-matched control values. In about 50% of these patients the H-reflex was bilaterally delayed, whereas the motor nerve conduction velocity was within normal limits for these patients (Table 4).

■ Magnetic resonance imaging

Severe lumbar canal stenosis was diagnosed in 75% of patients, while 25% of patients had mild stenosis. In all patients, dural sac cross-sectional area at its most

Table 3 Documentation of established reference norms from the literature used for the evaluation of the electrophysiological recordings without comparison to a control group

Reference values for:	Set as pathological if (mean \pm 2 SD) is:	Correlation of:
SSEP	$>0.199 \times \text{height} + 3.9037 + 5$	height correlated
CMAP	<5.7 (mV)	Age (34–66 years) correlated
NCV height <160 cm	>39 (m/s)	Age (60–79 years) and height correlated
NCV height 160–170 cm	>35 (m/s)	Age (60–79 years) and height correlated
NCV height >170 cm	>34 (m/s)	Age (60–79 years) and height correlated
F-wave height <160 cm	>56.0 (ms)	Age (40–79 years) and height correlated
F-wave height 160–170 cm	>57.5 (ms)	Age (40–79 years) and height correlated
F-wave height 170–180 cm	>61.1 (ms)	Age (40–79 years) and height correlated
F-wave height >180 cm	>68.5 (ms)	Age (40–79 years) and height correlated
H-reflex	$>3.00 + 0.1419 \times \text{height} + 0.0643 \times \text{age} + 2 \times 1.47$ (ms)	Age and height correlated
HM-interval	$>0.058 \times \text{age} + 0.120 \times \text{height} + 2.70 + 2 \times 1.37$ (ms)	Age and height correlated

Table 4 Electrophysiological recordings of the whole group (all 54 patients) including somatosensory evoked potentials (SSEP), reflexes (F-wave and H-reflex), compound muscle action potential (CMAP) of both tibial nerves and motor nerve conduction velocity (NCV) are rated as normal, pathological or abolished responses. Data are given as number (percentage) of patients. Mean value (standard deviation) relates separately to all the normal and pathological data

Patients with	Normal findings	Mean values (SD)	Pathological findings	Mean values (SD)	Abolished responses
SSEP (ms)	11 (21%)	40.59 (1.89)	42 (78%)	45.97 (9.93)	1
H-reflex (ms)	25 (47%)	26.84 (2.16)	28 (52%)	32.44 (3.03)	1
CMAP (mV)	33 (61%)	10.23 (3.19)	21 (39%)	3.41 (1.81)	0
F-wave (ms)	46 (85%)	50.95 (4.31)	8 (15%)	63.73 (1.90)	0
NCV (m/s)	48 (90%)	43.18 (4.17)	5 (9%)	34.5 (2.92)	1

stenotic level ranged from 0.2 to 1.5 cm² (mean 0.65 cm²). About 88% of patients revealed more than one stenotic segment (Fig. 2A). In 68% of patients a significant compression was found in 2 or 3 segments. The most frequently stenotic level was L4/5 (72%), followed by L3/4 (22%) (Fig. 2B). The distribution of the range of stenosis is highlighted in Fig. 2C.

Correlation analysis

Pearson correlations analysis did not find a significant correlation between the electrophysiological recordings and the radiological findings (most stenotic segment: SSEP right $p = 0.925$, SSEP left $p = 0.374$; number of stenotic levels: SSEP right $p = 0.454$, SSEP left $p = 0.739$) the sensory deficit (pin prick: $p = 0.117$; light touch: $p = 0.894$), and the reported pain intensity ($p = 0.284$). Only the ASIA Motor score showed a low correlation to the extent of the most stenotic segment ($p = 0.039$, $r = 0.372$).

Discussion

The present study shows that superior to the clinical examination, the electrophysiological recordings show pathological findings in the majority of patients suffering from LSS. Especially, in those patients with

no obvious neurological deficit or moderate spinal stenosis the electrophysiological recordings can indicate a lumbar nerve involvement. In addition, in patients with radiological findings of LSS but no typical complaints of neurogenic claudication (and vice versa) the electrophysiological recordings can confirm the affection of cauda equina fibres.

Impact of clinical examination

In accordance with previous studies [31], the neurological examination in an elderly population (average age between 60 and 70 years in most studies) with symptoms of LSS revealed no or only minor sensory-motor deficits in over 80% of patients [51]. As the neurological findings, even in severe LSS, are mainly non-specific (no characteristic pattern of sensory-motor deficit) the diagnosis of LSS based on the neurological examination is challenging.

In general, the clinical diagnosis of a neurogenic claudication is suspected when the following symptoms are present: back and lower extremity pain induced by walking and/or standing, relief of pain when seating and by ventral bending, major reduction in walking distance ability and a wide-based gait [27]. In our study, severe leg and/or lower back pain were found in 94% of patients, and were present in a unilateral or bilateral distribution. However, pain is a frequent and

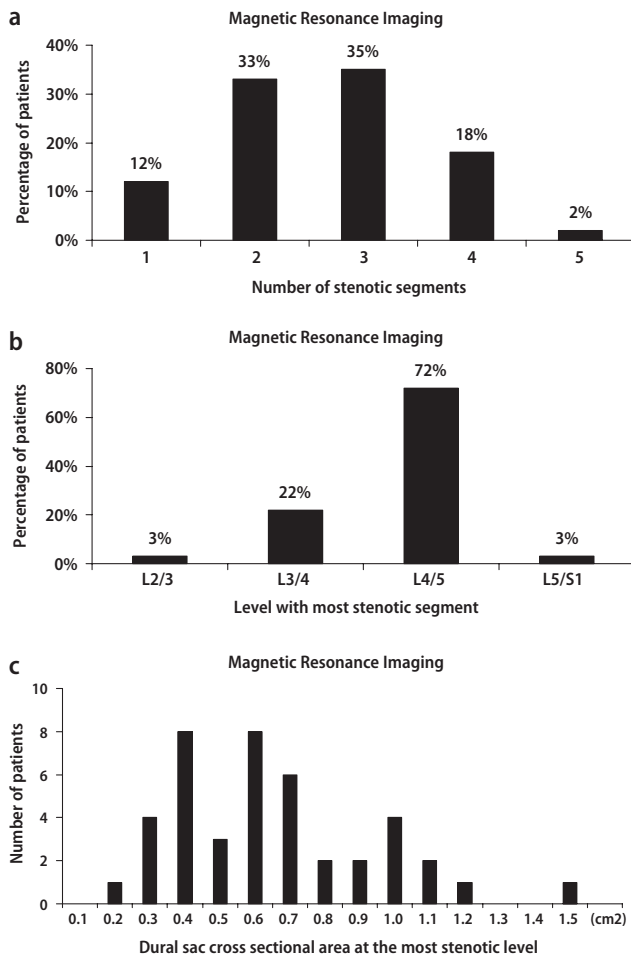


Fig. 2 (A) Number of stenotic segments in the patients suffering from LSS diagnosed by magnetic resonance imaging assessment. Data are given as percentage of patients (B) Level of lumbar stenosis in the patients suffering from LSS. Data are given as percentage of patients (C) Distribution of dural sac cross sectional area at the most stenotic level (cm²). Data are given as number of patients

non-specific symptom in elderly patients. Entrapment of the lumbosacral nerve roots in a constricted neural canal and foramina can lead to atypically distributed radicular pain, muscle weakness and movement induced pain syndromes with reduced walking capacity [35, 38]. Older patients suffering from polyneuropathy of different aetiologies can also challenge the clinical diagnosis of LSS [18, 49]. Additionally, osteoarthritis of the hip or knee and other less common conditions (like unstable isthmic spondylolisthesis and myxoedema claudication secondary to hypothyroidism) can produce claudication-like symptoms [6].

Impact of electrophysiological recordings

As is the case with other spinal disorders, i.e. spinal tumor, cervical myelopathy and spinal cord injury,

electrophysiological recordings can complement the clinical assessment of lumbar nerve involvement [15, 20, 25, 32, 42]. The present study is in accordance with a report comparing mild LSS with polyneuropathy [1]. Both diseases appear frequently in older age and may present with numbness and tingling of the feet, and clinical univocal diagnostic clues may be absent. Here the proposed electrophysiological recordings showed signs of a lumbar nerve involvement by delayed H-reflex and SSEP recordings while peripheral NCV was normal. These findings indicate a proximal segmental conduction failure at the lumbar level. A similar neurophysiological pattern of normal NCV but pathological reflex responses can be found in acute proximal polyneuritis. Especially in the early stage of this disorder, the proximal demyelination can be diagnosed by delayed or abolished H-reflex while the distal NCV is still normal [4, 52].

Tibial nerve SSEP recordings in dynamic studies indicated that SSEP recordings can confirm a neurogenic claudication due to cauda equina involvement [30]. They can be applied to differentiate neurogenic from vascular claudication, similar as shown in cervical spinal canal stenosis [55]. This was confirmed by a study using dermatomal somatosensory evoked potentials (DSSEP) [46]. DSSEP could indicate a dysfunction in the particular afferent neuronal pathway. However, unlike tibial nerve SSEP, they are not easy to perform and are not as routinely applied.

Patients with severe LSS showed, in addition to the H-reflex changes, a reduction of the CMAP (39% of subjects) indicating axonal damage. A pathological reduction or even complete loss of CMAP can be found in patients suffering from a degenerative or traumatic occlusion of the lumbar spinal canal. The nerve compression leads to an axonal damage and eventually a Wallerian degeneration of the peripheral nerve [26, 43].

Our analysis showed that F-wave values were less abnormal than the H-reflex and SSEP. Thus, while in demyelinating polyneuropathic disorders F-waves are of high sensitivity [29] they are less affected in LSS that primarily induces axonal damage due to nerve compression.

Electrophysiological recordings have also been applied during treadmill- or walking-stress tests to increase the diagnostic sensitivity in less symptomatic LSS patients [16, 33, 34, 39, 44]. In patients with mild LSS, electrophysiological recordings were pathological in an exercise treadmill test, but this was the case in patients both with and without neurogenic claudication [2]. Therefore, the significance of dynamic electrophysiological examinations as routine diagnostics of LSS remains open.

SSEP techniques with multiple peripheral and spinal recordings allow distinguishing spinal cord/

cauda lesions at and above the conus medullaris while focusing on the sensory pathways [5, 37, 54]. Combined SSEP and NCS recordings including reflex measurements have the advantage that both sensory and motor nerve components can be studied separately. As an impairment of SSEP and H-reflex might be induced by a primary sensory polyneuropathy sensory nerve conduction recordings should be considered. However, these are frequently affected even in healthy elderly subjects and therefore are of restricted value in proving the presence of a poor sensory neuropathy in these patients (mean age 70 years) [19].

We are aware that EMG studies including paraspinal recordings were shown to be sensitive in lumbar spinal canal stenosis [23]. Such EMG recordings become positive as soon as an axonal nerve root damage is established. However, the actual study intended to reveal signs of compression induced demyelination. This can be shown by delayed SSEP and reflex responses.

■ Impact of spinal magnetic resonance imaging

According to the literature MRI imaging is well established for diagnosis of LSS. Nevertheless, there exists currently no standardized grading of MRI scans in LSS. As a result, a high degree of variability might be expected [45]. In accordance with previous studies [3], there was no correlation between clinical symptoms and radiological findings. Imaging techniques distinguish mono- and multisegmental stenosis, as well as the severity of the stenosis that, however, are not related to the pain symptoms. This corroborates to neurophysiological recordings that also were not related to the morphology of the LSS assessed by imaging. Also the radiological distinction between

central and lateral stenosis was not related to any specific clinical symptoms. Therefore, MRI is of restricted value for diagnosing the clinical relevance of a LSS. Although the sensitivity and specificity of MRI for identifying individuals with LSS has previously been reported to be high [22], studies of asymptomatic individuals have reported false-positive imaging in approximately 20% of subjects [53]. Therefore, in clinically less clear cases it is advantageous to combine imaging and clinical findings with electrophysiological recordings.

Conclusions

Given the increasing prevalence of LSS in the aging population, along with the associated disability and costs, there is a need to improve the diagnostic assessment of patients assumed to be suffering from LSS. Both the clinical and neurological examinations are of restricted value in confirming the clinical relevance of a radiologically suspected LSS. Therefore, proof of spinal lumbar nerve affection in LSS would allow for an improvement in the diagnosis. Furthermore, the proposed electrophysiological recordings are able to exclude other neurological disorders that frequently occur in the elderly population. By this approach, the indication for surgical intervention versus non-surgical treatment can be supported by electrophysiological means. Whether the electrophysiological recordings in LSS provide any prognostic value of the outcome after surgery needs to be evaluated in further studies.

■ **Acknowledgement** We thank H. V. Hedel for performing the statistics and the International Institute for Research in Paraplegia (P66/01; Zürich, Switzerland) for financial support.

References

1. Adamova B, Vohanka S, Dusek L (2003) Differential diagnosis in patients with mild lumbar spinal stenosis: the contributins and limits of various tests. *Eur Spine J* 12:190–196
2. Adamova B, Vohanka S, Dusek L (2005) Dynamic electrophysiological examination in patients with lumbar spinal stenosis: Is it useful in clinical practice? *Eur Spine J* 14(3):269–276
3. Amundsen T, Weber H, Lilleas F, Nordal HJ, Abdelnoor M, Magnaes B (1995) Lumbar spinal stenosis: clinical and radiologic features. *Spine* 20:1178–1186
4. Atanasova D, Ishpekova B, Muradyan N, Novachkova S, Daskalov M (2004) Conduction block—the diagnostic value in the early stage of Guillain-Barre syndrome. *Electromyogr Clin Neurophysiol* 44(6):361–364
5. Baramki HG, Steffen T, Schondorf R (1999) Motor conduction alterations in patients with lumbar spinal stenosis following the onset of neurogenic claudication. *Eur Spine J* 8:411–416
6. Binder DK, Schmidt MH, Weinstein PhR (2002) Lumbar spinal stenosis. *Semin Neurol* 22(2):157–166
7. Boden SD, Davis DO, Dina TS, Patronas TS, Wiesel SW (1990) Abnormal magnetic-resonance scans of the lumbar spine in asymptomatic subjects. *J Bone Joint Surg Am* 72-A:403–408
8. Branddom RI, Johnson EW (1974) Standardization of H-reflex and diagnostic use in S1 radiculopathy. *Arch Phys Med Rehabil* 55:161–166
9. Burke D, Hallett M, Fuhr P, Pierrot-Deseilligny E (1999) H reflexes from the tibial and median nerves. *Recommend Pract Clin Neurophysiol* 6.4:259–262

10. Buschbacher RM (1999) Tibial nerve F-waves recorded from the abductor hallucis. *Am J Phys Med Rehabil* 78:43-47
11. Buschbacher RM (1999) Tibial nerve motor conduction to the abductor hallucis. *Am J Phys Med Rehabil* 78:15-20
12. Ciol MA, Deyo RA, Howell E, Kreif S (1996) An assessment of surgery for spinal stenosis: time trends, geographic variations, complications and reoperations. *J Am Geriatr Soc* 44:285-290
13. Cohen ME, Ditunno JF Jr, Donovan WH (1998) A test of the 1992 international standards for neurological and functional classification of spinal cord injury. *Spinal Cord* 36(8):554-560
14. Coulier B, Devyver B, Ghosez JP (2003) Severe underestimation of lumbar spinal stenosis by supine imaging. *Clin Radiol* 58(2):167-169
15. Curt A, Dietz V (1997) Ambulatory capacity in spinal cord injury: significance of somatosensory evoked potentials and ASIA protocol in predicting outcome. *Arch Phys Med Rehabil* 78:39-43
16. Deen HG Jr, Zimmerman RS, Lyons MK (1995) Measurement of exercise tolerance on the treadmill in patients with symptomatic lumbar spinal stenosis: a useful indicator of functional status and surgical outcome. *J Neurosurg* Jul;83(1):27-30
17. Ditunno JF, Young W, Donovan WH (1994) The international standards booklet for neurological and functional classification of spinal cord injury. *Paraplegia* 32:70-80
18. Dyck PJ, Kratz KM, Lehman KA (1991) The Rochester Diabetic Neuropathy Study: Design, criteria for types of neuropathy, selection bias, and reproducibility of neuropathic tests. *Neurology* 41:799-807
19. Esper G, Nardin R, Benatar M (2005) Sural and radial responses in healthy adults: Diagnostic implications for polyneuropathy. *Muscle Nerve* 31:628-632
20. Fisher MA (2002) Electrophysiology of radiculopathies. *Clin Neurophysiol* 113(3):317-335
21. Florence JM, Pandya S, King WM (1992) Intrarater reliability of manual muscle test (Medical Research Council scale) grades in Duchenne's muscular dystrophy. *Phys Ther* 72(2):115-122; discussion 122-126
22. Fritz JM, Delitto A, Welch WC, Erhard RE (1998) Lumbar spinal stenosis: a review of current concepts in evaluation, management, and outcome measurements. *Arch Phys Med Rehabil* 79:700-708
23. Haig AJ, Tong HC, Yamakawa KS (2005) The sensitivity and specificity of electrodiagnostic testing for the clinical syndrome of lumbar spinal stenosis. *Spine* 30(23):2667-2676
24. Hausmann O, Min K, Böni Th (2003) SSEP analysis in surgery of idiopathic scoliosis: the influence of spine deformity and surgical approach. *Eur Spine J* 12:117-123
25. Iseli E, Cavigelli A, Dietz V, Curt A (1999) Prognosis and recovery in ischaemic and traumatic spinal cord injury: clinical and electrophysiological evaluation. *J Neurol Neurosurg Psychiatry* 67:567-571
26. Johnsson K, Rosén I, Udén A (1987) Neurophysiologic investigation of patients with spinal stenosis. *Spine* 12:483-487
27. Katz JN, Dalgas M, Stucki G, Lipson SG (1995) Degenerative lumbar spinal stenosis. Diagnostic value of the history and physical examination. *Arthritis Rheum* 38:1236-1241
28. Katz JN, Lipson SJ, Chang LC, Levine SA, Fossel AH, Liang MH (1996) Seven-to-10-year outcome of decompressive surgery for degenerative lumbar spinal stenosis. *Spine* 21:92-98
29. Kohara N, Kimura J, Kaji R, Goto Y, Ishii J, Takiguchi M, Nakai M (2000) F-wave latency serves as the most reproducible measure in nerve conduction studies of diabetic polyneuropathy: multicentre analysis in healthy subjects and patients with diabetic polyneuropathy. *Diabetologia*, Springer Verlag 43:915-921
30. Kondo M, Matsuda H, Kureya S (1989) Electrophysiological studies of intermittent claudication in lumbar stenosis. *Spine* 14(8):862-866
31. Lawrence T, Kurz Jiri Dvorak (1996) Clinical, radiologic, and electrodiagnostic: diagnosis of degenerative lumbar stenosis. *The lumbar spine*. W.B. Saunders. Philadelphia (PA) 731-737
32. Leinonen V, Maatta S, Taimela S (2002) Impaired lumbar movement perception in association with postural stability and motor- and somatosensory-evoked potentials in lumbar spinal stenosis. *Spine* 27(9):975-983
33. London SF, England JD (1991) Dynamic F waves in neurogenic claudication. *Muscle Nerve* 14(5):457-461
34. Manganotti P, Zanette G, Tinazzi M, Polo A (1995) Dynamic F wave from lower limbs: value and clinical application. *Electromyogr Clin Neurophysiol* 35(6):323-329
35. Mariconda M, Zanforlino G, Celestino GA, Brancalone S, Fava R, Milano C (2000) Factors influencing the outcome of degenerative lumbar spinal stenosis. *J Spinal Disord* 13(2):131-137
36. Marino RJ, Graves DE (2004) Metric properties of the ASIA motor score: subscales improve correlation with functional activities. *Arch Phys Med Rehabil* 85(11):1804-1810
37. Miura T, Sonoo M, Shimizu T (2003) Establishment of standard values for the latency, interval and amplitude parameters of tibial nerve somatosensory evoked potentials (SEPs). *Clin Neurophysiol* 114:1367-1378
38. Onel D, Sari H, Donmez C (1993) Lumbar spinal stenosis: clinical/radiologic therapeutic evaluation in 145 patients. *Spine* 18:291-298
39. Pastor P, Valls-Sole J (1998) Recruitment curve of the soleus H reflex in patients with neurogenic claudication. *Mustle Nerve* Aug;21(8):985-990
40. Porter RW (1996) Spinal stenosis and neurogenic claudication. *Spine* 21:2046-2052
41. Postacchini F (1996) Management of lumbar spinal stenosis. Instructional course lecture. *J Bone Joint Surg* 78-B:154-164
42. Restuccia D, Insola A, Valeriani M (2000) Somatosensory evoked potentials after multisegmental lower limb stimulation in focal lesions of the lumbosacral spinal cord. *J Neurol Neurosurg Psychiatry* 69:91-95
43. Rutz S, Dietz V, Curt A (2000) Diagnostic and prognostic value of compound motor action potential of lower limbs in acute paraplegic patients. *Spinal Cord* 38:203-210
44. Scott F, John D (1991) Dynamic F-waves in neurogenic claudication. *Muscle Nerve* 14:457-461
45. Speciale AC, Pietrobon R, Urban CW (2002) Observer variability in assessing lumbar spinal stenosis severity on magnetic resonance imaging and its relation to cross-sectional spinal canal area. *Spine* 27(10):1082-1086
46. Storm SA, Kraft GH (2004) The clinical use of dermatomal somatosensory evoked potentials in lumbosacral spinal stenosis. *Phys Med Rehabil Clin N Am* 15(1):107-115
47. Turner JA, Ersek M, Herron L, Deyo R (1992) Surgery for lumbar spinal stenosis. Attempted meta-analysis of the literature. *Spine* 17:1-8
48. Verbiest H (1954) A radicular syndrome from developmental narrowing of the lumbar vertebral canal. *J Bone Joint Surg* 36B:230-237
49. Vinik AI, Liuzzi FJ, Holland MT (1992) Diabetic neuropathies. *Diabetes Care* 15:1926-1975
50. Visser SL, Zonneveldt A, De Rijke W, Don JA, Martens EIF, Stam D (1983) Normal Hoffmann reflex latencies (H-M interval) in relation to age and body length. *Clin Neurol Neurosurg* 85-2:85-91

-
51. Vrancken A, Franssen H, Wokke J (2002) Chronic idiopathic axonal polyneuropathy and successful aging of the peripheral nervous system in elderly people. *Arch Neurol* 59:533–540
 52. Vucic S, Cairns KD, Black DR, Chong PS, Cros D (2004) Neurophysiologic findings in early acute inflammatory demyelination polyradiculoneuropathy. *Clin Neurophysiol* 115(10):2329–2335
 53. Weishaupt D, Zanetti M, Hodler J (1998) MR imaging of the lumbar spine: prevalence of intervertebral disk extrusion and sequestration, nerve root compression, end plate abnormalities and osteoarthritis of the facet joints in asymptomatic volunteers. *Radiology* 209(3):661–666
 54. Yamada T (2000) Neuroanatomic substrates of lower extremity somatosensory evoked potentials. *J Clin Neurophysiol* 17(3):269–279
 55. Yu YL, Jones SJ (1985) Somatosensory evoked potentials in cervical spondylosis. Correlation of median, ulnar and posterior tibial nerve responses with clinical and radiological findings. *Brain* 108:273–300