

D. T. Winkler
P. Strnad
M. L. Meier
S. Roten
P. Went
P. Lyrer
A. J. Steck

Myasthenia gravis, paraneoplastic pemphigus and thymoma, a rare triade

Received: 30 October 2006
Received in revised form: 26 February 2007
Accepted: 12 March 2007
Published online: 3 August 2007

Sirs: Among human neoplasms, thymomas are associated with highest frequency with paraneoplastic autoimmune diseases. Myasthenia gravis (MG) is present in 30 to 60% [1], depending on the subtype of thymoma. Paraneoplastic pemphigus (PPP) on the other hand is only rarely associated with

thymomas. The coincidence of MG and PPP is very rare. Both, MG [2] and PPP [3], are associated with the occurrence of various autoantibodies. Around 80% of myasthenia patients test positively for acetylcholine receptor antibodies [4] while in PPP desmoglein-3 antibody titers are characteristically elevated [5]. We here studied the course of autoantibody titers before and after thymectomy in a patient with thymoma, MG and PPP. Antibodies against acetylcholine receptors (AChR) and against desmoglein-1 and -3 showed a significant decrease after thymectomy in parallel to clinical improvement.

We report the case of a 53-year-old woman who was admitted to our hospital with fluctuating diplopia, ptosis on her right side and progressive fatigue for several weeks. She reported progressive dysphagia and weight loss of 15 kg within a 6 month period. Furthermore, aphthous oral lesions appeared five months prior to admission. Neurological examination revealed slight weakness of the cervical musculature, inconsistent diplopia and ptosis on the right

side. Clinical myasthenic symptoms and elevated anti-acetylcholine receptor antibodies (3.3 pmol/ml; norm < 0.2 pmol/ml) led to the diagnosis of myasthenia gravis with predominant involvement of oropharyngeal and ocular muscles. CT scans of the chest revealed a homogeneous 1.7 x 5.0 x 8.5 cm anterior mediastinal mass consistent with a thymic tumor. CT scans of the abdomen and the pelvis were normal. Multiple genital, oral and pharyngeal bullous and ulcerating eruptions were observed, partly covered with white creamy candida spots (Fig. 1A, inset). Histological findings included interface dermatitis, apoptotic keratinocytes and focal areas of suprabasal acantholysis and were consistent with the diagnosis of paraneoplastic pemphigus (Fig. 1A). In line with the clinical and histological findings, desmoglein-1 (anti-Dsg-1) antibodies were initially normal (2.7 U/l; norm < 14 U/l), while the desmoglein-3 (anti-Dsg-3) titer (13.69 U/l; norm < 7 U/l) reached twice the norm at admission (Fig. 2).

D. T. Winkler, MD, PhD · P. Strnad, MD ·
P. Lyrer, MD · A. J. Steck, MD
Dept. of Neurology
University Hospital Basel
Petersgraben 4
4031 Basel, Switzerland

P. Strnad, MD
Palo Alto Veterans Affairs Medical Center
Palo Alto, California 94304, USA

M. L. Meier, MD
Consultant Dermatologist
Hôpital du Jura, Delémont

S. Roten, MD
Immunosa SA
1001 Lausanne, Switzerland

P. Went, MD
Institute of Pathology
University Hospital Basel
Basel, Switzerland

D. T. Winkler (✉)
Dept. of Neurology
University Hospital Basel
Petersgraben 3
4031 Basel, Switzerland
Tel.: +41-61/265-2525
Fax: +41-61/265-4100
E-Mail: winklerd@uhbs.ch

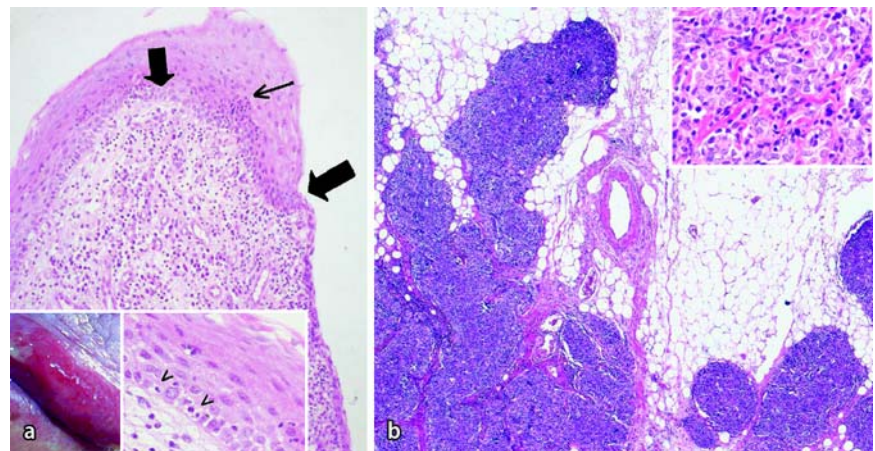


Fig. 1 **A** Paraneoplastic pemphigus with genital and oral blistering lesions (left inset). Histology of genital blistering lesions shows suprabasal acantholysis (bold arrows) and lichenoid tissue reaction (small arrow, magnification 10x). Apoptotic keratinocytes are present (right inset, arrowheads, 40x magnification). **B** Infiltration of the mediastinal fat by the thymoma indicates stage III according to Masaoka (magnification 10x). Inlet demonstrating large polygonal epithelial cells with few lymphocytes in an area of thymoma type B3 (magnification 40x)

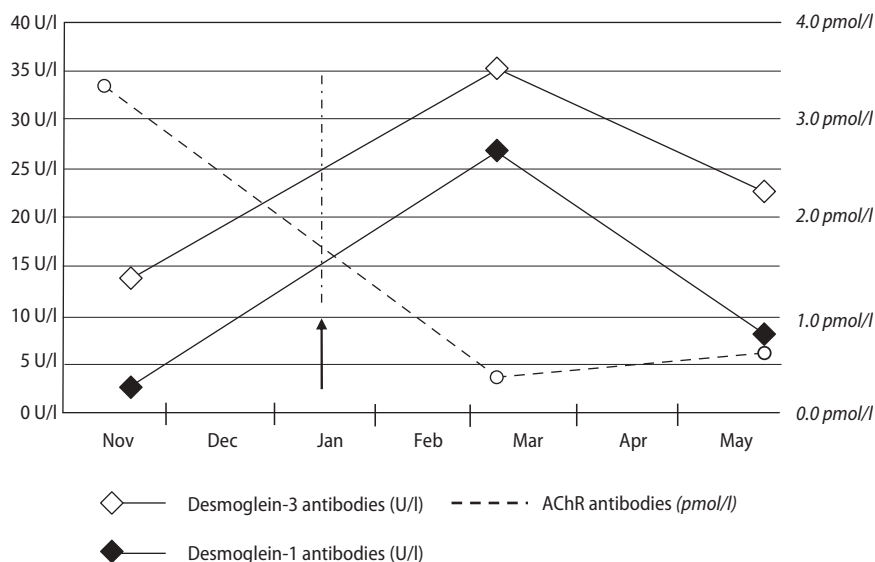


Fig. 2 Serum titers of antibodies against acetylcholine receptors, desmoglein-1 and -3, all of which declined four months after thymectomy. Interestingly, early postoperative levels of desmoglein-1 and -3 antibodies demonstrated a transient post-interventional increase (the vertical arrow indicates the date of surgery), whereas the acetylcholine receptor antibody titer was already lower

Treatment with pyridostigmine bromide, corticosteroids and azathioprine lead to an improvement of the myasthenic symptoms. After significant recovery from myasthenic symptoms, the patient underwent an elective transsternal thymectomy seven weeks after her first admission. Intraoperative findings showed an infiltration of mediastinal fat by the thymoma (Stage Masaoka III) and simultaneous resection of pericardium and the vena anonyma became necessary. Histology showed a combined thymoma of B2 and B3 type according to the WHO classification (Fig. 1B). The anterior mediastinum was postoperatively irradiated with a cumulative dose of 54 Gy.

Postoperatively, anti-Dsg-1 and -3 antibodies showed a transient increase. In contrast, AChR antibodies dropped to almost normal levels already seven weeks post-operation and the patient showed normal muscle strength under continued pyridostigmine and immunosuppressive therapy. Four months after thymectomy,

desmoglein antibodies also showed a significant decrease associated with a slow resolution of the mucous lesions.

Myasthenia gravis and pemphigus are both part of an interesting group of autoimmune diseases in which the passive transfer of antibodies can reproduce the disease manifestation [3, 6]. While MG is frequently associated with thymoma, PPP has only rarely been reported in thymoma patients [7–11]. We now report on a patient with the rare triade of thymoma, MG and PPP and describe for the first time the course of desmoglein antibodies before and after thymectomy. In parallel with the clinical recovery four months after thymectomy, all, AChR and anti-Dsg-1 and -3 antibodies showed an impressive decline (Fig. 2). The present case thus points out the parallel dynamics of two autoimmune mechanisms with a possible common denominator. In our case, the levels of pemphigus-associated antibodies had increased seven weeks after thymectomy while AChR antibodies already signifi-

cantly dropped. In parallel, clinical stabilization of myasthenic symptoms preceded the resolution of the mucous lesions. Furthermore, epitope spreading leading to transition from an initial, mucosal dominant type with only anti-Dsg3 antibodies, to an anti-Dsg1 (27.3 U/l) and anti-Dsg-3 (35.6 U/l) positive form had occurred. A similar beneficial effect of tumor ablation has recently also been reported in the case of Castleman's tumor, a rare lymphoproliferative disease that is sometimes associated with paraneoplastic pemphigus [12]. Our data provide further evidence for the important role of autoantibodies in the pathogenesis of myasthenia gravis and paraneoplastic skin diseases in thymoma patients and document the improvement of the associated diseases after radical treatment of the thymoma with concomitant immunosuppressive treatment. Further studies are necessary to analyze the pathomechanism underlying the different time course of the serological and clinical resolution of MG and PMP after thymectomy as presented in our case.

References

1. Chiu HC, Vincent A, Newsom-Davis J, Hsieh KH, Hung T (1987) Myasthenia gravis: population differences in disease expression and acetylcholine receptor antibody titers between Chinese and Caucasians. *Neurology* 37(12): 1854–1857
2. Vincent A, Palace J, Hilton-Jones D (2001) Myasthenia gravis. *Lancet* 357(9274):2122–2128
3. Anhalt GJ, Labib RS, Voorhees JJ, Beals TF, Diaz LA (1982) Induction of pemphigus in neonatal mice by passive transfer of IgG from patients with the disease. *N Engl J Med* 306(20): 1189–1196
4. Lindstrom JM, Seybold ME, Lennon VA, Whittingham S, Duane DD (1976) Antibody to acetylcholine receptor in myasthenia gravis. Prevalence, clinical correlates, and diagnostic value. *Neurology* 26(11):1054–1059

5. Amagai M, Nishikawa T, Nousari HC, Anhalt GJ, Hashimoto T (1998) Antibodies against desmoglein 3 (pemphigus vulgaris antigen) are present in sera from patients with paraneoplastic pemphigus and cause acantholysis in vivo in neonatal mice. *J Clin Invest* 102(4):775–782
6. Toyka KV, Drachman DB, Griffin DE, et al. (1977) Myasthenia gravis. Study of humoral immune mechanisms by passive transfer to mice. *N Engl J Med* 296(3):125–131
7. Patten SF, Dijkstra JW (1994) Associations of pemphigus and autoimmune disease with malignancy or thymoma. *Int J Dermatol* 33(12):836–842
8. Sherer Y, Shoenfeld Y (1999) A malignancy work-up in patients with cancer-associated (paraneoplastic) autoimmune diseases: pemphigus and myasthenic syndromes as cases in point (review). *Oncol Rep* 6(3):665–668
9. Leyn J, Degreef H (2001) Paraneoplastic pemphigus in a patient with a thymoma. *Dermatology* 202(2):151–154
10. Izumi Y, Kinoshita I, Kita Y, et al. (2002) Myasthenia gravis with diffuse alopecia areata and pemphigus foliaceus. *J Neurol* 249(10):1455–1456
11. Takeshita K, Amano M, Shimizu T, et al. (2000) Thymoma with pemphigus foliaceus. *Intern Med* 39(9):742–747
12. Wang L, Bu D, Yang Y, Chen X, Zhu X (2004) Castleman's tumours and production of autoantibody in paraneoplastic pemphigus. *Lancet* 363(9408):525–531