

MISCELLANEOUS

Cagatay Oysu · H. Baki Yilmaz · A. Asli Sahin
Mehmet Külekçi**Marble impaction in the nasopharynx following oral ingestion**

Received: 11 June 2003 / Accepted: 11 June 2003 / Published online: 10 July 2003

© Springer-Verlag 2003

Abstract Foreign body ingestion is an important emergency occurring in childhood. In this article, we report the case of a 5-year-old girl with marble impaction in the nasopharynx, which had not been discovered by routine X-rays of the chest and abdomen at the time of ingestion. The patient presented 4 months after the event with typical symptoms of adenoid hypertrophy and sinusitis, and the diagnosis was established on the basis of a plain film of the nasopharynx. This rare situation is potentially dangerous, since the foreign body may descend and cause sudden airway obstruction. Therefore, in all cases with vanishing foreign bodies in the aerodigestive system, nasopharyngeal impaction and its fatal consequences should be kept in mind and endoscopic examination of the region should be considered.

Keywords Marble · Nasopharynx · Foreign body · Impaction · Endoscopy

Introduction

Young children, especially under the age of 6 years, are naturally susceptible to ingesting foreign bodies, probably because of the lack of molar teeth and poor coordination of swallowing [5]. An age-related tendency to oral exploration and playing at the time of ingestion are among the causes of accidental foreign body ingestion in childhood [3]. Drooling, gagging, dysphonia and dysphagia are frequent symptoms, depending on the location and the nature of foreign body. Impaction of the foreign body in an unexpected anatomical location may cause atypical symptoms

and result in a delayed diagnosis. In this article, we report a pediatric case of foreign body ingestion with atypical presentation and location.

Case report

A 5-year-old girl with nasal obstruction and chronic cough was referred to our outpatient clinic by a pediatrician in order to be evaluated for adenoidectomy. Her parents reported that the girl had been examined in the emergency room for suspicion of marble ingestion 4 months previously. Posteroanterior and lateral chest and abdomen X-rays revealed nothing, and the child's nutritional habits had remained normal since then.

At presentation, periorbital edema and mouth breathing were noticed initially. Physical examination revealed no significant findings except thick retronasal and nasal drainage. Lateral plain X-ray showed a round radio-opaque foreign body in the nasopharynx (Fig. 1). During the examination under general anesthesia, a 16-mm

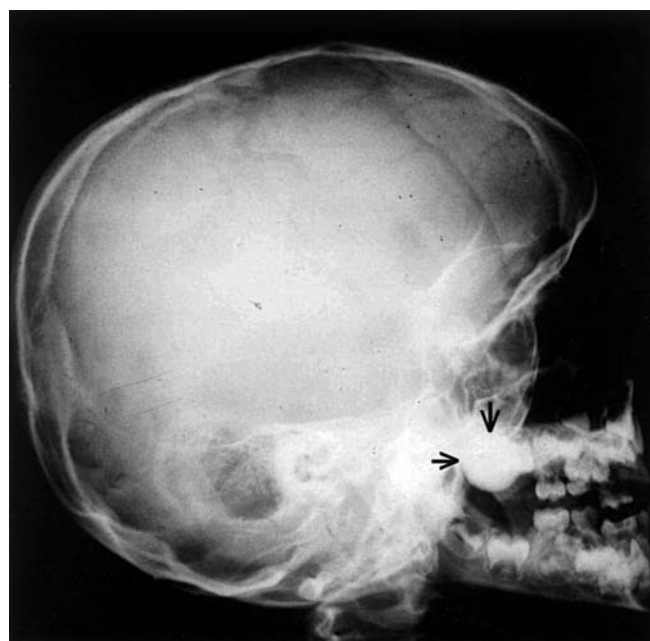


Fig. 1 Impacted marble (arrows) is seen in the lateral plain film of the nasopharynx

C. Oysu · H. B. Yilmaz · A. A. Sahin · M. Külekçi
Department of Otolaryngology, Taksim State Hospital,
Istanbul, Turkey

C. Oysu (✉)
Haci Hakki Bey sk. Basel ap. No. 4/7 Erenkoy,
34738 Istanbul, Turkey
Tel.: +90-216-4671109, Fax: +90-212-2445541,
e-mail: coysu@doruk.net.tr

marble was found to be stuck between the hypertrophic adenoid tissue and nasopharyngeal walls. Following the removal of the marble, adenoidectomy was performed. Follow-up was uneventful, and the patient was discharged on the following day.

Discussion

Foreign body ingestion is a universally important emergency occurring in childhood. According to the U.S. National Center for Health Statistics, foreign body ingestion and aspiration are one of the leading causes of accidental childhood death (personal communication). Children younger than 10 years of age constitute the vast majority of cases, and the peak is at the 2nd year of life [2]. Physical and functional immaturity of the masticatory and swallowing apparatus are plausible reasons for susceptibility [3]. Moreover, the tendency of children to oral exploration and their eating behavior while playing may be among the additional causes.

Coins and small pieces of toys are the most common esophageal foreign bodies [2, 5]. Foreign body impaction frequently occurs at anatomical narrowings of the esophagus, such as the upper esophageal sphincter and the level of the aortic arc [1, 5]. Congenital or acquired stricture locations are less common sites for impaction in childhood. The symptoms are determined by the level, nature and shape of the impacted foreign body. Vomiting, dysphagia, ptyalism and gagging are common symptoms for non-witnessed ingestion. The symptoms of witnessed or suspicious foreign body ingestions are milder because of the shorter period of time elapsed between the event and the presentation of the patient to a medical facility. In both situations, the diagnosis is usually made by chest and abdominal X-rays, or occasionally by endoscopy [5]. In asymptomatic cases with negative findings, the parental observation is usually accepted to be misleading.

In the present case, the patient had been considered to be normal at the initial examination 4 months previously, which is a typical example of a vanishing foreign body in the aerodigestive tract. To the best of our knowledge, this case is the fourth reported case of foreign body impaction in the nasopharynx, but the number of unreported cases

may be higher [4, 6]. The possible explanation for this impaction may be the upward movement of the marble by the gag reflex and its entrapment between the mildly hypertrophic adenoid tissue and nasopharyngeal walls.

As in our case, foreign bodies may remain asymptomatic in the nasopharynx for weeks or may mimic other common pediatric disorders such as adenoid hypertrophy and/or sinusitis. Although the outcomes of all reported cases were favorable, the situation is potentially dangerous. The foreign body lodged in the nasopharynx may descend, especially during playing or sleeping, and may cause sudden airway obstruction. Considering the frequency of esophageal foreign body impactions during childhood, one may assume that the rare nasopharyngeal impaction is insignificant. However, in all cases of foreign body ingestion, the possibility of nasopharyngeal impaction and its fatal consequences should be kept in mind. Routine X-ray of the nasopharynx will cause unnecessary radiation exposure, especially when ingestion of a radiolucent foreign body is suspected. However, in cases with a suspicious history of ingestion or vanishing foreign bodies, endoscopic examination of the nasopharynx is of paramount importance.

References

1. Crysdale WS, Sendi KS, Yoo J (1991) Esophageal foreign bodies in children. 15-year review of 484 cases. *Ann Otol Rhinol Laryngol* 100:320–324
2. Hsu W, Sheen Ts, Lin C, Tan C, Yeh T, Lee S (2000) Clinical experiences of removing foreign bodies in the airway and esophagus with a rigid endoscope: a series of 3,217 cases from 1970 to 1996. *Otolaryngol Head Neck Surg* 122:450–454
3. McGuirt WF, Holmes KD, Feehs R, Browne JD (1988) Tracheobronchial foreign bodies. *Laryngoscope* 98:615–618
4. Parker AJ, Bingham BJ, Osborne JE (1988) The swallowed foreign body: is it in the nasopharynx? *Postgrad Med J* 64:201–203
5. Stool SE, Manning SC (1990) Foreign bodies of the pharynx and esophagus. In: Bluestone CD, Stool SE (eds) *Pediatric otolaryngology*. 2nd edn. Philadelphia, W.B. Saunders, pp 1009–1019
6. Yadav SP, Goel HC, Chowdhary D, Jain L (1991) Marble in the nasopharynx. *Indian Pediatr* 28:183–184