

Infection (2013) 41:613–620
DOI 10.1007/s15010-012-0360-4

CLINICAL AND EPIDEMIOLOGICAL STUDY

Characteristics and outcome of 16 periprosthetic shoulder joint infections

Y. Achermann · F. Sahin · HK Schwyzer ·
C. Kolling · J. Wüst · M. Vogt

Received: 17 September 2012 / Accepted: 20 October 2012 / Published online: 3 November 2012
© Springer-Verlag Berlin Heidelberg 2012

Abstract

Purpose Shoulder arthroplasties are increasingly performed, but data on periprosthetic joint infections (PJI) in this anatomical position are limited. We retrospectively investigated the characteristics and outcome of shoulder PJI after primary arthroplasty from 1998 to 2010 in a single centre.

Methods Periprosthetic joint infection was defined as periprosthetic purulence, presence of sinus tract or microbial growth. A Kaplan–Meier survival method was used to estimate relapse-free survival of prosthesis.

Results From 1,571 primary shoulder prostheses, we evaluated 16 patients with a PJI at different stages, i.e. early ($n = 4$), delayed ($n = 6$) and late ($n = 6$) infections.

After completion of the study, Y. Achermann relocated to the research laboratory of Mark E. Shirtliff, University of Maryland, Baltimore, USA.

Y. Achermann
Division of Infectious Diseases and Hospital Epidemiology,
University Hospital Zurich, University of Zurich, Zurich,
Switzerland

Y. Achermann (✉)
Department of Microbial Pathogenesis, University
of Maryland-Baltimore, 650 W. Baltimore Street,
MD 21201 Baltimore, USA
e-mail: yvonne.achermann@gmail.com

F. Sahin · M. Vogt
Department of Internal Medicine, Infectious Diseases Service,
Cantonal Hospital Zug, Baar, Switzerland

H. Schwyzer · C. Kolling
Upper Extremity Department, Schulthess Clinic, Zurich,
Switzerland

J. Wüst
Microbiology Laboratory Unilabs, Zurich, Switzerland

The median patient age was 67 (range 53–86) years, and 69 % were females. The most commonly isolated microorganism was *Propionibacterium acnes* in 38 % of patients (monobacterial in four and polymicrobial in two patients). In 14 of the 16 patients, surgical interventions consisting of debridement and implant retention (6 patients), exchange (7) and explantation (1) were performed. Four patients had a relapse of infection with *P. acnes* ($n = 3$) or *Bacteroides fragilis* ($n = 1$). The relapse-free survival of the prosthesis was 75 % (95 % confidence interval 46–90 %) after 1 and 2 years, 100 % in six patients following the treatment algorithm for hip and knee PJI and 60 % in 10 patients not followed up. All but one of the relapses were previously treated without exchange of the prosthesis.

Conclusions As recommended for hip and knee PJI, we suggest treating shoulder PJI with a low-grade infection by microorganisms such as *P. acnes* with an exchange of the prosthesis. Cohort studies are needed to verify our results.

Keywords Shoulder arthroplasty · Prosthetic joint infection · Surgical management · Treatment outcome · *Propionibacterium acnes*

Introduction

Shoulder arthroplasties are becoming increasingly common, but data on shoulder periprosthetic joint infection (PJI) are still limited. The incidence of prosthetic shoulder infection varies from 0 to 1.9 % following primary implantation [1–4]. In previous studies an underlying trauma [2] or presence of a hematoma [5] were described as risk factors for shoulder PJI. The most commonly identified microorganisms in shoulder PJI are *Staphylococcus aureus*, coagulase-negative staphylococci (CNS)

and *Propionibacterium acnes* [2, 5]. Various surgical procedures for treating PJI have been described in the literature, including a two-stage exchange [1, 6, 7], a one-stage exchange [8], a resection arthroplasty [6, 7] or, as in cases of acute infection, debridement and retention of the prosthesis [1]. Antibiotic treatment or debridement alone does not eradicate the infection [1]. Zimmerli et al. [9] published an algorithm for hip and knee PJI in which they suggest the most successful surgical approaches in combination with adequately chosen antibiotic treatment [9, 10]. The algorithm was developed on the basis of in vitro studies and animal models of foreign body infections [9, 11–13] and a limited number of clinical studies [14]. To date, no information is available on the validity of this algorithm in shoulder PJI. We therefore retrospectively evaluated all patients from a 13-year cohort of primary shoulder arthroplasties at one orthopaedic centre in Switzerland.

Methods

Study population

The Schulthess Clinic is a specialised 160-bed orthopaedic centre with a high rate of surgical interventions (>8,600 documented in 2011). We retrospectively reviewed all 1,571 primary shoulder arthroplasties performed between 1998 and 2010 for PJI. Patients with a primary shoulder prosthesis implantation in an extern hospital presenting with a shoulder PJI at the Schulthess Clinic between 1998 and 2010 were also included in our study. Clinical information on shoulder PJI was retrieved from the prospectively managed database on all PJI from the Infectious Diseases Clinical Consulting Service. Patients with an incomplete documentation of PJI or follow-up were not evaluated further.

Definitions

Shoulder PJI was diagnosed if one or more of the following criteria were fulfilled: (1) visible purulence of a preoperative aspirate or intraoperative periprosthetic tissue (as determined by the surgeon), (2) presence of a sinus tract communicating with the prosthesis, (3) microbial growth in a preoperative joint aspirate, intraoperative periprosthetic tissue or sonication fluid of the removed implant or (4) synovial fluid with >1,700 leukocytes/ μ l or >65 % granulocytes, as determined in previous studies for knee PJI [15]. For pathogens that are slow growing and promote an indolent infection, such as CNS or Gram-positive anaerobes, the growth of the same organism in at least two independent specimens was required. Postoperative infections were classified into early (within 3 months after

surgery), delayed (3–24 months) and late (>24 months after surgery) infections based upon previous studies for knee and hip implant infections [9, 16–18].

Microbiological diagnosis

Aspirated fluid and intraoperative periprosthetic tissue specimens were cultured on blood agar plates, incubated aerobically with 5 % CO₂ and anaerobically at 35 °C for 7 days (until July 2006) or 10 days (after July 2006) [19]. In addition, thioglycollate broth was inoculated and cultured for 10 days. Isolated microorganisms were identified and their antimicrobial susceptibility tested using standard microbiological techniques [20]. After January 2007, explanted shoulder prostheses were sonicated to improve the detection of biofilm bacteria [21, 22].

Surgical treatment

The approach was individually determined at the surgeon's discretion. In the case of PJI, the type of revision was chosen among three potential approaches: (1) debridement and implant retention, (2) one-stage exchange or (3) two-stage exchange of the implant.

Comparison with the treatment algorithm for hip and knee PJI

We retrospectively determined whether the surgeon's decision was in agreement with the treatment algorithm for hip and knee PJI [9, 16]. According to this algorithm the least invasive surgical treatment should be used, while retention of the implant is allowed only if all of the following four conditions are fulfilled: (1) short duration of infection, including early postoperative infection (within 3 months after surgery) or acute hematogenous infection, (2) short duration of clinical signs (not longer than 21 days), (3) surrounding soft tissue is not severely damaged and (4) availability of antimicrobial agents active against biofilms (e.g. rifampin for staphylococci and quinolones for Gram-negative rods). If one or more of these conditions were not fulfilled, retention of the implant was considered inappropriate. In addition to surgical treatment, we retrospectively determined whether the antimicrobial therapy was in agreement with the recommended treatment duration in hip and knee PJI, namely, at least 3 months (maximum minus 15 days acceptable) for debridement and retention and 4–6 weeks for a two-stage exchange with a long interval [9, 16]. For the determination of an adequate antibiotic treatment we did not take into account the duration of the initial intravenous treatment and the choice of antibiotics.

Outcome evaluations

Follow-up in the orthopaedic outpatient clinic consisted of regularly scheduled visits at 6 weeks, 3 months, 6 months, 1 year and 2 years after surgery. Only patients with at least 1 year of follow-up were evaluated in this study. Follow-up examinations included clinical, radiological and laboratory assessments. We defined a relapse of infection if signs of a persistent infection (communicating sinus tract with the prosthesis) were present and/or the same pathogen either as monobacterial or polymicrobial infection was re-isolated. A new infection was defined as a shoulder PJI at the same anatomical site with isolation of a different microbial pathogen.

Statistical analysis

GraphPad Prism 6 software (GraphPad, San Diego, CA) was used for the statistical calculations and figures. The probability of relapse-free survival of shoulder prosthesis after 1 and 2 years and the 95 % confidence interval (95 % CI) were estimated using Kaplan–Meier curves and the log-rank test. Observations were censored at the time of diagnosis of relapse of PJI.

Results

Between 1998 and 2010, 1,571 primary shoulder prostheses were implanted, i.e. a median number of 128 per year (range 58–209). Nine (0.57 %) of the patients receiving the prostheses suffered from PJI. In addition, seven patients were referred for the treatment of their PJI. Characteristics of all 16 patients are summarised in Table 1.

Microbiology

A microbiological diagnosis was performed preoperatively and/or intraoperatively in 15 of 16 patients (94 %). In five of the eight patients who had the implant removed (63 %), cultures from the implant sonicate were performed in addition to normal tissue cultures.

The most commonly isolated microbial species was *P. acnes*, isolated as a monobacterial infection (4 cases, 25 %) and as polymicrobial infections (2 cases, 13 %). *Staphylococcus aureus* (methicillin susceptible) was found in two cases (13 %), and *Escherichia coli*, *Bacteroides fragilis*, *Peptostreptococcus magnus*, *Enterobacter aerogenes*, *Corynebacterium bovis* and *Streptococcus dysgalactiae* subsp. *equisimilis* were found in one case each (6 %). The one patient with negative intraoperative cultures at the time of implant removal, based on seven tissue biopsies and sonication fluid cultures being negative, was under antibiotic

Table 1 Characteristics of 16 episodes of shoulder periprosthetic joint infection after primary shoulder arthroplasty with outcome analysis

Characteristics	No. of episodes ^a
Median age (years)	67 (53–86)
Female	11 (69)
Type of prosthesis	
Anatomic	5 (31)
Inverse	11 (69)
Underlying joint disorder	
Osteoarthritis	8 (50)
Trauma	6 (38)
Rheumatoid arthritis	2 (13)
Manifestation of PJI after last surgery	
Early (<3 months)	4 (25)
Delayed (3–24 months)	6 (38)
Late (>24 months)	6 (38)
Surgical treatment	
Debridement with implant retention	6 (38)
One-stage exchange	0 (0)
Two-stage exchange	7 (41)
Explantation of prosthesis	1 (6)
No surgery (antibiotics only)	2 (13)

PJI periprosthetic joint infection

^a Data are presented as the number, with the percentage in parenthesis except for median age where the range is given in parenthesis. Percentages are rounded off and may not add up to 100 %

treatment with amoxicillin–clavulanate for 14 days (625 mg three times a day), thereby interfering with culture results since *P. acnes* was found in two of six tissue cultures at time of implantation of the new prosthesis. Susceptibility testing of *P. acnes* by the E-test was performed on the isolates from four of the six patients with positive *P. acnes* cultures [20]. All strains were susceptible to amoxicillin [minimal inhibitory concentration (MIC) 0.032–0.125 mg/l], clindamycin (MIC 0.032–0.064 mg/l), ceftriaxone (MIC 0.25 mg/l), rifampin (MIC 0.002–0.004 mg/l) and levofloxacin (MIC 0.5 mg/l).

Treatment

Surgical procedures are summarised in Tables 1 and 2. In seven patients with a two-stage prosthetic exchange, the median time from explantation to implantation of the new prosthesis was 3 (range 1.6–6.3) months. No surgical treatment was performed in two patients with early infections either due to surgical preference or patient denial of the revision. The median duration of the antibiotic treatment was 92 (range 0–544) days, of which for 13 (median; range 0–34) days the antibiotic was given intravenously. Of

Table 2 Clinical characteristics, treatment and outcome of 16 patients with shoulder PJI

Patient no.	Characteristics of initial PJI				Recommended procedure	Performed procedure	Duration of medication (days) ^a	Follow-up				
	Age (years), sex	Time to infection (months) ^a	Pathogenesis	Isolated pathogen				Cured, last follow-up (years)	Relapse, time to relapse (years)	Isolated micro-organism		
1	63, female	15.2	Delayed	<i>Staphylococcus epidermidis</i> (MR)	Exchange of prosthesis	Two stage exchange	28 (28, 0)	Teicoplanin i.v	Yes, 3.0	-	-	-
2	67, female	0.8	Early	<i>S. epidermidis</i> (MR)	Debridement and retention	No surgical treatment	84 (12, 72)	Vancomycin/rifampin i.v Sulfamethoxazole/tri-methoprim p.o	Yes, 3.7	-	-	-
3	73, female	11.4	Delayed	<i>Peptostreptococcus magnus</i>	Exchange of prosthesis	Explantation of prosthesis	43 (12, 31)	Amoxicillin-clavulanate i.v Amoxicillin-clavulanate p.o	Yes, 2.7	-	-	-
4	64, female	88.9	Hematogenous, followed by a chronic sinus tract	<i>Escherichia coli</i>	Exchange of prosthesis	Exchange of prosthesis	95 (34, 51)	Imipenem-Cilastatin i.v Ciprofloxacin p.o	Yes, 2.6	-	-	-
5	74, female	2.3	Early	<i>Propionibacterium acnes</i>	Debridement and retention	No surgical débridement	65 (0, 65)	Clindamycin p.o	Yes, 2.0	-	-	-
6	66, female	2.1	Early	<i>Enterobacter aerogenes</i>	Débridement and retention	Partial exchange	107 (13, 94)	Imipenem-cilastatin/gentamicin i.v Ciprofloxacin p.o	Yes, 3.2	-	-	-
7	86, male	32.2	Late, after trauma with seroma	<i>P. acnes</i>	Exchange of prosthesis	Débridement and retention	206 (18, 194)	Amoxicillin-clavulanate i.v/rifampin p.o Clindamycin/rifampin p.o	No	0.05	No diagnostic, persistent sinus tract	-
8	62, female	9.3	Delayed	<i>Corynebacterium bovis</i> [34]	Exchange of the prosthesis	Two-stage exchange	88 (14, 74)	Vancomycin i.v Clindamycin/rifampin p.o	Yes, 2.6	-	-	-
9	75, male	5.0	Delayed	<i>Bacteroides fragilis</i>	Exchange of prosthesis	Débridement and retention	544 (14, 530)	Imipenem-cilastatin i.v Amoxicillin-clavulanate p.o	No	0.23	Polymicrobial (<i>Bacteroides fragilis</i> , <i>Actinomyces meyeri</i>)	-
10	60, female	7.5	Delayed, >3 weeks symptoms	<i>Staphylococcus aureus</i>	Exchange of prosthesis	Two-stage exchange		Flucoxacin i.v/rifampin p.o Clindamycin/rifampin p.o	Yes, 8.7	-	-	-
11	66, male	148.7	Late, >4 weeks symptoms	<i>P. acnes</i> , <i>S. aureus</i>	Exchange of prosthesis	Débridement and retention	134 (6, 128)	Amoxicillin-clavulanate i.v Clindamycin p.o	Yes, 2.0	-	-	-

Table 2 continued

Patient no.	Characteristics of initial PJI					Follow-up				
	Age (years), sex	Time to infection (months) ^a	Pathogenesis	Isolated pathogen	Recommended procedure	Performed procedure	Duration of medication (days) ^a	Cured, last follow-up (years)	Relapse, time to relapse (years)	Isolated micro-organism
12	83, male	5.2	Delayed	<i>P. acnes</i>	Exchange of prosthesis	Débridement and retention	No AB	No	0.4	<i>P. acnes</i>
13	77, female	57.7	Late (not hematogenous)	<i>P. acnes</i>	Exchange of prosthesis	Partial exchange of implant	197 (7, 190) Amoxicillin-clavulanate i.v/rifampin p.o Clindamycin/rifampin p.o	Yes, 2.0	–	–
14	54, female	142.0	Late hematogenous followed by a chronic sinus tract	<i>Streptococcus dysgalactiae</i> subsp. <i>equisimilis</i>	Exchange of prosthesis	Two-stage exchange	86 (11, 65) Amoxicillin i.v and p.o	Yes, 4.0	–	–
15	75, female	1.7	Early, >3 weeks symptoms	Culture negative (under AB)	Exchange of prosthesis	Two-stage exchange	57 (0, 57) Amoxicillin-clavulanate p.o	No	0.2	<i>P. acnes</i>
16	53, male	34.6	Late (not hematogenous)	<i>P. acnes</i> , <i>S. aureus</i> , <i>S. epidermidis</i>	Exchange of prosthesis	Two-stage exchange	101 (28, 73) Imipenem-cilastatin i.v/rifampin p.o Clindamycin/rifampin p.o	Yes, 2.1	–	–

MR methicillin resistant, CMS coagulase-negative staphylococci, AB antibiotics

^a First number is the total duration of the antibiotic therapeutic regimen. The first number in parenthesis is the number of days of intravenous (i.v.) administration; the second number in parenthesis is the number of days of oral (p.o.) administration

the ten patients with isolated staphylococci or *P. acnes*, five received a combination treatment with rifampin.

Outcome evaluation

At last follow-up, 12 (75 %) patients were free of infection (median follow-up time 2.7 years, range 2–8.7 years). Four patients (25 %) had a relapse of infection (median 0.24 years, range 0.05–0.42 years), with an initial isolation of *P. acnes* in two patients and *Bacteroides fragilis* and negative cultures in one patient each. One patient died due to non-infectious cause. One patient from whom *Corynebacterium bovis* was isolated developed a new infection with *P. acnes* after 2.6 years ($n = 2$). The relapse-free survival rate of shoulder PJI was 75 % (95 % CI 46–90 %)

after 1 and 2 years (Fig. 1a). Table 2 summarises the outcome of all 16 patients with respect to time to infection, pathogenesis, isolated pathogen and the surgical procedure that was performed. Relapse of infection occurred in one of four cases of early infection (25 %), two of six cases of delayed infection (33 %) and one of six cases of late infection (17 %). Relapse of infection was also observed in three of six patients (50 %) with debridement and implant retention compared with two-stage exchange where one of seven (17 %) patients developed a relapse of infection.

If the recommended treatment algorithm for hip and knee PJI was followed ($n = 6$), the rate of relapse-free survival of the prosthesis was 100 %. By contrast, if the algorithm was not followed ($n = 10$), the relapse-free survival was 60 % after 1 and 2 years ($p < 0.09$) (Fig. 1b). In terms of only surgical treatment, the relapse-free survival of the prosthesis was 87.5 % if the surgical procedure was in line with the algorithm for hip and knee prosthesis and 62.5 % if not ($p < 0.25$).

Discussion

In our retrospective study we describe 16 patients with shoulder PJI after primary implantation. The most commonly isolated microorganism was *P. acnes*. The predominance of *P. acnes* in shoulder PJI is well known and might be related to the anatomic location of the axillary lymph glands [5, 9, 23–26]. *P. acnes* is an anaerobic Gram-positive rod that needs a long culture period of 10–14 days [19]. It is a major inhabitant of adult human skin, where it resides within sebaceous follicles. We found this pathogen in four cases as a monobacterial infection and in two cases as a polymicrobial infection. In addition, one patient presented with initial negative tissue cultures because of ongoing antibiotic treatment with amoxicillin–clavulanate but later demonstrated a positive culture for *P. acnes*. Therefore, we consider that *P. acnes* was predominant in seven of the 16 patients (44 %) analysed in our study. This level is remarkably different from what is commonly seen in cases of hip and knee PJI, where staphylococci, streptococci and Gram-negative bacteria are the major pathogens [16, 27].

Clinical trials and/or case reports provide little information on the optimal antibiotic treatment for *P. acnes* in PJI [23]. In our study, four of seven patients with *P. acnes* infection received a combination of rifampin and either amoxicillin or clindamycin. Recently published data from an animal cage model showed the relevance of antibiotic therapy with rifampin in combination with a potent second drug to avoid rifampin resistance, with the highest cure rate found with daptomycin and rifampin (63 %) [28]. Two other antibiotics known to have significant efficacy against *P. acnes*, amoxicillin and clindamycin, could not be tested

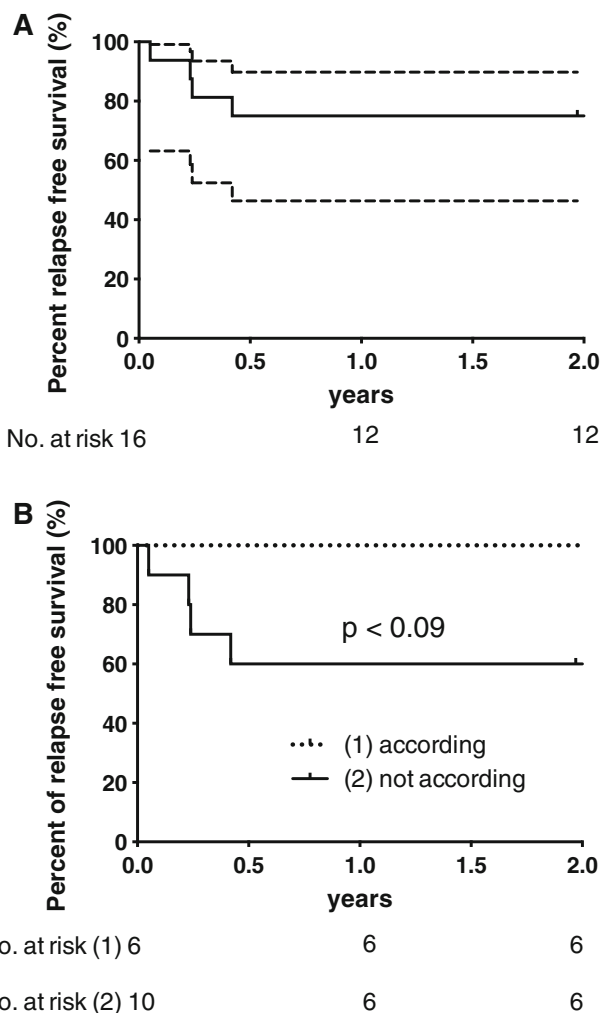


Fig. 1 **a** Percentage of relapse-free survival of 16 shoulder Periprosthetic joint infections (PJI) after primary arthroplasty. Dotted lines 95 % confidence interval (CI). The relapse-free survival was 75 % (95 % CI 46–90 %) after 1 and 2 years. **b** Percentage of relapse-free survival of 16 shoulder PJI stratified according to if treated accordingly ($n = 6$) or not ($n = 10$)

in the guinea pig model because the animals do not tolerate betalactams and clindamycin due to gastrointestinal toxicity. Further studies are needed to evaluate the optimal treatment in humans. In one patient of our study with relapse of *P. acnes* diagnosed at the time of implantation of the new prosthesis, treatment was provided with oral amoxicillin–clavulanate in the prosthesis-free interval, which supports the importance of initial intravenous antibiotic therapy, which is recommended in most guidelines [9, 29–31].

Despite the more invasive procedure, our results suggest that exchange of the prosthesis should be the treatment of choice in the majority of cases with shoulder PJI due to low-grade infection. In three of our four patients (75 %) with relapse of infection as evidence by the growth of *P. acnes* and *Bacteroides fragilis*, only debridement and retention without removal of the prosthesis was performed. Since *P. acnes* and *B. fragilis* cause indolent and asymptomatic infections for a prolonged period of time, a mature biofilm is often definitively established at the time of diagnosis of infection and exchange of foreign material is needed. This result is in line with results of a retrospective study by Sperling et al. [3], who reported a 50 % relapse of infection if the shoulder prosthesis was not exchanged [3, 7].

According to the Kaplan–Meier analysis, the treatment algorithm for hip and knee PJI can be adopted for a successful outcome of shoulder PJI. We showed for the first time in a small group of 16 shoulder PJI after primary arthroplasty that the relapse-free survival of the prosthesis is 100 % if treated according to the published algorithm for hip and knee PJI and 60 % after 2 years if not. The cure rate in other studies following the algorithm was 94.3 % after knee [17], 83 % [32] and 91 % [33] after hip and 100 % after elbow arthroplasty [22].

Although this is a retrospective study using a prospective database on PJI with a limited number of documented shoulder PJI after primary shoulder arthroplasty, our study is a systematic analysis of a large cohort in one single centre. To date, there has been no evidence to facilitate the choice of procedure in cases with shoulder PJI. Our findings will allow surgeons and physicians active in the field of infectious diseases to choose a more rational and possibly more successful approach in the treatment of shoulder PJI.

In summary, the predominant microorganism in shoulder PJI and relapse of infection among our patients was *P. acnes*. All but one of the relapses were previously treated without exchange of the prosthesis. If the recommended treatment algorithm for hip and knee PJI was followed, the rate of relapse-free survival of the prosthesis was 100 %. These data suggest that the treatment algorithm developed for hip and knee PJI can be applied to shoulder PJI. Further studies, particularly cohort studies, are needed to verify our results.

Acknowledgements This work was supported by the Hans-Paul Wälchli Foundation, Lugano, Switzerland. We thank Mark E. Shirtliff for his helpful comments and for improving the English language.

Conflict of interest Dr. H. K. Schwyzer received royalties from Smith and Nephew, Baar, Switzerland.

References

1. Coste JS, Reig S, Trojani C, Berg M, Walch G, Boileau P. The management of infection in arthroplasty of the shoulder. *J Bone Joint Surg Br.* 2004;86:65–9.
2. Singh JA, Sperling JW, Schleck C, Harmsen W, Cofield RH. Periprosthetic infections after shoulder hemiarthroplasty. *J Shoulder Elbow Surg.* 2011;21:1304–9.
3. Sperling JW, Kozak TK, Hanssen AD, Cofield RH. Infection after shoulder arthroplasty. *Clin Orthop Relat Res.* 2001;382:206–16.
4. Cuff DJ, Virani NA, Levy J, et al. The treatment of deep shoulder infection and glenohumeral instability with debridement, reverse shoulder arthroplasty and postoperative antibiotics. *J Bone Joint Surg Br.* 2008;90:336–42.
5. Cheung EV, Sperling JW, Cofield RH. Infection associated with hematoma formation after shoulder arthroplasty. *Clin Orthop Relat Res.* 2008;466:1363–7.
6. Romano CL, Borens O, Monti L, Meani E, Stuyck J. What treatment for periprosthetic shoulder infection? Results from a multicentre retrospective series. *Int Orthop.* 2012;36:1011–7.
7. Weber P, Utzschneider S, Sadoghi P, Andress HJ, Jansson V, Muller PE. Management of the infected shoulder prosthesis: a retrospective analysis and review of the literature. *Int Orthop.* 2011;35:365–73.
8. Ince A, Seemann K, Frommelt L, Katzer A, Loehr JF. One-stage exchange shoulder arthroplasty for peri-prosthetic infection. *J Bone Joint Surg Br.* 2005;87:814–8.
9. Zimmerli W, Trampuz A, Ochsner PE. Prosthetic-joint infections. *N Engl J Med.* 2004;351:1645–54.
10. Zimmerli W, Ochsner PE. Management of infection associated with prosthetic joints. *Infection.* 2003;31:99–108.
11. Schwank S, Rajacic Z, Zimmerli W, Blaser J. Impact of bacterial biofilm formation on in vitro and in vivo activities of antibiotics. *Antimicrob Agents Chemother.* 1998;42:895–8.
12. Widmer AF, Frei R, Rajacic Z, Zimmerli W. Correlation between in vivo and in vitro efficacy of antimicrobial agents against foreign body infections. *J Infect Dis.* 1990;162:96–102.
13. Zimmerli W, Frei R, Widmer AF, Rajacic Z. Microbiological tests to predict treatment outcome in experimental device-related infections due to *Staphylococcus aureus*. *J Antimicrob Chemother.* 1994;33:959–67.
14. Zimmerli W, Widmer AF, Blatter M, Frei R, Ochsner PE. Role of rifampin for treatment of orthopedic implant-related staphylococcal infections: a randomized controlled trial. *Foreign-Body Infection (FBI) Study Group. JAMA.* 1998;279:1537–41.
15. Trampuz A, Hanssen AD, Osmon DR, Mandrekar J, Steckelberg JM, Patel R. Synovial fluid leukocyte count and differential for the diagnosis of prosthetic knee infection. *Am J Med.* 2004;117:556–62.
16. Zimmerli W, Moser C. Pathogenesis and treatment concepts of orthopaedic biofilm infections. *FEMS Immunol Med Microbiol.* 2012;65:158–68.
17. Laffer RR, Graber P, Ochsner PE, Zimmerli W. Outcome of prosthetic knee-associated infection: evaluation of 40 consecutive episodes at a single centre. *Clin Microbiol Infect.* 2006;12:433–9.

18. Betsch BY, Eggl S, Siebenrock KA, Tauber MG, Muhlemann K. Treatment of joint prosthesis infection in accordance with current recommendations improves outcome. *Clin Infect Dis*. 2008;46:1221–6.
19. Schafer P, Fink B, Sandow D, Margull A, Berger I, Frommelt L. Prolonged bacterial culture to identify late periprosthetic joint infection: a promising strategy. *Clin Infect Dis*. 2008;47:1403–9.
20. Versalovic J, Carroll KC, Funke G, et al. (eds). *Manual of clinical microbiology*, 10th edn. Washington D.C., ASM press, 2011.
21. Trampuz A, Piper KE, Jacobson MJ, et al. Sonication of removed hip and knee prostheses for diagnosis of infection. *N Engl J Med*. 2007;357:654–63.
22. Achermann Y, Vogt M, Spormann C, et al. Characteristics and outcome of 27 elbow periprosthetic joint infections: results from a 14-year cohort study of 358 elbow prostheses. *Clin Microbiol Infect*. 2011;17:432–8.
23. Piper KE, Jacobson MJ, Cofield RH, et al. Microbiologic diagnosis of prosthetic shoulder infection using implant sonication. *J Clin Microbiol*. 2009;47:1878–84.
24. Kanafani ZA, Sexton DJ, Pien BC, Varkey J, Basmania C, Kaye KS. Postoperative joint infections due to *Propionibacterium* species: a case–control study. *Clin Infect Dis*. 2009;49:1083–5.
25. Topolski MS, Chin PY, Sperling JW, Cofield RH. Revision shoulder arthroplasty with positive intraoperative cultures: the value of preoperative studies and intraoperative histology. *J Shoulder Elbow Surg*. 2006;15:402–6.
26. Grosso MJ, Sabesan VJ, Ho JC, Ricchetti ET, Iannotti JP. Reinfection rates after 1-stage revision shoulder arthroplasty for patients with unexpected positive intraoperative cultures. *J Shoulder Elbow Surg*. 2012;21:754–8.
27. Marculescu CE, Berbari EF, Hanssen AD, et al. Outcome of prosthetic joint infections treated with debridement and retention of components. *Clin Infect Dis*. 2006;42:471–8.
28. Furustrand TU, Corvec S, Betrisey B, Zimmerli W, Trampuz A. Role of rifampin against *Propionibacterium acnes* biofilm in vitro and in an experimental foreign-body infection model. *Antimicrob Agents Chemother*. 2012;56:1885–91.
29. Esposito S, Leone S. Prosthetic joint infections: microbiology, diagnosis, management and prevention. *Int J Antimicrob Agents*. 2008;32:287–93.
30. Societe de Pathologie Infectieuse de Langue Francaise. Recommendations for bone and joint prosthetic device infections in clinical practice (prosthesis, implants, osteosynthesis). *Med Mal Infect*. 2010; 40:185–211.
31. Esposito S, Leone S, Bassetti M, et al. Italian guidelines for the diagnosis and infectious disease management of osteomyelitis and prosthetic joint infections in adults. *Infection*. 2009;37:478–96.
32. Giulieri SG, Graber P, Ochsner PE, Zimmerli W. Management of infection associated with total hip arthroplasty according to a treatment algorithm. *Infection*. 2004;32:222–8.
33. Tsukayama DT, Estrada R, Gustilo RB. Infection after total hip arthroplasty. A study of the treatment of one hundred and six infections. *J Bone Joint Surg Am*. 1996;78:512–23.
34. Achermann Y, Trampuz A, Moro F, Wust J, Vogt M. *Corynebacterium bovis* shoulder prosthetic joint infection: the first reported case. *Diagn Microbiol Infect Dis*. 2009;64:213–5.