

## Spontaneous spinal epidural haematoma during Factor Xa inhibitor treatment (Rivaroxaban)

M. Jaeger · B. Jeanneret · S. Schaeren

Received: 7 February 2011 / Revised: 8 August 2011 / Accepted: 18 August 2011 / Published online: 28 August 2011  
© Springer-Verlag 2011

**Abstract** We report on a 61-year-old female patient who developed a spontaneous spinal epidural haematoma (SSEH) after being treated by rivaroxaban, a new agent for the prevention of venous thromboembolic events in orthopaedic surgery. Although the pathogenesis of SSEH is unclear, anticoagulant therapy is a known risk factor. The patient sustained a sudden onset of severe back pain in the thoracic spine, followed by paraplegia below T8, 2 days after proximal tibial osteotomy and rivaroxaban therapy. Magnetic resonance imaging (MRI) of the whole spine demonstrated a ventral SSEH from C2 to T8. Whilst preparing for the emergency evacuation of the SSEH, the neurological symptoms recovered spontaneously 4 h after onset without surgery. After monitored bed rest for 48 h the MRI was repeated and the SSEH was no longer present. This rare condition of spinal cord compression and unusually rapid spontaneous recovery has not previously been reported following rivaroxaban therapy.

**Keywords** Rivaroxaban · Epidural haematoma · Compression · Spinal cord

### Introduction

Approximately 500 cases of spontaneous spinal epidural haematoma (SSEH) have been reported worldwide since Jackson first described it in *The Lancet* in 1869 [1].

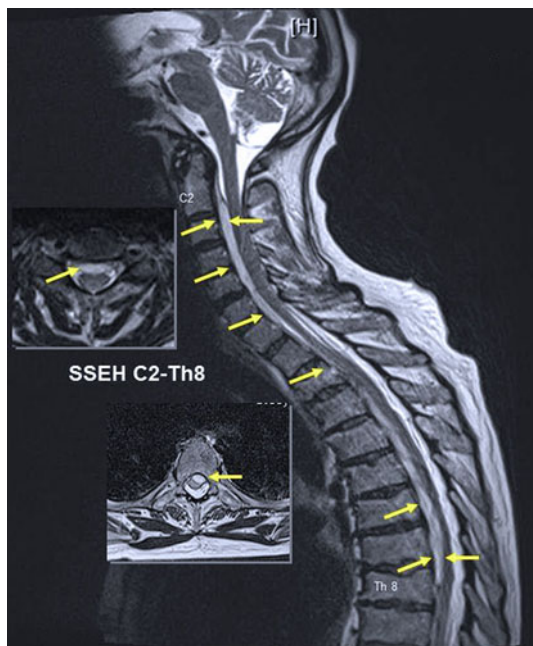
Although the aetiology remains unknown, multifactorial predisposing factors have been reported, especially associated with anti-coagulant use [2]. In this context, rivaroxaban (Xarelto<sup>®</sup>), a new orally administered direct Factor Xa inhibitor with superior efficacy and a similar safety profile to enoxaparin, is being prescribed with increasing frequency in elective orthopaedic surgery. Complications such as SSEH have not previously been reported [3], therefore here we describe the first case.

### Case report

After using the toilet, a 61-year-old healthy woman complained of severe pain in the thoracic spine 2 days after surgery of the lower limb (proximal tibial osteotomy) under general anaesthesia and prophylactic anticoagulant therapy starting 8 h after surgery (rivaroxaban 10 mg/day). 22 h after the last daily dose of rivaroxaban was administered, within minutes a progressive bilateral lower limb weakness and numbness occurred. 2 h later the neurologist diagnosed paraplegia of both legs (Medical Research Council grade 0) with a sensory level at T8 dermatome. Reflexes were depressed and rectal examination showed a decreased anal tone and perianal sensations. Magnetic resonance imaging (MRI) was immediately performed and showed a ventral localised SSEH extending from C2 to T8 (Fig. 1) without abnormal signal changes in the spinal cord. Arteriovenous malformation, tumour or fracture were not found. Routine blood investigations revealed an international normalised ratio of 1.0 and all other parameters were within normal range as before surgery.

With the exception of ibuprofen and tramadol for analgesia, no further medication was prescribed following surgery and rivaroxaban therapy.

M. Jaeger (✉) · B. Jeanneret · S. Schaeren  
Department of Orthopedic Surgery,  
University Hospital of University Basel,  
Spitalstrasse 21, 4031 Basel, Switzerland  
e-mail: jaegerm@uhbs.ch

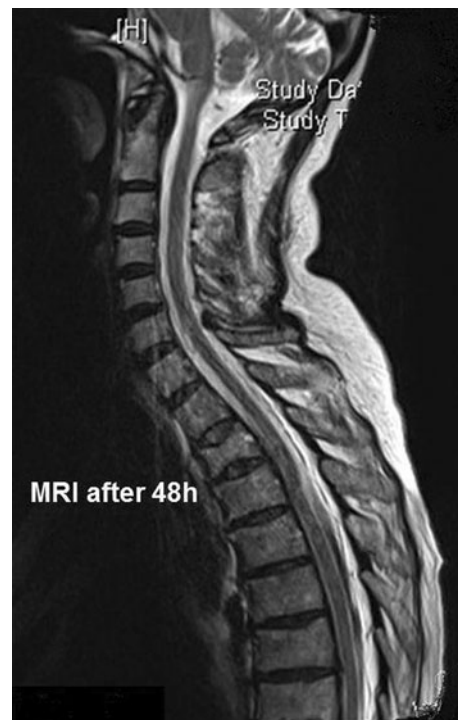

**Fig. 1** The immediately performed MRI showed anterior compressing epidural hematoma C2–Th8 without abnormal signal changes in the spinal cord (T2 weighted TSE-sequence)

The spinal surgeon repeated the clinical investigation 4 h after onset of paraplegia, found a recovered sensory and motor function with a mild hyperreflexia of both legs, and decided against decompressive surgery. The anticoagulant therapy (rivaroxaban) was stopped and neurologically monitored bed rest for 48 h, followed by a repeat MRI scan, were prescribed. The second MRI scan revealed that the SSEH was no longer present (Fig. 2), while the neurological symptoms were normalised. We resumed anticoagulant therapy (dalteparinum 2500 IE/day) and discharged the patient after 5 days.

## Discussion

SSEH is a rare disease, unrelated to trauma such as lumbar puncture. It occurs most frequently after the fourth or fifth decade [5] but it has been reported in all age groups. It accounts for 0.3–0.9% of epidural space occupying lesions [3], while anticoagulant therapy accounts for up to 17% of cases [5]. The male:female ratio of occurrence is 1.4:1 [6]. The most common location of SSEH is the cervicothoracic and thoracolumbal junction. The majority are located posteriorly or posteriolaterally, where extensive networks of venous convolute, namely the posterior internal vertebral venous plexus (IVVP) are found [7]. The anterior haematoma in our case is rare in SSEH. Several risk factors including anticoagulant, platelet-aggregation-inhibitor therapy, coronary thrombolysis, factor XI deficiency,



**Fig. 2** MRI after 48 h revealed no epidural hematoma and no compression of the spinal cord

haemophilia B, leukaemia and vascular malformation [4, 8] have been proposed. Most researchers assert that the lack of venous valves in epidural veins and the undulating thoracic and abdominal pressure causes an acute increase in venous pressure and bleeding. Some authors have advocated that small disrupted epidural arteries can cause SSEH [9]. In the current case the major cause may have been the undulating abdominal pressure (occurring when the patient was using the toilet) combined with anticoagulant therapy using a Factor Xa inhibitor and antiplatelet effect due to ibuprofen. Urgent decompression was indicated because the best outcomes can be expected when surgery is performed within 24 h or, ideally, within 12 h [10]. Only a small number of cases have been reported where complete recovery was achieved by conservative treatment [11, 12], although there remains the possibility for SSEH to resolve spontaneously. The cause of spontaneous resolution of SSEH has frequently been discussed in literature. Some authors have suggested leakage through the intervertebral foramen as a possible mechanism [13], others proposed a spreading of the haematoma within the spinal canal until blood clotting has been completed [14]. Thus, although anticoagulants such as Factor Xa inhibitor might promote formation of a larger hematoma, they might also facilitate spreading. As a result, a spontaneous decompression of the spinal neural structures might occur leading to a full remission of neurological deficit.

In our case, the patient would have been treated surgically if the symptoms had not improved significantly within the intervening 4 h. Prior to the present case, SSEH has not been reported during rivaroxaban therapy and therefore, the authors propose no additional precautions other than low molecular weight heparin [15]. The combinations of an antiplatelet effect due to ibuprofen might have contributed to the hypo-coagulated state.

## Conclusion

With the increasing use of new anticoagulant agents in orthopaedic surgery which facilitates prophylactic anticoagulation therapy, physicians should be alert to this rare but serious complication as well as the methods for diagnosing and urgent treatment. They should be aware of the possibility of an unusual spontaneous rapid neurological recovery but they cannot exclude the possibility that neurological deficits will not improve without surgery, in which case decompressive surgery is indicated.

**Acknowledgments** We thank Prof. Dimitrios Tsakiris and Dr. Annis Mechan for critical reading of this manuscript.

**Conflict of interest** None of the authors has any potential conflict of interest.

## References

- Jackson R (1869) Case of spinal apoplexy. *Lancet* 2:538–539
- Lonjon MM, Paquis P, Chanalet S, Grellier P (1997) Non-traumatic spinal epidural hematoma: report of four cases and review of the literature. *Neurosurgery* 41:483–487
- Shin JJ, Kuh SU, Cho YE (2006) Surgical management of spontaneous spinal epidural haematoma. *Eur Spine J* 15:998–1004
- Guzel A, Simsek O, Karasalioglu S, Kucukugurluoglu Y, Acunas B, Tosun A et al (2007) Spontaneous spinal epidural haematoma after seizure: a case report. *Clin Pediatr* 46:263–265
- Oh JYL, Lingaray K, Rahmat R (2008) Spontaneous spinal epidural haematoma associated with aspirin intake. *Singapore Med J* 49(12):e353
- Liu Z, Jiao Q, Yu J, Wang X, Li S, You C (2008) Spontaneous spinal epidural haematoma: analysis of 23 cases. *Surg Neurol* 69:253–260
- Groen RJ, Ponssen H (1991) Vascular anatomy of the spinal epidural space: considerations on the etiology of the spontaneous spinal epidural hematoma. *Clin Anat* 4:413–420
- Holtas S, Heiling M, Lonntoft M (1996) Spontaneous spinal epidural haematoma: findings at MR imaging and clinical correlation. *Radiology* 199:409–413
- Beatty RM, Winston KR (1984) Spontaneous cervical epidural hematoma. A consideration of etiology. *J Neurosurg* 61:143–148
- Serizawa Y, Ohshiro K, Tanaka K, Tamaki S, Matsuura K, Uchiyama T (1995) Spontaneous resolution of an acute spontaneous spinal epidural hematoma without neurological deficits. *Intern Med* 34:992–994
- Lovblad KO, Baumgartner RW, Zambaz BD, Remonda L, Ozdoba C, Schroth G (1997) Nontraumatic spinal epidural hematomas MR Features. *Acta Radiol* 38:8–13
- Markham JW, Lyng H, Stahlman GE (1967) The syndrome of spontaneous spinal epidural hematoma. Report of three cases. *J Neurosurg* 26:334–342
- Inamasu J, Hori S, Aoki K, Maruiwa H, Toyama Y (2000) Spontaneous spinal epidural hematoma. *Am J Emerg Med* 18(7):837–839
- Groen RJM (2004) Non-operative treatment of spontaneous spinal epidural hematomas: a review of the literature and a comparison with operative cases. *Acta Neurochir* 146:103–110
- Rosencher N, Arnaout L, Chabbouh T, Bellamy L (2008) Rivaroxaban (Xarelto®): efficacy and safety. *Annales Françaises d'Anesthésie et de Réanimation*; 27:22–27