

Clemens Reisinger  
Thomas Gluecker  
Augustinus Ludwig Jacob  
Georg Bongartz  
Deniz Bilecen

## Dynamic magnetic resonance angiography of the arteries of the hand. A comparison between an extracellular and an intravascular contrast agent

Received: 12 April 2008  
Revised: 10 June 2008  
Accepted: 3 July 2008  
Published online: 3 September 2008  
© European Society of Radiology 2008

C. Reisinger (✉) · T. Gluecker ·  
A. L. Jacob · G. Bongartz · D. Bilecen  
Department of Radiology,  
University Hospital Basel,  
Petersgraben 4,  
4031 Basel, Switzerland  
e-mail: reisingerc@uhbs.ch  
Tel.: +41-613-286324  
Fax: +41-612-654354

**Abstract** The purpose of this study was to compare the image quality of the intravascular contrast agent gadofosveset with the extracellular contrast agent gadoterate meglumine in time-resolved three-dimensional magnetic resonance (MR) angiography of the human arteries of the hand. The value of cuff compression technique for suppression of venous enhancement for both contrast agents was also investigated. Three-dimensional MR angiograms of both hands of 11 healthy volunteers were acquired for each contrast agent at 1.5-T, while subsystolic cuff compression was applied at one side. Quantitative and qualitative evaluation were performed and analyzed with Student's *t*-test. Visualization of vessels was superior in the images acquired with gadofosveset, especially in the late

phases. Quantitative and qualitative evaluation showed significantly higher values for gadofosveset. The cuff compression at the lower arm proved to be an effective method to enhance arterial vessels. In conclusion the blood pool agent gadofosveset is superior for the dynamic imaging of the vessels of the hand when compared with the extracellular contrast agent gadoterate meglumine. To fully utilize the advantages of intravascular contrast agents, venous overlay has to be delayed or reduced, which can be achieved effectively by subsystolic lower arm cuff compression.

**Keywords** Magnetic resonance angiography · Blood pool contrast agents · Peripheral vascular imaging · Cuff compression technique

### Introduction/Objective

Digital subtraction angiography (DSA) is still considered to be the “gold standard” for angiography of the arteries of the human hand. Although invasive, it has not yet been surpassed by magnetic resonance angiography (MRA). This is due to the still superior contrast-to-noise ratio (CNR) level and spatial resolution when compared with MRA, especially in the most peripheral segments of the vascular tree where the vessels are small. But MRA is about to catch up and has some advantages over DSA as well. It is minimally invasive, has no ionizing radiation exposure, can create a three-dimensional (3D) data set and may be combined with soft-tissue imaging for further diagnostic workup.

Furthermore, developments in MR imaging technique and hardware lead to a continuous improvement of temporal and spatial resolution as well as CNR. Recently, additionally to the established gadolinium (Gd)-based extracellular contrast agents for general MR imaging, intravascular contrast agents (or blood pool agents) have been introduced clinically as specific contrast agents for vascular MR exams. At present, only one of these agents is clinically available, which is gadofosveset (Vasovist, Bayer Schering Pharma, Germany). This molecule is reversibly attached to albumin in the blood and therefore remains intravascular for hours. Also, its relaxivity, meaning its ability to lower the T1- and T2-time of the adjacent tissue protons and thereby increasing its signal in T1-weighted sequences, is higher compared with other Gd-based contrast agents.

Contrast-enhanced MRA has been shown to be a robust and reproducible method to visualize the vessels of the hand, providing images of diagnostic quality [1]. However, the low spatial and temporal resolution with a low CNR and the impairment of arterial depiction by early venous enhancement remain as major problems [2].

With the introduction of the subsystolic venous cuff compression technique, a significant reduction of venous overlay was achievable and allowed arterial imaging before venous enhancement [3]. It also could be shown that a lower flow rate further lowers venous overlay [4]. But to increase the CNR, especially in the most peripheral arterial territory, elevation of the Gd concentration and/or relaxivity up to a certain degree is necessary. Until now, only extracellular contrast agents have been used for the imaging of the hand vessels. Now, with intravascular contrast agents, the restriction of diffusion of gadofosveset molecules into the interstitial space should lead to higher peripheral vascular Gd concentrations. This should even be amplified by the higher relaxivity of the molecule caused by the binding to the albumin. A drawback may be increased venous enhancement that might hamper the arterial read out. Therefore, we hypothesized that the application of intravascular contrast agent will increase CNR values along the complete vascular tree of the hand and thereby may improve the arterial depiction in comparison with extracellular contrast agents.

To our knowledge, no study has yet been published that compares the visualization of the vessels of the hand with extracellular and intravascular contrast agents. The purpose of our study was to assess the use of intravascular contrast agents in combination with subsystolic cuff compression.

## Materials and methods

Both hands of 11 non-smoking healthy volunteers (seven male; four female; mean age 27 years, age range 19–45 years) were examined twice in an interval of 7 days with a dynamic sequence. For a single examination eight 3D data sets with an acquisition time of 24 s each were obtained consecutively, with the second set starting simultaneously with contrast agent injection. The measurement before the administration of the contrast agent served as a mask for subtraction. This resulted in seven phases (or series) of post-contrast angiographies. In one case, the number of averages was increased by two to achieve an increased signal of the distal vessels, resulting an acquisition time per frame of 48 s. These angiograms were not included in the statistical evaluation.

### Image acquisition

For the examination, we used a 1.5-T whole-body MR system (Espreo, Siemens Medical Solutions, Erlangen, Germany) with a time-resolved 3D gradient-echo sequence

and following imaging parameters: 3D gradient-echo sequences with field of view 336×252 mm; matrix size 384×271 pixels; voxel size 0.9×0.9×0.9 mm; TR/TE 4.32/1.32; flip angle 40; acquisition time per slab 24 s; 60 partitions per slab; partition thickness 0.9 mm; bandwidth 430 Hz/pixel; time of k-space center 7.9 s; zero filling; parallel imaging mode iPAT GRAPPA; acceleration factor 2. The integrated spine coil and a flexible body coil were used for signal detection. Venous compression was applied at one side by inflating a standard blood pressure cuff at mid portion of the lower arm approximately 1 min before contrast-agent injection with a subsystolic pressure of 80 mmHg. The pressure was manually maintained during the whole arterial image acquisition. The systemic blood pressure was measured before imaging. The unilateral application of compression permitted an intraindividual comparison of venous overlay between the compressed and non-compressed side. This method was similar to a previously established method [3] with the exception that this time cuff compression was at the lower arm, for this location is easier to access in the prone position.

### Contrast agent administration

Contrast agent was applied with an injection rate of 2 ml/s and a standard concentration of 0.1 mmol Gd/kg body weight for gadoterate meglumine (Gd-DOTA, Dotarem, Guerbet, Aulney-sous-Bois, France) and of 0.03 mmol Gd/kg body weight for gadofosveset (Vasovist, Bayer Schering Pharma, Berlin, Germany), followed by a flush of 20 ml of normal saline (0.9%). The  $r_1$  relaxivity of the used contrast agents at 1.5 T and 37°C in blood are 4.2 mmol<sup>-1</sup>s<sup>-1</sup> for gadoterate meglumine and 19 mmol<sup>-1</sup>s<sup>-1</sup> for gadofosveset [5]. Injection was delivered into an antecubital vein of the non-compressed arm. A power injector (Spectris, Medrad, Pittsburgh, Pa.) was used for administration. All volunteers were examined in the prone position with both hands in pronation above the head. The thumbs were separated by soft cushions and slightly fixed to avoid induction currents and motion artifacts.

For every volunteer, written informed consent was obtained and the creatinine values were measured for calculation of the clearance rate at least 24 h before the first study. For estimation of the renal clearance, the Cockcroft/Gault-formula was used. A cut-off value of 60 ml/min was chosen. Further exclusion criteria were metal implants or foreign bodies, age below 18 or above 75 and claustrophobia. Volunteers were questioned after each study regarding adverse effects and discomfort during the study.

### Data evaluation

Quantitative evaluation of CNR as well as qualitative assessment of arterial visualization and venous overlay

were performed. For quantitative assessment of CNR polygonal regions of interest (ROIs) were defined in the source images in six different vascular regions as well as in the adjacent soft tissue and outside the body. The following arterial locations were measured: the distal radial artery, the distal ulnar artery, the superficial palmar arterial arch, the princeps polices artery, one common digital artery (usually MC2/3) and at least one proper digital artery (Fig. 1a). Noise was defined as the standard deviation (SD) of signal intensity (SI) of a constant area outside the body.

The CNR was calculated as  $CNR = (SI_{vessel} - SI_{adjacent\ soft\ tissue}) / noise$ . The mean CNR measured over all the vessel segments was calculated and compared between the different phases and contrast agents.

For qualitative evaluation, maximum intensity projections (MIPs) were reconstructed in the coronal plane prior to evaluation. The vessels were divided into a proximal, an intermediate and a distal segment, being separated by the palmar arch and the bifurcation into the proper digital arteries (Fig. 1b). These were evaluated independently for both hands and different phases. Qualitative data evaluation was performed by three experienced radiologists (A.L. J., T.G., D.B.), with at least 5 years' experience in vascular imaging. Each reviewer was unaware of the contrast agent used and the other reviewer's assessment. The different series were presented separately as MIP images and in a randomized order. The source images were available when needed. The arterial visualization score was rated on a four-point scale: 0=nondiagnostic study or no arterial filling; 1=poor data quality, diagnostic impairment; 2=suboptimal arterial signal, no diagnostic impairment; 3=good arterial signal. The venous overlay was rated on a

four-point scale: 0=no venous contamination; 1=minimal venous contamination, no reduction of diagnostic value; 2=major venous contamination, important diagnostic impairment; 3=nondiagnostic study. Statistical analysis was performed using a paired Student's *t*-test for both qualitative and quantitative data. A calculated *p* value of less than 0.05 was considered statistically significant. The study protocol was approved by the local ethics committee.

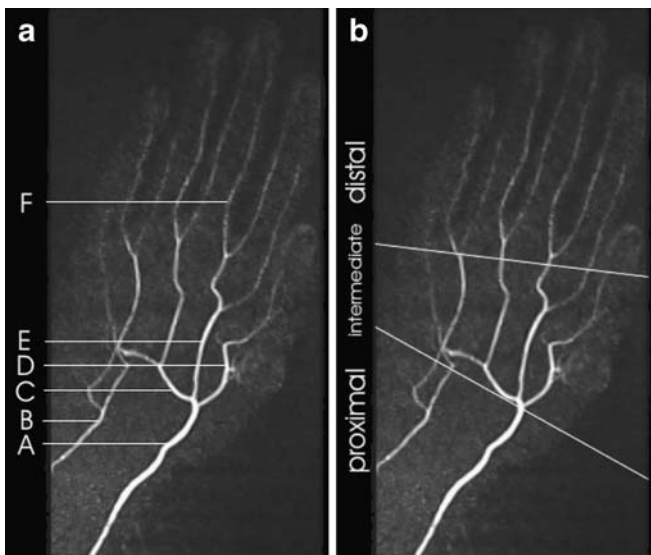
## Results

All examinations have been successfully completed, resulting in 22 angiograms of both hands. There were no complications that led to interruption or termination of the study. The volunteers stated some discomfort because of the inflated cuff and lying in a prone position but none complained about pain or paresthesia. No complications or adverse side effects related to the contrast material were observed.

To illustrate the intraindividual difference in arterial enhancement between both contrast agents, the two series of MIP reconstructed contrast-enhanced MR angiograms of the hand on the compressed side over time are displayed in Fig. 2, the first row being acquired with gadoterate meglumine and the second with gadofosveset. Both contrast agents led to sufficient enhancement of the proximal arteries starting approximately 72 s after injection. Filling of the distal arteries is completed after 120 s. During this time the arterial signal in the gadoterate meglumine series already decreases and the noise is increasing probably due to distribution in the extravascular, extracellular space. Therefore, in particular the digital arteries are displayed insufficiently. In the series acquired with gadofosveset, the arterial depiction remains constant over time and is only hampered by slight venous overlay distally, starting about 144 s after contrast agent injection.

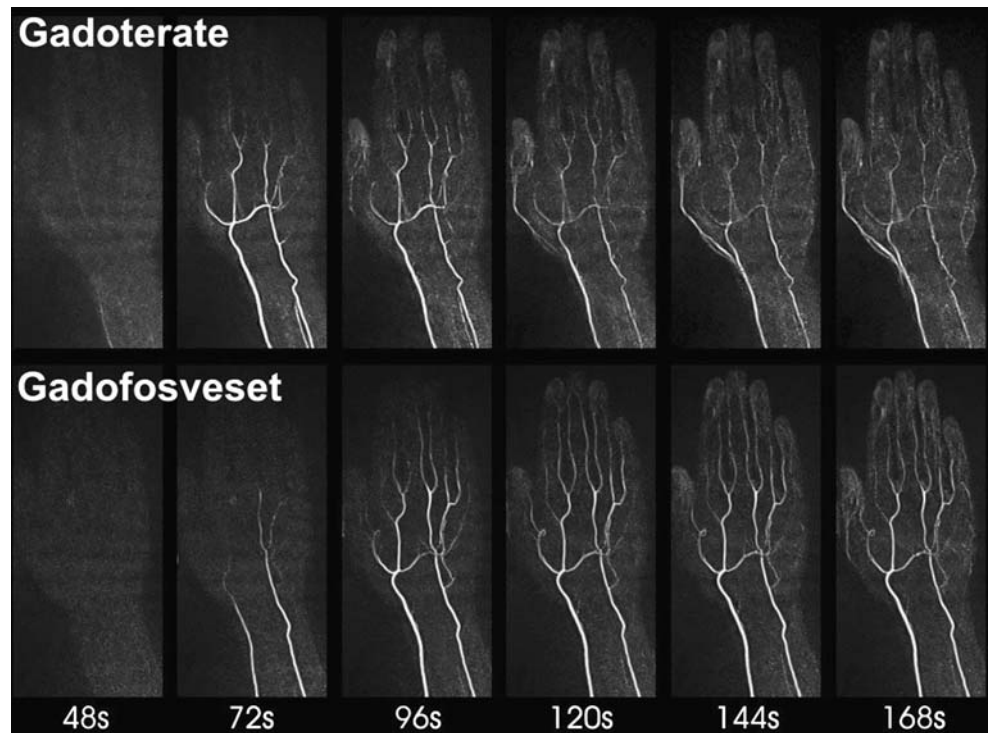
### Quantitative evaluation of arterial signal in the different segments

The mean CNR values for all arterial vessel segments over time are displayed in Fig. 3. Here, with both contrast agents the CNR starts to increase similarly at about 48 s after contrast-agent injection without cuff compression and about 72 s after injection with cuff compression applied. With gadoterate meglumine there is an early signal decrease in both extremities, whereas gadofosveset shows a late plateau phase with higher signal intensity. This difference in CNR proved to be statistically significant ( $p=0.0001$  and  $0.0028$ ). On average, the highest measured CNR value per series was 42.0 for gadofosveset and 33.7 for gadoterate meglumine, respectively.



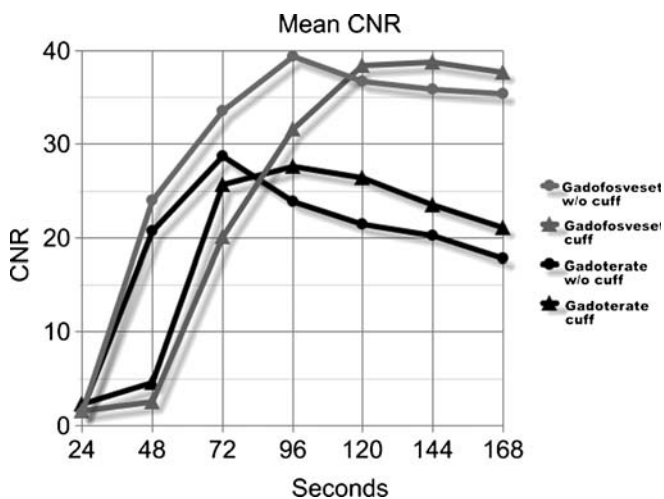
**Fig. 1** Arterial vessel segments measured for the estimation of CNR (A–F) and segmentation for the rating of arterial visualization and venous overlay (proximal, intermediate, distal)

**Fig. 2** Maximum intensity projections of the hand of a single volunteer with cuff compression applied. The *upper row* shows the enhancement of the vascular tree over time when gadoterate meglumine was injected. The *lower row* shows the corresponding angiograms with gadofosveset as contrast agent. While with both contrast agents early enhancement was similar with nice depiction of the proximal arteries, the late images obtained with gadoterate meglumine show increasing noise, probably due to distribution in the extravascular, extracellular space. Therefore, especially the peripheral arteries are displayed insufficiently when compared with the series acquired with gadofosveset



#### Qualitative evaluation of arterial visualization

The assessments of arterial visualization are displayed separately for the different segments in Fig. 4a–c, from proximal to distal artery segments. Without compression,

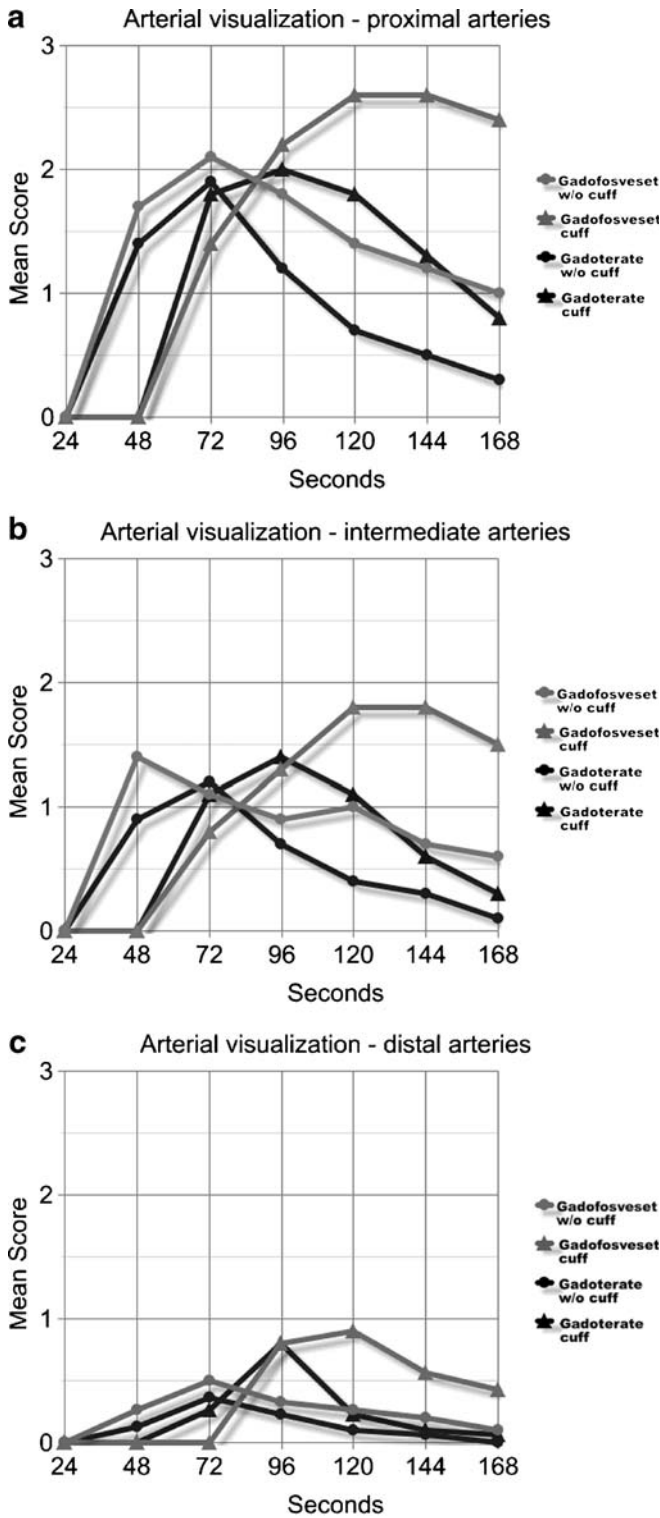


**Fig. 3** Mean CNR of all arterial segments separately for contrast agent and compression technique. Both contrast agents show similar vascular enhancement in early acquisitions, while during the later phases the mean CNR was significantly higher with gadofosveset (*gray*) than with gadoterate meglumine (*black*). Without cuff compression (*circles*), the CNR increases earlier, though equal values are reached with both agents using cuff compression (*triangles*)

both contrast agents showed similar results over time with an early rising score but a deterioration of arterial depiction starting about 96 s after contrast injection. Still, values for gadofosveset tend to be slightly higher. The score was dependent on venous overlay, as major venous overlay led to non-diagnostic arterial imaging. With cuff compression applied, the score rises a little later (about one sequence = 24 s) but stays on longer and reaches higher values, especially with gadofosveset. This pattern is somewhat comparable with the CNR graph. The differences in arterial visualization score between both contrast agents were statistically significant for all segments and both hands (see Table 1, mean AVS). The mean out of the highest score given per subject and segment is higher for gadofosveset as well (Table 1, mean highest AVS). The more distal the evaluated arteries, the less was the score. While proximal arteries received overall good scores (Fig. 4a), the digital arteries received predominantly non-diagnostic scores with the applied sequence (Fig. 4c).

**Fig. 4** Average rating for arterial visualization, separately for each segment (a–c). On the uncompressed side (*circles*), with both contrast agents the arterial depiction increases early and drops off again because of venous overlay and signal loss. With cuff compression applied (*triangles*), depiction starts a little later but stays on longer and reaches higher values, especially with gadofosveset. At the intermediate and distal arteries the graphs show a similar pattern but have a lower scale. The distal arteries especially were rarely rated above a score of 1 or 2. This implies that the imaging sequence used is not sufficient for diagnostic depiction of digital arteries





The doubling of acquisition time per frame in one volunteer led to improved signal and delineation, especially of the distal small arteries, showing that proper timing will help increasing image quality (images not shown).

**Assessment of cuff compression technique**

The use of the lower arm cuff compression was well tolerated in all subjects. To illustrate the impact of cuff compression, a series of MIP reconstructed images of a contrast-enhanced MR angiogram of both hands is displayed in Fig. 5. Compression was applied on the right side. The left side was without compression (non-compressed) and major venous overlay was observed early, compromising especially the evaluation of the distal arteries. This example illustrates the reduction of venous enhancement on the compressed side and the improved image quality related to compression. Though cuff compression led to a delay in arterial filling of approximately one image acquisition phase when compared with the uncompressed side. However, venous filling was delayed even more, usually starting with slow filling of the digital veins approximately 120 s after contrast agent injection. Thus, a phase with no or only minor venous overlay of 40–60 s resulted.

In Fig. 6, the assessment of venous overlay is displayed. For both the compressed and the non-compressed extremity, the score for venous enhancement increased similarly over time when comparing both contrast agents. Without cuff-compression applied, studies became non-diagnostic after approximately 96 s; while with cuff compression, the rating for venous overlay remained low until the end of the measurements. No significant differences between both contrast agents were found (Table 1, VCS). With cuff compression applied, higher arterial visualization scores were reached when using gadofosveset (Table 2). These differences were less pronounced with gadoterate meglumine.

**Discussion**

Imaging of the vessels of the hand may become necessary in patients with peripheral vascular or connective tissue disease and vascular lesions of the hand [6]. Due to its superior spatial resolution and the long-standing experience with this method, DSA is still considered to be the gold standard of palmar vessel depiction. However, contrast-enhanced MRA of the hand can already provide information approaching that of conventional angiography [1]. Furthermore, it is a noninvasive, quick and easy examination that produces a 3D data set of high-quality images without exposure to ionizing radiation. It is readily available in many institutions and can be used to obtain additional information of soft tissue and bone involvement. However, to make this method feasible for clinical routine

**Table 1** Comparison of gadoterate meglumine and gadofosveset, separated by extremity and segment (*AVS* arterial visualization score, *mean highest AVS* the average of the highest score assigned to a segment during the whole sequence, *CNR max* highest CNR value per series). *AVS* and *VCS* were measured on the respective four-point scales; CNRs are absolute values

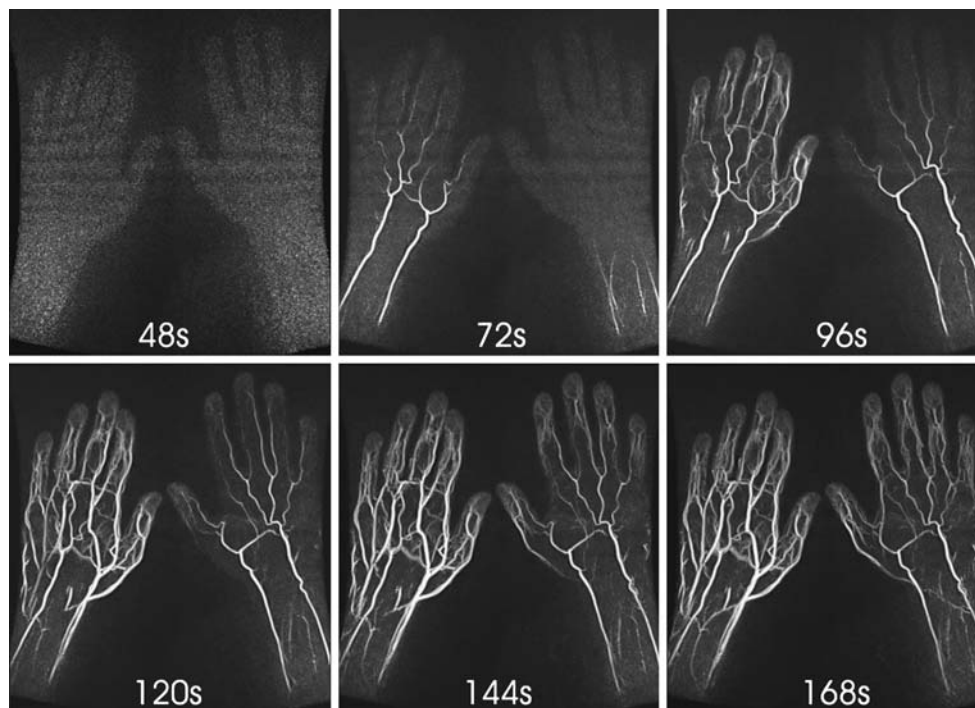
	Segments	Gadoterate w/o cuff	Gadofosveset w/o cuff		Gadoterate cuff	Gadofosveset cuff	
Mean AVS	Proximal	0.87	1.32	$p < 0.0001^*$	1.1	1.59	$p < 0.0001^*$
	Intermediate	0.52	0.8	$p = 0.0011^*$	0.64	1.02	$p = 0.0002^*$
	Distal	0.13	0.24	$p = 0.024^*$	0.21	0.39	$p = 0.0028^*$
Mean highest AVS	Proximal	2.6	2.9		2.6	2.9	
	Intermediate	1.83	2.36		1.93	2.16	
	Distal	0.6	0.9		0.96	1.4	
CNR max	All	34.9	42.6	$p = 0.0001^*$	33.7	42.0	$p = 0.0028$
VCS	All	1.41	1.42	$p = 0.86$	0.51	0.44	$p = 0.11$

\*Significant differences

and to ensure diagnostic results in MRA, the small digital vessels especially have to be depicted sufficiently; thus, adequate spatial resolution with high vessel contrast is essential. Intravascular contrast agents were specifically developed for contrast-enhanced MRA and promise to facilitate fulfillment of these criteria.

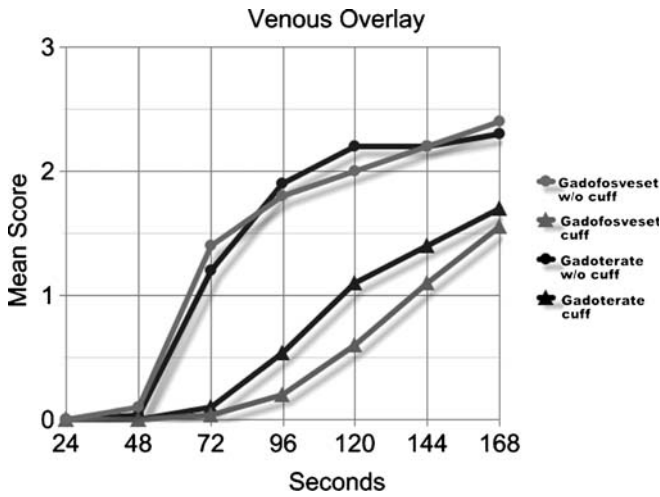
As our study shows, gadofosveset as intravascular contrast agent in fact improves first pass imaging of the arterial tree of the hand when compared with the extracel-

lular agent gadoterate meglumine. This might be to some part due to the higher relaxation rate of intravascular contrast agents. The relaxivity of gadoterate meglumine at 37°C in blood is  $4.2 \text{ l} \cdot \text{mmol}^{-1} \cdot \text{s}^{-1}$  and for gadofosveset it is  $19 \text{ l} \cdot \text{mmol}^{-1} \cdot \text{s}^{-1}$ , which is a factor of 4.5 more [5]. The injected Gd concentration was “only” 3.3-times lower for gadofosveset (0.1 vs 0.03 mmol/kg), which leads theoretically to a 1.36-times higher relaxivity per injection. However, with gadofosveset a smaller bolus was injected



**Fig. 5** These angiograms of a single volunteer were consecutively obtained with gadofosveset as contrast agent. Cuff compression was applied on the right side. Major venous overlay occurs early on the

non-compressed extremity compromising especially the evaluation of the distal arteries. On the compressed side, arterial enhancement is delayed but venous filling was diminished even more effectively



**Fig. 6** Mean score for venous overlay. Venous enhancement is significantly higher without compression applied (*circles*). Though there is no significant difference between the two contrast agents

(0.12 vs 0.2 ml/kg body weight). This in turn may lead to an advantage for gadoterate meglumine, since increased bolus size correlates with improved arterial depiction [4]. These differences in the injection protocol are in fact a limitation of this study. But in direct comparison, fading of arterial signal—probably due to distribution in the extravascular, extracellular space and diffusion—could be seen with gadoterate meglumine especially in the late phases, while gadofosveset retains a strong signal. This is reflected by significant differences in the qualitative as well as the quantitative data evaluation. Interestingly, even though an increased venous enhancement was expected for the intravascular contrast agent, the readers’ score for venous overlay was equivalent for both contrast agents. On the compressed extremity overlay was rated even a little less with gadofosveset. Probably the expected increase of venous contrast filling is compensated for by an increase of arterial signal intensity.

One of the advantages of blood pool agents lies in a prolonged intravascular residence that allows extended imaging with higher optical resolution in the steady state phase. Though we did not further investigate this, we think that steady state imaging is currently not feasible for the

vessels of the hand due to their small size and the overlap of arteries and veins (as we have observed in the late phases without compression). But sequences and algorithms for automatic differentiation of arteries and veins are currently under development and may change this in the future [7].

So far, venous overlay restricts arterial assessment. We demonstrated that continuous subsystolic lower arm cuff compression is an effective method to avoid or at least delay venous enhancement of arterial images. The mechanism of cuff compression works by a reduction of superficial vein blood flow with drainage through the deep veins and a venous-arterial backpressure mechanism via the capillary bed, which reduces arterial inflow velocity towards the lower arm arteries. The subsystolic cuff compression technique has already successfully been used to improve MR angiographic imaging of the lower extremity [8, 9]. It has also been utilized for the upper extremity as well [4]. But in difference to other protocols, in our study the cuff compression was applied at the lower arm, as this site is easier to access in the prone position.

A different approach was developed with suprasystolic compression to arrest blood flow in the arterial phase, thereby being able to extend image acquisition time, resulting in higher vessel signal and resolution [10]. Though this method requires individual bolus tracking technique and exact timing. Our continuous subsystolic cuff compression is easier to perform, more comfortable for the patient and allows dynamic depiction of arterial and subsequently venous filling. Still, there may be conditions in which venous depiction or abnormal and early venous filling can reveal pathologic features like venous malformations or hemangiomas.

A cuff pressure of 80 mmHg, which we used in our study, leads to a delay in arterial filling as well but is compensated for by a longer venous-free vessel depiction of about 40–60 s. This has to be regarded for acquisition schemes. As a restriction to this study, only a small set of volunteers with a mean age of 27 years was evaluated. It is known that in patients with vascular disease and in an older population the contrast kinetics vary significantly [11]. For instance, patients suffering from cellulites have rapid arteriovenous communication with a short arterial phase and increased incidence of venous contamination [12].

**Table 2** Comparison of compressed versus non-compressed extremity, separated by contrast agent and segment. For both contrast agents, the highest AVS per sequence was reached with compressed

extremity, while this difference was less pronounced with gadoterate meglumine. AVS was measured on the four-point scale. *Numbers in parentheses* state the time of maximum scoring

	Segments	Gadofosveset w/o cuff	Gadofosveset cuff		Gadoterate w/o cuff	Gadoterate cuff	
Highest mean AVS	Proximal	2.1 (72 s)	2.6 (144 s)	$p=0.026^*$	1.9 (72 s)	2.0 (96 s)	$p=0.027^*$
	Intermediate	1.4 (48 s)	1.8 (120 s)	$p=0.052$	1.2 (72 s)	1.4 (96 s)	$p=0.14$
	Distal	0.5 (72 s)	0.9 (120 s)	$p=0.025^*$	0.4 (72 s)	0.8 (96 s)	$p=0.084$

\*Significant differences

Therefore, further studies with higher temporal resolution focusing on patients with different vascular diseases may be necessary to optimize the imaging protocol. Furthermore techniques for vasodilatation, like warming-up the extremities with warm water or tempered cushions, may be useful but should be evaluated for the impact on the temporal change of arterial enhancement and venous filling first. The local application of vasodilating drugs as used in DSA is obviously not feasible with MRA, which may be the only inherent disadvantage of this non-invasive image acquisition.

The imaging sequence of our study showed to be insufficient for the diagnostic evaluation of the distal vessels of the hand. For improved depiction of the distal arteries the spatial resolution has to be increased. This may be accomplished by decreasing the field of view to one hand or a special region of interest, while using a dedicated

hand or wrist coil. Additionally, when using cuff compression acquisition time can be extended. In one example, we successfully extended the acquisition time to 48 s, receiving one phase of complete arterial enhancement without venous overlay on the compressed side. This way, diagnostic images with 0.5-mm isotropic resolution or less should be possible.

In conclusion, the use of the blood pool agent gadofosveset can improve the dynamic imaging of the vessels of the hand when compared with the extracellular gadoterate meglumine. But to fully utilize the advantages of intravascular contrast agents, venous overlay has to be delayed or reduced, which can effectively be achieved by lower-arm subsystolic cuff compression. However, especially in the distal arteries, image quality does not presently meet diagnostic standards with either the blood pool or extracellular contrast agent when using this protocol.

## References

- Connell DA, Koulouris G, Thorn DA, Potter HG (2002) Contrast-enhanced MR angiography of the hand. *Radiographics* 22:583–599
- Krause U, Pabst T, Kenn W, Hahn D (2002) High resolution contrast enhanced MR-angiography of the hand arteries: preliminary experiences. *VASA Zeitschrift für Gefasskrankheiten* 31:179–184
- Bilecen D, Aschwanden M, Heidecker HG, Bongartz G (2004) Optimized assessment of hand vascularization on contrast-enhanced MR angiography with a subsystolic continuous compression technique. *AJR Am J Roentgenol* 182:180–182
- Gluecker TM, Bongartz G, Ledermann HP, Bilecen D (2006) MR angiography of the hand with subsystolic cuff-compression optimization of injection parameters. *AJR Am J Roentgenol* 187:905–910
- Rohrer M, Bauer H, Mintorovitch J, Requardt M, Weinmann HJ (2005) Comparison of magnetic properties of MRI contrast media solutions at different magnetic field strengths. *Invest Radiol* 40:715–724
- Drape JL, Feydy A, Guerini H, Desmarais E, Godefroy D, Le Viet D, Chevrot A (2005) Vascular lesions of the hand. *Eur J Radiol* 56:331–343
- Wang Y, Yu Y, Li D, Bae KT, Brown JJ, Lin W, Haacke EM (2000) Artery and vein separation using susceptibility-dependent phase in contrast-enhanced MRA. *J Magn Reson Imaging* 12:661–670
- Bilecen D, Schulte AC, Bongartz G, Heidecker HG, Aschwanden M, Jager KA (2004) Infraglenal cuff-compression reduces venous contamination in contrast-enhanced MR angiography of the calf. *J Magn Reson Imaging* 20:347–351
- Zhang HL, Ho BY, Chao M, Kent KC, Bush HL, Faries PL, Benvenisty AI, Prince MR (2004) Decreased venous contamination on 3D gadolinium-enhanced bolus chase peripheral mr angiography using thigh compression. *AJR Am J Roentgenol* 183:1041–1047
- Wentz KU, Frohlich JM, von Weymarn C, Patak MA, Jenelten R, Zollikofer CL (2003) High-resolution magnetic resonance angiography of hands with timed arterial compression (tac-MRA). *Lancet* 361:49–50
- Prince MR, Chabra SG, Watts R, Chen CZ, Winchester PA, Khilnani NM, Trost D, Bush HA, Kent KC, Wang Y (2002) Contrast material travel times in patients undergoing peripheral MR angiography. *Radiology* 224:55–61
- Wang Y, Chen CZ, Chabra SG, Winchester PA, Khilnani NM, Watts R, Bush HL Jr, Craig Kent K, Prince MR (2002) Bolus arterial-venous transit in the lower extremity and venous contamination in bolus chase three-dimensional magnetic resonance angiography. *Invest Radiol* 37:458–463