

Eur Spine J (2010) 19 (Suppl 1):S2–S7
DOI 10.1007/s00586-009-1114-6

REVIEW ARTICLE

Classification of thoracolumbar fractures and dislocations

Max Aebi

Received: 23 July 2009 / Published online: 23 October 2009
© Springer-Verlag 2009

Abstract A classification of injuries is necessary in order to develop a common language for treatment indications and outcomes. Several classification systems have been proposed, the most frequently used is the Denis classification. The problem of this classification system is that it is based on an assumption, which is anatomically unidentifiable: the so-called middle column. For this reason, few years ago, a group of spine surgeons has developed a new classification system, which is based on the severity of the injury. The severity is defined by the pathomorphological findings, the prognosis in terms of healing and potential of neurological damage. This classification is based on three major groups: A = isolated anterior column injuries by axial compression, B = disruption of the posterior ligament complex by distraction posteriorly, and group C = corresponding to group B but with rotation. There is an increasing severity from A to C, and within each group, the severity usually increases within the subgroups from .1, .2, .3. All these pathomorphologies are supported by a mechanism of injury, which is responsible for the extent of the injury. The type of injury with its groups and subgroups is able to suggest the treatment modality.

Keywords Thoracolumbar fracture · Fracture-dislocation · Spine injury · Spinal fracture · Classification

Introduction

There have been attempts in the past to classify thoracolumbar injuries in different ways: according to mechanisms of injury [3], differentiating between flexion and distraction injuries [1, 4, 18, 20] or on the base of the so-called “ségment vertébral moyen” which Roy Camille, 1979 introduced [19]. René Louis introduced in 1977 the so-called three-column system based on the anterior column, which is the connection between the vertebral bodies and the discs and the two posterior columns consisting of the row of facet joints [11]. Therefore, René Louis’ three-column system represents a “trepied” concept. Denis in 1983 [2] as well as McAfee [14] used the term “three column” also in the context of thoracolumbar injuries. However, they meant something completely different from what René Louis meant. The Denis’ three column system is based on the idea that there is an anterior column including the two anterior thirds of the vertebral body and discs, a middle column consisting of the posterior third of the vertebral body and disc including the posterior vertebral body wall and finally a posterior column consisting of the connection of the facet joints on both sides and ligamentous bony complex between the spinal processes.

Here, the presented classification has leant ideas and concepts mostly from the classification of Nicoll [15] who differentiated between stable and non-stable thoracolumbar injuries and from the classification by Holdsworth by introducing four basic mechanisms of injuries represented in specific morphologies: compression, flexion, extension and flexion-rotation injuries [7].

Denis differentiated in his three-column concept between major and minor injuries. Minor injuries include transverse process, articular process pars inter-articularis fractures and spinal process fractures. Some of these

M. Aebi (✉)
MEM Research Center for Orthopaedic Surgery,
Institute for Evaluative Research in Orthopaedic Surgery,
University of Berne, Stauffacherstrasse 78,
3014 Bern, Switzerland
e-mail: max.aebi@MEMcenter.unibe.ch
URL: <http://www.MEMcenter.unibe.ch>

fractures are, however, not just minor injuries but just the tip of an iceberg, hiding a more important ligamentous injury.

The so-called major injuries include five types, namely the type A, B, C D and E. In the 1990s, the AO Group reviewed the issue of classification of spine injuries and came to the conclusion that there was no comprehensive classification system available and that the Denis classification—the most frequently used classification at this time—has a major problem consisting of the so-called three column and specifically the middle column. The middle column is a virtual column and not an anatomic entity and therefore not fit to be used as a denominator of an injury type [12, 13].

Therefore, a more logical concept needed to be developed. The AO Committee for spinal classification has demonstrated that a purely mechanistic classification is not useful for the practical application. In the daily practice, the doctors start from the description of the morphology since they look at an X-ray or another image modality and then they interpret the X-ray with some mechanistic terms.

Therefore, the classification system of the AO Group is based on three basic functions of a stable spine according to Whitesides [22]. A stable spine can resist three major forces: axial compression forces, axial distraction forces

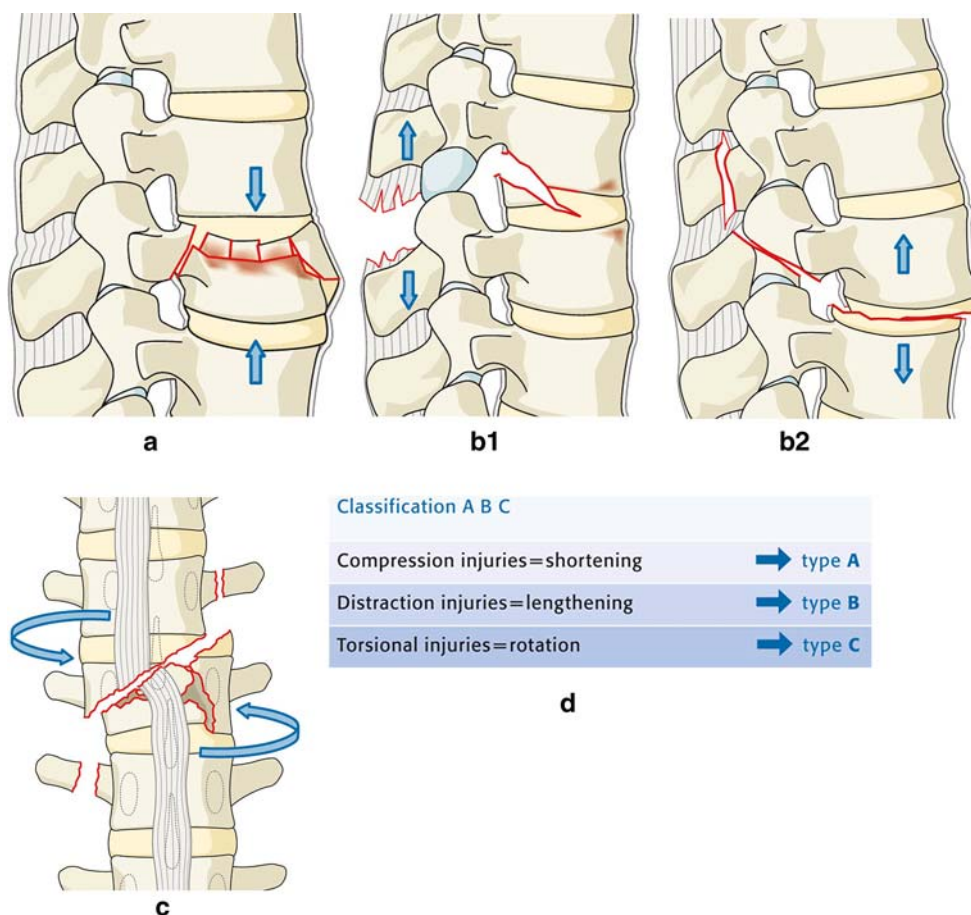
and torsional forces, respectively, rotation around the longitudinal axis. These mechanisms have more or less typical morphological patterns namely so-called compression injuries, distraction injuries and torsional injuries representing shortening, lengthening and rotation of the spine. Depending on where the centre of rotation of the spinal segment is located during an injury a corresponding injury pattern may occur.

If the centre of rotation is approximately at the posterior annulus a pure compression injury or burst fracture may result with shortening of the spine. In case the centre of rotation is located way posterior in the area of the spinous process then the result is a so-called extension distraction injury, respectively, a lengthening of the anterior column.

Three basic injury types can be therefore differentiated: Type A (compression), B (distraction) and C (rotation) injuries (Fig. 1).

As the Denis classification was based on 412 cases of which 197 cases were compression injuries without any neurological deficit and 215 cases, where burst seat belt or fracture dislocation injuries. The AO comprehensive classification of the thoracolumbar spine was based on more than 1,400 fractures and has been published in the *European Spine Journal* in 1994 [13]. The analysis of this whole

Fig. 1 Essential characteristics of the three injury types. **a** Type A, compression injury of the anterior column. **b** Type B, two-column injury with either posterior or anterior transverse disruption. **c** Type C, two-column injury with rotation. **d** Classification A B C (according to M. Aebi, V. Arlet, J.K. Webb, in AO-Manual of Spine Surgery, Vol. I, 2008. Thieme Publisher, Stuttgart)



collective of injuries clearly demonstrates a dominance of the injuries at the thoracolumbar junction with the most frequent fractures at L1, second frequent at T12, third frequent at L2, forth frequent at L3. Injuries of the T10 and L4 vertebrae are of the same frequency along with injuries of T5, 6, 7 and 8. A Classification of injuries has to tell the user something about the severity and the prognosis of the injury. Therefore, in the AO classification, there is a basic principle concerning severity: increasing severity from a Type A, Type B to the Type C injury and from the Group 1 to Group 3. The division of the injuries in Type A, B and C with each of them sub-divided in to three Groups leaves us with nine basic injury types. This nine basic injury types can all be sub-divided in totally 27 different injuries. It could be demonstrated that the most frequent thoracolumbar injuries are Type A injuries with about 65%, Type B with about 15% and Type C with about 20% of all thoracolumbar injuries. The severity of the injury is determined by the amount of the bony, respectively, ligamentous lesions or the combination of both as well as the combination of neuro-damage and mechanical instability. That is why there is an increasing degree of severity from A to C and 1 to 3, although all of these groups are overlapping and the most severe Type A injury may be more severe than their least severe B, etc. (Table 1).



There are some correlations between the severity of the injury and the accompanying neurological deficit. Type A-injuries, e.g. have a neurological deficit in about 70% of the injuries. The Type B injuries show a neurological deficit in the average of 32%. When looking at Type B3 injuries, a combination with a neurological deficit is demonstrated in about 50%. The Type C injury has neurological deficit in the average of 55%.

The fundamental principle of the AO classification is the recognition of the significance of the anterior and posterior column for the stability and prognosis.

Type A-lesions

The *Type A1-lesion* is a failure of the anterior column to resist compression and ends in an isolated vertebral body

Table 1 Progression of severity of thoracolumbar fractures

Severity 				
	A	A1	A2	A3
	B	B1	B2	B3
	C	C1	C2	C3
	type		group	

injury. This compression injury is expressed in shortening of the anterior column. The A 1.1 injuries are a subgroup of the compression type fractures (A1) with a pure impact fracture of the superior endplate, A 1.2 is a wedge type fracture and A 1.3, a vertebral body collapse in osteoporotic bone. In the A 1.2 fractures, the wedging is not sufficient to disrupt the posterior elements. Therefore, it remains an isolated vertebral body injury with the posterior elements intact. This kind of injuries can be on several levels at the same time. The A 1.3 fractures are typical osteoporotic compression fractures ending up in an impact of both endplates with mostly the posterior wall intact and different degrees of loss of height (so-called “fish”-vertebra).

The *Type A2-injuries* are split type fractures of the vertebral body only including fractures with a sagittal split (A 2.1) a frontal split (A 2.2) or so-called “pincer” fractures, which have the potential to end with a non-union due to the impacted disc material within the vertebral body [8].

The most frequent and severe fracture of the type A is the burst fracture *A3-lesion* with the subgroups of A 3.1 incomplete, A 3.2 complete and A 3.3 burst split fractures. The typical element of a burst fracture is the increase of the interpedicular distance and the loss of the height of the vertebral body. Typicalwise, burst fractures are characterised by a superior corner fragment of the posterior wall which may be accessible to ligamentotaxis. Complete burst fractures do involve both endplates, the superior as well as the inferior one. Considering burst fractures, it is advised to do a CT-Scan and to analyse the displaced fragments in the spinal canal in the horizontal cuts. A reversed fragment, in

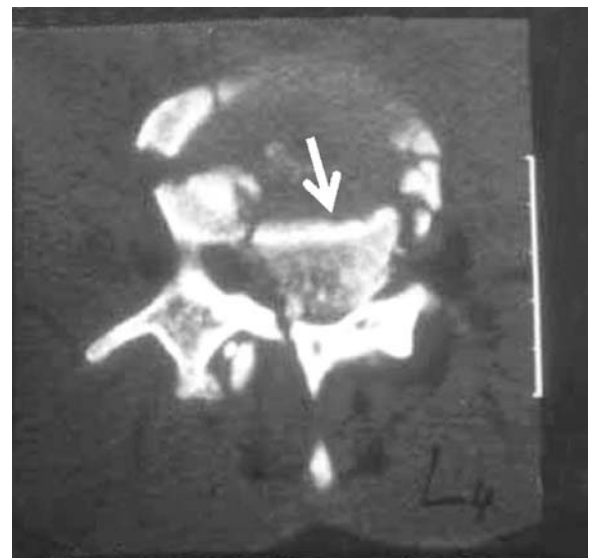


Fig. 2 Reverse cortical sign of the posterior wall fragment (*asterisk*) with cortex oriented towards the vertebral body (*arrow*)

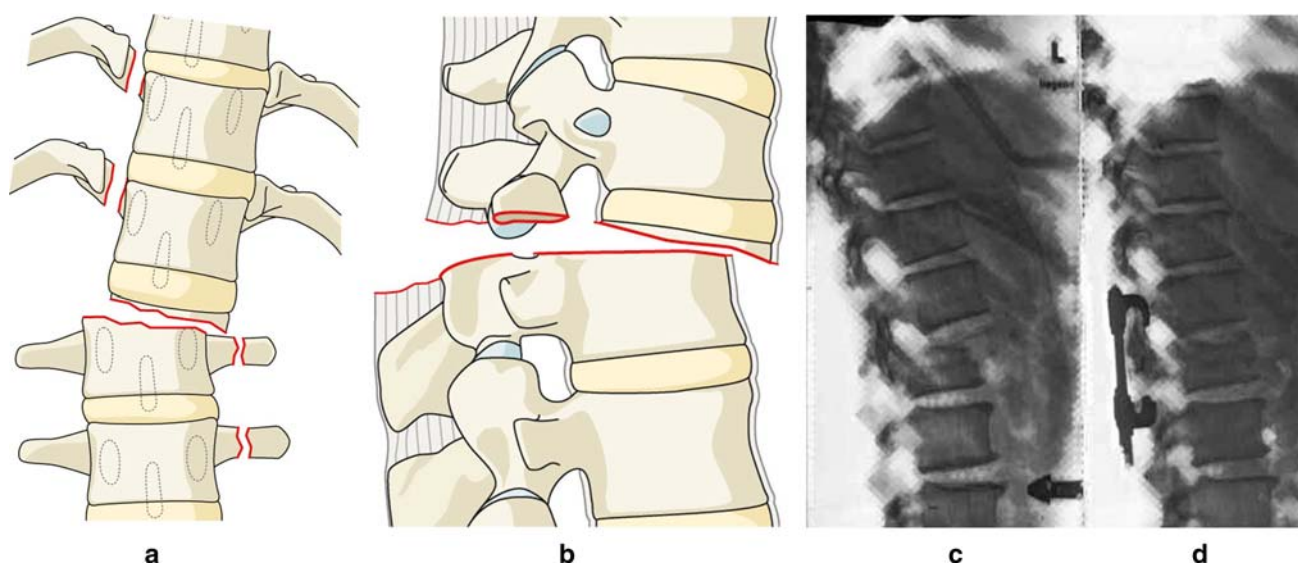


Fig. 3 Rotation-shear injury: Holdsworth slice fracture. **a** Anterior view. **b** Lateral view. **c** Example of a slice fracture with intact disc (arrow) and subchondral rotation shear injury. **d** Postoperative image

of injury shown (c) after reduction and unisegmental tension band fixation (according to M. Aebi, V. Arlet, J.K. Webb, in AO-Manual of Spine Surgery, Vol. I, 2008. Thieme Publisher, Stuttgart)

which the cortical bone of the posterior wall is looking towards the cancellous bone of the body instead towards the canal may be detected. In this case, the reduction by distraction may lead to a further dislocation of the fragment pushing onto the dural sac (buttonhole mechanism) (Fig. 2).

Type B-lesions

The Type B-lesion is, in most instances, a failure of the posterior column to resist distraction, which may lead to a disruption of the posterior tension banding system and a dislocation. The failure to resist distractive forces is mostly located in the posterior elements; however, rarely it can be also located in the anterior column producing very typical injuries (*B3-lesions*). It is important to understand that each B-lesion can be combined with an A-type appearance of the anterior column. However, the type of injury is always determined by the posterior column disruption and not by the injuries of the vertebral body. The posterior element disruption is the key in classifying vertebral injuries, since it implicates to a high degree the severity of the injury.

In *B1-lesions*, we find a posterior ligamentous disruption without relevant bony elements involved. The *B2-lesions* are basically bony seat belt injuries also called Chance fractures. They are usually seen on simple ap and lateral X-rays by a significant bony gap in the posterior elements. The amount of damage in the anterior column can be quite minor to severe [5].

Table 2 Classification of thoracolumbar fractures

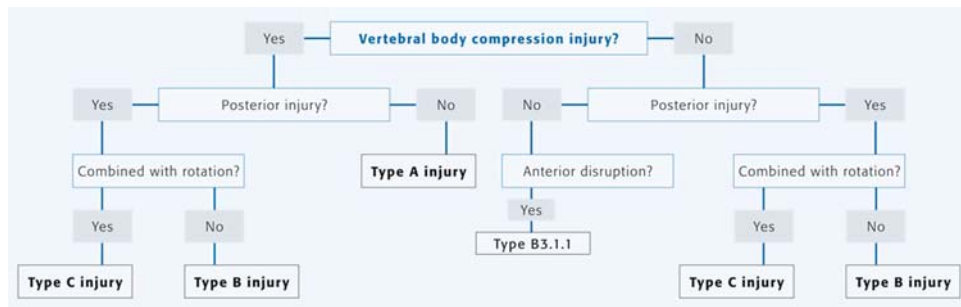
Type of injury	Loss of stability: bony, ligamentous, mixed	Deformity	Neuro-compression
A	—	— to ++	— to +++
B	+ to +++	— to +++	— to +++
C	+ to +++	+ to +++	— to +++

Table 3 Incidence of neurological deficit in 1,212 patients (12b)

Types of groups	Number of injuries	Neurological deficit (%)
Type A	890	14
A1	501	2
A2	45	4
A3	344	32
Type B	145	32
B1	61	30
B2	82	33
B3	2	50
Type C	177	55
C1	99	53
C2	62	60
C3	16	50
Total	1,212	22

Type C-lesions

These injuries end up in a disrupted posterior tension banding system and a disruption of the anterior column with a rotational dislocation. The *C1-lesion* is a rotational

Table 4 X-ray algorithm of AOSpine classification of injuries of the thoracic and lumbar spine

injury combined with a typical anterior lesion. In case of just a superficial analysis, such an injury may appear as a A-lesion. The *C2-lesion* is a rotational injury with a typical B type lesion and the *C3-lesion* is characterised by multi-level and shear injuries with a big variety and quite rare forms in their appearance. Very specific injury is the shear injuries of which one is called a “slice fracture” and where the fracture passes exactly underneath the end plate (Fig. 3). There is also the possibility of multilevel shear lesions. The C-injuries are always characterised by the rotation of two vertebrae against each other, what is visible even on a simple ap and lateral view of a conventional X-ray.

The AO classification has a *prognostic value* when taking into account the simple lesion types like A, B, C and analysing them with regard to the *stability*, the *deformity* and for potential of *neuro-compression*. A-lesions do usually have a good stability, a minor deformity, however, specifically in the burst fractures, we may find a significant neuro-compression by the fragments located in the spinal canal) (Table 2).

The B-lesions may have a minor to quite extensive instability as well as a secondary deformity and a neuro-compression due to translational dislocation in a vertebral segment. The same is true for the C-lesions, which usually have a significant instability, the deformity and a neuro-compression potential (Table 3). In summary, the determination of the injury type (A, B, C) is quite simple. The proposed algorithm is strictly based on an image analysis of spine injuries combined with additional information about mechanism of injuries, neurological deficits, etc. The key question is directed towards the condition of the posterior tension banding system.

In case, a patient comes to the emergency room with a thoracolumbar injury and after a clinical examination specifically in terms on neurological deficit, we usually have standard X-rays available or in rather advanced infrastructure a spiral CT with ap reconstruction of the

whole spine. The first question when analysing an image is always, whether the vertebral body has a compression injury or not. If this question is answered by Yes, we have for sure an A-lesion as long as there is no posterior lesion of the tension banding system detected. It is, therefore, paramount to analyse the posterior elements to proof or disproof a posterior element injury in the context with an anterior column injury. If there is a vertebral body compression injury combined with a posterior element injury; then the question is only whether the injury is combined with rotation or not. In case there is rotation, then we are encountering a C-lesion. If there is no rotation with a posterior element disruption, then we are talking about a B-lesion. In case, the question of a vertebral body compression injury is answered with No, then still we have to ask about the possible posterior element lesions. If we can proof that there is a posterior element lesion, then the next question again is whether it is combined with rotation or not. In case of a combination with rotation, we deal with a C injury, and where in case no rotation is present, it is a B-lesion (Table 4).

The AO-Spine classification is the most comprehensive and the most logical classification available until to date, although it has never been systematically validated. Several authors and groups have tried to validate this classification and came up sometimes with strange results. Some obvious injuries have been misinterpreted rather due to misunderstanding the classification than due to an inappropriate classification [6, 9, 10, 16, 17, 21].

In a recent publication about the AO-spine fracture classification, the authors based their results on more than 15 surgeons who basically independently classified the given injuries. The differentiation between an A-lesion and C-lesion though with obvious rotation was for some of the examiners not possible. Therefore such a validation will not help further and strongly supports a prospective validation by examiners who understand the concept of the clarification system [23].

Conflict of interest statement None of the authors has any potential conflict of interest.

References

1. Chance QC (1948) Note on a type of flexion fracture of the spine. *Br J Radiol* 21:452–453
2. Denis F (1983) The three column spine and its significance in the classification of acute thoracolumbar spinal injuries. *Spine* 8:817–831
3. Ferguson RL, Allen BL Jr (1984) A mechanistic classification of thoracolumbar spine fractures. *Clin Orthop* 189:77–88
4. Gertzbein SD, Court-Brown CM (1988) Flexion/distraction injuries of the lumbar spine. Mechanisms of injury and classification. *Clin Orthop* 227:52–60
5. Groves CJ, Cassar-Pullicino VN, Tins BJ, Tyrrell PNM, McCall IW (2005) Chance-type flexion-distraction injuries in the thoracolumbar spine: MR imaging characteristics. *Radiology* 236:601–608
6. Grunhagen J, Egbers HJ, Heller M, Reuter M (2005) Comparison of spine injuries by means of CT and MRI according to the classification of Magerl. *Rofo* 177(6):828–834
7. Holdsworth FW (1963) Fractures, dislocations, and fracture dislocations of the spine. *J Bone Joint Surg [Br]* 45:6–20
8. Jeanneret B, Ward J-C, Magerl F (1993) Pincer fractures: a therapeutic quandary. *Rev Chir Orthop* 79(spécial):Abstract 38
9. Keynan O, Fisher CG, Vaccaro A, Fehlings MG, Oner FC, Dietz J, Kwon B, Rampersaud R, Bono C, France J, Dvorak M (2006) Radiographic measurement parameters in thoracolumbar fractures: a systematic review and consensus statement of the spine trauma study group. *Spine* 31(5):E156–E165
10. Leibl T, Funke M, Dresing K, Grabbe E (1999) Instability of spinal fractures—therapeutic relevance of different classifications. *Rofo* 170(2):174–180
11. Louis R (1977) Les théories de l'instabilité. *Rev Chir Orthop* 63:423–425
12. Magerl F, Harms J, Gertzbein SD, Aebi M, Nazarian S (1990) A new classification of spinal fractures. Presented at the Société Internationale de Chirurgie Orthopédique et de Traumatologie (SICOT) Meeting, Montreal, September 9, 1990
13. Magerl F, Aebi M, Gertzbein SD, Harms J, Nazarian S (1994) A comprehensive classification of thoracic and lumbar injuries. *Eur Spine J* 3(4):184–201
14. McAfee PC, Yuan HA, Fredrickson BE, Lubicky JP (1983) The value of computed tomography in thoracolumbar fractures. An analysis of one hundred consecutive cases and a new classification. *J Bone Joint Surg Am* 65:461–479
15. Nicoll EA (1949) Fractures of the dorso-lumbar spine. *J Bone Joint Surg Br* 31:376–394
16. Oner FC, van Gils AP, Dhert WJ, Verbout AJ (1999) MRI findings of thoracolumbar spine fractures: a categorisation based on MRI examinations of 100 fractures. *Skeletal Radiol* 28(8):433–443
17. Oner FC, Ramos LM, Simmermacher RK, Kingma PT, Diekerhof CH, Dhert WJ, Verbout AJ (2002) Classification of thoracic and lumbar spine fractures: problems of reproducibility. A study of 53 patients using CT and MRI. *Eur Spine J* 11(3):235–245
18. Rennie W, Mitchell N (1973) Flexion distraction injuries of the thoracolumbar spine. *J Bone Joint Surg Am* 55:386–390
19. Roy-Camille R, Saillant G, Berteaux D, Marie-Anne S (1979) Early management of spinal injuries. In: McKibbin B (ed) *Recent advances in orthopaedics*, vol 3. Churchill Livingstone, Edinburgh, pp 57–87
20. Smith WS, Kauter H (1969) Patterns and mechanics of lumbar injuries associated with lap seat belts. *J Bone Joint Surg Am* 51:239–254
21. Vaccaro AR, Zeiller SC, Hulbert RJ, Anderson PA, Harris M, Hedlund R, Harrop J, Dvorak M, Wood K, Fehlings MG, Fisher C, Lehman RA Jr, Anderson DG, Bono CM, Kuklo T, Oner FC (2005) The thoracolumbar injury severity score: a proposed treatment algorithm. *J Spinal Disord Tech* 18(3):209–215
22. Whitesides TE Jr (1977) Traumatic kyphosis of the thoracolumbar spine. *Clin Orthop* 128:78–92
23. Wood KB, Khanna G, Vaccaro AR, Arnold PM, Harris MB, Mehbod AA (2005) Assessment of two thoracolumbar fracture classification systems as used by multiple surgeons. *J Bone Joint Surg Am* 87:1423–1429