

Joerg Kleeberg
Raphael Maire
Jean-Philippe Chave
Jean-Antoine Pournaras
Yan Guex-Crosier
Renaud A. Du Pasquier

Inaugural description of Cogan syndrome in an HIV-infected person

Received: 11 December 2007
Received in revised form: 27 February 2008
Accepted: 7 March 2008
Published online: 30 June 2008

Sirs: Cogan syndrome is an uncommon disease, characterized by non-syphilitic interstitial keratitis, and cochleovestibular manifestations. The latter look alike severe Ménière's disease and usually lead to deafness in 3 months [1, 2]. Almost 60% of the patients develop systemic manifestations, 10% of them suffering from life-threatening complications such as a systemic necrotizing vasculitis [3, 4]. The physiopathogenesis of Cogan syndrome is likely autoimmune, possibly mediated by the humoral immune response [4, 5].

In July 2006, a 43 year-old woman known for HIV infection

for 21 years, and hepatitis C, presented with three bouts of rotatory vertigo, emesis and left hearing loss. She was on antiretroviral treatment since 1992, and, since 2000 specifically on nevirapine, lamivudine, and zidovudine. Her CD4 count and HIV viral load were 616 cells/mm³ and undetectable, respectively. Suspecting Ménière's disease, she was placed on a one-week treatment of prednisone 40 mg daily. Two weeks later, a fourth attack of vertigo motivated another ENT examination revealing complete deafness on the left, sensorineural deafness of 50 dB on the right side and bilateral vestibular dysfunction. A brain MRI showed bilateral enhancement of the cochlea, semicircular canals and vestibulocochlear nerve (Fig. 1 a2). Valacyclovir 500 mg tid and prednisone 60 mg daily were prescribed for putative herpetic infection. Five days later, the patient was diagnosed with bilateral iritis, acute on the left and healing on the right eye, which was successfully treated with daily topical glucocorticoid eye drops. Otherwise, the patient was afebrile and in good general condition.

In August 2006, her CD4 count was 128 cells/mm³, a drop that was attributed to corticosteroids, but HIV viral load remained undetectable. A neurological examination revealed a horizontal nystagmus beating to the right side after suppression of fixation, a positive head thrust sign to the left, and ataxia of vestibular origin. Audiometry, auditory evoked potentials and caloric testing confirmed the presence of a bilateral total deafness and left vestibular loss. CSF examination was normal besides proteins at 82.5 mg/dl. In the CSF, cultures were negative such as were serology for syphilis and PCR for HIV, cytomegalovirus (CMV), herpes simplex-1 and -2, varicella zoster, and Epstein-Barr viruses, and for

Mycobacterium tuberculosis. Blood serologies were negative for syphilis, borreliosis, rubella, mumps and the above-mentioned viruses except for slightly positive CMV-specific IgM and IgG. Except for lymphopenia, slightly elevated erythrocyte sedimentation rate and liver enzymes, an extensive work-up was within normal limits, including neutrophil count, CRP, antinuclear, anti-nucleoproteins, and anti-neutrophil cytoplasmic antibodies, cryoglobulins, rheumatoid factor, angiotensin-converting enzyme, HLA-B27, Bence Jones proteins in the urine, thoraco-abdominal CT scan and transthoracic echocardiography. Suspecting Cogan syndrome, IV methylprednisolone at 1000 mg/d for 5 days followed by slow tapering of prednisone together with mycophenolate mofetil 1500 mg/d were introduced. In September, an interstitial keratitis of the left eye (Fig. 1 b, c), then of the right eye confirmed this diagnosis. Ocular lesions responded favourably to topical steroid therapy; however, the severe cochleovestibular deficits did not improve at all. In October 2006, CD4 count had increased to 599 cells/mm³.

■ Comment

This is the first description of Cogan's syndrome in an HIV+ patient. This syndrome was likely not due to immunosuppression – since CD4 count was high at disease onset – or to an “immune reconstitution inflammatory syndrome” (IRIS) since our patient had been on antiretroviral therapy for 14 years with a stable CD4 count. Even if we cannot rule out a coincidence, HIV might still have been instrumental in the pathogenesis of this Cogan syndrome. Indeed, HIV frequently causes an autoimmune dysregulation with

Dr. J. Kleeberg (✉) · Prof. R. A. Du Pasquier
Dept. of Neurology
CHUV
1011 Lausanne, Switzerland
E-Mail: joerg.kleeberg@chuv.ch

PD Dr. R. Maire
Dept. of Otolaryngology and Head and Neck Surgery
CHUV
1011 Lausanne, Switzerland

Dr. J.-P. Chave
Dept. of Internal Medicine
Devison of Infectious Diseases
CHUV
1011 Lausanne, Switzerland

Dr. J.-A. Pournaras · PD Dr. Y. Guex-Crosier
Jules Gonin Eye Hospital
University of Lausanne
Avenue de France 15
1000 Lausanne 7, Switzerland

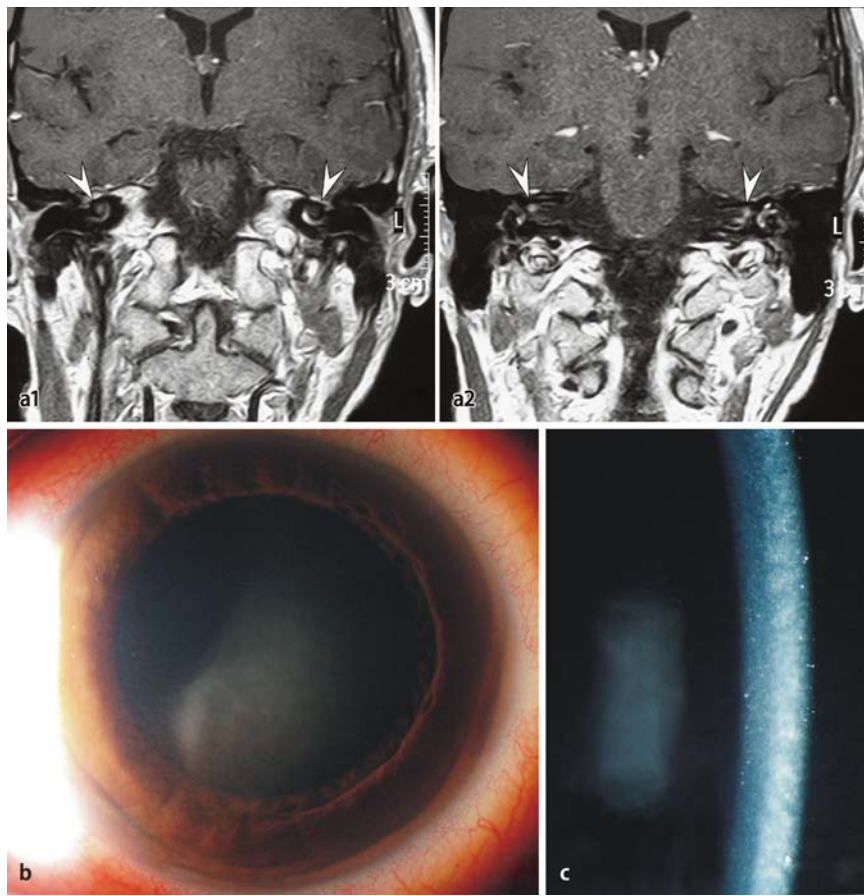


Fig. 1 **a1, a2** Magnetic resonance imaging of the brain. Coronal T1-weighted image showing contrast enhancement of bilateral cochlea (white arrows, **a1**) and vestibular nerves (white arrows, **a2**), predominantly on the left side. Photograph of the left eye demonstrating typical features of interstitial keratitis: **b** diffuse corneal haze, **c** central midstromal haze revealed by slit-lamp examination

loss of self-tolerance and increased autoimmunity [6, 7].

■ **Acknowledgments** This work was supported by grants from Swiss National Foundation (FN 3200BO-104262 and PP00B-106716).

References

1. Cogan DG (1945) Syndrome of nonsyphilitic interstitial keratitis and vestibuloauditory symptoms. *Arch Ophthalmol* 33:144–149
2. Haynes BF, Kaiser-Kupfer MI, Mason P, Fauci AS (1980) Cogan's syndrome: studies in thirteen patients, long-term follow-up, and a review of the literature. *Medicine (Baltimore)* 59:426–441
3. Vollertsen RS (1990) Vasculitis and Cogan's syndrome. *Rheum Dis Clin North Am* 16:433–439
4. Garcia Berrocal JR, Vargas JA, Vaquero M, Ramon y Cajal S, Ramirez-Camacho RA (1999) Cogan's syndrome: an oculo-audiovestibular disease. *Postgrad Med J* 75:262–264
5. Lunardi C, Bason C, Leandri M, Navone R, Lestani M, Millo E, Benatti U, Cilli M, Beri R, Corrocher R, Puccetti A (2002) Autoantibodies to inner ear and endothelial antigens in Cogan's syndrome. *Lancet* 360:915–921
6. Krupica T Jr, Fry TJ, Mackall CL (2006) Autoimmunity during lymphopenia: A two-hit model. *Clin Immunol* 120: 121–128
7. Zandman-Godfard G, Shoenfeld Y (2002) HIV and autoimmunity. *Autoimmun Rev* 1:329–337