

Inadvertent Fracture of a Plastic Biliary Stent During a Combined Percutaneous–Endoscopic Procedure: A Word of Caution Regarding Self-Locking Pigtail Biliary Catheters

Common bile duct (CBD) stricture is a rare complication of severe necrotizing pancreatitis, and may be a therapeutic challenge since patients with this disease are often very debilitated [1–3]. Due to the inflammation induced by pancreatitis, conventional stent placement during endoscopic retrograde cholangiopancreatography (ERCP) can be quite difficult [4, 5]. We report on the fracture of a plastic biliary stent which occurred during a rendezvous (combined percutaneous–endoscopic) procedure, and was related to the self-locking mechanism of a percutaneous pigtail biliary catheter. We also suggest approaches to prevent this complication.

Case Report

A 52-year-old man was admitted to the hospital for worsening cholestasis 8 months after an episode of acute necrotizing gallstone pancreatitis, requiring ERCP with biliary stone extraction, cholecystectomy, necrosectomy, and retroperitoneal lavage. He also had a history of kidney transplantation 14 years earlier for glomerulonephritis. An abdominal CT scan disclosed ascites, dilated intra- and extrahepatic bile ducts, edema of the body and tail of the pancreas, and numerous small fluid collections in the posterior abdomen. Repeat ERCP disclosed a tight CBD stricture, which could not be crossed using various guidewires. A percutaneous 8.5 Fr biliary drain (MAC-LOC, Cook, Bloomington, IN, USA) was inserted through the stricture, with its distal loop secured in the duodenum using the locking mechanism (Fig. 1). Five days later, a rendezvous procedure was performed to exchange the percutaneous biliary catheter with multiple 10 Fr plastic stents. A standard hydrophilic guidewire (Jagwire, Boston Scientific, Natick, MA, USA) was inserted percutaneously through the MAC-LOC catheter and into the duodenal lumen, grasped endoscopically with a snare, and used to insert a 10 Fr plastic biliary stent (CLSO-10-7, Wilson-Cook Medical, Winston-Salem, NC, USA). After partial withdrawal of the percutaneous biliary catheter into the intrahepatic bile ducts, transpapillary stent insertion was performed uneventfully (Fig. 2). The percutaneous biliary catheter, whose distal end was located 3 cm above the upper end of the stent, was then removed without fluoroscopic control. At this time, the stent migrated into the right liver lobe and was broken into two fragments (Fig. 3). The distal portion of the stent was removed endoscopically (using a balloon inflated inside the stent), but the smaller portion of the stent could not be retrieved from a peripheral bile duct despite multiple attempts. A percutaneous biliary catheter was left in drainage alongside the remaining stent fragment.

As the general condition of the patient deteriorated with development of retroperitoneal abscesses, stent fragment retrieval was not attempted further. The patient died 2 months later from multiorgan failure secondary to sepsis.

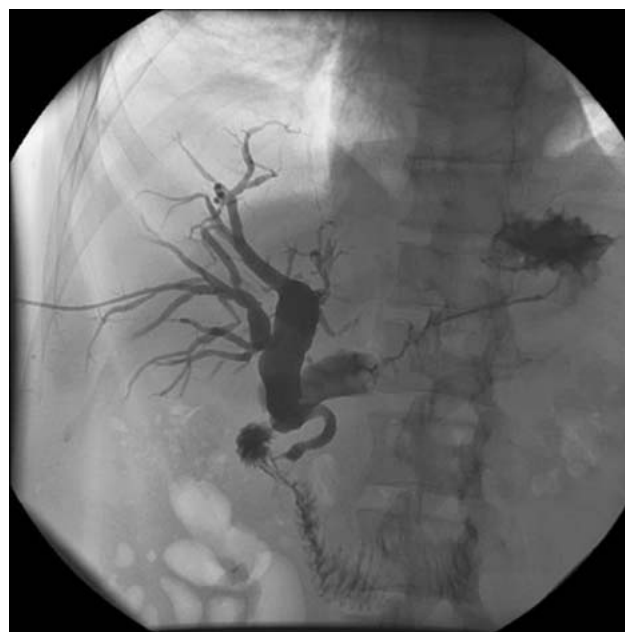

Fig. 1. Percutaneous transhepatic cholangiography shows a severe dilation of the intra- and extrahepatic bile ducts upstream from a short stricture located at the junction between the mid and lower thirds of the common bile duct. Note that the intrapancreatic portion of the common bile duct is distorted.

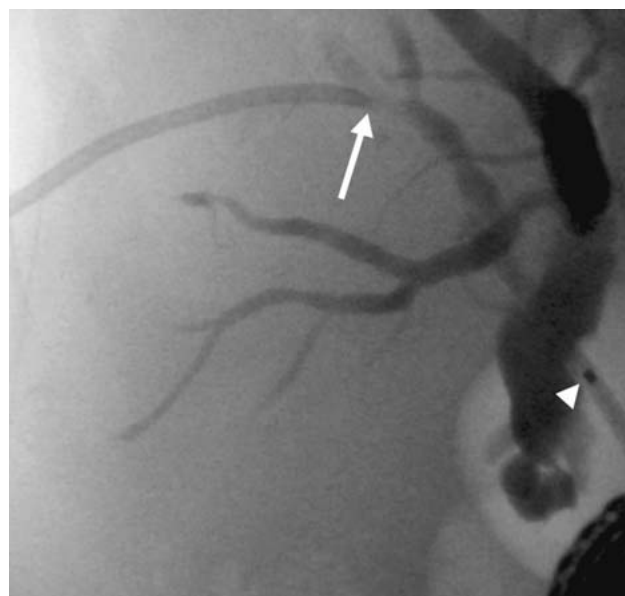


Fig. 2. At the end of the rendezvous procedure, the tip of the percutaneous biliary catheter (arrow) is located 3 cm above the guiding catheter used for transpapillary stent insertion (arrowhead). Note that the percutaneous catheter is straight as the locking mechanism has been released before withdrawal.

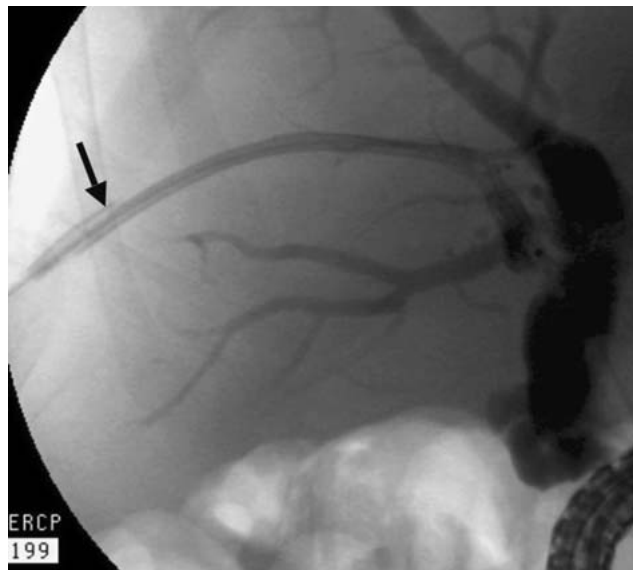


Fig. 3. Broken (arrow) plastic stent migrated into the right hepatic lobe. The long portion of the stent only was retrieved endoscopically; the smaller portion was left in a peripheral bile duct.

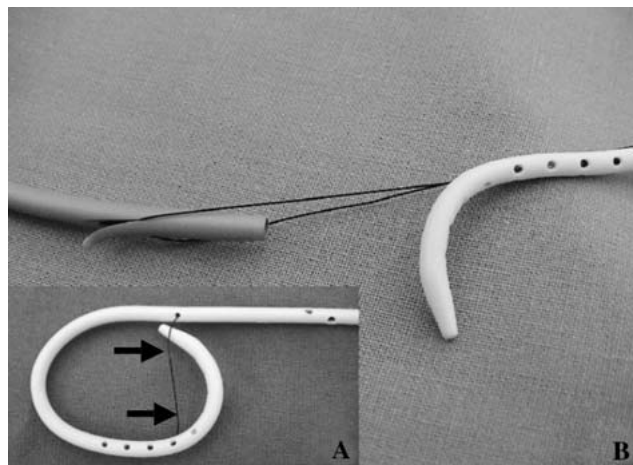


Fig. 4. **A** A string (arrows) helps to form the pigtail of the self-locking percutaneous biliary catheter (white). **B** A plastic stent (left) may be snared by this string, at a location where it is more fragile.

Discussion

Self-locking pigtail catheters are used for routine drainage procedures in most centers because their design contributes to prevention of accidental catheter dislodgment. However, the use of such catheters is associated with additional difficulties, related to the locking mechanism. These include difficulty unlocking the pigtail, migration of the string inside the catheter, and retention of the string after removal of the catheter [6]. In the reported case, the plastic biliary stent was sectioned by the string of the locking mechanism, which was caught on the proximal flap of the stent (Fig. 4). The design of the biliary stent, particularly its side holes, also contributed to the fracture. To avoid such complications

during rendezvous procedures, we suggest exchanging the pigtail catheter with a straight model before transpapillary stent insertion (a catheter is required to protect the parenchyma from potential damage due to the “cheese-cutter” effect) or, alternatively, to use plastic stents without side holes (e.g., Tannenbaum stent models).

To our knowledge, bile duct lesions complicating acute pancreatitis have been reported in 12 cases only, all of which were related to the severe, necrotizing form of the disease [3, 7–9]. They consisted of sloughing (acute phase) or stricture (late phase) of the extrahepatic bile ducts. During the acute phase of the disease, the necrotizing pancreatic process may extend to the extrahepatic bile ducts (including the gallbladder in some cases) [7–9]; this complication may be evidenced at laparotomy or by the detection of bilious ascites, and has been successfully treated by Roux-en-Y hepaticojejunostomy. During the late phase, CBD strictures have been reported after a partial CBD necrosis or as *de novo* complications, and were managed by surgical bilio-enteric anastomosis or CBD stenting [3, 8].

In conclusion, caution is required when self-locking percutaneous biliary catheters are replaced by internal drains during combined percutaneous–endoscopic procedures. Endoscopic material impaired by the wire of these catheters may lead to severe complications.

Jean-Marc Dumonceau¹

Michel Kahaleh²

Sylvain Terraz³

¹Division of Gastroenterology and Hepato-pancreatology, Geneva University Hospital, Geneva, Switzerland

²Digestive Health Center, University of Virginia Health System, Charlottesville, Virginia, USA

³Department of Radiology, Geneva University Hospital, Geneva, Switzerland

e-mail: jean-marc.dumonceau@hcuge.ch, jmdumonceau@hotmail.com

References

1. Gotzinger P, Sautner T, Kriwanek S, et al. (2002) Surgical treatment for severe acute pancreatitis: extent and surgical control of necrosis determine outcome. *World J Surg* 26:474–478
2. Tsiotos GG, Luque-de Leon E, Sarr MG (1998) Long-term outcome of necrotizing pancreatitis treated by necrosectomy. *Br J Surg* 85:1650–1653
3. Connor S, Alexakis N, Raraty MG, et al. (2005) Early and late complications after pancreatic necrosectomy. *Surgery* 137:499–505
4. Dumonceau JM, Deviere J, Delhaye M, Baize M, Cremer M (1998) Plastic and metal stents for postoperative benign bile duct strictures: The best and the worst. *Gastrointest Endosc* 47:8–17
5. Costamagna G, Shah SK, Tringali A (2003) Current management of postoperative complications and benign biliary strictures. *Gastrointest Endosc Clin North Am* 13:635–648, ix
6. Maher MM, Kealey S, McNamara A, O'Laoidh R, Gibney RG, Malone DE (2002) Management of visceral interventional radiology catheters: A troubleshooting guide for interventional radiologists. *Radiographics* 22:305–322
7. Dhall JC, Marwah S, Singh RB, Marwah N, Mathur SK (2000) Extrahepatic biliary-ductal necrosis in acute pancreatitis: A rare complication. *Pediatr Surg Int* 16:209–210
8. Chaudhary A, Sachdev A, Negi S (2001) Biliary complications of pancreatic necrosis. *Int J Pancreatol* 29:129–131
9. Schein M, Assalia A, Schmulevski P, Meislin V, Hashmonai M (1993) Infected peri-pancreatic necrosis causing gallbladder necrosis by direct extension. *HPB Surg* 7:77–79