

Benedict Rilliet
Olivier Vernet
Alessia Pica

The Geneva and Lausanne (French-speaking Switzerland) experience: in favor of the transsphenoidal approach when feasible

Received: 31 March 2005
Published online: 14 June 2005
© Springer-Verlag 2005

B. Rilliet (✉)
Service de Neurochirurgie,
Hopitaux Universitaires de Geneve,
rue Micheli-du-Crest 24,
1205 Geneva, Switzerland
e-mail: benedict.rilliet@hcuge.ch
Fax: +41-22-3728220

O. Vernet
Service de Neurochirurgie,
Centre Hospitalier Universitaire Vaudois,
rue du Bugnon 21,
1005 Lausanne, Switzerland

A. Pica
Service de Radio-oncologie,
Centre Hospitalier Universitaire Vaudois,
rue du Bugnon 21,
1005 Lausanne, Switzerland

Abstract Background: The authors present their current attitude towards management of craniopharyngiomas in children. Radical surgery cannot be performed when one is not sure about its potential danger to the visual pathways and the hypothalamus.

Methods: Most of the surgeries that have been performed in our institution via an intracranial approach were incomplete and followed by radiotherapy, in the last 10 years with stereotactic conformational radiotherapy. **Discussion:** Considering our past and present experience concerning the transsphenoidal approach for treatment of craniopharyngiomas, we make a plea for the consideration of this approach in children whenever feasible (around 25% of the cases in children older than 5 years). Craniopharyngiomas that can be removed by

this approach represent a milder form of the disease and the results concerning the visual, hypothalamic functions and quality of life are significantly better than that obtained via an intracranial approach. When the craniopharyngioma cannot be removed by this approach because of tight hypothalamic adhesences, the technique of cystosphenoidostomy with a custom-made shunt plus adjuvant stereotactic conformational radiotherapy is an alternative for its total removal.

Keywords Craniopharyngioma · Children · Transsphenoidal approach · Cysto-sphenoidal shunt

Following the literature on the difficult topic of management of craniopharyngiomas, one has the strong impression that the swing of the pendulum is again in favor of conservative surgery plus radiotherapy and not, by all means, radical surgery. Proponents of the conservative approach are well known to us all [2–4, 8], but their perspective was often criticized by promoters of the so-called “aggressive surgery”, especially in the light of lower recurrence rate after total removal. Things have changed; first of all, conventional radiotherapy is now abandoned in most centers in favor of conformational stereotactic radiotherapy with linear accelerator or Gamma knife therapy. Preplanning in the field of irradiation are nowadays much more precise owing to the refinement of computer programs and there is a hope that this will minimize the

secondary effects on the normal vital surrounding structures. Nevertheless, we still need more than 10 years to evaluate the late effects of stereotactic irradiation of craniopharyngiomas in children.

Furthermore, papers now appear that consider not just the “oncological” prognosis in terms of curing this benign tumor of dysembryoplastic nature, but also the long-term functional prognosis, in terms of hypothalamic sequels (principally obesity) and quality of life (essentially school performance). The recent evaluation by neuropediatricians (and not neurosurgeons!) of a series of 25 consecutive craniopharyngioma patients under 16 years of age who were treated in a single institution between 1980 and 2002 with a management policy of radical tumor excision is very informative in this respect [6]. Resection was assessed as

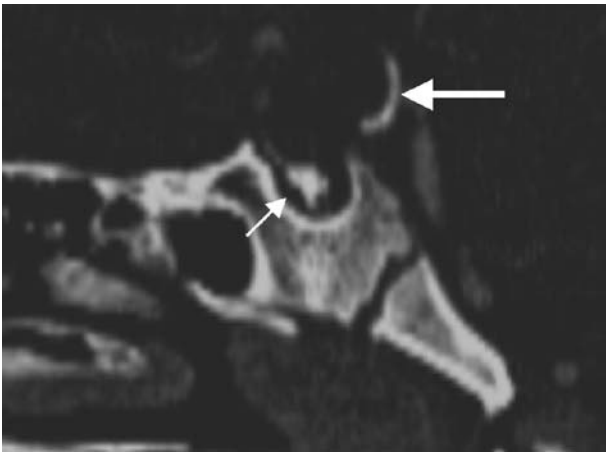


Fig. 1 CT: lateral reconstruction showing incomplete pneumatization of the sphenoid bone and thickened sellar floor, intra-sellar calcification (*small arrow*) and calcification of the posterior aspect of the suprasellar capsule of the cyst (*larger arrow*)

“macroscopically total” at first surgery in 23 of 25 patients, but this resulted in endocrine deficiency in 24/25, visual complications in 16/24, neurological complications in 8/24, obesity in 14/23, increased daytime sleepiness in 6/21 and significant school problems in 10/20.

Considering the data mentioned above, we have adopted—in Geneva and in Lausanne in the last 10 years—a more conservative approach. We have found that the only patients in whom we can achieve a total removal and who are not subsequently submitted to radiotherapy are those in which a transsphenoidal (TS) approach was performed. With only one exception, this was not the case in children who have been operated on at our institutions via an intracranial (IC) approach. Most of these patients have been submitted to adjuvant stereotactic radiosurgery that focused on tumor remnants.

Infra-diaphragmatic craniopharyngiomas represent a milder form of the disease and it is therefore of utmost importance to identify and select this subgroup of patients, because of the possibility of radical surgery as a unique

Fig. 2 T₁-weighted image (**a** coronal and **b** sagittal views). Arrow points to hypo-intense calcification

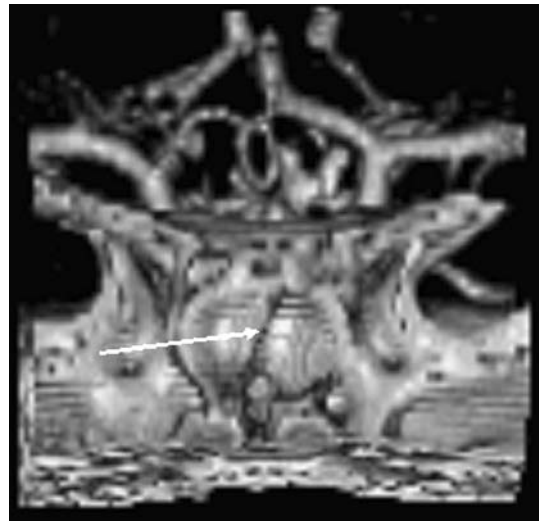
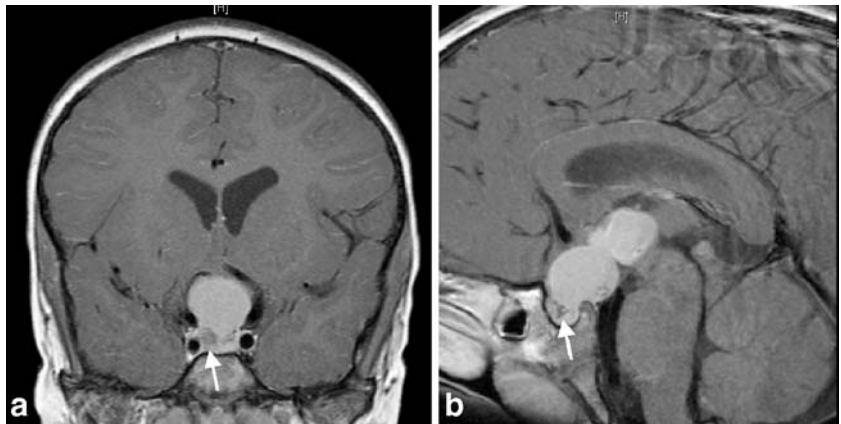


Fig. 3 3D reformatted coronal view of the sphenoidal block for better planning of the approach. Note the slightly oblique bony septum of the sphenoidal sinus (*arrow*)

treatment with an excellent visual outcome and a small percentage of complications due to a less-aggressive surgery (since the intra-cranial cavity is not virtually penetrated).

Operation through a TS route is reserved for patients with an infra-diaphragmatic (intra-sellar or intra- and supra-sellar), predominately cystic tumor. This approach can also be used as a combined procedure before or after craniotomy during a staged surgery, or as a secondary procedure for relapse when the residual cystic tumor has progressively entered and dilated the sella.

In a previously reported multi-center study (Geneva, Lausanne and Montreal), 24% of children were operated on via a TS approach [7]. The outcome in this group of patients was significantly better when compared with children who were operated on via the intracranial approach.

Of the last 11 children who underwent operation in the period January 1996–January 2005, four were operated on via a TS approach (36%) and only one recent case is

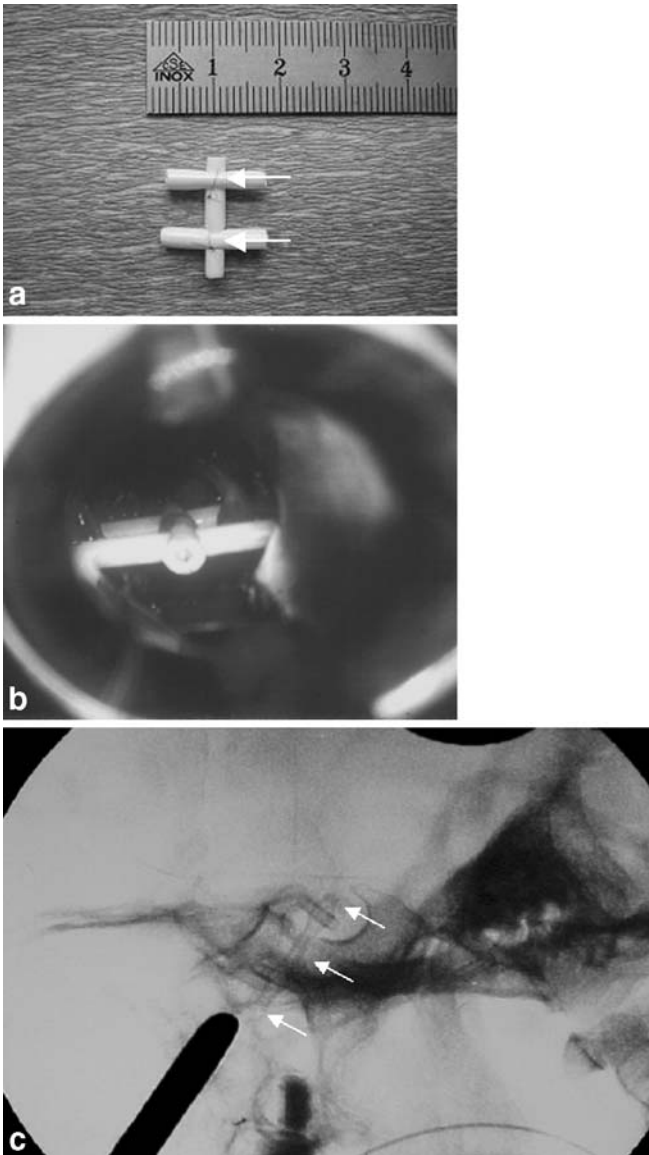


Fig. 4 **a** Custom-made shunt after Spaziante and de Divitis [9] with a simple piece of silastic tube; *arrows* point at 60 prolene suture to secure the parts of the H-shaped shunt. **b** Per-operative view of the cysto-sphenoidal shunt. The *upper horizontal tube* allows the shunt not to escape from the drained intrasellar portion of the craniopharyngioma cyst and the *lower horizontal tube* is seen in the sphenoidal sinus. **c** Lateral X-ray view of the skull (*arrows* delineate the shunt)

undergoing radiotherapy; six were operated from above and only one was not irradiated because a total removal was achieved. Another child had been already treated in another hospital by an IC approach and presented with severe obesity and was almost blind. A drain with a subcutaneous reservoir was inserted stereotactically in a cystic relapse of the craniopharyngioma and the patient was eventually treated with an intra-cavitary injection of Rhenium.

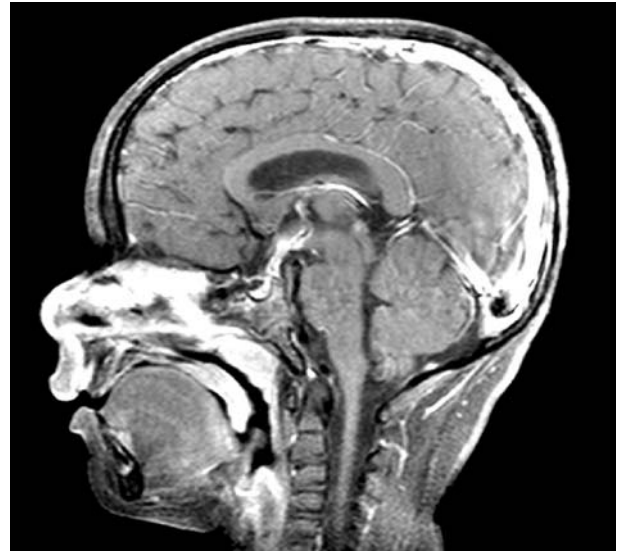


Fig. 5 Post-operative MR with gadolinium at day 3 showing collapse of the cyst after insertion of the cysto-sphenoidal shunt. 3rd ventricle is again visible

The TS approach can be performed even in small children, when the sphenoid bone is not fully pneumatized (conchal-type). Neuronavigation guidance is an adjunct to this approach to work as precisely as possible in the mid-line at the stage of drilling the bone. However, even with a careful TS approach and an opening of the thickened sellar floor with a high-speed drill, children below the age of 5 are rarely suitable candidates for this method. In the ISPC 91 series of 106 children operated below the age of five gathered by Choux et al. [1], only three craniopharyngiomas were approached via the TS route. When total removal is not possible and provided the arachnoid has not been opened, a custom-made cysto-sphenoidal shunt (CSS) can be inserted and left permanently. The patient is then sent to the radio-oncology department for stereotactic irradiation. This technique was first described by Laws [5] more than 20 years ago. In Europe, Spaziante and de Divitis [9] reported their experience regarding cystosphenoidostomy in 16 patients and, despite the fact that the cyst was in communication with the sphenoidal sinus, only one patient suffered a meningitis (4 years after the insertion of CCS) that was healed with antibiotics. Although there is now a recent trend to approach the sella with endoscopes, we are not yet aware of cases where the CSS could be placed with a purely endoscopic technique.

A recent case, which is discussed below, is an illustration of the cystosphenoidostomy technique.

Case report

A 512-year-old boy was admitted in the pediatric hospital on 6 January 2005. He has been followed up for 1 year for a polydipsy-polyuria syndrome that was thought

