

ORIGINAL ARTICLE

A. Kohler · R. Hoffmann · A. Platz · M. Bino

Diagnostic value of duplex ultrasound and liquid crystal contact thermography in preclinical detection of deep vein thrombosis after proximal femur fractures

Received: 29 August 1996

Abstract During a prospective clinical study the diagnostic value of the two non-invasive examinations colour-coded duplex ultrasound (Duplex) and fluid crystal contact thermography (LCCT) was investigated in relation to phlebography, the standard examination for the diagnosis of deep vein thrombosis (DVT), in 112 patients with proximal femur fractures. In 19% of the patients, DVT was diagnosed by phlebography, with the main localisation in the lower leg in 19 of 21 (90%) thromboses. With a negative prediction value of 83%, Duplex is less suitable than LCCT under such difficult examination conditions as the early postoperative period. The specificity of Duplex is 95%, but the sensitivity only 18%. The specificity of LCCT is 85% and the sensitivity 75%. Considering the frequency of postoperative DVT after surgery on the legs, especially hip surgery, a postoperative screening for DVT should become mandatory. LCCT has proved to be a suitable, cheap, non-invasive examination with a negative prediction value of 94%.

Introduction

Deep leg vein thrombosis (DVT) is, in spite of prophylaxis with heparin, still a frequent postoperative complication, especially after operations involving the lower extremities. Operations around the hip carry a very high risk, with published rates of thrombosis from 20% up to 40% [1, 6–10, 13, 17]. Therefore, these patients should be checked routinely. To prevent dangerous lung embolism and chronic vein insufficiency, an early diagnosis of DVT at the level of the lower leg is needed before appositional growth of the clot has occluded the popliteal vein and

starts to give rise to typical clinical symptoms. This requires very precise diagnostic methods at the calf and the feasibility of monitoring in the first postoperative days.

The golden standard for the diagnosis of DVT is still anterograde phlebography [1, 4, 10]. Despite the high incidence of DVT with possibly severe consequences [11], testing with phlebography has not become standard practice for high-risk operations such as hip surgery. This contrasts with the many obligatory preoperative examinations, which give indications of risks much lower than those associated with DVT. Arguments against using phlebography are the application of intravenous contrast, high dosage of X-radiation, pain and costs.

In addition to phlebography there are various technical examinations for the diagnosis of DVT. Colour-coded duplex ultrasound (Duplex) and liquid crystal contact thermography (LCCT) are two non-invasive ones which can be done a few days after the operation [1–6, 8, 10]. Duplex has a high sensitivity and specificity for the diagnosis of DVT, but the collective of patients is in most studies highly selected and the interpretation especially at the lower leg is controversial [1, 5, 6, 10, 17]. LCCT also has a good sensitivity but a slightly lower specificity [2, 8, 16]. LCCT is easy to use, with the patient lying in bed on the ward. The technique and interpretation of the results of LCCT are easy to learn. A non-invasive, reliable screening method for DVT diagnosis would be very helpful in postoperative management. Therefore, these two methods were evaluated during a prospective study under difficult clinical examination conditions during the early postoperative period with mostly very elderly patients.

Patients and methods

In a prospective, randomised, monocentric clinical study, the efficacy of low molecular weight heparin (LMWH; Sandoparin) given as one subcutaneous (s.c.) application of 3000 international units (IU) per 24 h was compared with the standard prophylaxis for high-risk operations, low-dose heparin (not fractionated heparin; LDH; Liquemin) given 3 times 5000 IU s.c. per 24 h. As a standard control to prove or exclude thrombosis, a phlebography was

A. Kohler (✉) · R. Hoffmann · A. Platz
Departement Chirurgie, Universitätsspital Zürich, Rämistrasse 100,
CH-8091 Zürich, Switzerland

M. Bino
Institute for Diagnostic Radiology, University of Zürich Hospital,
Zürich, Switzerland

Table 1 Contraindications for prophylaxis with heparin

– bleeding shock, polytrauma
– severe burn injury
– haemorrhagic diathesis (anamnesic tendency for suffusions, increased bleeding tendency)
– severe hypertension (blood pressure over 200 mmHg systolic or 115 mmHg diastolic)
– florid gastrointestinal ulcer
– head and brain injury
– oral anticoagulation with derivatives of coumarin or medication with non-steroidal anti-rheumatics

performed in the first week after the operation. Before the phlebography LCCT and Duplex were done to investigate these two methods of screening for the preclinical detection of deep DVT. Sensitivity, specificity, and positive and negative prediction values were calculated in relation to the results of the phlebography. All patients with proximal femur fractures (femur neck and intertrochanteric fractures) were included who did not have contraindications according to Table 1. Admission to the hospital occurred for all patients on the day of trauma. The randomisation to group A (Liquemin) or group B (Sandoparin) was done in the emergency room after confirming the diagnosis by X-ray. The first dose was given preoperatively in the emergency room after primary diagnostics and randomisation. For postoperative care on the operated leg, an elastic bandage was applied from the foot to the pelvis (hip-spika bandage). The bandage was removed on the second postoperative day. Mobilisation beside the bed was started on the 2nd postoperative day, and walking training was instituted on the 2nd or 3rd day after the vacuum drains (Redon) had been removed. Prophylaxis with heparin was always given for a minimum of 10 days. Before the control examinations the patient was informed a second time about the study (the first information given in the emergency room is commonly not satisfactory either for the patient or the doctor) and gave written consent. Between the 4th and 6th postoperative days clinical examination and LCCT were performed by one of three surgeons experienced in this technique, then the Duplex control and lastly phlebography were done at the Institute for Diagnostic Radiology. The examiners were not informed of each other's results.

LCCT was performed on the patient in his bed on the ward. In contrast to infrared thermography or indirect thermography, air conditioning or darkening of the examination room is not necessary. Fifteen minutes before the examination, the leg end of the bed was elevated to 15°. To achieve symmetric conditions both legs were freed from bandages, bed splints and coverlet, up to the hip. From 1 h beforehand neither physiotherapy nor ointment application was allowed. Outside rotation of the operated leg and then symmetric positioning of the opposite leg in supine position gave the best contact zone for the LCCT detector. In every instance all three projections, lower legs, knees and thigh, were checked.

Duplex was performed in the supine position. Changes of position to prone or standing up were not feasible due to the short time after operation and the old age of most of the patients.

Anterograde phlebography was done bilaterally on a tilt table. After injection of contrast in a dorsal vein of the foot, standard exposures at the level of the lower leg, knee, thigh and pelvis were taken. If the phlebography was not performed for any reason, the patient was excluded from the study. Oral anticoagulation with acenocoumarol (Sintrom) was started for 3 months if DVT was diagnosed in the lower leg with phlebography, or if full mobilisation after 10 days was not anticipated. Thrombosis of the popliteal, femoral or iliac veins was treated with full dosage continuous intravenous heparin, bed rest for 5–6 days and overlapping oral anticoagulation with acenocoumarol for 6 months.

The study was approved by the Ethics Committee of the University Hospital of Zürich.

Table 2 Reasons for prematurely ending study

Reason	Group B	Group A	Total
Bleeding complications	0	2	2
Phlebography refused	8	21	29
Administrative mistakes	6	6	12
Postoperative intensive care	3	2	5
Transfer to other hospitals	1	3	4
Age, infirmity	0	3	3
Total	18	37	55

Statistical analysis

The mean values were compared with the z-test. The contingency tables were analysed with the chi-square test. The limit for significance was always $\alpha = 0.05$ (5%). Sensitivity and specificity were calculated as usual. The positive/negative prediction value (p) is the possibility that the diagnosis is true if the result of the examination is positive/negative. Positive predictive value = $p(K/T+)$; K = ill patients and $T+$ = positive result of the examination. Negative predictive value = $p(G/T-)$; G = healthy patients and $T-$ = negative result of the examination.

Patients

From June 1993 until June 1995 at the University Hospital of Zurich, 167 patients with a proximal femur fracture (femur neck and intertrochanteric fractures) were randomised for the study, giving 125 women and 42 men with a mean age of 75.9 (+/- 13.5) years (range 28–96 years). The study was completed by 112 patients, 55 patients interrupted the study for different reasons (see Table 2), the most frequent one being the absence of phlebography, which some patients refused.

Results

In all, 112 patients completed the study, 45 in group A and 67 in B. The two groups were compared for the following criteria: age, sex, weight, height, preoperative bed rest, varicosis, anamnestic state after thrombosis or pulmonary embolism, atrial fibrillation, neoplasm, systemic angiopathy, diagnosis of operation, type of operation, surgeon and type of anaesthesia. There was no significant difference either for any of these criteria between the two groups or in relation to patients with thrombosis. Group A had significantly ($P = 0.001$) more drop-outs ($n = 37$) than group B ($n = 18$) (Table 2). Of the 112 patients with phlebography results, we found 21 cases of DVT (19%), 12 of 45 patients in group A (27%) and 9 of 67 patients in group B (13%). The difference between the groups is not significant ($P = 0.08$). With 19 patients (90%) the thrombosis was limited to the lower leg, and thus only 2 had thrombosis in the femoral and iliac vein.

LCCT was done on 107 patients (Figs. 1, 2); for 5 patients the instrument was out of order because of a technical defect. Many patients complained of pain during Duplex because of the attempted positioning procedure. In consideration of the unequivocal statistical results, we stopped performing Duplex after 79 patients because of poor acceptance. The results of phlebography, LCCT, Du-

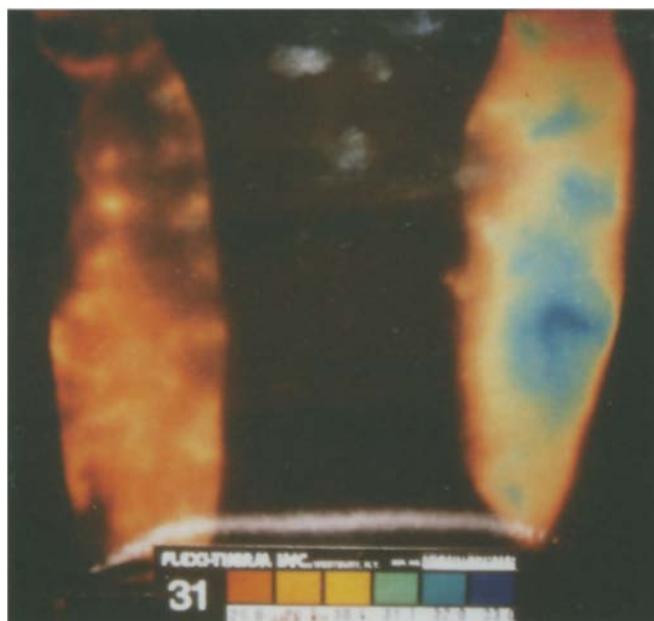


Fig. 1 LCCT finding in the ventral lower leg showing regional hyperthermia on the left side laterally (*blue area*)

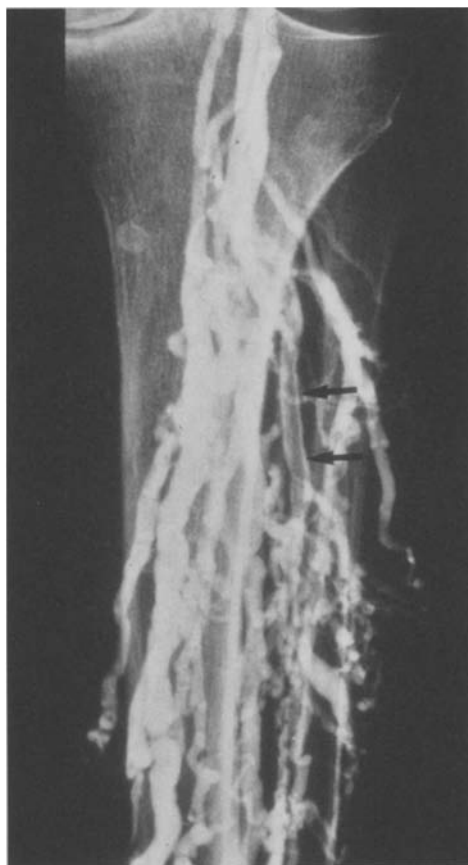

Fig. 2 Corresponding phlebography of the same patient with a fresh thrombosis in the fibular veins

Table 3 Results of the diagnostic methods in relation to phlebography (DVT deep vein thrombosis, LCCT liquid crystal contact thermography, Duplex colour-coded duplex ultrasound)

a) clinical examination vs phlebography			
Clinical exam	Phlebography		
	DVT yes	DVT no	Total
DVT yes	2 (1.8%)	19 (17.0%)	21 (18.8%)
DVT no	3 (2.7%)	88 (78.5%)	91 (81.2%)
Total	5 (4.5%)	107 (95.5%)	112 (100%)

b) LCCT vs phlebography			
LCCT	Phlebography		
	DVT yes	DVT no	Total
DVT yes	15 (14.0%)	5 (4.7%)	20 (18.7%)
DVT no	13 (12.1%)	74 (69.2%)	87 (81.3%)
Total	28 (26.1%)	79 (73.9%)	107 (100%)

c) Duplex vs phlebography			
Duplex	Phlebography		
	DVT yes	DVT no	Total
DVT yes	3 (3.8%)	14 (17.7%)	17 (21.5%)
DVT no	3 (3.8%)	59 (74.7%)	62 (78.5%)
Total	6 (7.6%)	73 (92.4%)	79 (100%)

Table 4 Statistical characteristics of LCCT and Duplex

LCCT	
Sensitivity	75%
Specificity	85%
Positive predictive value	54%
Negative predictive value	94%
Duplex	
Sensitivity	18%
Specificity	95%
Positive predictive value	46%
Negative predictive value	83%

plex and clinical examination are summarised in Table 3. In relation to the results of the phlebography, the statistical values were calculated (Table 4).

Discussion

The rate of thrombosis in our study is 19%, which is about the average of many other publications [1, 4–7, 9, 13, 17]. Prophylaxis with LMWH once a day has proven to be at least as efficacious as LDH three times a day. The *P* value of 0.08 even shows a tendency towards significant difference for the benefit of LMWH.

The clinical diagnosis of DVT postoperatively is unreliable. The differentiation between post-traumatic or post-

operative oedema and deep haematomas leads to false clinical judgements. In our study, with most diagnosed DVT in the lower leg, clinical evaluation is not sufficient.

Duplex has been assessed as having a high specificity of 95% but in contrast to the results from other studies, a low sensitivity of only 18% [1, 5, 18]. Reasons for this low sensitivity include the main localisation of DVT in the lower leg in 19 of 21 patients, the early postoperative time period of the examination and the old age of our patients. The low diagnostic precision of Duplex in the lower leg has also been confirmed by Ginsberg et al. and Magnusson et al. [4, 10]. Elderly patients often cannot cooperate in changing position to get more information with the Duplex because of postoperative pain and the many handicaps of old age.

LCCT was also limited by the early postoperative time period and the patient's inability to cooperate; in particular the prone position for dorsal exposure was not feasible.

LCCT had a lower specificity of 85% but a better sensitivity of 75%. The positive predictive value of 54% (Duplex 46%) and the negative predictive value of 94% (Duplex 83%) shows that LCCT is suitable for screening patients early in the postoperative period, to exclude DVT with a probability of 94%, even under difficult examination conditions. Cooke and Pilcher [2, 3] described thermography already in the 1970s as a suitable technique for the preclinical diagnosis of DVT. But the system was too complicated to be routinely applied. The technique of LCCT described by Pochaczewsky and collaborators [14] makes the examination much easier and allows one to check patients on the ward without difficult preparations. In spite of our aggressive antithrombotic prophylaxis, thrombosis remains a severe postoperative problem with a rate of 19%. Considering that over 60% of thromboses originate intraoperatively [12], early postoperative diagnosis is decisive to identify patients with DVT as soon as possible to institute adequate therapy to prevent appositional growth of the clot. The remaining high incidence of DVT with different types of prophylaxis involving heparin also seems to indicate that the rate of intraoperative origin is not influenced much by the type of prophylaxis. The localisation pattern of DVT with increased incidence in the lower leg in more recent publications suggests that the prophylaxis may slow down the postoperative growth of the clot in the bigger veins above the lower leg. This should give enough time for a postoperative diagnosis.

In our study LCCT has proven to be a suitable examination for the early postoperative detection of DVT before the manifestation of clinical symptoms. For screening for DVT of the lower leg, LCCT is superior to Duplex. Considering all the preoperative diagnostics used to reduce the perioperative risk for risks much lower than that of DVT, a postoperative control to exclude DVT should become mandatory. LCCT is a suitable non-invasive screening examination after high-risk operations like hip surgery. It allows a carefully directed early further diagnosis with phlebography and therapy with oral anticoagulation

for patients with DVT. This management limits most DVT at the level of the lower leg before irreparable changes [11] in the big veins above the popliteal vein or embolism can occur.

References

1. Barrellier MT, Bosson JL, Vignon C, Rousseau JF, Bernard M, Boissel M, Fauchon G, Pegoix M, Thomassin C, Trahay A (1994) Echo-doppler for early diagnosis of deep venous thrombosis in orthopedic surgery and traumatology. *J Mal Vasc* 19: 298–307
2. Cooke ED, Pilcher MF (1973) Thermography in the diagnosis of deep venous thrombosis. *Br Med J* 2: 523–526
3. Cooke ED, Pilcher MF (1974) Deep vein thrombosis: preclinical diagnosis by thermography. *Br J Surg* 61: 971–978
4. Ginsberg JS, Caco CC, Brill-Edwards PA, Panju AA, Bona R, Demers CM, Tutters LM, Nugent P, McGinnis J, Grant BM (1991) Venous thrombosis in patients who have undergone major hip or knee surgery: detection with compression US in impedance plethysmography. *Radiology* 181: 651–654
5. Girasole GJ, Cuomo F, Denton JR, O'Conner D, Ernst A (1994) Diagnosis of deep vein thrombosis in elderly hip-fracture patients by using the duplex scanning technique. *Orthop Rev* 23: 411–416
6. Grady-Benson JC, Oishi CS, Hanson PB, Cowell CW, Otis SM, Walker RH (1994) Routine postoperative duplex ultrasonography screening and monitoring for the detection of deep vein thrombosis. A survey of 110 total hip arthroplasties. *Clin Orthop* 307: 130–141
7. Hoffmann R (1991) The thrombo-embolic risk in surgery. *Hepato-gastroenterology* 38: 272–278
8. Hoffmann R, Brüttsch HP, Schwarz R (1990) Die Flüssigkristall-Kontaktthermographie in der Diagnostik der tiefen Venenthrombose. *Angiologie* 60: 12–17
9. Knudson MM, Lewis FR, Clinton A, Atkinson K, Mergerman J (1994) Prevention of venous thromboembolism in trauma patients. *J Trauma* 37(3): 480–487
10. Magnusson M, Eriksson BI, Kälebo P, Sievertsson R (1996) Is colour doppler ultrasound a sensitive screening method in diagnosing deep vein thrombosis after hip surgery? *Thromb Haemost* 75: 242–245
11. Milne AA, Stonebridge PA, Bradbury AW, Ruckley CV (1994) Venous function and clinical outcome following deep vein thrombosis. *Br J Surg* 81: 847–849
12. Nicolaidis AN (1975) Thromboembolism. Medical and technical publishing, Lancaster p 205
13. Platz A, Hoffmann R, Kohler A, Bischoff T, Trentz O (1993) Thromboembolieprophylaxe bei Hüftfraktur: Unfraktioniertes Heparin versus niedermolekulares Heparin. *Z Unfallchir Versicherungsmed* 86: 184–188
14. Pochaczewsky R, Pillari G, Feldman F (1982) Liquid crystal contact thermography of deep venous thrombosis. *Am J Radiol* 138: 717–723
15. Ritchie WG, Soulen RL, Lapayowker MS (1979) Thermographic diagnosis of venous thrombosis. *Radiology* 131: 341–344
16. Sandler DA, Martin JF (1985) Liquid crystal thermography as a screening test for deep-vein thrombosis. *Lancet* 1 (8430): 665–667
17. Walker RH (1994) Secondary prevention of venous thromboembolism in joint replacement using duplex ultrasonography. *Orthopedics* 17 [Suppl]: 14–17
18. Wenda K, Jaeger U, Das Gupta K, Degreif J, Runkel M, Ritter G (1993) Zur Entstehung der Thrombosen in der Hüftgelenkendoprothetik. Eine Studie mit der farbcodierten Duplexsonographie. *Unfallchirurg* 96: 373–381