

Christian T. Hamel  
Walter R. Marti  
Daniel Oertli

## Simplified placement and management of cutting setons in the treatment of transsphincteric anal fistula: technical note

Accepted: 10 November 2003  
Published online: 4 February 2004  
© Springer-Verlag 2004

An invited commentary on this paper is available at <http://dx.doi.org/10.1007/s00384-003-0567-z>

C. T. Hamel (✉) · W. R. Marti · D. Oertli  
Department of Surgery,  
General Surgical Service,  
University Hospital of Basel,  
Spitalstrasse 21, 4031 Basel, Switzerland  
e-mail: [chamel@uhbs.ch](mailto:chamel@uhbs.ch)  
Tel.: +41-61-2652525  
Fax: +41-61-2657250

**Abstract** *Background:* We report one safe and standardized technique of seton placement and management. *Conclusions:* A simplified way to manage cutting setons helps to minimize manipulation and may reduce pain. In most patients our technique can be used with no additional anesthesia and in an outpatient setting.

**Keywords** Fistula-in-ano · Cutting seton · Seton

### Introduction

We report a standardized technique for placement and management of cutting setons in the treatment of transsphincteric fistula-in-ano which permits minimal manipulation and harm to the anal structures. Using this described technique, the management of cutting setons can be performed in an outpatient setting with no need for an anesthesia in most cases.

### Technique

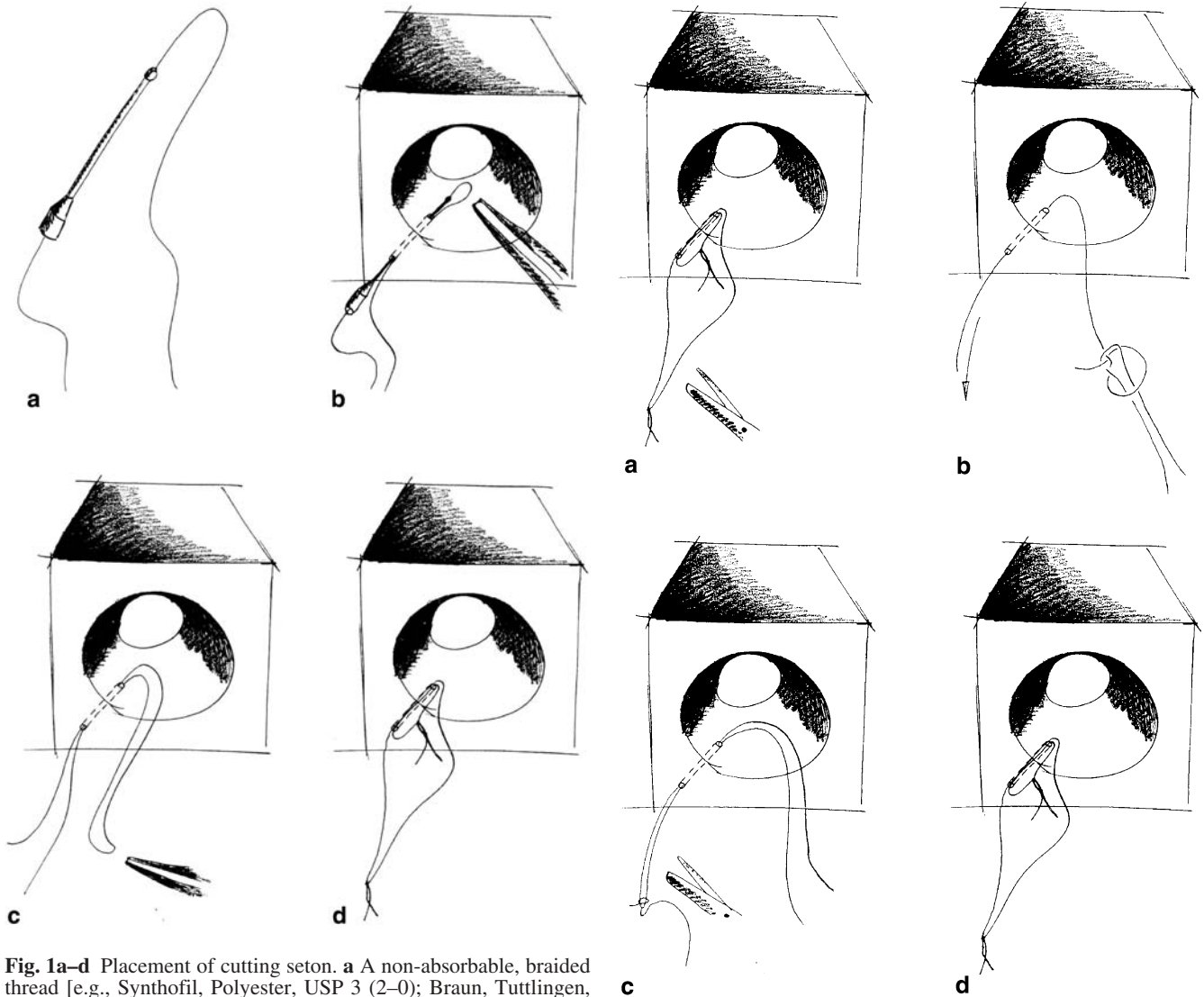
#### Placement of the seton

The identification of the primary tract of the fistula and the placement of the thread can be performed in one single step. A non-absorbable, braided thread (e.g., Synthofil, Polyester, USP 3 (2–0); Braun, Tuttlingen, Germany) is inserted in an olive tip cannula (Fig 1a). After excision of the external opening and the extrasphincteric parts of the fistula, this cannula is used to probe

for the tract of the fistula (Fig. 1b). Once the internal opening of the fistula is identified, the thread is grasped at the tip of the cannula with a pair of forceps and is pulled out of the anus (Fig. 1c). The olive tip cannula is removed and the thread is cut in two parts. The mucosa is incised over the muscular bridge (not shown in figures) to ensure that the thread is tied around the “naked” muscle only. One thread is tied snugly around the muscle; the other is tied loosely (Fig. 1d).

#### Management of cutting setons

The snugly tied seton has to be replaced after 14 days to provide appropriate tension to cut slowly through the muscle. To preserve the anal structures and to reduce pain for the patient, it is important to avoid excessive manipulation. This can easily be achieved with the second loosely tied seton (Fig. 2a). A new thread is folded in the middle and connected to the opened sling of the loose seton using a special knot shown in Fig. 2b. This knot is very small and provides a secure connection of the two



**Fig. 1a–d** Placement of cutting seton. **a** A non-absorbable, braided thread [e.g., Synthofil, Polyester, USP 3 (2–0); Braun, Tuttlingen, Germany] is inserted in an olive tip cannula. **b** This cannula is used to probe for the tract of the fistula. **c** Once the internal opening of the fistula is identified, the thread is grasped at the tip of the cannula with a pair of forceps and is pulled out of the anus. **d** The olive tip cannula is removed and the thread is cut in two parts. The mucosa is incised over the muscular bridge (not shown in figures) to ensure that the thread is tied around the “naked” muscle only. One thread is tied snugly around the muscle. The other is tied loosely

**Fig. 2a–d** Management (replacement) of cutting seton. **a** The loose seton is cut and used as a guide for the new setons. **b** A new thread is folded in the middle and connected to the opened sling of the loose seton using a special knot, which is very small and provides a secure connection of the two threads. **c** The old thread is removed and in the same maneuver two new setons are placed. **d** One thread is tied snugly around the remaining portion of the sphincter muscle. The other is tied loosely

threads. The old thread is removed and in the same maneuver two new setons are placed. Again, one thread is tied snugly around the remaining portion of the sphincter muscle; the other is tied loosely (Fig. 2d). This procedure can be performed under mild analgesia and eventually sedation (e.g., propofol plus morphine) or oral pain medication, depending on the patient’s tolerance. It does not require general or regional anesthesia.

Our experience in twelve patients with a transsphincteric fistula was as follows: all patients achieved complete

healing, with no complaints of incontinence at follow-up. In eleven patients the management of the setons could be performed under regular oral pain medication. One patient preferred intravenous sedation with Disoprivan (propofol). All patients were treated in an outpatient setting.

## Discussion

Once a fistula-in-ano is identified, plans must be made for surgery. The choice of operation will be influenced by the anatomy of the fistula, the sphincteric function, and the presence or absence of inflammatory bowel disease. The first step is a meticulous examination under anesthesia to determine the type of fistula and to identify the site of the internal opening. The inability to recognize and identify the internal opening of the fistula is the most common cause for recurrent fistula-in-ano. In a series of 1,000 patients reported on by Mazier [1], the internal opening was found in 96% of the patients and the recurrence rate was 3.9%. It was argued that 35.9% of these recurrences were due to missed internal openings, a finding very similar to the 31.8% recurrences thought to be due to missed primary openings in the series of Sainio and Husa [2]. Ramanujam et al. reported a recurrence rate of only 1.8% when the internal opening was found at the initial surgery [3].

Assuming that the anatomy of the fistula tract has been determined and the internal opening located, the surgeon can choose from a number of options. The majority of anal fistulas are superficial and easily treated by fistulotomy [4]. On the other hand, high transsphincteric fistulas remain a problem due to the risks of incontinence and recurrence [4, 5]. For many years setons have been used to treat this challenging problem. They are used in high fistula on the assumption that they induce chronic fibrosis, therefore fixing and preventing retraction of the sphincter when the latter is divided [4]. Setons, which are normally made of surgical sutures or elastic bands, can be used either as definitive treatment, with the intention to cut through the muscle over the fistula (cutting seton), or as a way to provide long-term drainage (loose seton) to minimize the chance of recurrent abscess formation.

Loose setons are used most frequently in the setting of Crohn's disease. Endoanal flap repairs have an advantage in that only a few muscle fibers of the sphincter are divided during the course of the operation and, as a one-step procedure, it may be an alternative treatment in patients with high fistulas. Other options include the use of fibrin glue and setons coated with chemical agents [6, 7].

One important issue is the management of cutting setons. There are numerous ways how to do it. It is very important to avoid additional damage to the sphincter muscle. Massive manipulation and the intense search for the tract of the fistula itself can result in further damage to the anal structures. Walfisch et al. [8] described the use of double setons in 1997. The authors proposed to tie one seton and leave the second untied. This second seton is tied after 1 month. We have taken this technique further because the cutting setons often have to be replaced—usually after an interval of 2–4 weeks—in order to be efficient. The setons may be too loose to cut through the structures or may even come loose. Manipulation of the setons can cause discomfort to the patients and can be painful. Another advantage of this technique when compared with using a slipknot is that when the sling is too tight, the setons can be replaced immediately in the same manner while the slipknot cannot be loosened.

## Conclusions

We report one safe and standardized technique of seton placement and management. A simplified way to manage cutting setons helps to minimize manipulation and may reduce pain. In most patients our technique can be used with no additional anesthesia and in an outpatient setting.

## References

- Mazier WP (1971) The treatment and care of anal fistulas: a study of 1,000 patients. *Dis Colon Rectum* 14:134–144
- Sainio P, Husa A (1985) Fistula-in-ano: clinical features and long-term results of surgery in 199 adults. *Acta Chir Scand* 383:7–88
- Ramanujam PS, Prasad ML, Abcarian H, et al (1984) Perianal abscesses and fistulas: a study of 1023 patients. *Dis Colon Rectum* 27:593–597
- Ho KS, Tsang C, Seow-Choen F, Ho YH, Tang CL, Heah SM, Eu KW (2001) Prospective randomised trial comparing ayurvedic cutting seton and fistulotomy for low fistula-in-ano. *Tech Coloproctol* 5:137–141
- Chan KM, Lau CW, Lai KK, Auyeung MC, Ho LS, Luk HT, Lo KH (2002) Preliminary results of using a commercial fibrin sealant in the treatment of fistula-in-ano. *J R Coll Surg Edinb* 47:407–410
- Seow-Choen F, Nicholls RJ (1992) Anal fistula. *Br J Surg* 79:197–205
- Garcia-Aguilar J, Belmonte C, Wong DW, Goldberg SM, Madoff RD (1998) Cutting seton versus two-stage seton fistulotomy in the surgical management of high anal fistula. *Br J Surg* 85:243–245
- Walfisch S, Menachem Y, Koretz M (1998) Double seton—a new modified approach to high transsphincteric anal fistula. *Dis Colon Rectum* 140:731–732