

Surgical hip dislocation versus hip arthroscopy for femoroacetabular impingement: clinical and morphological short-term results

Patrick O. Zingg · Erika J. Ulbrich ·
Tobias C. Buehler · Fabian Kalberer ·
Vaughan R. Poutawera · Claudio Dora

Received: 14 December 2011 / Published online: 14 October 2012
© Springer-Verlag Berlin Heidelberg 2012

Abstract

Introduction Surgical hip dislocation (SHD) is an accepted standard to treat femoroacetabular impingement (FAI). However, arthroscopic techniques have gained widespread popularity and comparable results are reported. The purpose of this prospective comparative study was to test the hypothesis that, when compared to SHD, hip arthroscopy (HA) results in faster recovery, better short-term outcome, and equivalent morphological corrections.

Materials and methods 38 patients presenting with clinically and morphologically verified isolated FAI were allocated to either HA or SHD. Morphological evaluation consisted of pre- and postoperative X-rays, and arthro-MRI. Demographic data, sport activities, hospital stay, complications, and the time off work were recorded. The subjective hip value, WOMAC, HHS, and hip abductor strength were measured up to 1 year.

Results Shorter hospital stay and time off work, less pain at 3 months and 1 year, higher subjective hip values at 6 weeks and 3 months, and better WOMAC at 3 months were seen after HA. The HHS and the hip abductor strengths were higher in the HA group. However, morphological corrections at the head–neck-junction achieved

by HA showed some overcorrection when compared to SHD. Labral refixation was performed less frequent in the HA group.

Conclusion When compared to SHD, HA results in faster recovery and better short-term outcome. However, some overcorrection of the cam deformity and limited frequency of labrum refixation with HA in this study may have a negative impact on long-term outcome.

Keywords Femoroacetabular impingement · Hip arthroscopy · Surgical hip dislocation · Recovery · Morphological correction

Introduction

Femoroacetabular impingement (FAI) is increasingly recognized as a common hip condition affecting the adolescent and adult population with groin pain and disability [1–5]. When conservative measures such as non-steroidal anti-inflammatory medications, activity modification, and injections fail, surgical options addressing the underlying osseous pathoanatomy and associated labral and chondral lesions may be undertaken.

The development of a surgical technique allowing hip dislocation without endangering the blood supply to the femoral head was critical to the understanding and the treatment of this condition and other intra-articular hip pathologies [6]. This surgical technique termed surgical hip dislocation (SHD) allowed to describe the pathomechanism of FAI [1, 3, 5, 7] and to develop the treatment strategies such as osteochondroplasty, acetabular rim resection, and fixation of torn labrum.

Subsequently, alternative potentially less invasive techniques to treat this condition using either a direct anterior

P. O. Zingg (✉) · T. C. Buehler · F. Kalberer · C. Dora
Department of Orthopaedics, University of Zurich, Balgrist,
Forchstr. 340, 8008 Zurich, Switzerland
e-mail: patrick.zingg@balgrist.ch

E. J. Ulbrich
Department of Radiology, University of Zurich,
Balgrist, Zurich, Switzerland

V. R. Poutawera
Department of Orthopaedic Surgery, Tauranga Hospital,
Tauranga, New Zealand

approach [8–11] or arthroscopic techniques [12–16] have been proposed.

Whereas clinical success has been reported for all three surgical methods, faster rehabilitation and return to sports, and less morbidity have been claimed for hip arthroscopy (HA) and the direct anterior approach.

Adequate correction of cam and pincer deformities is technically demanding and may be achieved more easily and accurately by SHD, thus potentially increasing the likelihood of preventing early hip osteoarthritis (OA).

The purpose of the present study was to test the hypothesis that (1) the postoperative recovery and short-term outcome after HA is superior compared to SHD and (2) the morphological corrections achieved by HA are equally sufficient when compared to the corrections achieved by SHD.

Materials and methods

Patients

After gaining approval from our responsible Investigational Ethical Review Board, a prospective comparative study comparing surgical treatment of FAI using arthroscopy versus SHD was started in July 2007. All patients presenting with symptomatic FAI proven by clinical examination, plain radiographs, and magnetic resonance imaging were included. A positive impingement sign together with hip internal rotation in the 90° flexed hip position of approximately 20° or less was the clinical criteria. Additionally, a cam deformity (alpha angle higher 55°) [17] on radial MRI sections and/or pincer deformity (crossover sign or coxa profunda or protrusion acetabuli on anteroposterior pelvic X-ray) together with corresponding chondrolabral lesions on arthro-MRI were the morphological criteria. Patients who had undergone previous surgery on their hip, or whose radiological investigations revealed acetabular retroversion with insufficient posterior wall (positive posterior wall sign) [18], additional acetabular dysplasia according to Lequesne's criteria (17), sequels of childhood hip disease such as Perthes disease or slipped capital femoral epiphysis, or hip OA higher to grade 1 according to Tonnis [19] were excluded.

From 375 patients presenting up to December 2009, 175 were excluded because of the above-mentioned exclusion criteria. Detailed hardcopy information concerning this comparative trial was given and explained to the remaining 200 patients and written informed consent was obtained.

One hundred and sixty-two patients declined to participate and were treated outside the study group by either SHD (33) or hip arthroscopy (129). 28 patients consented to participate in this study and were included. 10 of them

agreed to be randomly allocated to either arthroscopy (6 patients) or SHD (4 patients) and 28 of them made their own decision regarding HA (17 patients) or SHD (11 patients). Overall, 23 patients underwent arthroscopy and 15 SHD for FAI. All surgeries were performed by two senior hip surgeons having done (131/37) open surgical dislocations and (94/64) arthroscopies for FAI before July 2007.

Surgical techniques

General anesthesia was used for all surgeries. SHD was performed according to the technique described by Ganz [6].

As for the arthroscopic technique, patient positioning and portal placements followed Byrd's [20] description using fluoroscopy. Osteochondroplasty was judged adequate when by dynamic examination and with direct visualization an impingement-free internal rotation of at least 30° in the 90° flexed hip position was achieved.

Whereas weight bearing as tolerated on two crutches for 6 weeks was prescribed after HA, patients after hip dislocation were prescribed touch weight bearing on two crutches for 6 weeks because of concerns about eventual secondary displacement of the trochanteric osteotomy.

Clinical evaluation

Patient's age, gender, height, weight, BMI, working activity, inability to work as well as sport activity prior to the manifestation of FAI and before the surgical treatment were recorded before the index surgery.

After surgery, patients were asked to document their pain at rest and during daily activities on a weekly basis for the first 6 weeks using a visual analog scale (VAS).

Prior to the surgery and follow-up visits at 6 weeks, 12 weeks, and 1 year after surgery patients completed a WOMAC [2, 21], a subjective hip value using a VAS and a pain VAS at rest, during daily activities and sport activity.

Additionally, the range of hip internal rotation in 90° of hip flexion and hip abductor strength in the side position was measured. For the latter, an apparatus designed for measuring muscular strength during a period of 5 s was used (IsoBex, Medical Device Solutions AG).

Anteroposterior and cross-table lateral views were acquired at 6 weeks and magnetic resonance imaging at 3 months.

Morphological assessment

All morphological measurements were performed by an experienced musculoskeletal radiologist. On anteroposterior pelvic X-rays and cross-table lateral views acquired

preoperatively and 6 weeks after the surgery, the presence of a cross-over sign (COS) [18], a posterior wall sign (PWS) [18], a prominence of the ischial spine (PRISS) [22], and a herniation pit [23] was recorded, the CE-Angle [24], AC-Index [25], and quantitative COS [26] were measured and the OA grade was assessed according to Tonnis [19]. Additionally, the resection width angle [27] and the resection depth ratio [27] were determined according to Fig. 1.

On reconstructed radial reformations of magnetic resonance tomography scans acquired preoperatively and 3 months after the surgery, the alpha angle [17], anterior femoral head–neck offset [28], resection width angle, resection depth ratio, acetabular depth, and the anterior acetabular coverage angle were measured each on seven positions from anterior to posterosuperior according to Locher [29] (Fig. 2). The acetabular coverage angle was defined by an angle between two lines connecting each the center of rotation with either the anterior or the posterior rim of the acetabulum (Fig. 3). The acetabular depth (defined by the distance between the center of the femoral neck and the line that connects the anterior and posterior acetabular rim [30]) was measured only on position one (Fig. 2).

Statistical methods

Statistical analyses were performed by a statistical consultant. The postoperative alpha angle on a cross-table lateral view was chosen to be the primary outcome parameter and was used for the sample size calculation. According to a pilot study comprising 26 patients, a mean alpha angle of 38° with a standard deviation of 7.5° was achieved after correction of the cam deformity using SHD. We assumed that if an alternative surgical technique would result in alpha angles differing less than 7.5° when compared to the angles after SHD, this technique would be equivalent. Accordingly, a 7.5° difference was used for the

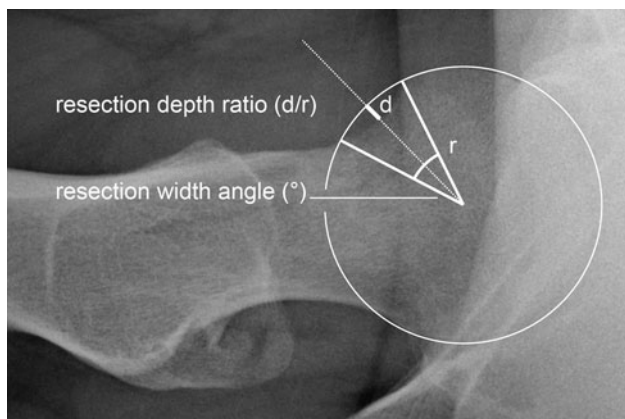


Fig. 1 Resection width angle and resection depth ratio

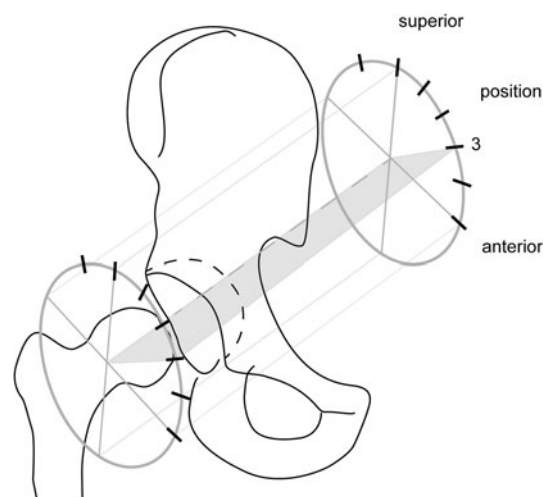


Fig. 2 Positions of the seven radial reformation planes in which the alpha angle, the anterior femoral head–neck offset, the resection width angle, the resection depth ratio, the acetabular depth, and the anterior acetabular coverage angle were measured

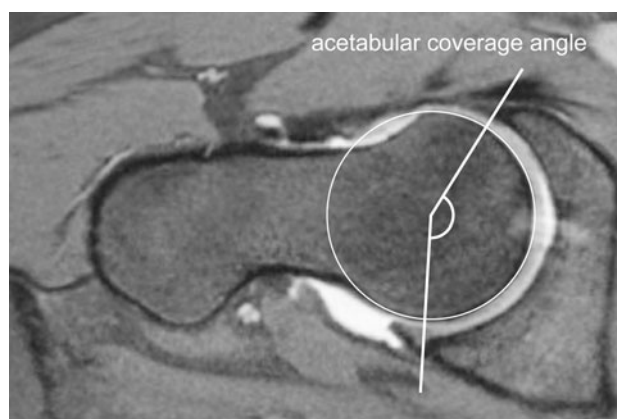


Fig. 3 Acetabular coverage angle measured in the seven different planes shown in Fig. 2

sample size calculation and revealed a number of 14 patients in each group in order to reject the null hypothesis with a significance level of 5 % and a power of 80 %. The paired Wilcoxon signed-rank test was used to compare pre- and postoperative values. The Mann–Whitney *U* and Chi-square test were performed to compare continuous and non-continuous data between the two groups. The level of significance was set at $p < 0.05$.

Results

Patient's demography and preoperative subjective and clinical parameters are summarized in Table 1. No

Table 1 Patient's demographics, preoperative subjective, and clinical parameters

	Arthroscopy					Open surgery					<i>p</i>
	<i>n</i>	Mean	SD	Min	Max	<i>n</i>	Mean	SD	Min	Max	
<i>n</i>	23					15					
Randomized	6					4					
Side (<i>r/l</i>)	8/15					7/8					
Gender (female/male)	5/18					4/11					
Age (years)		27.6	8.4	17.7	45.7		28.9	8.0	18.0	42.8	ns
BMI		24.4	3.3	20.7	33.3		23.4	3.8	17.7	31.6	ns
Labor (light/medium/heavy)	11/9/3					7/6/2					ns
Inability to work	3					2					
Level of sports activity											
Before FAI (high/intermediate/potentially low/low/none)	18/4/0/0/1					11/1/2/1/0					ns
Incapable	0					0					
With FAI (high/intermediate/potentially low/low/none)	9/7/1/1/1					5/2/2/2/0					ns
Incapable	4					4					
Harris hip score		75.2	10.3	54.0	96.0		80.2	8.3	64.0	97.0	ns
WOMAC											
Pain		2.5	2.1	0.0	6.5		3.0	2.1	0.0	5.5	ns
Stiffness		2.4	2.7	0.0	7.5		3.1	2.9	0.0	7.5	ns
ADL		2.1	1.7	0.1	5.4		2.5	2.0	0.0	5.3	ns
Overall		2.3	1.9	0.0	6.2		2.9	2.1	0.2	5.9	ns
Pain (VAS)											
At rest		15.0	21.9	0.0	75.0		18.3	13.8	0.0	40.0	ns
With ADL		33.5	25.3	0.0	90.0		40.0	22.3	0.0	70.0	ns
At sports		52.1	31.2	0.0	100.0		65.9	27.0	5.0	100.0	ns
Subjective hip value (%)		59.1	17.6	30.0	90.0		62.3	15.5	30.0	90.0	ns
Internal rotation ipsilateral (°)		11.5	8.1	0	25		13.3	5.8	5	25	ns

significant differences were encountered between the two groups. Even if 17 patients did not show an alpha angle higher than 55° on cross-table lateral views, 10 of them had at least on one radial MRI section, an alpha angle higher than 55°. Overall, 29 patients had a mixed type impingement with both alpha angles higher than 55° on radial MRI sections and a positive crossover sign or coxa profunda or protrusion acetabuli, 2 had an isolated cam and 7 an isolated pincer impingement.

Nevertheless, in all patients a cam deformity was encountered to some extent during surgery and was always surgically addressed. In 36 patients, a pincer deformity was present and corrected with acetabular rim resection. Labrum fixation was performed in ten cases, one arthroscopically and in nine during SHD, without any changes in the rehabilitation protocol. In the other 26 cases, the labrum was debrided before performing the acetabular rim resection.

In all patients, some degree of acetabular cartilage damage was recognized during surgery. In all but 11 cases,

the damaged cartilage part was excised when the acetabular rim was trimmed. In the remaining cases (6 treated by arthroscopy and 5 by SHD), some cartilage softening was left back without additional treatment and without adaptation of the rehabilitation protocol. Specific cartilage treatment such as microfracturing was never performed in that collective.

All recorded morphological parameters before surgery are summarized in Table 2. Overall, patients undergoing arthroscopic surgery for FAI showed similar pathologic hip morphology when compared to patients undergoing surgical dislocation. Nevertheless, there was a significant difference of the acetabular coverage angle in the position five that pointed to more important morphological pathologies on the acetabular side in the patients undergoing hip dislocation. Conversely, a significant difference in terms of head–neck offset ratio in positions one to four with more important morphological pathologies on the femoral side in patients undergoing arthroscopic treatment was noted.

Postoperative recovery and short-term outcome

After HA the requirements for hospital discharge were achieved faster than after surgical dislocation resulting in a

significantly shorter hospital stay of 3 (SD 0.8, range 2–5) versus 5 days (SD 1, range 4–7), respectively ($p < 0.001$).

During the first 6 weeks self-administered weekly, pain VAS levels at rest and during daily activities were similar

Table 2 Preoperative morphological parameters

Preoperative	Arthroscopy					Open surgery					<i>p</i>
	<i>n</i>	Mean	SD	Min	Max	<i>n</i>	Mean	SD	Min	Max	
<i>n</i>	23					15					
X-ray											
Osteoarthritis (grade 1)	12					5					
CE angle (°)		32	4.8	24.0	43.0		32.7	4.5	25.0	43.0	ns
AC index (°)		6	4.0	0.0	10.0		6.2	4.9	−4.0	10.0	ns
Alpha angle (°)		59	11.4	43.0	83.0		56.6	6.2	49.0	67.0	ns
Head–neck offset ratio		0.18	0.04	0.12	0.25		0.16	0.04	0.11	0.24	ns
COS											
COS ratio	16	0.20	0.07	0.08	0.32	9	0.26	0.07	0.17	0.34	ns
PWS											
PRISS	10					6					
Coxa profunda	8					5					
Protrusio acetabuli	8					5					
Herniation pit	1					0					
	3					3					
MRI											
Alpha angle 1 (°)		53	7.8	38.0	75.0		50	8.2	37.0	66.0	ns
Alpha angle 2 (°)		56	9.4	38.0	75.0		52	10.4	37.0	69.0	ns
Alpha angle 3 (°)		58	9.8	41.0	76.0		53	9.6	33.0	69.0	ns
Alpha angle 4 (°)		60	9.8	40.0	76.0		56	12.5	33.0	79.0	ns
Alpha angle 5 (°)		58	10.9	39.0	80.0		60	14.5	38.0	79.0	ns
Alpha angle 6 (°)		58	13.3	39.0	85.0		59	15.2	38.0	80.0	ns
Alpha angle 7 (°)		53	13.4	34.0	90.0		52	10.7	41.0	77.0	ns
Head–neck offset ratio 1		0.18	0.03	0.11	0.23		0.23	0.04	0.14	0.29	ns
Head–neck offset ratio 2		0.18	0.04	0.09	0.24		0.22	0.05	0.14	0.29	0.005
Head–neck offset ratio 3		0.15	0.05	0.05	0.23		0.21	0.05	0.14	0.31	0.006
Head–neck offset ratio 4		0.15	0.06	0.04	0.32		0.19	0.05	0.13	0.31	0.007
Head–neck offset ratio 5		0.16	0.05	0.04	0.24		0.19	0.06	0.08	0.28	0.011
Head–neck offset ratio 6		0.17	0.05	0.06	0.26		0.18	0.07	0.08	0.28	ns
Head–neck offset ratio 7		0.19	0.04	0.11	0.26		0.15	0.07	0.06	0.27	ns
Acetabular coverage angle 1 (°)		156	9.8	139.0	180.0		152	9.9	133.0	165.0	ns
Acetabular coverage angle 2 (°)		161	8.0	144.0	176.0		158	9.1	139.0	172.0	ns
Acetabular coverage angle 3 (°)		172	6.9	157.0	188.0		170	9.8	149.0	183.0	ns
Acetabular coverage angle 4 (°)		179	8.5	160.0	195.0		171	14.4	140.0	194.0	ns
Acetabular coverage angle 5 (°)		154	12.2	136.0	182.0		145	6.5	135.0	158.0	0.020
Acetabular coverage angle 6 (°)		154	13.2	134.0	183.0		146	7.6	133.0	158.0	ns
Acetabular coverage angle 7 (°)		153	12.3	132.0	188.0		150	10.1	134.0	165.0	ns
Acetabular depth (mm)		5	2.8	0.0	10.0		6	1.4	3.0	8.0	ns
Impingement											
Mixed	18					11					
Cam	0					2					
Pinzer	5					2					

in both groups and averaged 24.6 (SD 20, range 0–75) versus 25.8 (SD 21, range 0–77) ($p = 0.456$).

Table 3 summarizes the parameters evaluated at 6 weeks, 3 months, and 1 year after surgery. In terms of subjective parameters, patients in the arthroscopy group reported better scores than patients after surgical dislocation. They reported significant less pain levels at rest and during daily activities at 3 months and 1 year, superior subjective hip values at 6 weeks and 3 months, and better overall satisfaction at 3 months. The recorded Harris hip score was significantly superior in the arthroscopy group during all postoperative evaluations but differences got smaller over time. The same was recorded for hip abductor strengths. When compared to the SHD group, the level of sports activity was significantly higher in the arthroscopy group at 3 months but similar at 1 year. Pain during sports activities did not significantly differ between the groups. Overall, preoperative levels of sports activities were achieved in both groups after 1 year, but sport activity levels recorded before the manifestation of FAI were not achieved.

Comparing patients with labral refixation with those that had a labral resection, no significant differences were found with regard to subjective hip value, WOMAC, and HHS at all times.

Time off work (workers compensation) after surgery was significantly less in the arthroscopy group, even if secondary surgeries such as hardware removal are not taken into account. Exact numbers as well as perioperative complications and surgical revisions are summarized in Table 4.

Morphological correction

Table 5 summarizes the morphological parameters after surgery. In terms of the alpha angle, a bigger correction was obtained using the arthroscopic technique. All other parameters did not significantly differ. Figure 4 illustrates lower alpha angles after arthroscopy on different positions around the neck from anterior to posterosuperior representing more extensive osteochondroplasty in this group.

Discussion

The present prospective comparison of surgical treatment of FAI using SHD and HA reveals a shorter hospital stay, less pain levels up to 1 year after surgery, better subjective hip values and WOMAC up to 1 year after surgery as well as faster return to work activities in the arthroscopy group. Nevertheless, even if sufficient and similar corrections of the underlying morphological pathologies were achieved in both groups, hip arthroscopy was significantly more

associated with overcorrection of the cam deformity and with resection as opposed to refixation of the labrum.

Length of hospital stay is very rarely mentioned in the literature. One study on SHD reported a mean of 3 days of postoperative hospitalization, which is 2 days shorter than the 5 days in our study [7]. Length of hospital stay, however, depends on social and cultural factors resulting in important differences between countries and continents. Having an identical criteria for hospital discharge for all patients, arthroscopic treatment relevantly reduced hospital stay by 2 days in our setting.

Within the first 6 weeks, pain at rest and during activities of daily living did not differ between HA and SHD. We prescribed different weight-bearing regimens after HA and after SHD, respectively, and this may have interfered with the pain scores recorded. We are not aware of pain records within the first 6 weeks in the literature with which our data could be compared. Nevertheless, after the first 6 weeks period, rehabilitation regimens were the same for both groups and patients treated by SHD reported approximately two- and fivefold higher pain levels at rest and with daily activities than those treated by HA. 1 year after the index procedure, this difference persisted being still twofold higher during daily activities and we are yet not able to report if this difference will persist after a longer follow-up. In terms of other self-administered outcome scores, differences in favor of HA were recorded at 3 months for the subjective hip value (84 vs. 70 %) but disappeared at 1 year. According to the HHS, hip function after SHD remained inferior to hip function after HA even after 1 year (85 vs. 93 points). The comparisons of the clinical short-term results of both techniques with the existing literature are difficult because of the varying outcome measures used [31] and lack of the detailed and continuously recorded results during the first postoperative year. However, the literature provides data with respect to the gain of internal rotation after the impingement surgery. In our population, a benefit of approximately 18° from preoperatively to the 3 months and 1 year follow-up was seen. This benefit of internal rotation is in accordance with Kelly et al [32] reporting an increase from 9.9 to 27.6° postoperatively at 3 months after arthroscopic decompression. However, according to other investigations the gain of internal rotation may be less important or even without significant improvement [33, 34]. Although in these two investigations SHD was performed, we have not seen a significant difference either in absolute postoperative internal rotation or in the gain between the two techniques. A possible explanation for the varying results reported in the literature may be the potential positive influence of limited overcorrection of the deformities or compromising coexisting deformities such as reduced femoral torsion and CCD angle, and a deep acetabulum.

Table 3 Postoperative subjective and clinical parameters

	Arthroscopy					Open surgery					<i>p</i>
	<i>n</i>	Mean	SD	Min	Max	<i>n</i>	Mean	SD	Min	Max	
<i>n</i>	23					15					
Harris hip score											
6 weeks		81.4	14.1	58.0	100.0		55.3	16.7	14.0	82.0	<0.001
3 months		92.2	11.1	65.0	100.0		80.6	16.2	60.0	100.0	0.034
12 months		93.4	11.7	54.0	100.0		84.9	14.0	63.0	100.0	0.027
WOMAC (6 weeks)											
Pain		1.6	1.4	0.0	5.5		2.1	1.8	0.0	4.5	ns
Stiffness		2.5	2.3	0.0	6.0		2.5	2.8	0.0	8.0	ns
ADL		2.2	1.6	0.0	5.0		3.2	1.8	1.0	7.0	ns
Overall		2.0	1.6	0.0	5.6		2.7	1.9	0.5	6.5	ns
WOMAC (3 months)											
Pain		0.7	1.2	0.0	4.0		2.2	2.0	0.0	6.0	0.012
Stiffness		1.2	1.4	0.0	3.8		2.7	2.4	0.0	7.5	0.041
ADL		0.8	1.1	0.0	4.0		2.0	2.0	0.0	5.3	ns
Overall		0.9	1.1	0.0	3.9		2.3	1.9	0.0	5.5	0.024
WOMAC (12 months)											
Pain		0.9	1.2	0.0	3.9		2.3	1.9	0.0	5.5	0.011
Stiffness		1.6	1.9	0.0	6.3		2.6	2.5	0.0	7.5	ns
ADL		0.9	1.8	0.0	7.2		1.9	2.2	0.0	6.0	ns
Overall		1.1	1.5	0.0	5.8		2.3	2.1	0.0	5.2	ns
Pain at rest (VAS)											
6 weeks		6.3	11.1	0.0	30.0		14.7	20.7	0.0	80.0	ns
3 months		2.4	7.4	0.0	30.0		10.0	13.6	0.0	40.0	0.021
12 months		5.5	12.2	0.0	40.0		15.0	22.8	0.0	60.0	ns
Pain during activities of daily living (VAS)											
6 weeks		14.5	14.5	0.0	50.0		20.1	17.8	0.0	70.0	ns
3 months		13.2	17.9	0.0	70.0		24.5	18.6	0.0	50.0	0.034
12 months		10.1	17.4	0.0	55.5		24.3	26.0	0.0	80.0	0.042
Pain during sports activities (VAS)											
3 weeks		18.7	24.0	0.0	80.0		13.6	6.3	5.0	20.0	ns
12 months		15.3	24.5	0.0	100.0		16.4	16.1	0.0	40.0	ns
Level of sports activity											
3 months											
High/intermediate/potentially low/low/none	7/2/3/0/1					1/1/0/3/0					0.033
Incapable	10					10					
12 months											
High/intermediate/potentially low/low/none	10/6/1/0/4					5/3/1/2/0					ns
Incapable	2 ^a					4 ^b					
Subjective hip value (%)											
6 weeks		71.4	17.1	30.0	96.0		47.3	16.2	20.0	70.0	<0.001
3 months		83.7	13.2	50.0	100.0		69.7	19.4	40.0	95.0	0.019
12 months		83.3	16.8	50.0	100.0		73.9	22.9	35.0	100.0	ns
Internal rotation ipsilateral (°)											
3 months		27.6	5.6	15.0	40.0		29.4	6.1	19.0	40.0	ns
12 months		29.6	5.1	20.0	40.0		32.3	5.1	24.0	45.0	ns
Internal rotation contralateral (°)											
3 months		28.2	6.5	19.0	40.0		31.5	6.0	20.0	40.0	ns

Table 3 continued

	Arthroscopy					Open surgery					<i>p</i>
	<i>n</i>	Mean	SD	Min	Max	<i>n</i>	Mean	SD	Min	Max	
12 months		30.6	7.2	20.0	45.0		29.9	5.5	20.0	40.0	ns
Abduction strength ipsilateral (kg)											
3 months		10.1	3.6	3.5	18.5		5.2	2.8	1.7	11.7	<0.001
12 months		10.5	3.5	6.3	18.7		7.8	4.0	2.4	15.6	0.043
Abduction strength contralateral (kg)											
3 months		10.4	4.1	4.2	20.4		8.1	3.1	3.6	15.0	ns
12 months		10.1	3.9	4.2	20.5		8.6	3.1	3.5	13.3	ns

^a One patient incapable related to acute ACL rupture

^b One patient incapable related to acute FAI on the controlateral side

Table 4 Time off work, complications, and revision surgery

	Arthroscopy					Open surgery					<i>p</i>
	<i>n</i>	Mean	SD	Min	Max	<i>n</i>	Mean	SD	Min	Max	
<i>n</i>	23					15					
Inability to work (days)											
Index surgery only		53.8	31.1	12.0	122.0		77.1	35.1	14.0	144.0	0.036
Revision surgery included		53.8	31.1	12.0	122.0		108.9	86.9	22.0	36.0	0.013
Complications											
Transient neuropraxia lateral femoral cutaneous nerve	1										
Revision surgery											
Hardware removal						6					
Arthroscopic adhesiolysis						1					
Time after index procedure (days)							183.9	97.2	96.0	345.0	

Despite comparable work conditions, time off work due to the index procedure was less after arthroscopy (54 days) than after SHD (77 days) and we were able to clearly document a faster recovery after HA. We are not aware of data on ability to work after surgical treatment of FAI in the literature. The higher rate of surgical revisions after SHD (6 hardware removal and 1 adhesiolysis vs. none in the arthroscopy group) additionally increased time off work in this group to 109 days. The need for hardware removal in 40 % of cases after SHD is a well documented disadvantage [31, 35, 36] and as a direct consequence, a markedly higher complication rate in this group was recorded.

On average, return to previous sport activity levels (i.e., levels before onset of symptoms) was not achieved within 1 year in either group. This is inferior to reports on cohorts of professional hockey players, returning after a mean of 9.6 and 3.9 months [11, 20]. However, in terms of overall fitness

and financial pressure to return to the same level of sports activities, the patient population of the present investigation cannot be compared to elite hockey players. In general and from a clinical point of view, our results are in accordance with the systematic review by Botser et al. [31] highlighting that arthroscopy for FAI seems to have the faster rehabilitation rate and a lower complication rate.

The pathological morphology leading to FAI is thought to be responsible for the development of early OA [3, 37] and residual deformities after surgical treatment, while allowing for improvement of patient's symptoms, still may contribute towards early degeneration of the joint. Such residual deformities were on a first view equally avoided after HA and SHD. Nevertheless, in terms of osteochondroplasty, compared to corrections after SHD, the arthroscopic technique significantly removed more bone than necessary in some positions resulting in lower alpha angles.

Table 5 Postoperative morphological parameters

Postoperative	Arthroscopy					Open surgery					<i>p</i>
	<i>n</i>	Mean	SD	Min	Max	<i>n</i>	Mean	SD	Min	Max	
<i>n</i>	23					15					
X-ray											
CE anlge (°)		30	4.8	18.0	37.0	31	6.6	22.0	43.0	ns	
AC index (°)		7	3.5	0.0	16.0	7	3.5	0.0	13.0	ns	
Alpha angle (°)		38	5.0	28.0	53.0	39	2.7	35.0	44.0	ns	
Head–neck offset ratio		0.22	0.05	0.12	0.36	0.21	0.03	0.17	0.28	ns	
COS	7					8					
COS ratio		0.17	0.06	0.09	0.25	0.27	0.13	0.07	0.46	ns	
Resection depth ratio		0.06	0.02	0.03	0.13	0.06	0.03	0.00	0.13	ns	
Sector of resection (°)		41	7.1	20.0	50.0	46	7.8	31.0	60.0	ns	
MRI											
Alpha angle 1 (°)		36	5.2	27.0	49.0	39	4.9	29.0	46.0	ns	
Alpha angle 2 (°)		35	5.5	26.0	48.0	41	5.1	30.0	48.0	0.005	
Alpha angle 3 (°)		35	5.6	26.0	48.0	40	5.3	32.0	52.0	0.012	
Alpha angle 4 (°)		37	5.5	29.0	49.0	42	7.0	35.0	62.0	0.022	
Alpha angle 5 (°)		41	7.0	21.0	54.0	45	7.5	35.0	69.0	ns	
Alpha angle 6 (°)		42	6.1	34.0	53.0	48	8.8	41.0	75.0	0.040	
Alpha angle 7 (°)		43	4.7	33.0	51.0	41	13.0	36.0	62.0	ns	
Head–neck offset ratio 1		0.23	0.05	0.12	0.36	0.23	0.04	0.15	0.29	ns	
Head–neck offset ratio 2		0.23	0.05	0.14	0.36	0.22	0.04	0.14	0.29	ns	
Head–neck offset ratio 3		0.23	0.05	0.14	0.36	0.21	0.03	0.15	0.26	ns	
Head–neck offset ratio 4		0.21	0.05	0.10	0.30	0.18	0.04	0.11	0.23	ns	
Head–neck offset ratio 5		0.19	0.05	0.12	0.28	0.16	0.04	0.09	0.23	ns	
Head–neck offset ratio 6		0.18	0.05	0.06	0.31	0.16	0.03	0.10	0.21	ns	
Head–neck offset ratio 7		0.18	0.03	0.13	0.27	0.18	0.05	0.12	0.33	ns	
Acetabular coverage angle 1 (°)		152	8.9	132.0	165.0	151	8.0	143.0	173.0	ns	
Acetabular coverage angle 2 (°)		156	7.7	145.0	170.0	158	7.5	144.0	175.0	ns	
Acetabular coverage angle 3 (°)		164	6.3	150.0	174.0	167	7.9	152.0	179.0	ns	
Acetabular coverage angle 4 (°)		170	9.9	151.0	188.0	170	7.2	154.0	185.0	ns	
Acetabular coverage angle 5 (°)		151	16.9	119.0	183.0	157	15.2	127.0	182.0	ns	
Acetabular coverage angle 6 (°)		148	7.6	137.0	165.0	150	15.7	128.0	189.0	ns	
Acetabular coverage angle 7 (°)		148	7.6	137.0	165.0	149	8.1	135.0	160.0	ns	
Resection depth ratio 1		0.14	0.04	0.08	0.22	0.11	0.08	0.00	0.24	ns	
Resection depth ratio 2		0.14	0.06	0.04	0.27	0.11	0.08	0.00	0.24	ns	
Resection depth ratio 3		0.14	0.06	0.04	0.26	0.13	0.08	0.00	0.27	ns	
Resection depth ratio 4		0.16	0.08	0.00	0.31	0.14	0.07	0.00	0.27	ns	
Resection depth ratio 5		0.14	0.08	0.04	0.31	0.13	0.07	0.00	0.24	ns	
Resection depth ratio 6		0.09	0.08	0.00	0.23	0.11	0.08	0.00	0.23	ns	
Resection depth ratio 7		0.07	0.07	0.00	0.19	0.07	0.07	0.00	0.20	ns	
Sector of resection 1 (°)		42	9.2	27.0	58.0	38	18.4	0.0	67.0	ns	
Sector of resection 2 (°)		44	8.2	27.0	58.0	40	18.5	0.0	67.0	ns	
Sector of resection 3 (°)		43	9.6	22.0	65.0	41	14.2	0.0	60.0	ns	
Sector of resection 4 (°)		41	8.4	26.0	55.0	42	13.5	0.0	57.0	ns	
Sector of resection 5 (°)		38	7.7	26.0	55.0	36	15.7	0.0	54.0	ns	
Sector of resection 6 (°)		28	18.0	0.0	49.0	28	18.3	0.0	51.0	ns	
Sector of resection 7 (°)		23	19.8	0.0	54.0	25	19.8	0.0	53.0	ns	
Acetabular depth (mm)		7	2.1	2.0	10.0	6	2.5	0.0	10.0	ns	

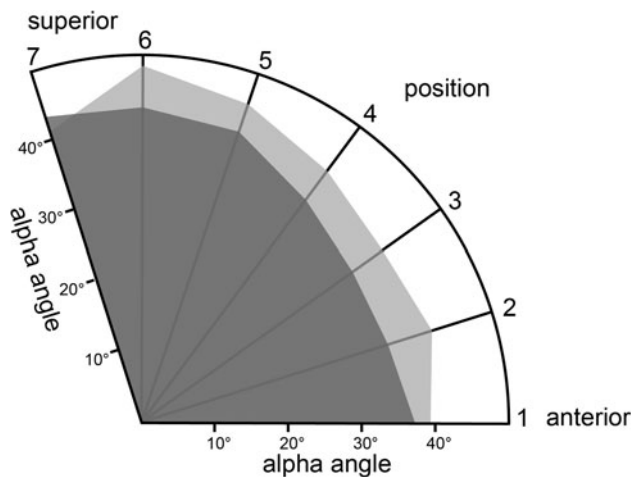


Fig. 4 Average postoperative alpha angles in the seven different positions according to Fig. 2. *Gray* patients after SHD, *black* patients after hip arthroscopy

This overcorrection is unwelcomed since irreversible and may be an issue in terms of joint sealing. Additionally, labral refixations were much less often realized when hip arthroscopy was performed and, due to the loss of sealing effect, eventually will negatively influence long-term outcome [38].

We are not aware of any other published prospective clinical trials comparing the quality of bony correction after arthroscopic surgery with SHD using MRI data. Mardones [21] compared both techniques on cadaver specimens but, because of a very small sample size, statistical analyses were not possible and comparisons remained descriptive.

If hardware removal after SHD is not taken into account, complications occurred once in each group and consisted of a transient neurapraxia of the lateral nerve of the thigh and articular adhesions resulting in arthroscopic adhesiolysis.

The present study has some limitations. It is confined to FAI without any other disturbance of the hip architecture such as might be seen in sequels of childhood hip disease presenting with short necks, high riding greater trochanter, and globally non-spherical heads as well as acetabular retroversion with insufficient posterior wall. Accordingly, the results of the present study are limited to pure FAI. Therefore, SHD as well as other open surgical techniques still should be considered as an important alternatives to hip arthroscopy, especially, when complex hip impingement pathologies are to be treated. Initially designed to be a randomized trial, randomization had to be abandoned because the majority of patients presenting to us declined randomization. Nevertheless, the proportion of patients who declined randomization was similar between the groups, thus minimizing any relevant bias. Second, pre-operative morphological analysis showed some significant differences in terms of the extent of pathologies between

the two groups. Since, some of these differences were in favor of the arthroscopy group and some in favor of the SHD group, we feel that these differences not relevantly or negatively influence our results. Third, other morphological factors potentially favoring FAI such as diminished femoral torsion and low CCD angle were not taken into account but may have influenced clinical manifestation of FAI as well as impingement-free ROM tested during surgery. This may also explain the fact that patients without or with only mild cam morphologies on workup imaging got some osteochondroplasty during surgery and that overcorrection of the cam deformity was judged necessary during intraoperative dynamic testing. Finally, the sample size was just enough in terms of alpha angle measurements but higher numbers of patients would have been advantageous considering all the other recorded morphometric parameters. The popularity of HA forced us to stop the trial since no patients fulfilling our inclusion criteria could be included in the hip dislocation group.

In conclusion, postoperative recovery in terms of hospital stay and time to return to work as well as short-term outcome in terms of pain levels and hip function after HA is superior compared to SHD. However, in terms of overcorrection of the cam deformity and the limited ability to preserve the labrum, both negatively influencing the seal of the hip joint, the arthroscopic technique remained inferior and might be of clinical relevance at long-term. Arthroscopic techniques and skills must be improved to overcome these issues.

Conflict of interest The authors declare that they have no conflict of interest.

References

1. Beck M, Kalhor M, Leunig M, Ganz R (2005) Hip morphology influences the pattern of damage to the acetabular cartilage: femoroacetabular impingement as a cause of early osteoarthritis of the hip. *J Bone Joint Surg Br* 87(7):1012–1018
2. Beck M, Leunig M, Parvizi J, Boutier V, Wyss D, Ganz R (2004) Anterior femoroacetabular impingement: part II. Midterm results of surgical treatment. *Clin Orthop Relat Res* 418:67–73
3. Ganz R, Leunig M, Leunig-Ganz K, Harris WH (2008) The etiology of osteoarthritis of the hip: an integrated mechanical concept. *Clin Orthop Relat Res* 466(2):264–272
4. Ganz R, Parvizi J, Beck M, Leunig M, Notzli H, Siebenrock KA (2003) Femoroacetabular impingement: a cause for osteoarthritis of the hip. *Clin Orthop Relat Res* 417:112–120
5. Leunig M, Beaulieu PE, Ganz R (2009) The concept of femoroacetabular impingement: current status and future perspectives. *Clin Orthop Relat Res* 467(3):616–622
6. Ganz R, Gill TJ, Gautier E, Ganz K, Krugel N, Berlemann U (2001) Surgical dislocation of the adult hip a technique with full access to the femoral head and acetabulum without the risk of avascular necrosis. *J Bone Joint Surg Br* 83(8):1119–1124
7. Leunig M, Beck M, Woo A, Dora C, Kerboull M, Ganz R (2003) Acetabular rim degeneration: a constant finding in the aged hip. *Clin Orthop Relat Res* 413:201–207

8. Clohisy JC, McClure JT (2005) Treatment of anterior femoroacetabular impingement with combined hip arthroscopy and limited anterior decompression. *Iowa Orthop J* 25:164–171
9. Clohisy JC, Zebala LP, Nepple JJ, Pashos G (2010) Combined hip arthroscopy and limited open osteochondroplasty for anterior femoroacetabular impingement. *J Bone Joint Surg Am* 92(8):1697–1706
10. Hartmann A, Gunther KP (2009) Arthroscopically assisted anterior decompression for femoroacetabular impingement: technique and early clinical results. *Arch Orthop Trauma Surg* 129(8):1001–1009
11. Laude F, Sariali E, Nogier A (2009) Femoroacetabular impingement treatment using arthroscopy and anterior approach. *Clin Orthop Relat Res* 467(3):747–752
12. Bardakos NV, Vasconcelos JC, Villar RN (2008) Early outcome of hip arthroscopy for femoroacetabular impingement: the role of femoral osteoplasty in symptomatic improvement. *J Bone Joint Surg Br* 90(12):1570–1575
13. Byrd JW, Jones KS (2009) Arthroscopic femoroplasty in the management of cam-type femoroacetabular impingement. *Clin Orthop Relat Res* 467(3):739–746
14. Ilizaliturri VM Jr, Orozco-Rodriguez L, Acosta-Rodriguez E, Camacho-Galindo J (2008) Arthroscopic treatment of cam-type femoroacetabular impingement: preliminary report at 2 years minimum follow-up. *J Arthroplasty* 23(2):226–234
15. Larson CM, Giveans MR (2008) Arthroscopic management of femoroacetabular impingement: early outcomes measures. *Arthroscopy* 24(5):540–546
16. Philippon MJ, Yen YM, Briggs KK, Kuppersmith DA, Maxwell RB (2008) Early outcomes after hip arthroscopy for femoroacetabular impingement in the athletic adolescent patient: a preliminary report. *J Pediatr Orthop* 28(7):705–710
17. Notzli HP, Wyss TF, Stoecklin CH, Schmid MR, Treiber K, Hodler J (2002) The contour of the femoral head-neck junction as a predictor for the risk of anterior impingement. *J Bone Joint Surg Br* 84(4):556–560
18. Reynolds D, Lucas J, Klaue K (1999) Retroversion of the acetabulum. A cause of hip pain. *J Bone Joint Surg Br* 81(2):281–288
19. Tonnis D, Heinecke A (1999) Acetabular and femoral anteversion: relationship with osteoarthritis of the hip. *J Bone Joint Surg Am* 81(12):1747–1770
20. Byrd JW (1994) Hip arthroscopy utilizing the supine position. *Arthroscopy* 10(3):275–280
21. Mardones R, Lara J, Donndorff A, Barnes S, Stuart MJ, Glick J, Trousdale R (2009) Surgical correction of “cam-type” femoroacetabular impingement: a cadaveric comparison of open versus arthroscopic debridement. *Arthroscopy* 25(2):175–182
22. Kalberer F, Sierra RJ, Madan SS, Ganz R, Leunig M (2008) Ischial spine projection into the pelvis: a new sign for acetabular retroversion. *Clin Orthop Relat Res* 466(3):677–683
23. Pitt MJ, Graham AR, Shipman JH, Birkby W (1982) Herniation pit of the femoral neck. *AJR Am J Roentgenol* 138(6):1115–1121
24. Wiberg G (1939) Studies on dysplastic acetabula and congenital subluxation of the hip joint with special reference to the complication of osteoarthritis. *Acta Chir Scand Suppl* 83:1–130
25. Lequesne M (1963) Coxometry. Measurement of the basic angles of the adult radiographic hip by a combined protractor. *Rev Rhum Mal Osteoartic* 30:479–485
26. Siebenrock KA, Kalbermatten DF, Ganz R (2003) Effect of pelvic tilt on acetabular retroversion: a study of pelvis from cadavers. *Clin Orthop Relat Res* 407:241–248
27. Mardones RM, Gonzalez C, Chen Q, Zobitz M, Kaufman KR, Trousdale RT (2005) Surgical treatment of femoroacetabular impingement: evaluation of the effect of the size of the resection. *J Bone Joint Surg Am* 87(2):273–279
28. Ejer H, Leunig M, Mahomed MN, Ganz R (2001) Cross-table lateral radiographs for screening of anterior femoral head-neck offset in patients with femoroacetabular impingement. *Hip Intern* 11(1):37–41
29. Locher S, Werlen S, Leunig M, Ganz R (2002) MR-Arthrography with radial sequences for visualization of early hip pathology not visible on plain radiographs. *Z Orthop Ihre Grenzgeb* 140(1):52–57
30. Pfirrmann CW, Mengiardi B, Dora C, Kalberer F, Zanetti M, Hodler J (2006) Cam and pincer femoroacetabular impingement: characteristic MR arthrographic findings in 50 patients. *Radiology* 240(3):778–785
31. Botser IB, Smith TW Jr, Nasser R, Domb BG (2011) Open surgical dislocation versus arthroscopy for femoroacetabular impingement: a comparison of clinical outcomes. *Arthroscopy* 27(2):270–278
32. Kelly BT, Bedi A, Robertson CM, Dela Torre K, Giveans MR, Larson CM (2012) Alterations in internal rotation and alpha angles are associated with arthroscopic cam decompression in the hip. *Am J Sports Med* 40(5):1107–1112
33. Naal FD, Miozzari HH, Schar M, Hesper T, Notzli HP (2012) Midterm results of surgical hip dislocation for the treatment of femoroacetabular impingement. *Am J Sports Med* 40(7):1501–1510
34. Kempthorne JT, Armour PC, Rietveld JA, Hooper GJ (2011) Surgical dislocation of the hip and the management of femoroacetabular impingement: results of the Christchurch experience. *ANZ J Surg* 81(6):446–450
35. Beaulé PE, Le Duff MJ, Zaragoza E (2007) Quality of life following femoral head-neck osteochondroplasty for femoroacetabular impingement. *J Bone Joint Surg Am* 89(4):773–779
36. Yun HH, Shon WY, Yun JY (2009) Treatment of femoroacetabular impingement with surgical dislocation. *Clin Orthop Surg* 1(3):146–154
37. Tannast M, Goricki D, Beck M, Murphy SB, Siebenrock KA (2008) Hip damage occurs at the zone of femoroacetabular impingement. *Clin Orthop Relat Res* 466(2):273–280
38. Song Y, Ito H, Kourtis L, Safran MR, Carter DR, Giori NJ (2012) Articular cartilage friction increases in hip joints after the removal of acetabular labrum. *J Biomech* 45(3):524–530