

High expression of peptide receptors as a novel target in gastrointestinal stromal tumours

Jean Claude Reubi¹, Meike Körner¹, Beatrice Waser¹, Luca Mazzucchelli^{1, 2}, Louis Guillou³

¹ Division of Cell Biology and Experimental Cancer Research, Institute of Pathology, University of Berne, Berne, Switzerland

² Institute of Pathology, Locarno, Switzerland

³ Institute of Pathology, University of Lausanne, Lausanne, Switzerland

Received: 4 December 2003 / Accepted: 19 January 2004 / Published online: 18 February 2004

© Springer-Verlag 2004

Abstract. Recent significant advances in understanding the biology of gastrointestinal stromal tumours (GIST) have led to the introduction of a new targeted therapy (imatinib mesylate, Glivec). Hopes of a new era of a specific cancer therapy, however, have been tempered by the recognition that a significant proportion of patients who initially respond to the drug eventually become resistant to it. Given the successful development of peptide receptor scintigraphy and radiotherapy for neuroendocrine tumours, we postulated that a similar approach could offer a valid alternative in the diagnosis and therapy of GIST. Using *in vitro* receptor autoradiography to measure peptide receptors, we found that 16/19 GIST expressed bombesin subtype 2 receptors, 16/19 expressed vasoactive intestinal peptide subtype 2 receptors (VPAC₂) and 12/19 expressed cholecystokinin subtype 2 receptors, in most cases in extremely high densities. All GIST metastases were shown to express two or more of these peptide receptors in very high density. Receptors were also expressed in non-responders to Glivec or after chemoembolisation. Conversely, somatostatin subtype 2, cholecystokinin subtype 1, bombesin subtype 1 and 3, and neuropeptide Y subtype Y₁ and Y₂ receptors were not or only rarely expressed. These data represent a strong molecular basis for the use of radiolabelled bombesin, vasoactive intestinal peptide and/or cholecystokinin analogues as targeting agents to localise GIST tumours in patients by *in vivo* scintigraphy and/or to perform targeted radiotherapy to destroy GIST primaries, metastases and recurrences, including those resistant to Glivec.

Keywords: Gastrointestinal stromal tumours – Cancer targeting – Peptide receptors – Bombesin receptors – Cholecystokinin receptors

Eur J Nucl Med Mol Imaging (2004) 31:803–810

DOI 10.1007/s00259-004-1476-2

Introduction

Gastrointestinal stromal tumours (GIST) have gained increasing interest in the past few years. First, the interstitial cell of Cajal, an intestinal pacemaker cell, has been suggested as the cell of origin of these tumours [1]. Second, the recent recognition that most GIST have a gain-of-function mutation in *KIT* proto-oncogene, resulting in ligand-independent activation of the KIT receptor tyrosine kinase, sheds more light on their pathogenesis [2, 3]. Finally, a small molecule (STI 571, imatinib mesylate, Glivec) used for the treatment of chronic myeloid leukaemia proved to be therapeutically effective in metastatic GIST [4, 5] through selective inhibition of the enzymatic activity of the KIT tyrosine kinase pathway. This latter major clinical advance, however, has been hampered by the recognition that not all patients respond adequately to Glivec, and that many of those who initially respond may become resistant to the treatment after some time [6, 7, 8, 9]. Hence, the identification of alternative therapy modalities for GIST will represent a major challenge for future clinical investigations. In this context, it will also be very important to develop diagnostic tools able to detect small metastases and local recurrences of GIST, thereby allowing treatment of the disease at an early stage.

In recent years, it has been shown that some human cancers can overexpress specific peptide receptors and that these can be targeted for either diagnostic or radiotherapeutic purposes [10]. The best evidence has been provided for somatostatin receptors expressed in neuro-

Jean Claude Reubi (✉)

Division of Cell Biology and Experimental Cancer Research,
Institute of Pathology, University of Berne, Murtenstrasse 31,
PO Box 62, 3010 Berne, Switzerland

e-mail: reubi@pathology.unibe.ch

Tel.: +41-31-6323242, Fax: +41-31-6328999

endocrine tumours, which can currently be targeted with ^{111}In -DTPA-octreotide for their in vivo localisation or with ^{90}Y -DOTATOC for targeted radiotherapy [11]. Indeed, somatostatin receptor scintigraphy was shown to be the diagnostic tool of first choice for a subgroup of gut neuroendocrine tumours, as it was superior to all other conventional imaging methods [12], and radiotherapy with ^{90}Y -DOTATOC appears extremely promising in tumours expressing somatostatin receptors, with more than 25% remissions and about 60% disease stabilisation [13, 14, 15, 16]. More recently, other peptide receptors have emerged as being overexpressed in selected tumours [10] and appear to have a strong in vivo targeting potential. These are bombesin receptors of the BB_2 subtype, better known as gastrin-releasing peptide (GRP) receptors, which are overexpressed in prostate and breast cancers [10] and can be visualised in vivo in these tumours [17, 18]. Also cholecystokinin 2 (CCK_2) receptors expressed in medullary thyroid carcinomas (MTC) [10] can be selectively targeted in vivo [19, 20].

Peptide receptors can also be expressed in normal tissues. Of particular interest in relation to GIST is the fact that somatostatin receptors, vasoactive intestinal peptide (VIP) receptors, GRP receptors and substance P receptors of the NK_1 subtype were found to be expressed in the putative precursor cell of GIST, namely the Cajal cells of the gastrointestinal tract in animals as well as in humans [21, 22]. In the present study we therefore investigated a number of peptide receptors, including the four mentioned above, for their expression in GIST using in vitro receptor autoradiography.

Materials and methods

The peptide receptors investigated in this study include bombesin receptors [with their three subtypes, namely BB_1 (NMB receptors), BB_2 (GRP receptors) and BB_3], VIP receptors (VPAC_1 and VPAC_2 subtypes), CCK_1 and CCK_2 receptors, somatostatin receptors (sst_2 receptors), substance P receptors (NK_1 receptor subtype) and neuropeptide Y (NPY) receptors (Y_1 and Y_2 subtypes). The methodology used is in vitro receptor autoradiography identifying the respective receptor proteins morphologically as specific binding sites. The methods used for the identification of the various receptors and their subtypes were reported in detail previously [23, 24, 25, 26, 27, 28]. Subtype-selective VIP receptor autoradiography was performed using ^{125}I -VIP (2,000 Ci/mmol, Anawa, Wangen, Switzerland) as radioligand with the VPAC_1 -selective [K^{15} , R^{16} , L^{27}]-VIP(1-7)GRP(8-27) and VPAC_2 -selective Ro25-1553 [25]. Subtype-selective CCK receptor autoradiography was performed using ^{125}I -[D-Tyr-Gly, Nle 28,31]-CCK26-33 (^{125}I -CCK; 2,000 Ci/mmol, Anawa, Wangen, Switzerland) as radioligand, displaced with CCK-8 or gastrin to discriminate between CCK_1 and CCK_2 receptors [24]. Subtype-selective bombesin receptor autoradiography was performed using ^{125}I -[D-Tyr 6 , β -Ala 11 , Phe 13 , Nle 14]-bombesin(6-14) (2,000 Ci/mmol, Anawa, Wangen, Switzerland) as radioligand, with unlabelled GRP, NMB and [D-Tyr 6 , β -Ala 11 , Phe 13 , Nle 14]-bombesin(6-14) to discriminate between GRP, NMB and BB_3 receptors [27]. sst_2 receptors were detected with ^{125}I -[Tyr 3]-octreotide (2,000 Ci/mmol, Anawa, Wangen, Switzerland) displaced with the sst_2 -selective ligand L-779-976 [28]. NK_1 receptors were identified with ^{125}I -Bolton-Hunter-SP (2,000 Ci/mmol, Anawa, Wangen, Switzerland) as radioligand and displaced with the NK_1 -selective agonist [Sar 9 , Met(O $_2$) 11]-SP [23]. NPY receptors were detected with ^{125}I -PYY (2,000 Ci/mmol, Anawa, Wangen, Switzerland), using [Leu 31 , Pro 34]-NPY as displacer for Y_1 receptors and PYY(3-36) as displacer for Y_2 recep-

Table 1. Clinicopathologic data on 15 gastrointestinal stromal tumour primaries

Site	Case	Sex	Age (yrs)	Tumour size (cm)	Mitotic index ^a	Tumour necrosis	Tumour grade: NIH Consensus Conference ^b
a) Stomach	1	M	67	6	5	No	Intermediate risk
	2	F	48	7	6	Yes	High risk
	3	F	71	5	16	No	High risk
	4	M	42	8.5	2	No	Intermediate risk
	5	M	59	9	3	No	Intermediate risk
	6	M	69	4	1	No	Very low risk
	7	F	54	0.9	1	No	Very low risk
	8 ^c	F	49	20	54	Yes	High risk
b) Small intestine	9	M	71	3	1	Yes	Low risk
	10	F	78	5	1	Yes	Low risk
	11 ^c	F	49	4	3	No	Low risk
c) Mesentery/epiploon	12	M	69	12	21	No	High risk
	13	M	41	20	76	Yes	High risk
	14 ^c	F	67	21	2	No	High risk
	15 ^c	M	82	23	33	Yes	High risk

^a Number of mitoses/50 hpf (one high-power field: 0.174 mm 2)

^b Reference no. [7]

^c Metastases at diagnosis

Table 2. Receptor data on 19 gastrointestinal stromal tumour primaries (presented in the same order as in Table 1) and metastases

Site	Case	Sex	Age (yrs)	Receptors		VPAC ₂	CCK	NPY ^a		sst ₂	NK ₁
				Bombesin				CCK ₁	CCK ₂		
				GRP	NMB						
1. Primaries											
a) Stomach	1	M	67	1,994 het		4,723	-	13,260	-	347 het	-
	2	F	48	3,002 het		-	-	-	-	-	-
	3	F	71	-		5,501	-	11,464	-	-	-
	4	M	42	2,085	12,316	1,004	1,653	12,512	-	-	-
	5	M	59	1,304 het		10,880	-	11,632	166 (Y1)	-	-
	6	M	69	1,884 het		778	7,478	5,363	827 (Y2)	492	1,212 het
	7	F	54	-		478 het	-	-	952 (Y1)	-	-
	8 ^b	F	49	160 het		650	-	12,962	-	-	-
b) Small intestine	9	M	71	16,827 het		-	-	11,959 het	-	-	-
	10	F	78	31,533		6,265	-	-	-	-	-
	11 ^b	F	49	3,933		1,849	-	534 het	8,013 het (Y2)	129 het	-
c) Mesentery/epiploon	12	M	69	-		705	-	-	-	1,045 het	203
	13	M	41	7,171 het		2,538	-	774	-	-	-
	14 ^b	F	67	192 het		-	-	-	-	-	-
	15 ^b	M	82	24,467		522	-	-	-	-	-
2. Metastases											
a) Lymph node	16	F	73	3,640		7,079	-	12,020	-	-	-
b) Liver	17 ^c	M	42	18,184		5,787	-	747	-	-	1,663 het
	18	F	21	1,142 het		3,698	-	10,459	2,598 (Y1)	-	940
c) Peritoneum	19 ^d	F	41	8,329		5,242	6,826	-	-	-	-

Numbers represent receptor density in each tumour expressed as dpm/mg tissue

-, Receptor negative; het, heterogeneous receptor distribution

^a Y1 and Y2 indicate the predominant NPY receptor subtype present in the tumour^b Metastases at diagnosis^c Chemo-embolisation prior to sampling^d Glivec therapy prior to sampling

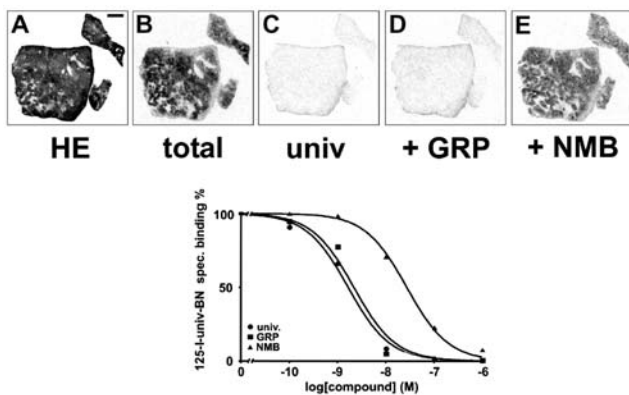


Fig. 1A–E. Characterisation of GRP receptors (BB_2) in GIST. **A** Haematoxylin-eosin stained section. *Bar*=1 mm. **B** Autoradiogram showing total binding of ^{125}I -[D-Tyr⁶, β -Ala¹¹, Phe¹³, Nle¹⁴]-BN(6-14). **C** Autoradiogram showing non-specific binding in the presence of 50 nM of unlabelled [D-Tyr⁶, β -Ala¹¹, Phe¹³, Nle¹⁴]-bombesin(6-14), as universal ligand. **D** Autoradiogram showing ^{125}I -[D-Tyr⁶, β -Ala¹¹, Phe¹³, Nle¹⁴]-BN(6-14) binding in the presence of 50 nM GRP. Full displacement is observed. **E** Autoradiogram showing ^{125}I -[D-Tyr⁶, β -Ala¹¹, Phe¹³, Nle¹⁴]-BN(6-14) binding in the presence of 50 nM NMB. Only weak displacement is seen. *Bottom part:* Complete displacement curves in a GRP receptor-expressing GIST. ^{125}I -[D-Tyr⁶, β -Ala¹¹, Phe¹³, Nle¹⁴]-BN(6-14) is displaced by nanomolar concentrations of the unlabelled analogue (●). Moreover, GRP (■) displaces the radioligand with high affinity while NMB (▲) is much less active

tors [26]. In all experiments, the autoradiograms were quantified using a computer-assisted image processing system, as described previously [25, 26]. Radiolabelled tissue sections were exposed to ^3H -Hyperfilms together with standards (Autoradiographic [^{125}I]microscales, Amersham) that contained known amounts of isotope, cross-calibrated to tissue-equivalent ligand concentration. The image analyser was calibrated to the standards; it performed interpolation to read values that lay between those of the film standards. A tumour was considered as receptor-positive when the optical density measured over a tissue area in the total binding section was at least twice that of the non-specific binding section. In the present study, 19 frozen GIST samples were analysed (Tables 1, 2). The clinical data of the patients and the tumour characteristics are listed in Table 1.

Results

All GIST tested in this study expressed peptide receptors. Three of these peptide receptors, namely GRP (BB_2) receptors, VPAC_2 receptors and CCK_2 receptors, were found with a very high incidence in these tumours (Table 2). GRP receptors were found in 16/19 cases, VPAC_2 receptors were expressed in 16/19 tested cases and CCK_2 receptors were found in 12/19 cases, whereas CCK_1 receptors were present in only 3/19 cases. The extraordinarily high density of all three receptors was remarkable, with densities above 2,000 dpm/mg tissue being observed for GRP receptors in 10/19 tumours, for

VPAC₂ receptors

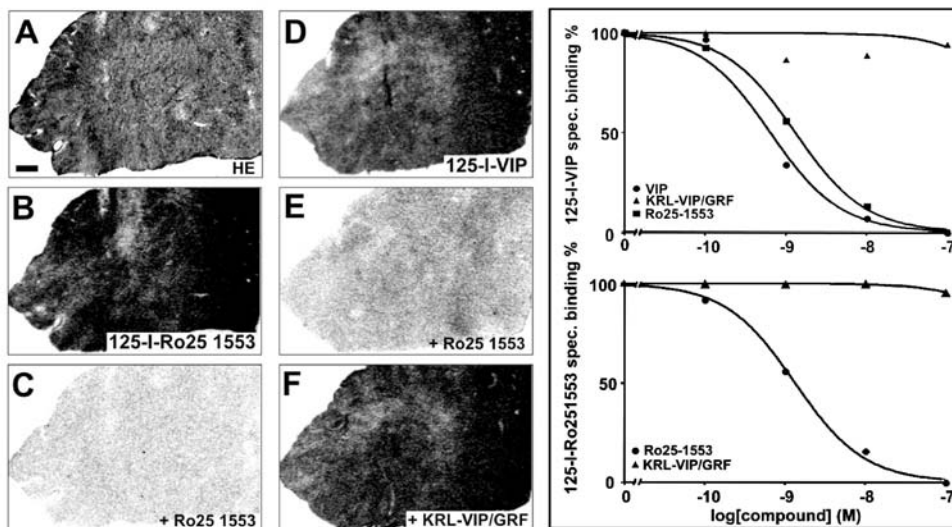


Fig. 2A–F. Characterisation of VPAC_2 receptors in GIST. Receptor autoradiography showing a tumour (**A** haematoxylin-eosin stained section, *bar*=1 mm) expressing VPAC_2 , measured either with the VPAC_2 -selective radioligand ^{125}I -Ro25-1553 (**B** total binding; **C** non-specific binding (in the presence of 20 nM unlabelled Ro25-1553)] or with the universal radioligand ^{125}I -VIP (**D** total binding) displaced by 20 nM of Ro25-1553 (**E**) but not by

20 nM of the VPAC_1 -selective KRL-VIP/GRF (**F**). The two graphs on the right show complete displacement curves either with ^{125}I -VIP as universal ligand (*upper graph*) displaced with nanomolar concentrations of VIP (●) and Ro25-1553 (■) but not KRL-VIP/GRF (▲), or with ^{125}I -Ro25-1553 (*lower graph*) displaced by Ro25-1553 (●) but not by KRL-VIP/GRF (▲)

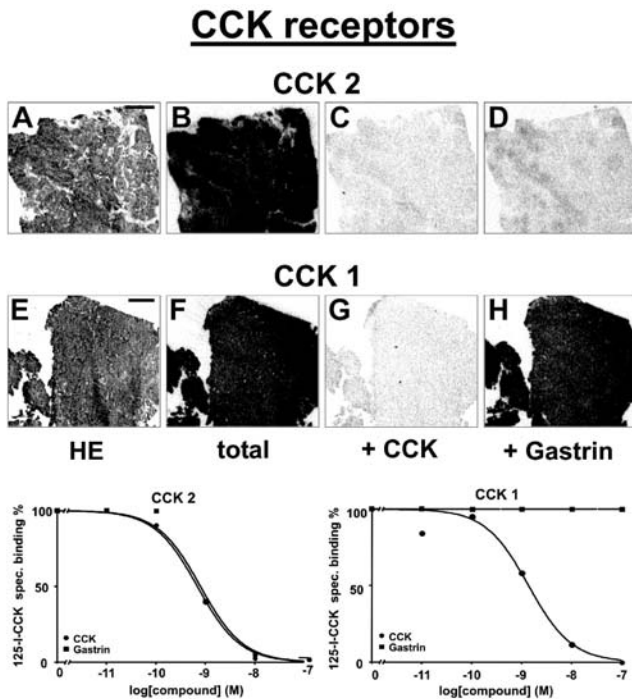


Fig. 3A–H. Characterisation of CCK receptors in GIST. *Upper part:* Receptor autoradiography of a CCK₂ receptor-expressing (A–D) and a CCK₁ receptor-expressing (E–H) GIST. A, E Haematoxylin-eosin stained sections. Bars = 1 mm. B, F Autoradiograms showing total binding of ¹²⁵I-CCK. C, G Autoradiograms showing binding of ¹²⁵I-CCK in the presence of 50 nM CCK. Full displacement is seen in both cases. D, H Autoradiograms showing binding of ¹²⁵I-CCK in the presence of 50 nM gastrin. Displacement is seen in D, but not in H, indicating CCK₂ receptors in the upper case and CCK₁ in the lower case. *Bottom part:* Complete displacement curves in a CCK₂-expressing (left) and a CCK₁-expressing (right) GIST. In both cases, ¹²⁵I-CCK was displaced by nanomolar concentrations of CCK (●), whereas it was displaced by gastrin (■) only in the left case

VPAC₂ receptors in 9/19 tumours and for CCK₂ receptors in 9/19 tumours. In 16/19 tested GIST (84%), at least one of these receptors was expressed with a very high density. In many cases, the measured densities of GRP, VPAC₂ and/or CCK₂ receptors reached levels higher than those usually found for the somatostatin receptors in neuroendocrine gastroenteropancreatic tumours [28]. Conversely, sst₂ receptors, NK₁ receptors, NMB (BB₁), BB₃ and NPY receptors were found only rarely in GIST, and, if present, usually in low to moderate density. Compared with VPAC₂, VPAC₁ was rarely expressed, and then only in low amounts. Furthermore, as reported previously for other tumour types, vessels expressing one or several peptide receptors, in particular NK₁ or/and NPY receptors, were frequently found in GIST. Figures 1, 2 and 3 show examples of tumours expressing some of the most frequently found peptide receptors in GIST, namely GRP, VPAC₂ and CCK receptors. Figure 1

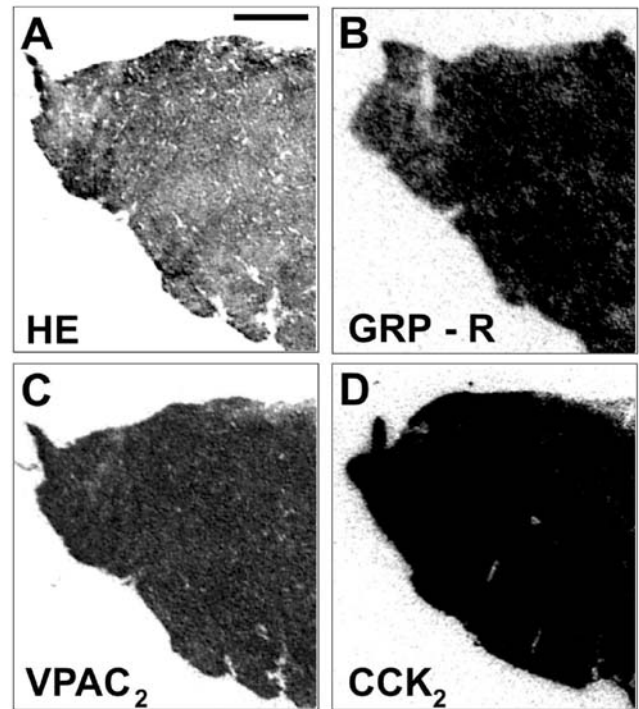


Fig. 4A–D. GIST (A haematoxylin-eosin stained section, bar = 1 mm) expressing concomitantly a high density of GRP receptors (B autoradiogram showing total binding of ¹²⁵I-[D-Tyr⁶, β-Ala¹¹, Phe¹³, Nle¹⁴]-bombesin(6-14)), VPAC₂ receptors (C autoradiogram showing total binding of ¹²⁵I-Ro25-1553) and CCK₂ (D autoradiogram showing total binding of ¹²⁵I-CCK). Full displacement was seen with the respective subtype-selective analogues (data not shown)

shows an example of a tumour expressing GRP receptors (BB₂). Figure 2 is an example of a tumour expressing a high density of VPAC₂ receptors. Figure 3 illustrates two tumours having CCK receptors, one with CCK₂, the other with CCK₁ expression. In all examples, the pharmacological characteristics of the various receptors are also presented in competition experiments. Figure 4 shows a typical example of a GIST expressing concomitantly the three receptors, GRP, VPAC₂ and CCK₂.

No correlations were found between receptor status and any of the listed tumour characteristics, such as tumour size, mitotic index or presence of tumour necrosis (Tables 1, 2). There was no correlation between the receptor expression and the tumour localisation. However, it should be mentioned that peptide receptors could be identified in primary GIST in all locations, namely stomach, small intestine and mesentery. It is, moreover, important to note that all GIST metastases expressed concomitantly at least two of the peptide receptors in very high amounts. Finally, it should be stressed that the two patients with a terminal condition that had been treated prior to sampling (case 19 with Glivec, case 17 with chemo-embolisation) both retained a very high density of several peptide receptors (Table 2).

Discussion

We report for the first time that GIST express high levels of peptide receptors. These results may have an important and immediate clinical impact. It should indeed be possible to take advantage of the expression of these receptors to target GIST *in vivo*. Two different strategies should be considered: first, the development of *in vivo* receptor targeting of GIST for diagnostic purposes, namely for the precise localisation and the early detection of GIST recurrences and metastases, which still represent a difficult clinical problem, especially after anti-tyrosine kinase receptor therapy. Second, the development of peptide receptor radiotherapy, either as an alternative to Glivec or as an adjuvant treatment, for cases not responding or developing resistance to this drug. Peptide receptor targeting of GIST for diagnostic purposes could be successful in the relatively near future since the basic methods have already been developed and are available for two of the three peptide receptors most often expressed in GIST. There is indeed good evidence that GRP receptor-positive tumours can be localised *in vivo* with radiolabelled bombesin analogues. Van de Wiele et al. [17] were the first to report the visualisation of breast cancer; Scopinaro et al. [18] detected small prostate cancer metastases with this method. Moreover, CCK₂ receptor-positive medullary thyroid carcinomas (MTC) were successfully visualised with radiolabelled gastrin or CCK analogues [19, 20]. The fact that GIST express a density of CCK₂ receptors much higher than MTC, and a density of GRP receptors equal to or higher than prostate and breast cancers, is a strong argument for predicting successful visualisation of the smallest GIST recurrences and metastases. Finally, methods for peptide receptor radiotherapy have been developed that could be applied to GIST. The best evidence has been provided by the somatostatin receptor radiotherapy of neuroendocrine tumours using radiolabelled octreotide derivatives; studies from various centres agree on a 25% remission rate and a 60% stabilisation rate for somatostatin receptor-expressing neuroendocrine tumours using current protocols [11, 14, 15, 16]. Moreover, in a small series of MTC patients, CCK₂ receptor radiotherapy was also found to be successful [29]. Although there is as yet no *in vivo* evidence of successful VPAC₂ targeting of human cancers, specific VPAC₂ analogues are available [30] which should be developed as radioligands in order to take advantage of the very large number of VPAC₂ in GIST. Such VPAC₂ receptor scintigraphy may, compared with VIP receptor scintigraphy using ¹²⁵I-VIP, be characterised by a much lower background of normal organs, most frequently expressing VPAC₁ receptors [10]. Ultimately, if successful at a single level, one may try multi-receptor targeting [10, 28] as a potentially more powerful strategy, including CCK₂ receptor targeting in combination with GRP receptor targeting, and, once developed for clinical use, with VPAC₂ targeting.

With respect to the utilisation of the radiolabelled compounds for diagnosis and therapy, an appropriate assessment of the tumour to background ratio for the respective receptors should be helpful. Such an assessment is, however, difficult in the gastrointestinal tract, since the background consists, in this complex organ, of several different kinds of normal tissue (mucosa, muscles, nerves, immune cells) with a distinct peptide receptor expression that may also differ from one gut area to the other. Based on *in vitro* data, the following can be stated: VPAC₂ are primarily distributed in the gut smooth muscles and vessels [21], but not in the mucosa, which expresses VPAC₁ [25]. CCK₂ receptors are located in the smooth muscles and mucosa, very predominantly in the stomach [21, 31]. GRP receptors are located in the gut smooth muscles and nerves, but not in the mucosa [21]. Although the receptor density reaches significant levels in selected normal human tissues (e.g. CCK₂ in stomach), GIST tumours appear in general to express a higher density of the respective receptors. Furthermore, according to recent *in vivo* targeting studies in humans, the presence of peptide receptors in the normal gastrointestinal tract does not seem to affect significantly the scintigraphic evaluation, an exception being the CCK₂ receptors in the stomach: With ¹²³I-VIP scintigraphy (identifying VPAC₁ and VPAC₂), no clinically relevant uptake of the tracer was obtained in the normal intestinal mucosa [32], while using CCK₂ receptor scintigraphy, strong uptake was detected in the stomach but not in other parts of the gastrointestinal tract [33]. GRP receptor scintigraphy with ^{99m}Tc-RP527 did not identify specific uptake in the intestines, although enterohepatic clearance of this tracer affected the interpretation of the scans at this level [17, 34].

The fact that the cells of origin of GIST, the Cajal cells [1], express several of these receptors in physiological conditions is a possible explanation for the expression of these receptors in GIST. It remains unclear, however, why the GRP receptors, the VPAC₂ receptors and the CCK₂ receptors are expressed in such a high incidence and amount, whereas other receptors, also expressed in Cajal cells, such as the sst₂ and NK₁ receptors, are only occasionally found in these tumours.

The very strong expression of three peptide receptors in GIST also has potential biological implications. First, GRP, VPAC₂ and CCK₂ receptors can be added to the number of known biological markers characterising this type of tumour. Second, knowing the strong growth-stimulating properties of GRP, VIP and CCK [35, 36], it is possible that all three peptides influence GIST growth through their respective receptors. Thus, in addition to activating mutations in the KIT receptor tyrosine kinase, and to the recently characterised activating mutations in the platelet-derived growth factor receptor [37], overexpression of peptide receptors may also have a significant pathogenetic role in the progression of GIST.

In conclusion, our *in vitro* study shows that most GIST express GRP, VPAC₂ and/or CCK₂ receptors. Al-

though it is clear that successful in vivo application of the present data will also depend on a variety of additional criteria [38, 39], the present receptor data predict that radiolabelled bombesin, vasoactive intestinal peptide and/or cholecystokinin analogues could be used as targeting agents to localise GIST in patients by scintigraphy. They also suggest that targeted radiotherapy with these radiolabelled peptides may offer an effective alternative to GIST treatment.

Acknowledgement. We thank Dr. P. Robberecht, Brussels, for the gift of Ro25-1553 and KRL-VIP/GRF. We also thank Mrs. R. Rehmann and V. Eltschinger, Berne, for excellent technical assistance, and Dr. Hanifa Bouzourene for her help in selecting the GIST cases.

References

- Kindblom LG, Remotti HE, Aldenborg F, Meis-Kindblom JM. Gastrointestinal pacemaker cell tumor (GIPACT): gastrointestinal stromal tumors show phenotypic characteristics of the interstitial cells of Cajal. *Am J Pathol* 1998; 152:1259–1269.
- Hirota S, Isozaki K, Moriyama Y, Hashimoto K, Nishida T, Ishiguro S, Kawano K, Hanada M, Kurata A, Takeda M, Muhammad Tunio G, Matsuzawa Y, Kanakura Y, Shinomura Y, Kitamura Y. Gain-of-function mutations of c-kit in human gastrointestinal stromal tumors. *Science* 1998; 279:577–580.
- Rubin BP, Singer S, Tsao C, Duensing A, Lux ML, Ruiz R, Hibbard MK, Chen CJ, Xiao S, Tuveson DA, Demetri GD, Fletcher CD, Fletcher JA. KIT activation is a ubiquitous feature of gastrointestinal stromal tumors. *Cancer Res* 2001; 61: 8118–8121.
- Joensuu H, Roberts PJ, Sarlomo-Rikala M, Andersson LC, Tervahartiala P, Tuveson D, Silberman S, Capdeville R, Dimitrijevic S, Druker B, Demetri GD. Effect of the tyrosine kinase inhibitor STI571 in a patient with a metastatic gastrointestinal stromal tumor. *N Engl J Med* 2001; 344:1052–1056.
- van Oosterom AT, Judson I, Verweij J, Stroobants S, Donato di Paola E, Dimitrijevic S, Martens M, Webb A, Sciot R, Van Glabbeke M, Silberman S, Nielsen OS. Safety and efficacy of imatinib (STI571) in metastatic gastrointestinal stromal tumours: a phase I study. *Lancet* 2001; 358:1421–1423.
- Demetri GD, von Mehren M, Blanke CD, Van den Abbeele AD, Eisenberg B, Roberts PJ, Heinrich MC, Tuveson DA, Singer S, Janicek M, Fletcher JA, Silverman SG, Silberman SL, Capdeville R, Kiese B, Peng B, Dimitrijevic S, Druker BJ, Corless C, Fletcher CD, Joensuu H. Efficacy and safety of imatinib mesylate in advanced gastrointestinal stromal tumors. *N Engl J Med* 2002; 347:472–480.
- Fletcher CD, Berman JJ, Corless C, Gorstein F, Lasota J, Longley BJ, Miettinen M, O'Leary TJ, Remotti H, Rubin BP, Shmookler B, Sobin LH, Weiss SW. Diagnosis of gastrointestinal stromal tumors: a consensus approach. *Hum Pathol* 2002; 33:459–465.
- Barthe C, Cony-Makhoul P, Melo JV, Mahon JR. Roots of clinical resistance to STI-571 cancer therapy. *Science* 2001; 293:2163.
- von Mehren M, Blanke CD, Joensuu H. High incidence of durable responses induced by imatinib mesylate (imatinib) in patients with unresectable and metastatic gastrointestinal stromal tumors. *Proc Am Soc Clin Oncol* 2002; 21:abstract 1608.
- Reubi JC. Peptide receptors as molecular targets for cancer diagnosis and therapy. *Endocr Rev* 2003; 24:389–427.
- Kwekkeboom DJ, Krenning EP, de Jong M. Peptide receptor imaging and therapy. *J Nucl Med* 2000; 41:1704–1713.
- Gibril F, Reynolds JC, Doppman JL, Chen CC, Venzon DJ, Termanini B, Weber HC, Stewart CA, Jensen RT. Somatostatin receptor scintigraphy: its sensitivity compared with that of other imaging methods in detecting primary and metastatic gastrinomas. *Ann Intern Med* 1996; 125:26–34.
- Valkema R, Jamar F, Jonard P, Bakker WH, Norenberg J, Hadley J, Smith C, Kvols L, Pauwels S, Krenning EP. Targeted radiotherapy with ⁹⁰Y-SMT487 (Octreo Ther): a phase I study [abstract]. *J Nucl Med* 2000; 41 (suppl):111P.
- Waldherr C, Pless M, Maecke HR, Haldemann A, Mueller-Brand J. The clinical value of [⁹⁰Y-DOTA]-D-Phe¹-Tyr³-octreotide (⁹⁰Y-DOTATOC) in the treatment of neuroendocrine tumours: a clinical phase II study. *Ann Oncol* 2001; 12:941–945.
- Paganelli G, Zoboli S, Cremonesi M, Bodei L, Ferrari M, Grana C, Bartolomei M, Orsi F, De Cicco C, Macke HR, Chinol M, de Braud F. Receptor-mediated radiotherapy with ⁹⁰Y-DOTA-D-Phe¹-Tyr³-octreotide. *Eur J Nucl Med* 2001; 28: 426–434.
- Kwekkeboom DJ, Bakker WH, Kam BL, Teunissen JJM, Kooij PP, Herder WW, Feelders RA, Eijck CHJ, Jong M, Srinivasan A, Erion JL, Krenning EP. Treatment of patients with gastro-entero-pancreatic (GEP) tumours with the novel radiolabelled somatostatin analogue [¹⁷⁷Lu-DOTA⁰,Tyr³]-octreotate. *Eur J Nucl Med Mol Imaging* 2003; 30:417–422.
- Van de Wiele C, Dumont F, Vanden Broecke R, Oosterlinck W, Cocquyt V, Serreyn R, Peers S, Thornback J, Slegers G, Dierckx RA. Technetium-99m RP527, a GRP analogue for visualisation of GRP receptor-expressing malignancies: a feasibility study. *Eur J Nucl Med* 2000; 27:1694–1699.
- Scopinaro F, De Vincentis G, Varvarigou AD, Laurenti C, Iori F, Remediani S, Chiarini S, Stella S. ^{99m}Tc-bombesin detects prostate cancer and invasion of pelvic lymph nodes. *Eur J Nucl Med Mol Imaging* 2003; 30:1378–1382.
- Behr TM, Jenner N, Behe M, Angerstein C, Gratz S, Raue F, Becker W. Radiolabeled peptides for targeting cholecystokinin-B/gastrin receptor-expressing tumors. *J Nucl Med* 1999; 40:1029–1044.
- Kwekkeboom DJ, Bakker WH, Kooij PP, Erion J, Srinivasan A, de Jong M, Reubi JC, Krenning EP. Cholecystokinin receptor imaging using an octapeptide DTPA-CCK analogue in patients with medullary thyroid carcinoma. *Eur J Nucl Med* 2000; 27:1312–1317.
- Rettenbacher M, Reubi J. Localization and characterization of neuropeptide receptors in human colon. *Naunyn-Schmiedebergs Arch Pharmacol* 2001; 364:291–304.
- Sternini C, Wong H, Wu V, de Giorgio R, Yang M, Reeve J Jr, Brecha NC, Walsh JH. Somatostatin 2A receptor is expressed by enteric neurons, and by interstitial cells of cajal and enterochromaffin-like cells of the gastrointestinal tract. *J Comp Neurol* 1997; 386:396–408.
- Hennig IM, Laissue JA, Horisberger U, Reubi JC. Substance P receptors in human primary neoplasms: tumoural and vascular localisation. *Int J Cancer* 1995; 61:786–792.
- Reubi JC, Schaer JC, Waser B. Cholecystokinin(CCK)-A and CCK-B/gastrin receptors in human tumors. *Cancer Res* 1997; 57:1377–1386.
- Reubi JC, Läderach U, Waser B, Gebbers J-O, Robberecht P, Laissue JA. Vasoactive intestinal peptide/pituitary adenylate

- cyclase-activating peptide receptor subtypes in human tumors and their tissues of origin. *Cancer Res* 2000; 60: 3105–3112.
26. Reubi JC, Gugger M, Waser B, Schaer JC. Y1-mediated effect of neuropeptide Y in cancer: breast carcinomas as targets. *Cancer Res* 2001; 61:4636–4641.
 27. Reubi JC, Wenger S, Schmuckli-Maurer J, Schaer JC, Gugger M. Bombesin receptor subtypes in human cancers: detection with the universal radioligand (¹²⁵I)-[D-TYR(6), beta-ALA(11), PHE(13), NLE(14)] Bombesin(6–14). *Clin Cancer Res* 2002; 8:1139–1146.
 28. Reubi JC, Waser B. Concomitant expression of several peptide receptors in neuroendocrine tumors as molecular basis for in vivo multireceptor tumor targeting. *Eur J Nucl Med Mol Imaging* 2003; 30:781–793.
 29. Behr TM, Béhé MP, Angerstein C, Hüfner M, Becker W. Cholecystokinin (CCK)-B/gastrin-receptor binding peptides for diagnosis and therapy of metastatic medullary thyroid cancer. *J Nucl Med* 2001; 42 Suppl:157P, No.587.
 30. Gourlet P, Vertongen P, Vandermeers A, Vandermeers-Piret MC, Rathe J, de Neef P, Waelbroeck M, Robberecht P. The long-acting vasoactive intestinal polypeptide agonist RO 25-1553 is highly selective of the VIP2 receptor subclass. *Peptides* 1997; 18:403–408.
 31. Reubi JC, Waser B, Läderach U, Stettler C, Friess H, Halter F, Schmassmann A. Localization of cholecystokinin A and cholecystokinin B/gastrin receptors in the human stomach and gallbladder. *Gastroenterology* 1997; 112:1197–1205.
 32. Raderer M, Kurtaran A, Hejna M, Vorbeck F, Angelberger P, Scheithauer W, Virgolini I. ¹²³I-labelled vasoactive intestinal peptide receptor scintigraphy in patients with colorectal cancer. *Br J Cancer* 1998; 78:1–5.
 33. Behr TM, Behe MP. Cholecystokinin-B/gastrin receptor-targeting peptides for staging and therapy of medullary thyroid cancer and other cholecystokinin-B receptor-expressing malignancies. *Semin Nucl Med* 2002; 32:97–109.
 34. Van De Wiele C, Dumont F, Dierckx RA, Peers SH, Thornback JR, Slegers G, Thierens H. Biodistribution and dosimetry of (^{99m}Tc)-RP527, a gastrin-releasing peptide (GRP) agonist for the visualization of GRP receptor-expressing malignancies. *J Nucl Med* 2001; 42:1722–1727.
 35. Moody TW, Chan D, Fahrenkrug J, Jensen RT. Neuropeptides as autocrine growth factors in cancer cells. *Curr Pharm Des* 2003; 9:495–509.
 36. Baldwin GS. The role of gastrin and cholecystokinin in normal and neoplastic gastrointestinal growth. *J Gastroenterol Hepatol* 1995; 10:215–232.
 37. Heinrich MC, Corless CL, Duensing A, McGreevey L, Chen CJ, Joseph N, Singer S, Griffith DJ, Haley A, Town A, Demetri GD, Fletcher CD, Fletcher JA. PDGFRA activating mutations in gastrointestinal stromal tumors. *Science* 2003; 299:708–710.
 38. Heppeler A, Froidevaux S, Eberle AN, Maecke HR. Receptor targeting for tumor localisation and therapy with radiopeptides. *Curr Med Chem* 2000; 7:971–994.
 39. Riccabona G, Decristoforo C. Peptide targeted imaging of cancer. *Cancer Biother Radiopharm* 2003; 18:675–687.