

Gonococcal Tonsillar Infection – A Case Report and Literature Review

C. Balmelli, H.F. Günthard

Abstract

Oral gonococcal infection is an uncommon but well-described manifestation of gonococcal infection, usually described as pharyngitis in the literature. Tonsillitis is much rarer and its role in the clinical presentation in oral gonorrhoea is less clear. We describe a case of oral gonorrhoea presenting with tonsillitis and a discrete cervical lymphadenopathy and present a review of the literature from 1961 to 2002. Of the 512 reported cases of oral gonococcal infection, only 61 have been described to be tonsillitis. The tonsils were invariably enlarged and infected. A whitish-yellow exudate in the cryptae was described in 12 cases (20.6%). Fever and cervical lymphadenopathy appear to be rather uncommon, since they have been described in only five (8.2%) and six (9.3%) of the 61 patients with tonsillitis, respectively. Gonococcal tonsillitis should be included in the differential diagnosis of tonsillitis in sexually active patients.

Infection 2003; 31: 362–365
DOI 10.1007/s15010-003-4003-7

Introduction

Infection of the oropharynx following oral sexual intercourse was first postulated by *Desruelles* (1836) and *Hölder* (1851), well before *Albert Neisser* discovered the gonococcus.

Up to 1934, and especially during the 1960s and 1970s, several cases of oral gonococcal infection were reported, generally described as “pharyngitis.” Occasionally, various manifestations such as gingivitis [1], tonsillitis [2, 5, 9, 10, 13, 14], stomatitis and glossitis [1] were described.

Surprisingly, little or no attention was given to the features of the tonsils in the oral gonococcal infection and the few reported cases have all been published after 1961.

Some confusion persists in the literature with regard to the role of tonsillitis in oral gonococcal infection. Is tonsillitis an uncommon presentation of oral gonorrhoea or is it a major manifestation that was generically included in the term “pharyngitis” used in most of the described cases without further specification? Furthermore, clinical and

anatomical features of gonococcal tonsillitis were hardly described and images of gonococcal tonsillitis were not found in our literature search.

For this reason, we report a case of gonococcal tonsillitis and discuss its clinical features by reviewing the literature.

Case Report

A 25-year-old previously healthy homosexual man attended our infectious disease outpatient clinic requesting an HIV screening test. He had had unprotected oral and anal sexual intercourse with a one-time partner of unknown HIV status 6 days before. The last HIV screening was performed in 1998 and was negative. Specific questions regarding a potential acute retroviral syndrome revealed that the patient had suffered a sore throat during the preceding 3 days in the absence of fever.

Physical examination revealed a temperature of 36.6 °C. Both tonsils, in particular the right one, were enlarged and reddened and cryptae were partially covered with a yellow, suppurative-looking mass (Figure 1). The posterior wall of the pharynx was also reddened. A discrete bilateral cervical lymphadenopathy was also noted. The remaining physical examination was unremarkable.

Laboratory values of interest were as follows: hemoglobin 13.0 g/dl (normal level 13.5–17.5), WBC count 9,140/μl (normal level 3,000–9,600), neutrophil count 6,780/μl (normal level 1,400–8,000), lymphocyte count 1,380/μl (normal level 1,500–4,000), C-reactive protein 12 mg/l (normal level < 5), lactate dehydrogenase 422 U/l (normal level 150–420); the remainder of the chemistry panel was normal. HIV-1 and 2 serology, HIV-p24 antigen and HIV-RNA were negative.

A Gram stain of a tonsillar swab showed intracellular gram-negative diplococci (Figure 2). Ligase chain reaction (LCR) (Roche cobas amplicor, Roche, Switzerland) for *Neisseria gonorrhoeae* and *Chlamydia trachomatis* became positive for *N. gonorrhoeae*; LCR from the urethral swabs remained negative for both organisms. Empiric treatment for gonococci and chlamydiae was initiated with azythromycin 1,000 mg and ciprofloxacin 500 mg single-dose based on the Gram stain before LCR results were available. Five days later we saw the patient again. He no longer had a

C. Balmelli (corresponding author), H.F. Günthard

Division of Infectious Diseases and Hospital Epidemiology, Dept. of Medicine, University Hospital Zürich, Rämistr. 100, CH-8091 Zürich, Switzerland; Phone: (+41/12) 55-3322, Fax: -3291, e-mail:carlo.balmelli@usz.ch

Received: January 27, 2003 • Revision accepted: March 20, 2003

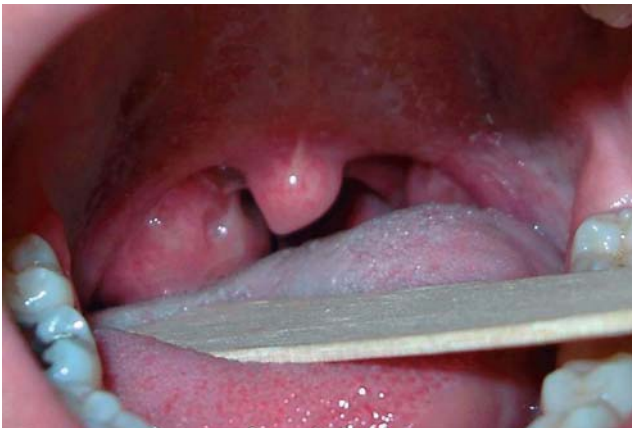

Figure 1. Acute exudative tonsillitis with a whitish-yellow exudate.

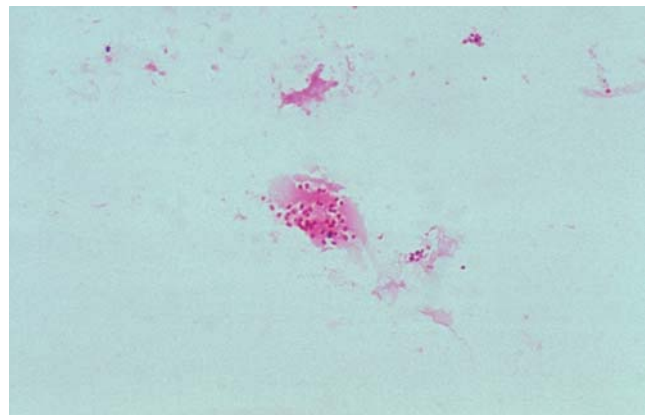


Figure 2. Gram stain of a tonsillar swab showing gram-negative diplococci.

sore throat. The tonsils were less swollen, the suppurative material had disappeared, yet the tonsils were still slightly enlarged. The cervical lymph nodes were no longer enlarged. The patient did not present for a follow-up visit 3 months later for repeating the HIV serology.

Discussion

Here we present a rarely observed case of acute exudative tonsillitis caused by *N. gonorrhoeae*. It is well known that gonococci can cause pharyngitis, but symptoms are often lacking [14]. The fact that gonococci can cause exudative tonsillitis is not well known and explains why this specific clinical manifestation of oral gonococcal disease is often not mentioned in the differential diagnosis of tonsillitis in standard textbooks such as *Mandell's "Principles and Practice of Infectious Disease"* (5th edition) and *Armstrong's "Infectious Diseases"* (1st edition). Of the 512 cases of oral gonorrhoea reported in the literature between 1961 and 2003, only 61 were specified as tonsillitis (Table 1). It is important to point out that in many of the studies, particularly in the larger ones such as those of *Wiesner et al.* [14] and *Stolz et al.* [16], oral gonorrhoea was described only as pharyngitis, without specifying whether the tonsils were also involved. Thus, it remains unclear whether tonsillitis was to some extent also subsumed under the term pharyngitis. Of the 61 cases of gonococcal tonsillitis summarized in table 1, 39 (64%) were reported to be symptomatic, mainly with sore throat. The prevalence of symptoms seems to be slightly higher in tonsillitis than in cases reported as pharyngitis (often reported to be about 50%). This finding could be explained by the fact that a certain degree of pharyngeal redness (which justified the use of the term pharyngitis) often remains asymptomatic, whereas acute exudative tonsillitis usually causes symptoms. Interestingly, *Wiesner et al.* [14] found no correlation between the finding of an inflamed pharynx and the presence of a sore throat in patients with oropharyngeal gonorrhoea, but they found some correlation between the complaint of a sore throat and the practice of fellatio.

In the cases of gonococcal tonsillitis described in the literature the tonsils were invariably enlarged and showed some degree of inflammation. In one case an asymmetrical enlargement of the tonsils was described, as seen in our patient. The finding of a whitish-yellow exudate was specifically reported in only 12 cases (20.6%); bilateral cervical lymphadenopathy was reported in only six patients (9.3%) and therefore seems to be rare. However, as described in a 4-year-old child, enlargement of cervical lymph nodes can be grotesque [14]. Fever was described in five patients (8.2%) and therefore appears to be an uncommon finding in uncomplicated oral gonorrhoea. Pharyngeal abscesses are not described in the literature.

The most important risk factor for developing oral gonococcal infection was universally reported to be the practice of fellatio. This was supported in many studies [13, 14, 19] by the high prevalence of oral gonococci in females and homosexual men who admitted fellatio. Although heterosexual men who have had a positive culture for gonococci from the oropharynx were also reported in the literature, the link with the practice of cunnilingus seems to be much less clear. A small number of cases of oral gonorrhoea among females and homosexual men who denied fellatio but had concurrent genital gonorrhoea suggested a possible role for an autoinoculation mechanism [14, 18].

Modern antibiotic therapy for gonorrhoea is effective against oral infection. This was not the case with the old penicillin therapy used in the 1960s and 1970s, which often failed to eradicate gonococci from the tonsils and led some authors to find an explanation for the noted higher frequency of disseminated gonococcal infection among patients with positive cultures from the oropharynx [14, 18].

Nevertheless, oral gonococcal infection remains a difficult diagnosis because symptoms are often lacking and it can occur in the absence of genital infection. Furthermore, a high index of suspicion is needed by physicians to consider gonococcal disease in sexually active patients presenting with acute exudative tonsillitis (Figure 1). The Gram

Table 1
Synopsis of oral gonococcal disease reported in the literature.

[Ref.] year	No. of patients	Genital gonorrhoea	Oral gonorrhoea	Oral gonorrhoea only	Tonsillitis described	Asymptomatic oral infection	Symptomatic oral infection (sore throat)	Patients with fever	Oral manifestation described (no.)	Other manifestation	Clinical feature of the tonsils (no.)
[1] 1961	1	1	1	0	0	0	1	0	Gingivo-stomatitis	Genital infection	-
[2] 1967	3	3	3	0	1	0	3	0	Pharyngitis (2) Tonsillitis (1)	Genital infection	Enlarged, inflamed, no exudate
[3] 1969	505	1	1	1	0	1	0	0	Cultures positive for gonococci. Normal mucosa	None	Normal
[4] 1969	1	1	1	0	0	0	1	0	Glossitis	Genital infection, dermatitis	-
[5] 1970	1	1	1	1	1	0	1	0	Tonsillo-pharyngitis	None	Enlarged, inflamed with whitish-yellow exudate. Multiple pharyngeal vesicles
[6] 1971	1	1	1	1	1	0	1	1	Tonsillo-pharyngitis	Arthritis	-
[7] 1971	1	1	1	0	1	0	1	0	Tonsillitis	Arthritis	Enlarged, inflamed, no exudate
[8] 1971	424	210	13	0	3	10	3	1 (with tonsillitis)	Tonsillitis (3) Pharyngitis (10)	Genital infection	Enlarged, inflamed, white-yellow exudate in the cryptae
[9] 1972	1	1	1	0	1	0	1	0	Tonsillitis	Arthritis, genital infection	Enlarged, slightly red
[10] 1971	50	50	2	0	2	2	0	0	Tonsillo-pharyngitis	Genital infection	Enlarged, slightly inflamed
[11] 1972	119	119	3	0	0	2	1	0	Generic pharyngitis	Genital infection	-
[12] 1972	79	79	11	0	0	8	3	0	Generic pharyngitis	Genital, rectal infection	-
[13] 1972	65	33	1	0	0	1	0	0	Tonsillitis	Genital infection (33)	Enlarged, inflamed, no exudate
[14] 1973	2,224	872	150	15	0	7	6	0	Generic pharyngitis	Genital infection	-
[14] 1973	1	1	1	1	1	0	1	1	Tonsillitis	High fever, cervical lymphadenopathy	Enlarged, red, yellow exudate in the cryptae
[15] 1975	4	4	4	2	2	0	4	0	Pharyngitis (2) Tonsillitis (2)	Genital infection	Enlarged, redness, no exudate
[16] 1974	467	467	30	?	0	25	5	2	Generic pharyngitis	Genital infection	-
[17] 1975	1	1	1	?	1	0	1	0	Tonsillitis	Cervical lymphadenopathy	Enlarged, inflamed, greyish-yellow exudate
[18] 1976	196	74	2	2	2	2	0	0	Tonsillitis	Genital infection	Slightly enlarged, slightly red, no exudate
[19] 1985	951	951	74	25	22	49	25	0	Tonsillitis (22) Generic pharyngitis (52)	Pharyngitis (52) Cervical lymphadenopathy (4)	Enlarged, inflamed (22), yellow exudates (6)
[20] 1973	1,346	1,346	210	16	23	11	199	3 (all tonsillitis)	Tonsillitis	Arthralgia (1) Tonsillitis (23)	Enlarged, inflamed, no exudate
This report	1	0	1	1	1	0	1	0	Tonsillitis	None	Asymmetrically enlarged tonsils with white-yellow exudate in the cryptae

stain of a tonsillar swab, as shown for our patient, is an excellent method of obtaining a rapid diagnosis that can be subsequently confirmed by LCR or culture. The entity of gonococcal tonsillitis should be specifically mentioned in the differential diagnosis of acute tonsillitis and not merely be subsumed in the term pharyngitis.

Acknowledgment

We thank Joseph Wong, MD, for critical review of the manuscript.

References

- Schmidt H, Hjorting-Hansen E, Philipsen HP: Gonococcal stomatitis. *Acta Derm Venerol* 1961; 41: 324–325.
- Fiumara NJ, Wise HM, Marray M: Gonorrhoeal pharyngitis. *N Engl J Med* 1967; 276: 1248–1250.
- Thatcher RW, McCraney WT, Kellogg DS Jr, Whaley WH: Asymptomatic gonorrhoea. *JAMA* 1969; 210: 315–317.
- Cowan L: Gonococcal ulceration of the tongue in the gonococcal dermatitis syndrome. *Br J Vener Dis* 1969; 45: 228–231.
- Metzger AL: Gonococcal arthritis complicating gonorrhoeal pharyngitis. *Ann Intern Med* 1970; 73: 267–269.
- La Luna F, Agus B: Gonococcal pharyngitis and arthritis. *Ann Intern Med* 1971; 75: 649.
- Iqbal Y: Gonococcal tonsillitis. *Br J Vener Dis* 1971; 47: 144–145.
- Bro-Jorgensen A, Jensen J: Gonococcal tonsillar infection. *Br Med J* 1971; 4: 660–661.
- Schüller JL, Stolz E: Een patientemet tonsillitis gonorrhoeica. *Ned Tijdschr Geneesk* 1972; 116: 2216–2218.
- Hellgren L: Gonorré-Tonsillit efter genito-oral Kontakt. *Laektidningen* 1971; 68: 569–571.
- Ratnatunga CS: Gonococcal pharyngitis. *Br J Vener Dis* 1972; 48: 184–186.
- Owen RL, Hill JL: Rectal and pharyngeal gonorrhoea in homosexual men. *JAMA* 1972; 220: 1315–1318.
- Rodin P, Monteiro GE, Scrimgeour G: Gonococcal pharyngitis. *Br J Vener Dis* 1972; 48: 182–183.
- Wiesner PJ, Tronca E, Bonin P: Clinical spectrum of pharyngeal gonococcal infection. *N Engl J Med* 1973; 288: 181–185.
- Becker GD, Wernicke AM: Gonococcal pharyngitis a report of 4 cases and a review of the literature. *Ann Otol Rhinol Laryngol* 1974; 83: 550–554.
- Stolz E, Schuller J: Gonococcal oro and nasopharyngeal infection. *Br J Vener Dis* 1974; 50: 104–108.
- Jamsky RJ: Gonococcal tonsillitis: report of a case. *Oral Surg Oral Med Pathol* 1977; 44: 197–200.
- Van Overbeck JJ: Gonococcal infection on the oropharynx. *Arch Otolaryngol* 1976; 102: 94–96.
- Tikjob G, Petersen MS, Ousted M, Oehlenschlaeger J: Localisation of gonococci in the anterior oral cavity. A possible reservoir of the gonococcal infection? *Ann Clin Res* 1985; 17: 73–75.
- Bro-Jorgensen A, Jensen T: Gonococcal pharyngeal infections. Report of 110 cases. *Br J Vener Dis* 1973; 49: 491–499.