

Clin Orthop Relat Res (2009) 467:699–703
DOI 10.1007/s11999-008-0616-6

SYMPOSIUM: FEMOROACETABULAR IMPINGEMENT: CURRENT STATUS OF DIAGNOSIS
AND TREATMENT

Impingement-free Hip Motion

The ‘Normal’ Angle Alpha after Osteochondroplasty

Mirjam Neumann MD, Quanjun Cui MD,
Klaus A. Siebenrock MD, Martin Beck MD

Published online: 19 November 2008
© The Association of Bone and Joint Surgeons 2008

Abstract Femoroacetabular impingement is considered a cause of hip osteoarthritis. In cam impingement, an aspherical head-neck junction is squeezed into the joint and causes acetabular cartilage damage. The anterior offset angle α , observed on a lateral crosstable radiograph, reflects the location where the femoral head becomes aspheric. Previous studies reported a mean angle α of 42° in asymptomatic patients. Currently, it is believed an angle α of 50° to 55° is normal. The aim of this study was to identify that angle α which allows impingement-free motion. In 45 patients who underwent surgical treatment for femoroacetabular impingement, we measured the angle α preoperatively, immediately postoperatively, and 1 year postoperatively. All hips underwent femoral correction and, if necessary, acetabular correction. The correction was considered sufficient when, in 90° hip flexion, an internal rotation of 20° to 25° was possible. The angle α was

corrected from a preoperative mean of 66° (range, 45°–79°) to 43° (range, 34°–60°) postoperatively. Because the acetabulum is corrected to normal first, the femoral correction is tested against a normal acetabulum. We therefore concluded an angle α of 43° achieved surgically and with impingement-free motion, represents the normal angle α , an angle lower than that currently considered sufficient.

Introduction

Femoroacetabular impingement (FAI) is a pathologic condition in which structural abnormalities of the femoral head-neck junction and/or acetabulum result in an abutment between the proximal femur and the acetabular rim, causing labral tear and chondral lesion [2, 8, 9]. There is evolving evidence that FAI eventually leads to osteoarthritis of the hip, particularly in the young adult [2, 8, 9].

There are two mechanisms of FAI. Cam FAI presents with an aspherical femoral head-neck contour caused by widening of the femoral neck or a reduction in the head-neck offset [2, 8]. The asphericity is developmental in origin. The aspherical extension of the femoral head is covered by hyaline cartilage, and it is believed the incomplete or late separation of the common growth plate of the proximal femur into the growth plates of the greater trochanter and of the femoral head is one cause for its appearance [18, 20]. Other causes include slipped capital femoral epiphysis and posttraumatic alterations of the femoral head-neck contour [5, 12]. A cam effect occurs when during flexion and additional internal rotation of the hip, the aspherical portion of the femoral head is wedged into the acetabulum, which in turn causes damage to the acetabular labrum and adjacent cartilage [2, 8, 12]. The

Each author certifies that he or she has no commercial associations (eg, consultancies, stock ownership, equity interest, patent/licensing arrangements, etc) that might pose a conflict of interest in connection with the submitted article.

Each author certifies that his or her institution has approved the human protocol for this investigation and that all investigations were conducted in conformity with ethical principles of research.

M. Neumann, K. A. Siebenrock, M. Beck
Department of Orthopaedic Surgery, University of Bern,
Inselspital, Bern, Switzerland

Q. Cui
Department of Orthopaedic Surgery, University of Virginia,
Charlottesville, VA, USA

M. Beck (✉)
Department of Orthopaedics, Luzerner Kantonsspital,
6000 Luzern, Switzerland
e-mail: martin.beck@ksl.ch

current treatment includes the removal of the aspherical part of the head-neck junction [6, 11].

The second mechanism is called pincer FAI and is secondary to a localized or global acetabular overcoverage [2, 8]. Radiographically, this appears as acetabular retroversion or coxa profunda to protrusio [16, 17]. The femoral neck is normal. The increased acetabular coverage limits the range of motion and, as a result, the labrum is caught between the femoral neck and the acetabular rim. Cartilage damage is less extensive than in the cam type and limited to a narrow strip along the acetabular rim [2]. For pincer impingement, the acetabular rim is resected to give the acetabulum a normal depth and orientation with reattachment of the labrum [6, 11].

Pure cam or pincer FAI is rare. In most hips, a combination of the two mechanisms is present [2]. Surgical treatment of this type of FAI is directed at restoring both a more normal femoral head-neck offset and the appropriate acetabular depth and orientation.

The anterior offset angle α has been used to quantify the asphericity at the femoral head-neck junction (Fig. 1A) [14]. In the original description, the angle α was measured on an oblique paraxial MRI cut through the center of the femoral head. The angle α is formed by a line through the center of the femoral head in the axis of the femoral neck and a line connecting the center of the femoral head to a point where the femoral head extrudes a circle drawn around the femoral head (that is the point where the sphericity of the femoral head ends). Nötzli et al. [14] reported the average value of the angle α in patients without symptoms was 42° (range, 33° – 48°), whereas the angle α in patients with FAI ranged from 55° to 94° with an average of 74° . Based the data of Nötzli et al. [14], the angle α of 55° , indicating the lower range of the angle α in the symptomatic group, is often wrongly interpreted as the upper limit that allows impingement-free motion [10, 15]. However, the true value of the angle α that allows impingement-free motion remains unknown.

At surgery, first the acetabular pathology (coxa profunda, retroversion) is treated by resection of the acetabular rim and reattachment of the labrum if necessary. Then the aspherical part of the femoral head-neck junction is removed until internal rotation of 20° to 25° is obtained at 90° hip flexion. Within this range of motion, no impingement occurs as documented by the intraoperative examination. The postoperative lateral radiograph therefore must show an angle α that is representative for impingement-free motion in a normal hip.

The aim of the study was therefore to determine the angle α that is required for (1) impingement-free motion of the hip and (2) its evolution during the first year after surgery.

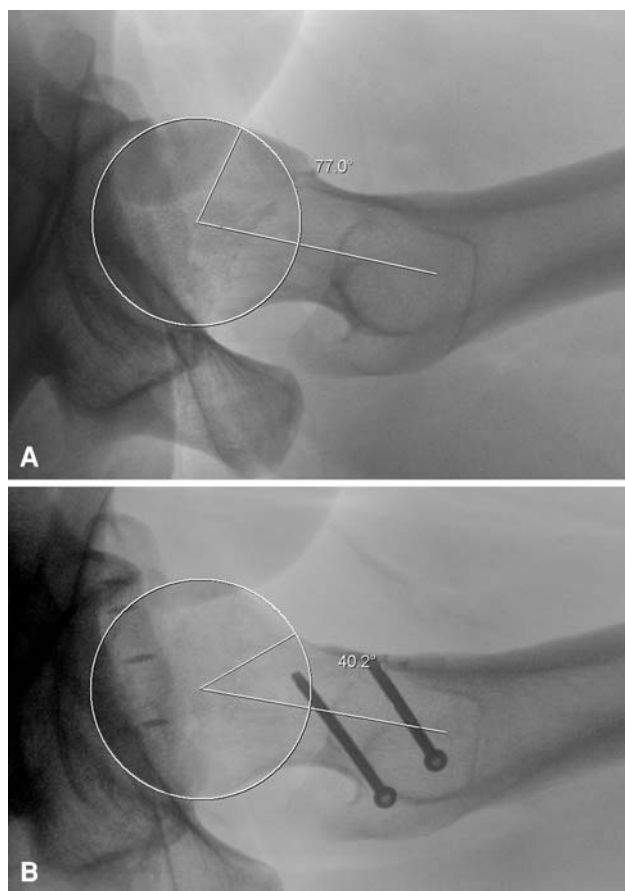


Fig. 1A–B Lateral crosstable view of a left hip in neutral position showing the (A) preoperative and (B) postoperative angle α in the same patient. The technique for measuring the angle α is shown. The limbs of the angle α are a line through the center of the femoral head along the axis of the femoral neck axis and a line connecting the center of the femoral head to a point where the femoral head lies outside a circle around the femoral head.

Materials and Methods

We identified all 68 patients who underwent surgical dislocation and resection osteochondroplasty of the hip for the treatment of FAI from January 1, 2001, to December 31, 2001. If the digital documentation of the radiographs was not complete, hard copies were retrieved from the archive and scanned. Patients with missing radiographic documentation or insufficient quality that precluded accurate measurement of the angle α or who were lost to followup were excluded; radiographs were lost in 17 patients, of insufficient quality in two, and four patients were lost to followup at 1 year. This left 45 patients followed for 1 year. Thirteen hips had radiographic followup of 2 years. There were 27 men and 18 women. Mean age at surgery was 35.5 years (range, 20–51 years).

Thirty-two hips had mixed cam-pincer impingement, of which 25 had a coxa profunda. The remaining 13 hips had a pure cam impingement. All mixed impingements had a

resection of the bony rim, in 12 followed by reattachment of the labrum.

We have previously reported the surgical technique [6, 7, 11]. Briefly, the patient was placed in the lateral decubitus position. Using a trochanteric flip approach, the joint capsule was exposed and incised in a Z-shaped way. After capsulotomy, the hip was inspected, put through the range of motion, and examined for impingement. Acetabular and femoral causes of FAI were identified. The surgical treatment first was directed at the correction of the acetabular pathology with resection of the acetabular rim and reattachment of the labrum, and focus was then shifted toward removing any nonspherical portion of the femoral head. At the end of surgery, an intraoperative examination of impingement-free range of motion was performed and documented. The goal was to obtain 20° to 25° of internal rotation at 90° hip flexion.

The lateral crosstable views were taken in neutral position of the leg with the patella pointing upward. The anterior offset angle α was measured on the preoperative and postoperative lateral crosstable view of the hip (Fig. 1). The legs of the angle α are formed by a line through the center of rotation in the axis of the femoral neck and a line connecting the center of the femoral head with a point where the femoral head extrudes a circle around the femoral head (Fig. 1A). A previous study demonstrated good reproducibility for this method ($r = 0.97$ for intraobserver and interobserver correlations) [12]. The angle α was measured digitally with ImageJ software (version 1.37; National Institutes of Health, Bethesda, MD). The measurements were made twice by two orthopaedic surgeons (MN, QC) on radiographs obtained preoperatively (Fig. 1A), immediately after surgery (Fig. 1B), and at 8 weeks and at least 1 year postoperatively. In total, four sets of radiographs were taken. Any preoperative radiographs older than 3 months were repeated the day before surgery. The radiographs after surgery were taken with the patient still on the operating table under anesthesia. The 8-week radiographs were taken at the first postoperative visit and the radiographs after 1 year were taken within a range of ± 2 weeks. Intra- and interobserver variance in measuring the angle α were assessed using intraclass correlation coefficients. Intra- and interobserver measurements were 0.8214 (confidence interval, 0.6915–0.8965) and 0.8547 (confidence interval, 0.7704–0.9081), respectively.

In addition to measurement of the angle α , radiographs were analyzed for degenerative changes using the Tönnis classification for osteoarthritis [19].

The differences between the pre- and postoperative angle α were analyzed using paired Student's *t* test. The statistical analyses were conducted using SAS 9.1 (SAS Institute Inc, Cary, NC).

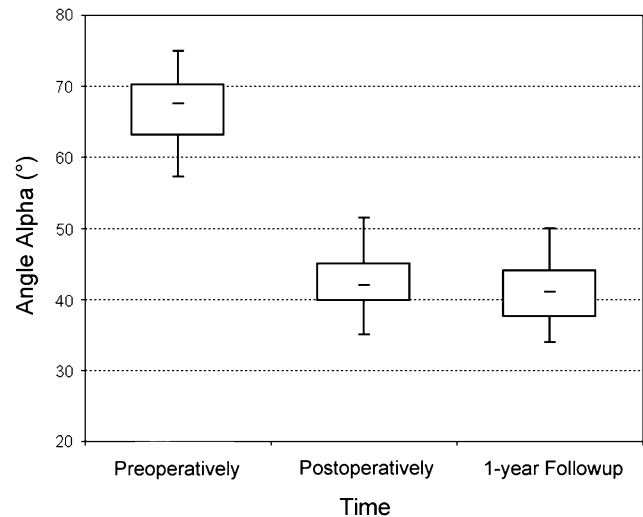


Fig. 2 Box plots of the angle α measured preoperatively, postoperatively, and 1 year after surgery are shown. The small horizontal lines in the boxes indicate the mean value, the box the standard deviation, and the lines going up and down indicate the double standard deviation.

Results

A decrease of the angle α to an average of 43° after surgery was observed in all hips. The angle α remained stable 1 year after surgery. The mean preoperative angle α measured 66° (range, 45°–79°). Immediately after surgery, the mean angle α measured 43° (range, 34°–60°). Thus, the surgery reduced ($p < 0.0001$) the angle α by 23°. At 1 year after surgery, the angle α was similar ($p = 0.771$) to that immediately postoperative (mean 41°; range, 34°–51°) (Fig. 2). In the 13 hips with 2-year followup, the angle α remained unchanged with a value of 43° (range, 35°–50°) at 1 year and at 2 years.

At the time of surgery, 16 of 45 (36%) patients had no osteoarthritis, 28 (62%) had Grade I, and one had Grade II osteoarthritis. In seven hips, a small osteophyte developed at the proximal limit of the resection area 1 year after resection osteochondroplasty with five of these patients having preoperative degenerative changes of Tönnis Grade I; the other two were Grade 0.

Discussion

FAI has been recognized as one of the major risk factors for early degeneration of the hip [2, 3, 8]. Two different mechanisms, cam and pincer FAI, initiate damage to the labrum and adjacent acetabular cartilage. Although the pincer impingement is characterized by general or local acetabular overcoverage, cam impingement is a function of an aspherical head-neck junction. During flexion and internal rotation of the hip, the aspherical extension of the

femoral head is forced into the acetabulum, causing damage of the acetabular rim [2, 3, 8]. A measure to quantify the asphericity is the anterior offset angle α described by Nötzli et al. [14]. They reported an average angle α of 42° in asymptomatic volunteers and 74° in patients with FAI. Based on the data of Nötzli et al. [14], the angle α of 55°, indicating the lower range of the angle α in the symptomatic group, has been used as the upper limit allowing impingement-free motion [15]. However, the value of the angle α that allows impingement-free motion is unknown. We therefore determined the angle α required for impingement-free motion of the hip and its evolution during the first year after surgery.

There are some limitations to our study. Originally, the angle α was measured on MRI on an oblique plane parallel to the axis of the femoral neck passing through the center of the femoral head [14]. This oblique plane was believed to correspond to the radiographic representation of the proximal femur using a lateral crosstable radiograph [14]. Another limitation is a reliance on radiography as opposed to CT or MRI with radial reformation to determine the angle α . The impingement site at the anterolateral quadrant of the femoral head neck junction is commonly a blind zone radiographically [4]. Although this is true, the aim of the study was to define the normal angle α on the lateral crosstable view so the hip surgeon has a reliable value above which impingement is more likely to occur. However, at the same time, one must recognize the lateral radiograph is only a screening tool and, if the patient is symptomatic, further investigations, mainly MR arthrography with radial imaging, are necessary to establish or exclude the diagnosis. In this study (and in our daily clinical use), the lateral crosstable view was taken with the hip in neutral rotation and the patella pointing upward. Based on the paper of Meyer et al., it is often recommended to take the radiograph in maximal internal rotation to bring the anterolateral head neck junction into radiographic view [13]. However, they identified the best view to show the critical anterolateral area would be 25° flexion, 20° abduction, and neutral rotation. Because this is not feasible in clinical practice, they recommended the Dunn view or a lateral crosstable view in approximately 15° of internal rotation. As a screening tool, the lateral crosstable view in neutral rotation is sufficient, because even with 15° internal rotation or more, the asphericity does not come into view. If there is clinical suspicion for FAI, more precise imaging of the femoral neck, including radial MR arthrography, is necessary [4].

At surgery, both acetabular and femoral pathologies are treated, usually addressing the acetabulum first. The correction of the femoral side therefore is tested against a “normal” acetabulum; therefore, the influence of the acetabulum is neutralized. The resulting angle α of 43° therefore

must be the angle that is necessary for impingement-free motion in a hip without pathology of the acetabulum. The value of 43° is in keeping with other publications [1, 14].

Our data suggest an average postoperative angle α of 43° (range, 34°–60°). This is the result of intraoperatively observed impingement-free motion with approximately 20° to 25° of internal rotation in 90° hip flexion. To correctly interpret these values, one has to keep in mind that impingement not only is the result of asphericity of the femoral head, but also depends on the depth of the acetabulum. In a dysplastic hip, the angle α can exceed the normal value without causing impingement because the acetabulum is too small. Conversely, an angle α of 43° may not be sufficient to allow impingement-free motion in protrusio because the acetabulum is too deep. The upper limit of the range with 60° can be explained with a rather small, marginally dysplastic acetabulum. The lower end of the range cannot be explained with the depth of the acetabulum, because this was corrected before the neck resection is performed, but rather is the result of excessive resection of the femoral neck.

Osteophyte formation after resection osteochondroplasty seems closely related to the preoperative degenerative changes in the hip. A previous study reported four of 19 patients had osteophyte formation after surgery, and all four also had preoperative joint space narrowing [2]. In the current study, five of the seven patients with postoperative osteophyte formation had associated osteoarthritis preoperatively. The small number of patients in this study precluded meaningful statistical analysis of the influence of preoperative joint degeneration on the appearance of the osteophytes.

Our data suggest an angle α of 43° provides impingement-free motion of the hip, provided there is no major abnormality of the acetabulum (coxa profunda, retroversion). However, depending on the shape and depth of the acetabulum, an angle higher than 43° may be sufficient. Conversely, in a very deep hip, it may be necessary to reduce the femoral neck to a lower angle α than the recommended 43°. The value of 43° can be used as a screening tool to assess the likelihood for cam FAI, but it must be kept in mind that asphericity of the femoral head-neck junction only can be excluded with further imaging (MR arthrography with radial images). It can also be used preoperatively for planning the extent of the resection osteochondroplasty.

References

1. Beaulé PE, Zaragoza E, Motamedi K, Copelan N, Dorey FJ. Three-dimensional computed tomography of the hip in the assessment of femoroacetabular impingement. *J Orthop Res*. 2005;23:1286–1292.

2. Beck M, Kalhor M, Leunig M, Ganz R. Hip morphology influences the pattern of damage to the acetabular cartilage: femoroacetabular impingement as a cause of early osteoarthritis of the hip. *J Bone Joint Surg Br.* 2005;87:1012–1018.
3. Beck M, Leunig M, Parvizi J, Boutier V, Wyss D, Ganz R. Anterior femoroacetabular impingement: part II. Midterm results of surgical treatment. *Clin Orthop Relat Res.* 2004;418:67–73.
4. Dudda M, Albers C, Mamisch TC, Werlen S, Beck M. Do normal radiographs exclude asphericity of the femoral head-neck junction? *Clin Orthop Relat Res.* doi:10.1007/s11999-008-0617-5.
5. Eijer H, Myers S, Ganz R. Anterior femoroacetabular impingement after femoral neck fractures. *J Orthop Trauma.* 2001;15:475–481.
6. Espinosa N, Beck M, Rothenfluh DA, Ganz R, Leunig M. Treatment of femoro-acetabular impingement: preliminary results of labral refixation. Surgical technique. *J Bone Joint Surg Am.* 2007;89(Suppl 2):36–53.
7. Ganz R, Gill TJ, Gautier E, Ganz K, Krugel N, Berlemann U. Surgical dislocation of the adult hip a technique with full access to the femoral head and acetabulum without the risk of avascular necrosis. *J Bone Joint Surg Br.* 2001;83:1119–1124.
8. Ganz R, Parvizi J, Beck M, Leunig M, Nötzli H, Siebenrock KA. Femoroacetabular impingement: a cause for osteoarthritis of the hip. *Clin Orthop Relat Res.* 2003;417:112–120.
9. Ito K, Minka MA 2nd, Leunig M, Werlen S, Ganz R. Femoroacetabular impingement and the cam-effect: a MRI-based quantitative anatomical study of the femoral head-neck offset. *J Bone Joint Surg Br.* 2001;83:171–176.
10. Kubiak-Langer M, Tannast M, Murphy SB, Siebenrock KA, Langlotz F. Range of motion in anterior femoroacetabular impingement. *Clin Orthop Relat Res.* 2007;458:117–124.
11. Lavigne M, Parvizi J, Beck M, Siebenrock KA, Ganz R, Leunig M. Anterior femoroacetabular impingement: part I. Techniques of joint preserving surgery. *Clin Orthop Relat Res.* 2004;418:61–66.
12. Leunig M, Casillas MM, Hamlet M, Hersche O, Nötzli H, Slongo T, Ganz R. Slipped capital femoral epiphysis: early mechanical damage to the acetabular cartilage by a prominent femoral metaphysis. *Acta Orthop Scand.* 2000;71:370–375.
13. Meyer DC, Beck M, Ellis T, Ganz R, Leunig M. Comparison of six radiographic projections to assess femoral head/neck asphericity. *Clin Orthop Relat Res.* 2006;445:181–185.
14. Nötzli HP, Wyss TF, Stoecklin CH, Schmid MR, Treiber K, Hodler J. The contour of the femoral head-neck junction as a predictor for the risk of anterior impingement. *J Bone Joint Surg Br.* 2002;84:556–560.
15. Pfirrmann CW, Mengiardi B, Dora C, Kalberer F, Zanetti M, Hodler J. Cam and pincer femoroacetabular impingement: characteristic MR arthrographic findings in 50 patients. *Radiology.* 2006;240:778–785.
16. Ruelle M, Dubois JL. The protrusive malformation and its arthroscopic complication. I. Radiological and clinical symptoms: etiopathogenesis [in French]. *Rev Rhum Mal Osteoartic.* 1962;29:476–489.
17. Siebenrock KA, Schoeniger R, Ganz R. Anterior femoroacetabular impingement due to acetabular retroversion: treatment with periacetabular osteotomy. *J Bone Joint Surg Am.* 2003;85:278–286.
18. Siebenrock KA, Wahab KH, Werlen S, Kalhor M, Leunig M, Ganz R. Abnormal extension of the femoral head epiphysis as a cause of cam impingement. *Clin Orthop Relat Res.* 2004;418:54–60.
19. Tönnis D. Normal values of the hip for the evaluation of x-rays in children and adults. *Clin Orthop Relat Res.* 1976;119:39–47.
20. Wagner S, Hofstetter W, Chiquet M, Ganz R, Siebenrock K. Early osteoarthritic changes of human femoral head cartilage subsequent to femoro-acetabular impingement. *Osteoarthritis Cartilage.* 2003;11:508–518.