

Original Article

Diagnostic Performance of ^{11}C -choline PET/CT and FDG PET/CT in Prostate Cancer

Kazuhiro Kitajima^{a*}, Shingo Yamamoto^b, Soichi Odawara^a, Kaoru Kobayashi^c,
Masayuki Fujiwara^c, Norihiko Kamikonya^c, Kazuhito Fukushima^d, Yukako Nakanishi^b,
Takahiko Hashimoto^b, Yusuke Yamada^b, Toru Suzuki^b, Akihiro Kanematsu^b,
Michio Nojima^b, and Koichiro Yamakado^c

^aDivision of Nuclear Medicine and PET Center, Departments of^bUrology,

^cRadiology, Hyogo College of Medicine, Nishinomiya, Hyogo 663-8501 Japan,

^dDepartment of Nuclear Medicine, University Hospital Wuerzburg, D-97080 Wuerzburg, Germany.

We compared ^{11}C -choline and FDG PET/CT scan findings for the staging and restaging of prostate cancer. Twenty Japanese prostate cancer patients underwent ^{11}C -choline and FDG PET/CT before (n=5) or after (n=15) treatment. Using a five-point scale, we compared these scanning modalities regarding patient- and lesion-based diagnostic performance for local recurrence, untreated primary tumor, and lymph node and bony metastases. Of the 20 patients, documented local lesions, and node and bony metastases were present in 11 (55.0%), 9 (45.0%), and 13 (65.0%), respectively. The patient-based sensitivity/specificity/accuracy/area under the receiver-operating-characteristic curve (AUC) values for ^{11}C -choline-PET/CT for diagnosing local lesions were 90.9%/100%/95.0%/1.0, whereas those for FDG-PET/CT were 45.5%/100%/75.0%/0.773. Those for ^{11}C -choline-PET/CT for node metastasis were 88.9%/100%/95.0%/0.944, and those for FDG-PET/CT were 44.4%/100%/75.0%/0.722. Those for ^{11}C -choline-PET/CT for bone metastasis were 84.6%/100%/90.0%/0.951, and those for FDG-PET/CT were 76.9%/100%/85.0%/0.962. The AUCs for local lesion and node metastasis differed significantly ($p=0.0039$, $p=0.011$, respectively). The lesion-based detection rates of ^{11}C -choline compared to FDG PET/CT for local lesion, and node and bone metastases were 91.7% vs. 41.7%, 92.0% vs. 32.0%, and 94.8% vs. 83.0% ($p=0.041$, $p=0.0030$, $p<0.0001$), respectively. ^{11}C -choline-PET/CT is more useful for the staging and restaging of prostate cancer than FDG-PET/CT in Japanese men.

Key words: prostate cancer, PET, choline, FDG, Japanese

Integrated positron emission tomography/computed tomography (PET/CT) with 2-[^{18}F]fluoro-2-deoxy D-glucose (FDG) has been shown to be a useful tool for combined metabolic and anatomic evaluations of cancers. Although FDG, an analog of glucose that can visualize metabolic activity, is the most widely used radiotracer for the imaging of various

malignancies, its application in cases of prostate cancer is limited because of its low sensitivity and specificity [1,2]. Moreover, a urinary excretion of FDG in the urinary bladder may interfere with evaluation of prostate lesions. Many new tracers have been introduced to overcome these limitations, including ^{18}F - or ^{11}C -choline, ^{18}F - or ^{11}C -acetate, 16β - ^{18}F -fluoro-5 α -dihydrotestosterone (^{18}F -FDHT), anti-3- ^{18}F -fluorocy-

Received November 21, 2017; accepted January 23, 2018.

*Corresponding author. Phone: +81-798-45-6883; Fax: +81-798-45-6262
E-mail: kitajima@med.kobe-u.ac.jp (K. Kitajima)

Conflict of Interest Disclosures: No potential conflict of interest relevant to this article was reported.

clobutane-1-carboxylic acid (^{18}F -FACBC), and prostate-specific membrane antigen (^{68}Ga -PSMA), which are currently under investigation [2].

In Western countries, ^{11}C - and ^{18}F -choline PET/CT examinations have been successfully used for the restaging of prostate cancer in patients who exhibit biochemical disease recurrence after they underwent definitive therapy [3,4]. However, ^{11}C -choline uptake may occur via a choline-specific transporter protein that is overexpressed in the membrane of prostate cancer cells [5]. ^{11}C -choline is phosphorylated by choline kinase, which is upregulated and retained within tumor cells for the synthesis of phosphatidylcholine [5], an essential component of cell membranes involved in the modulation of transmembrane signaling during carcinogenesis.

Four research groups have directly compared the diagnostic performance of choline-PET/CT with that of FDG-PET/CT for the staging and restaging prostate cancer in non-Japanese men [6-9], of which three reported the superiority of choline PET/CT [6-8] and the fourth reported that the diagnostic performance of each was the same [9]. Thus, the true superiority of choline PET/CT has yet to be confirmed in Japanese men. We conducted the present study to compare the findings obtained with ^{11}C -choline PET/CT with those obtained with FDG-PET/CT for the staging and restaging of prostate cancer in Japanese men.

Patients and Methods

Patients. This retrospective study was approved by the ethics committee at our institution (no. 2213). Informed consent was obtained from each patient after the procedure details were fully explained. A total of 20 patients (age range 50-90 years, mean 70.8 years) with histopathologically proven prostate cancer underwent ^{11}C -choline PET/CT and FDG-PET/CT examinations at a maximum interval of 2 weeks for the staging ($n=5$) and restaging ($n=15$) of prostate cancer at our institution between October 2015 and June 2017, and all were included in this study. The median free serum prostate specific antigen (PSA) level in the five patients who underwent both examinations before treatment was 104 ng/mL (range 3.0-5,916.6 ng/mL), and that in the 15 who underwent both examinations during or after treatment was 10.1 (range 2.1-1,274.4 ng/mL). At the time of the examinations, 14 of the 20 patients (70.0%)

had received androgen-deprivation therapy. Additional patient details and demographic data are shown in Table 1.

^{11}C -choline PET/CT. ^{11}C -choline was synthesized using a commercial module as described by Hara [10] and an CYPRIS-325R cyclotron (Sumitomo Heavy Industries [SHI], Tokyo, Japan). The acquisition of emission scans from the mid-thigh to the head was started 6 min after an intravenous injection of 3.0 MBq/kg body weight of ^{11}C -choline. All PET/CT examinations were performed using a PET/CT scanner equipped with a 64-multi-detector computed tomography device (Gemini TF64; Philips Medical Systems, Eindhoven, The Netherlands). Whole-body PET acquisition in 3D mode was performed from the mid-thigh to the top of the head (1.5 min per bed position; 6-8 bed positions) and reconstructed using the ordered subsets expectation maximization (OSEM) reconstruction algorithm (33 subsets, three iterations, 4 mm per slice) with attenuation correction based on low-dose CT (120 kVp, 100 mA, slice thickness 2 mm, transverse field of view 600 mm), which was also used for anatomical correlation.

FDG PET/CT. FDG was synthesized using the nucleophilic substitution method with an FDG-synthesizing instrument F-200 (SHI) and CYPRIS-325R cyclotron (SHI). Patients were instructed to fast for 5 h

Table 1 Patient characteristics

Characteristics	value
Age (years)	
Mean	70.8 ± 9.4
Range	50~90
PSA (ng/mL)	
Patients without any previous treatments ($n=5$)	
Mean	1,249.8 ± 2,609.8
Range	3.0~5,916.6
Median	104
Patients with previous treatments ($n=15$)	
Mean	101.3 ± 324.9
Range	2.1~1,274.4
Median	10.1
Previous treatment	
None	5
Radiotherapy	1
Radiotherapy + Hormonal therapy	6
Hormonal therapy	7
Hormonal therapy + Chemotherapy	1

PSA: prostate specific antigen

prior to scanning, and blood glucose was measured immediately before an injection of 3.0 MBq/kg body weight of FDG. None of the patients had a blood glucose level > 160 mg/dL. Whole-body FDG-PET/CT was performed 60 min after the injection of FDG from the top of the head to the mid-thigh, with the same acquisition and reconstruction parameters noted above for ^{11}C -choline PET/CT. No indwelling catheter or diuretic was used. The median time between the ^{11}C -choline and FDG PET/CT scanning procedures was 9 days.

Imaging analysis. Two experienced nuclear medicine experts (both with at least 9 years of experience with PET/CT) who had no knowledge of the other imaging results or clinical data prospectively interpreted the ^{11}C -choline and FDG PET/CT images. They then used a five-point scale (1: definitely absent, 2: probably absent, 3: indeterminate, 4: probably present, 5: definitely present) to grade the lesions in each patient based on consensus. Discordant readings by the two observers for each modality were resolved in a subsequent consensus review. To calculate the sensitivity and specificity of each modality, scores of 3, 4 and 5 were considered positive.

A semiquantitative analysis of abnormal radiotracer uptake for each lesion was also retrospectively performed using the maximum standardized uptake value (SUVmax), calculated as follows: $\text{SUV} = \text{volume of interest (VOI) radioactivity concentration (Bq/mL)} / [\text{injected dose (Bq)}/\text{patient weight (g)}]$. The SUVmax, defined as the highest SUV value for the pixels with the highest count within the VOI, was measured and recorded for the focal areas of uptake.

Gold standard. The final diagnosis was obtained based on histological confirmation, radiological imaging findings obtained in subsequent magnetic resonance imaging (MRI), computed tomography (CT), and bone scintigraphy examinations, or at clinical follow-up including the PSA level, MRI, CT, bone scintigraphy, and FDG-PET/CT or ^{11}C -choline PET/CT results.

Statistical analysis. We conducted a receiver-operating-characteristic (ROC) analysis to evaluate the diagnostic performance of each imaging modality. We also used an ROC contrast estimation to compare the diagnostic capability of the 2 modalities on a per-patient basis. In the determination of whether the area under the ROC curve (AUC) values were different, the correlation of the testing methods was accounted for in the analysis. Tests for differences in sensitivity, speci-

ficity, and accuracy between the imaging modalities were conducted with the McNemar test. We also examined whether there was a significant difference in the mean SUVmax for local lesions, lymph node metastasis, bone metastasis, and all lesions between ^{11}C -choline and FDG PET/CT by using a paired *t*-test. *P*-values < 0.05 were considered significant. All statistical analyses were performed using SAS software (ver. 9.3; SAS Institute, Cary, NC, USA).

Results

Local recurrence or primary prostate tumor.

Eleven (55%) of the 20 patients were shown to have 12 local recurrent or primary lesions (7 local recurrent lesions, 5 cases of untreated primary prostate cancer). The 7 local recurrent lesions consisted of 5 in the prostate gland and 2 in the seminal vesicles. In the 5 pretreatment patients, ^{11}C -choline PET/CT was able to detect all 5 cases of prostate cancer, whereas FDG-PET/CT detected only 3. In the 15 posttreatment patients, ^{11}C -choline PET/CT was able to detect four of 5 intra-prostate recurrent lesions and both of the 2 seminal vesicle lesions, whereas FDG-PET/CT detected only 2 of the 4 intra-prostate recurrent lesions.

The patient-based and lesion-based sensitivities of ^{11}C -choline PET/CT compared to FDG-PET/CT were 90.9% (10/11) versus 45.5% (5/11) and 91.7% (11/12) versus 41.7% (5/12) ($p=0.074$ and $p=0.041$), respectively (Tables 2,3). The SUVmax values for the 12 locally recurrent lesions shown by both ^{11}C -choline PET/CT and FDG-PET/CT were 6.18 ± 2.57 and 3.71 ± 5.06 , respectively ($p=0.044$) (Table 3). A representative case is shown in Fig. 1.

Lymph node metastasis. Nine (45%) of the 20 patients were shown to have 25 metastatic lymph nodes (6 outer inguinal, 5 inter-inguinal, 2 obturator, 2 common inguinal, 5 para-aortic, 2 mediastinal, 2 supraclavicular, 1 inguinal). The patient- and lesion-based sensitivity of ^{11}C -choline PET/CT compared to FDG-PET/CT was 88.9% (8/9) versus 44.4% (4/9) and 92.0% (23/25) versus 32.0% (8/25) ($p=0.13$ and $p=0.0030$), respectively (Tables 2,3). Two false-negative cases determined by ^{11}C -choline PET/CT were tiny para-aortic metastatic nodes measuring 4 and 5 mm. The SUVmax values of the 25 metastatic nodes shown by both ^{11}C -choline PET/CT and FDG-PET/CT were 6.88 ± 3.69 and 1.54 ± 2.06 , respectively ($p < 0.00001$)

Table 2 Patient-based diagnostic result of ¹¹C-choline PET/CT and FDG-PET/CT

	Sensitivity 95%CI	Specificity 95%CI	Accuracy 95%CI	AUC 95%CI
Local Recurrence or untreated primary tumor				
¹¹ C-Choline PET/CT	90.9% (10/11) 73.9~100%	100% (9/9) 100%	95.0% (19/20) 85.4~100%	1.0
FDG-PET/CT	45.5% (5/11) 16.0~74.9%	100% (9/9) 100%	70.0% (14/20) 49.9~90.1%	0.773 0.585-0.891
<i>p</i> value	0.074	1.0	0.074	0.0039
Lymph node metastasis				
¹¹ C-Choline PET/CT	88.9% (8/9) 68.3~100%	100% (11/11)	95.0% (19/20) 85.4~100%	0.944 0.681-0.993
FDG-PET/CT	44.4% (4/9) 12.0~76.9%	100% (11/11)	75.0% (15/20) 56.0~94.0%	0.722 0.524-0.860
<i>p</i> value	0.13	1.0	0.13	0.011
Bone metastasis				
¹¹ C-Choline PET/CT	84.6% (11/13) 65.0~100%	100% (7/7)	90.0% (18/20) 76.9~100%	0.951 0.745-0.992
FDG-PET/CT	76.9% (10/13) 54.0~99.8%	100% (7/7)	85.0% (17/20) 69.4~100%	0.962 0.765-0.995
<i>p</i> value	1.0	1.0	1.0	0.851
All lesions				
¹¹ C-Choline PET/CT	94.4% (17/18) 83.9~100%	100% (2/2)	95.0% (19/20) 85.4~100%	1.0
FDG-PET/CT	66.7% (12/18) 44.9~88.4%	100% (2/2)	70.0% (14/20) 44.9~90.1%	0.889 0.746-0.956
<i>p</i> value	0.074	1.0	0.074	0.028

AUC, area under the receiver-operating-characteristic curves; CI, confidence interval; PET/CT, positron emission tomography/computed tomography.

Table 3 Lesion-based diagnostic sensitivity of ¹¹C-choline PET/CT and FDG PET/CT

	¹¹ C-choline PET/CT	FDG PET/CT	<i>p</i> value
Local Recurrence or primary tumor			
Sensitivity	91.7% (11/12)	41.7% (5/12)	0.041
95% CI	76.0~100%	13.8~69.6%	
SUVmax	6.18 ± 2.57	3.71 ± 5.06	0.044
Lymph node metastasis			
Sensitivity	92.0% (23/25)	32.0% (8/25)	0.00030
95% CI	81.4~100%	13.7~50.3%	
SUVmax	6.88 ± 3.69	1.54 ± 2.06	<0.0001
Bone metastasis			
Sensitivity	94.8% (145/153)	83.0% (127/153)	<0.0001
95% CI	91.2~98.3%	77.1~89.0%	
SUVmax	5.59 ± 2.60	4.43 ± 2.96	<0.0001
All lesions			
Sensitivity	94.2% (179/190)	73.7% (140/190)	<0.0001
95% CI	90.9~97.5%	67.4~79.9%	
SUVmax	5.79 ± 2.79	4.00 ± 3.16	<0.0001

PET/CT, positron emission tomography/computed tomography; CI, confidence interval; SUVmax, maximum standard uptake value.

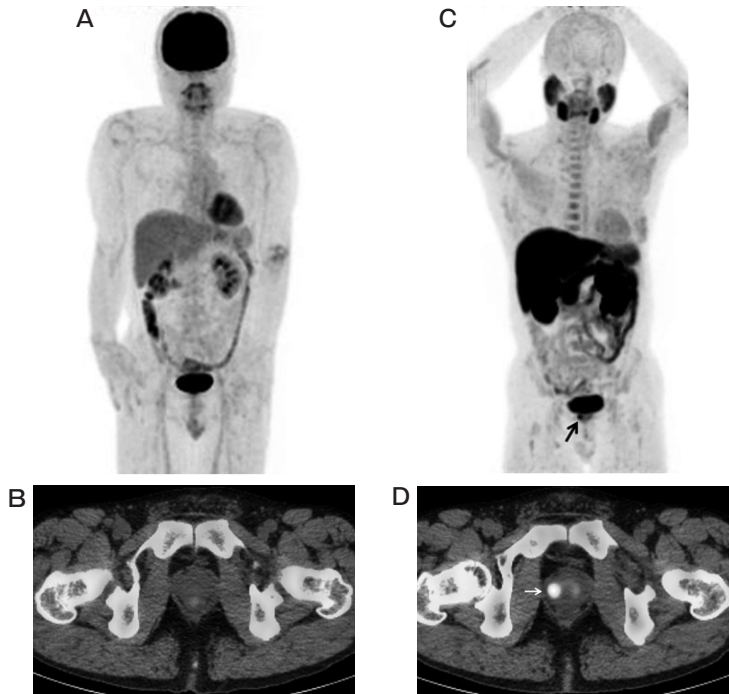


Fig. 1 Representative case of a 50-year-old man with prostate cancer (Gleason score 4+3) and PSA level 15.76 ng/mL. **A**, Maximum intensity projection (MIP) from FDG-PET showing no abnormal findings; **B**, FDG-PET/CT image showing no abnormal findings at the same level as panel **D** below; **C**, MIP from ^{11}C -choline PET showing abnormal ^{11}C -choline uptake in the right side of the prostate gland (*arrow*); **D**, ^{11}C -choline PET/CT image showing moderate ^{11}C -choline uptake (SUVmax 5.22) in the right side of the prostate (*arrow*), reflecting primary prostate cancer.

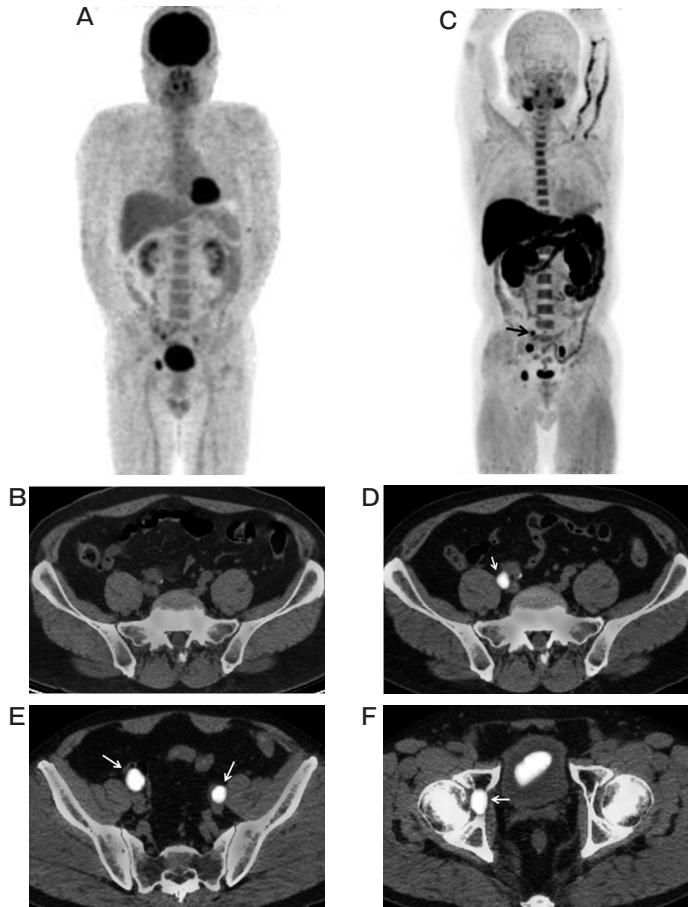


Fig. 2 A 66-year-old man with a PSA level of 4.68 ng/mL who underwent radiotherapy and androgen-deprivation therapy for prostate cancer (cT4N0M0, initial PSA 79.5 ng/mL), in whom pelvic node and bone metastasis was found. **A**, MIP from FDG PET showing three abnormal FDG uptake spots in the pelvis; **B**, FDG-PET/CT image showing no abnormal findings at the same level as panel **D** below; **C**, MIP from ^{11}C -choline PET showing four abnormal ^{11}C -choline uptake spots in the pelvis, including the right internal iliac area (*arrow*); **D**, ^{11}C -choline PET/CT image showing strong ^{11}C -choline uptake (SUVmax 6.35) in the right 6-mm internal iliac node (*arrow*), suggesting lymph node metastasis; **E**, ^{11}C -choline PET/CT image showing strong ^{11}C -choline uptake in the right 14-mm external iliac (SUVmax 13.90) and left 8-mm external iliac (SUVmax 9.01) nodes (*arrows*), reflecting lymph node metastasis; **F**, ^{11}C -choline PET/CT image showing strong ^{11}C -choline uptake (SUVmax 11.77) in the right acetabular cartilage (*arrow*), reflecting bone metastasis.

(Table 3). A representative case is shown in Fig. 2.

Bone metastasis. Thirteen (65%) of the 20 patients were shown to have 153 metastatic bone lesions (14 cervical vertebra, 28 thoracic vertebra, 16 lumbar vertebra, 13 sacral vertebra, three sternum, 2 clavicle, 12 rib, nine scapula, 14 iliac bone, 8 pubic, 8 ischium, 10 acetabulum, 5 upper extremities, 8 lower extremities, 3 skull). The patient-based and lesion-based sensitivity of ^{11}C -choline PET/CT compared to FDG-PET/CT was 84.69% (11/13) versus 76.9% (10/13) and 94.8% (145/153) versus 83.0% (127/153) ($p=1.0$ and $p<0.00001$), respectively (Tables 2,3). Eight false-negative cases shown by ^{11}C -choline PET/CT were composed of 1 cervical vertebral, 1 thoracic vertebra, 1

lumbar vertebra, 1 sacral vertebra, 2 scapula, and 2 rib locations. The SUVmax values of the 153 bone metastases shown by both ^{11}C -choline PET/CT and FDG-PET/CT were 5.59 ± 2.60 and 4.43 ± 2.96 , respectively ($p<0.0001$) (Table 3). Two representative cases are shown in Fig. 2 and 3.

Of the 153 metastatic bony lesions, 109 (71.2%) were osteoblastic, 13 (8.5%) were osteolytic, three (2.0%) were mixed, and 28 (18.3%) were invisible according to the CT morphological type (Table 4). The visualization rate of ^{11}C -choline compared to FDG PET/CT was 94.5% versus 84.4% for the osteoblastic type, 84.6% versus 45.5% for the osteolytic type, 100% versus 100% for the mixed type, and 100% versus 96.4%

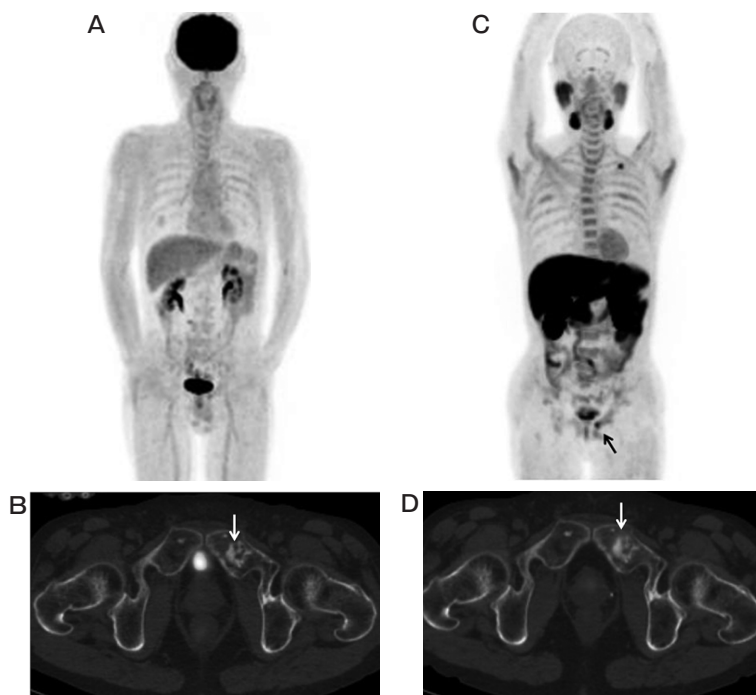


Fig. 3 A 69-year-old man with a PSA level of 4.52 ng/mL who underwent androgen-deprivation therapy for prostate cancer (cT3N1M1, initial PSA 221 ng/mL), in whom bone metastasis was found; **A**, MIP from FDG PET showing no abnormal findings; **B**, FDG-PET/CT image showing no abnormal FDG uptake in the region of osteoblastic change in the left pubic area (arrow) at the same level as **D** below, suggesting an absence of viability; **C**, MIP from ^{11}C -choline PET showing 2 abnormal ^{11}C -choline uptake spots in the left inferior clavicular and left pubic (arrow) areas. The abnormal uptake in the left inferior clavicular area was thought to be physiological uptake pooled in the left subclavian vein; **D**, ^{11}C -choline PET/CT image showing moderate ^{11}C -choline uptake (SUVmax 4.45) in the region of osteoblastic change in the left pubic area (arrow), reflecting active bone metastasis.

Table 4 The visualization rates of ^{11}C -choline PET/CT and FDG PET/CT for the different CT types of bone metastases

CT pattern	Lesion no. (%)	Sensitivity of ^{11}C -choline PET/CT	Sensitivity of FDG PET/CT	p value	SUVmax on ^{11}C -choline PET/CT	SUVmax on FDG PET/CT	p value
Osteoblastic	109 (71.2%)	94.5% (103/109)	84.4% (92/109)	0.0026	5.18 ± 2.40	4.29 ± 2.14	0.00098
Osteolytic	13 (8.5%)	84.6% (11/13)	45.5% (5/11)	0.041	4.52 ± 2.99	1.56 ± 2.61	0.0018
Mixed	3 (2.0%)	100% (3/3)	100% (3/3)	1.0	8.47 ± 4.85	6.17 ± 2.91	0.29
Invisible	28 (18.3%)	100% (28/28)	96.4% (27/28)	1.0	7.36 ± 2.02	6.11 ± 4.47	0.0047
Total	153 (100%)	94.8% (145/153)	83.0% (127/153)	<0.0001	5.59 ± 2.60	4.43 ± 2.96	<0.0001

SUVmax, maximum standardized uptake value; PET/CT, Positron emission tomography/computed tomography.

for the invisible type. The sensitivity of ^{11}C -choline PET/CT was significantly higher than that of FDG-PET/CT for both the osteoblastic and osteolytic types ($p=0.0026$ and $p=0.041$, respectively).

Discussion

In the present study, we found that compared to FDG-PET/CT, ^{11}C -choline PET/CT has significantly higher sensitivity for diagnosing local recurrence or untreated primary prostate cancer, as well as nodal and bone metastasis. This is the first report to present a comparison of ^{11}C -choline PET/CT and FDG-PET/CT for staging and restaging prostate cancer in Japanese men. To the best of our knowledge, 4 studies have directly compared the diagnostic performance of choline PET/CT with that of FDG-PET/CT for the detection and localization of prostate cancer in non-Japanese men [6-9]. The authors of 3 of those studies reported that ^{11}C -choline PET/CT has significantly higher patient-based sensitivity for restaging prostate cancer compared to FDG-PET/CT [6-8], similar to our present results. The patient-based sensitivity for ^{11}C -choline PET/CT compared to FDG-PET/CT in those three reports was 47% versus 27% [6], 68% versus 34% [7], and 61% versus 31% [8]. Only a single study has reported that ^{18}F -fluorocholine PET/CT and FDG-PET/CT showed the same patient-based sensitivity (79%) for staging and restaging prostate cancer [9].

In Western countries, ^{11}C - and ^{18}F -choline PET/CT have been successfully used for the restaging of prostate cancer in patients with biochemical disease recurrence after undergoing definitive therapy, especially when the PSA level is >1.0 ng/mL [1-3, 11]. One systematic review and meta-analysis of 19 selected studies with a total of 1,555 patients reported pooled sensitivity of 85.6% and pooled specificity of 92.6% [12]. Picchio *et al.* concluded that the routine use of ^{11}C -choline PET/CT for the restaging of prostate cancer after a radical prostatectomy cannot be recommended for patients with a PSA value <1 ng/mL [11]. They also commented that in addition to the PSA value, the PSA doubling time and other clinical and pathological features, including locally advanced tumor (pT3a-T4) or lymph node involvement at the initial staging should be considered when referring patients for ^{11}C -choline PET/CT.

Although choline-PET/CT has limitations for

detecting primary prostate cancer, it may be useful in the minority of newly diagnosed patients with high clinical suspicion of distant metastatic disease (*e.g.*, serum PSA level >20 ng/mL, Gleason score 8-10, locally advanced tumor shown by palpation and/or MRI) [3]. In such cases, it would be highly desirable to identify patients with distant disease before they are exposed to the morbidity of localized therapy that may not be beneficial. Beheshti *et al.* [13] evaluated ^{18}F -fluorocholine PET/CT for the pretreatment staging of prostate cancer in 130 intermediate- and high-risk patients, and they demonstrated that the patient-based sensitivity and specificity for the detection of metastatic lymph nodes ≥ 5 mm in diameter were 66% and 96%, respectively, with 43 instances of bone metastasis detected in 13 patients. They also estimated that the results of a pretreatment ^{18}F -fluorocholine PET/CT examination would prompt a change of therapy in 15% of patients overall and 20% of high-risk patients.

The potential influence of anti-androgenic treatment in patients who undergo an ^{11}C -choline examination remains controversial. A significant reduction in ^{11}C -choline uptake following treatment with the nonsteroidal androgenic antagonist bicalutamide was reported during the staging phase of prostate cancer patients [14]. Conversely, in a population of 358 patients who had undergone a prostatectomy and showed an increased PSA serum level, androgen deprivation therapy was revealed as a variable that could significantly predict an increased risk of positive ^{11}C -choline PET/CT findings only when analyzed alone and not in comparison with other variables, primarily PSA-related values and the Gleason score [15]. One group also found that the accuracy of ^{11}C -choline PET/CT for detecting bone metastasis did not differ significantly between hormone-resistant patients and those who did not receive anti-androgenic treatment [16]. Based on these results, a withdrawal of anti-androgenic treatment cannot be recommended for the performance of ^{11}C -choline PET/CT examinations in hormone-resistant patients.

Our study has some limitations. First, only a small number of patients at a single institution were enrolled. A prospective, multicenter trial with a larger cohort would help to clarify the exact role of ^{11}C -choline PET/CT in clinical decision-making and long-term outcomes in a clinical setting. Second, the enrolled population was heterogeneous, as it included patients with pre-

treatment and post-treatment prostate cancer and treatment-naïve patients, as well as those with or without hormonal treatment. Such heterogeneity likely introduced confounding factors into the analysis. Third, the ideal gold standard for any analysis is the histological confirmation of obtained findings. However, clinical follow-up is known to be a valid approach for the evaluation of diagnostic accuracy and response to therapy, and it would have been unethical to investigate all PET/CT-detected lesions with the use of an invasive procedure. Although positive findings are easy to confirm, negative findings only indicate that it was not possible to acquire positive findings during follow-up, making it uncertain whether the findings are truly negative. Fourth, new and more sensitive PET tracers for prostate cancer, such as ^{18}F -FACBC and ^{68}Ga -PSMA, were recently introduced for clinical use in Western countries [2], but they are not yet available in Japan.

In conclusion, ^{11}C -choline PET/CT is a convenient and noninvasive one-step procedure for the staging and restaging of prostate cancer in Japanese men.

References

1. Kitajima K, Murphy RC, Nathan MA and Sugimura K: Update on positron emission tomography for imaging of prostate cancer. *Int J Urol* (2014) 21: 12–23.
2. Kitajima K, Yamamoto S, Fukushima K, Minamimoto R, Kamai T and Jadvar H: Update on advances in molecular PET in urological oncology. *Jpn J Radiol* 2016; 34: 470–485.
3. Kitajima K, Murphy RC and Nathan MA: Choline PET/CT for imaging prostate cancer: an update. *Ann Nucl Med* (2013) 27: 581–591.
4. Kitajima K, Murphy RC, Nathan MA, Froemming AT, Hagen CE, Takahashi N and Kawashima A: Detection of recurrent prostate cancer after radical prostatectomy: comparison of ^{11}C -choline PET/CT with pelvic multiparametric MR imaging with endorectal coil. *J Nucl Med* (2014) 55: 223–232.
5. Uchida T and Yamashita S: Molecular cloning, characterization, and expression in *Escherichia coli* of a cDNA encoding mammalian choline kinase. *J Biol Chem* (1992) 267: 10156–10162.
6. Picchio M, Messa C, Landoni C, Gianolli L, Sironi S, Brioschi M, Matarrese M, Matei DV, De Cobelli F, Del Maschio A, Rocco F, Rigatti P and Fazio F: Value of [^{11}C]choline-positron emission tomography for re-staging prostate cancer: a comparison with [^{18}F] fluorodeoxyglucose-positron emission tomography. *J Urol* (2003) 169: 1337–1340.
7. Garcia JR, Soler M, Blanch MA, Ramirez I, Riera E, Lozano P, Pérez X, Delgado E, Carrio I and Lomeña F: PET/CT with ^{11}C -choline and ^{18}F -FDG in patients with elevated PSA after radical treatment of a prostate cancer. *Rev Esp Med Nucl* (2009) 28: 95–100.
8. Richter JA, Rodríguez M, Rioja J, Peñuelas I, Martí-Climent J, Garrastachu P, Quincoces G, Zudaire J and García-Velloso MJ: Dual tracer ^{11}C -choline and FDG-PET in the diagnosis of biochemical relapse after radical treatment. *Mol Imaging Biol* (2010) 12: 210–217.
9. Beaugerard JM, Williams SG, Degrado TR, Roselt P and Hicks RJ: Pilot comparison of F-fluorocholine and F-fluorodeoxyglucose PET/CT with conventional imaging in prostate cancer. *J Med Imaging Radiat Oncol* (2010) 54: 325–332.
10. Hara T and Yuasa M: Automated synthesis of [^{11}C]choline, a positron-emitting tracer for tumor imaging. *Appl Radiat Isot* (1999) 50: 531–533.
11. Picchio M, Briganti A, Fanti S, Heidenreich A, Krause BJ, Messa C, Montorsi F, Reske SN and Thalmann GN: The role of choline positron emission tomography/computed tomography in the management of patients with prostate-specific antigen progression after radical treatment of prostate cancer. *Eur Urol* (2011) 59: 51–60.
12. Evangelista L, Zattoni F, Guttilla A, Saladini G, Zattoni F, Colletti PM and Rubello D: Choline PET or PET/CT and biochemical relapse of prostate cancer: a systematic review and meta-analysis. *Clin Nucl Med* (2013) 38: 305–314.
13. Beheshti M, Imamovic L, Broinger G, Vali R, Waldenberger P, Stoiber F, Nader M, Gruy B, Janetschek G and Langsteger W: ^{18}F choline PET/CT in the preoperative staging of prostate cancer in patients with intermediate or high risk of extracapsular disease: a prospective study of 130 patients. *Radiology* (2010) 254: 925–933.
14. Giovacchini G, Picchio M, Coradeschi E, Scattoni V, Bettinardi V, Cozzarini C, Freschi M, Fazio F and Messa C: [^{11}C]choline uptake with PET/CT for the initial diagnosis of prostate cancer: relation to PSA levels, tumour stage and anti-androgenic therapy. *Eur J Nucl Med Mol Imaging* (2008) 35: 1065–1073.
15. Giovacchini G, Picchio M, Coradeschi E, Bettinardi V, Gianolli L, Scattoni V, Cozzarini C, Di Muzio N, Rigatti P, Fazio F and Messa C: Predictive factors of [^{11}C]choline PET/CT in patients with biochemical failure after radical prostatectomy. *Eur J Nucl Med Mol Imaging* (2010) 37: 301–309.
16. Picchio M, Spinapoliche EG, Fallanca F, Crivellaro C, Giovacchini G, Gianolli L and Messa C: [^{11}C]Choline PET/CT detection of bone metastases in patients with PSA progression after primary treatment for prostate cancer: comparison with bone scintigraphy. *Eur J Nucl Med Mol Imaging* (2012) 39: 13–26.