



Carotid artery thrombosis and cerebral infarction after multiple traumas

Gholamreza Faridaalae¹, Bahman Naghipour², Sajjad Ahmadi¹, Seyed Hesam Rahmani^{3*}¹Emergency Medicine Department, Maragheh University of Medical Sciences, Maragheh, Iran²Department of Anesthesiology, Madani Hospital, Tabriz University of Medical Sciences, Tabriz, Iran³Emergency Medicine Department, Imam Khomeini Hospital, Urmia University of Medical Sciences, Urmia, Iran**Received:** 18 November 2015**Accepted:** 18 December 2015**Published online:** 29 January 2016***Corresponding author:** Seyed Hesam Rahmani, Emergency Medicine Department, Imam Khomeini Hospital, Urmia University of Medical Sciences, Urmia, Iran. Tel: +989121167809; Fax: 041133858859; Email: rahmani_h@umsu.ac.ir**Competing interests:** None.**Funding information:** None.**Citation:** Faridaalae G, Naghipour B, Ahmadi S, Rahmani SH. Carotid artery thrombosis and cerebral infarction after multiple traumas. *Journal of Emergency Practice and Trauma* 2017; 3(2): 68-70. doi: 10.15171/jept.2016.01.

Abstract

Carotid artery thrombosis and concomitant brain infarction after blunt trauma are rare conditions. We report a 34-year-old woman with multiple traumas due to pedestrian car accident. At the time of initial visiting, she was somnolent and her Glasgow coma scale (GCS) score was 14. Initial vital signs (V/S) and brain computed tomography (CT) scan were normal. One day after admission to the emergency observation unit, GCS improved to 15 but right-sided hemiparesis occurred. Magnetic resonance imaging (MRI) showed brain infarction and Doppler sonography indicated internal carotid artery thrombosis. She was admitted in the Neurosurgery ward and underwent anticoagulant therapy. With appropriate treatment, the patient's condition improved after 5 days of admission and she was discharged on oral warfarin treatment and close follow up. Although there is no ideal treatment for traumatic internal carotid artery thrombosis, it seems that in most cases anticoagulation therapy is the preferred method of treatment but in some patients surgical or endovascular revascularization is indicated.

Keywords: Trauma, Brain, Infarction, Accidents

Introduction

Significant carotid artery injuries due to blunt trauma cause delayed neurologic deficit and can occur in 0.08% to 0.86% of cases, with a mortality rate up to 40% (1-3). In 85% of reported cases, the extracranial internal carotid artery (ICA) or carotid bifurcation is involved and an intimal tear or mural contusion is thought to be the underlying cause of thrombotic occlusion (4,5). Brain infarction occurs due to occlusion of brain blood flow and the most common symptom of carotid and vertebrobasilar artery occlusion is hemiplegia and hemiparesis. We report an uncommon case of brain infarction and carotid artery thrombosis after multiple traumas in a 34-year-old woman.

Case Presentation

Emergency medical service (EMS) brought a 34-year-old woman to the emergency room with multiple traumas due to pedestrian car accident while crossing the street. The car speed was about 40-50 km/h. Her past medical history was insignificant. At the time of initial visit, she was somnolent and her Glasgow coma scale (GCS) was 14. The pupils were midsize and reactive. Neurologic examination was normal and muscle strength was symmetric and improved to V/V. Initial vital signs were as below: Pulse rate (PR) = 78/min, respiratory rate (RR)

= 18/min, blood pressure (BP) = 110/70 mm Hg, axillary temperature (AT) = 36.4, (SPO₂) = 98%. Initial brain computed tomography (CT) scan was normal. Initial laboratory tests and radiography of neck, pelvic, chest and serial extended focused assessment with sonography for trauma (EFAST) were normal. With regard to somnolence, we decided to admit her to the emergency observation unit and performed serial physical examination. One day after admission to the observation unit, patient complains of reducing right sided extremities muscle strength and in physical examination, we found right-sided hemiparesis. Based on the examination, right upper extremity muscle strength was III/V and right lower extremity muscle strength was IV/V. The brain magnetic resonance imaging (MRI) showed acute cerebral infarction in the left side of brain (Figure 1A-C) and the Doppler sonography showed ICA thrombosis. We admitted her in the Neurosurgery ward and started treatment with unfractionated heparin (UH) and warfarin. Five days later, her right upper and lower extremity muscle strength improved to IV/V and V/V respectively. She was discharged on oral warfarin for 5 mg/day and close follow-up.

Discussion

Most physicians think that brain infarction after trauma is



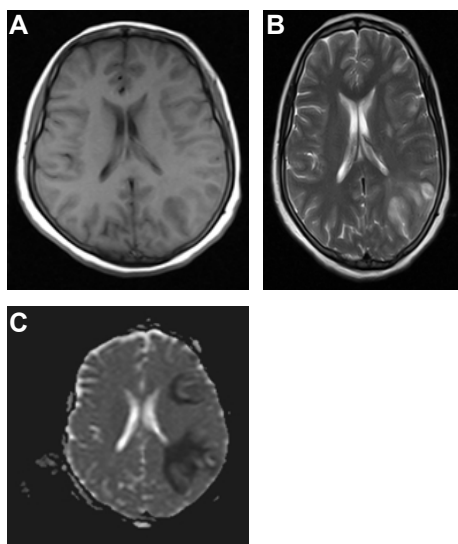


Figure 1. (A) Brain MRI T1. (B) Brain MRI T2. (C) Brain MRI DW.

rare. In one study, the calculated annual hospital frequency rate of stroke was 27.1/100 000 of the pediatric population (6). Because of clinical presentation of brain trauma, the diagnosis of brain infarction after trauma is difficult and we must consider it for all patients with cervical and head trauma.

Kilinçer et al reported in 2008 a case of cerebral infarction after traumatic carotid artery injury and concluded that the incidence of traumatic carotid dissection and thrombosis is higher than previously observed (7).

Martin and Humphrey in 1998 reported a case of stroke occurring five months after ICA injury (8).

Yamada et al in 1967 and DiVincenti et al in 1994 reported that the usual evolution of symptoms is slower than might be expected after major arterial trauma, and the subsequent delay in diagnosis and treatment may unfavorably influence the prognosis (5,9).

Bradley in 1973 and Thal et al in 1976 described certain clinical features that may assist in making a diagnosis of blunt carotid injury (hematoma of lateral neck, Homer syndrome, transient attack of ischemia, lucid interval, limb paresis in an alert patient). These patients often have other injuries and assessing neurologic deficits may be difficult in the presence of associated closed head trauma. Early separation of these patients from those with carotid artery injuries is important since restoration of carotid blood flow prior to the onset of irreversible neurologic damage is necessary if the reported mortality rate of 40% is to be reduced (10,11).

Perry et al (12) in 1980 reported a series of 17 patients with carotid-blunt trauma, 3 without any symptoms, 10 patients had limb paresis and 4 had severe neurologic injury. Surgery was attempted in 15 of them and was successful in 8. These 8 patients with successful repair were improved after surgery, but only 2 of 9 patients improved without repair, and 4 died. The mortality rate in these series was 23%. This experience suggests that repair is safe and effective in patients with carotid injuries that

have only mild neurologic deficits. In contrast, patients with complete occlusion, severe neurologic deficits and loss of consciousness are not appropriate for attempts at revascularization (12).

In a study by Biffi et al (13) in 1998, using screening with arteriography, they determined the benefit of early diagnosis in blunt carotid artery injuries. Patients without specific contraindications were anticoagulated and endovascular stents were used in the setting of pseudoaneurysms. Thirty-seven patients were identified among 15331 blunt-trauma patients. During the screening period, 25 patients were asymptomatic. Eight patients died and 7 of the survivors had permanent severe neurologic deficits. Mortality rate associated with blunt carotid artery injuries was 15% and severe neurologic morbidity was 16%. Asymptomatic patients at diagnosis had a better neurologic outcome than those who were symptomatic. Symptomatic patients who were treated with anticoagulant showed a trend toward better neurologic improvement at the time of discharge than those who were not anticoagulated. They concluded that screening allows the identification of asymptomatic patients and facilitates early systemic anticoagulation, which is associated with improved neurologic outcome (13).

In 1996, Fabian et al published the largest single institution BCI experience and demonstrated improved neurologic deficits when patients were fully treated with heparin (14). Faridaalae et al in 2014 reported a case of posttraumatic hemicerebral infarction in a 4-year-old girl who was involved in a car accident. On admission time, her GCS score was 8 and her vital signs were stable. Brain CT scan showed a subdural hematoma (SDH). In second day, GCS decreased to 5 and control brain CT showed a brain infarction. Six days after admission, her GCS decreased to 3 and her pupils became dilated bilaterally and unresponsive to light, she was pronounced dead (15). Behzadnia et al in 2015 reported a case of posttraumatic cerebellar infarction in a 2-year-old who sustained head injury in a car accident 30 minutes before admission. At presentation, GCS was 8. CT scan revealed left-sided frontal contusions, fronto-temporo-parietal and interhemispheric acute SDH, and considerable midline shift. The patient underwent craniotomy emergently. Second day after surgery, the patient showed neurological deterioration (GCS: 3 and bilateral dilated nonreactive pupils) and circulatory collapse. Urgent brain CT scanning showed large bilateral cerebellar and occipital infarct. Despite all aggressive measures, she had another episode of cardio-respiratory arrest on the third postoperative day and died (16).

Acknowledgements

We express our thanks to the staff of the emergency and neurosurgery departments of Imam Khomeini hospital in Urmia.

Ethical issues

Written informed consent was obtained from the patient

for publishing this case and any accompanying images.

Authors' contributions

Writing manuscript; SHR, SA. Original idea; GF. Data gathering; BN.

References

1. Biffi WL, Moore EE, Elliott JP, Ray C, Offner PJ, Franciose RJ, et al. The devastating potential of blunt vertebral arterial injuries. *Ann Surg* 2000; 231(5): 672-81.
2. Inamasu J, Guiot BH. Vertebral artery injury after blunt cervical trauma: an update. *Surg Neurol* 2006; 65(3): 238-45.
3. Yanagawa Y, Iwamoto S, Nishi K. Pontine infarction induced by injury of the perforating branch of the basilar artery after blunt head impact: case report. *Neurol Med Chir (Tokyo)* 2008; 48(8): 343-6.
4. Crissey MM, Bernstein EF. Delayed presentation of carotid intimal tear following blunt craniocervical trauma. *Surgery* 1974; 75(4): 543-9.
5. Yamada S, Kindt GW, Youmans JR. Carotid artery occlusion due to nonpenetrating injury. *J Trauma* 1967; 7(3): 333-42.
6. Al-Sulaiman A, Bademosi O, Ismail H, Magboll G. Stroke in Saudi children. *J Child Neurol* 1999;14(5): 295-8.
7. Kiliñer C, Tiriyaki M, Celik Y, Turgut N, Balci K, Utku U, et al. Cerebral infarction due to traumatic carotid artery dissection: case report and review of current management. *Ulus Travma Acil Cerrahi Derg* 2008; 14(4): 333-7. [In Turkish].
8. Martin P, Humphrey PR. Disabling stroke arising five months after internal carotid artery dissection. *J Neurol Neurosurg Psychiatry* 1998; 65(1): 136-7. doi: 10.1136/jnnp.65.1.136.
9. DiVincenti F, Weber B. Traumatic carotid artery injuries in civilian practice. *Am Surg* 1974; 40(5): 277-80.
10. Bradley EL 3rd. Management of penetrating carotid injuries: an alternative approach. *J Trauma* 1973; 13(3): 248-55.
11. Thal E, Snyder W 3rd, Hays R, Perry M. Management of carotid artery injuries. *Surgery* 1974; 76(6): 955-62.
12. Perry MO, Snyder WH, Thal ER. Carotid artery injuries caused by blunt trauma. *Ann Surg* 1980; 192(1): 74-7.
13. Biffi WL, Moore EE, Ryu RK, Offner PJ, Novak Z, Coldwell DM, et al. The unrecognized epidemic of blunt carotid arterial injuries: early diagnosis improves neurologic outcome. *Ann Surg* 1998; 228(4): 462-70.
14. Fabian TC, Patton JH Jr, Croce MA, Minard G, Kudsk KA, Pritchard FE. Blunt carotid injury. Importance of early diagnosis and anticoagulant therapy. *Ann Surg* 1996; 223(5): 513-22.
15. Faridaalae G, Taghian A, Sattarzadeh Ghadim T. Posttraumatic hemispheric infarction in a four-year-old girl. *Trauma Mon* 2014; 19(4): e16054. doi: 10.5812/traumamon.16054.
16. Behzadnia H, Emamhadi MR, Yousefzadeh-Chabok S, Alijani B. Posttraumatic cerebellar infarction in a 2-year-old child. *Caspian Journal of Neurological Sciences* 2015; 1(1): 49-54.