

Surgical management of cardiac tamponade: Is left anterior minithoracotomy really safe and effective?



Mirko Barone*, Marco Prioletta, Giuseppe Cipollone, Decio Di Nuzzo, Pierpaolo Camplese, Felice Mucilli

Department of General and Thoracic Surgery, University Hospital of Chieti, Chieti, Italy

Received: 1 September 2016
Accepted: 18 November 2016
Published online: 27 May 2017

***Corresponding author:** Mirko Barone, MD; Department of General and Thoracic Surgery, University Hospital "SS. Annunziata" of Chieti, Italy.
Phone: +39 0871 358289;
Fax: +39 0871 358220;
Email: mir87mb@libero.it

Competing interests: None.

Funding information: None.

Citation: Barone M, Prioletta M, Cipollone G, Di Nuzzo D, Camplese P, Mucilli F. Surgical management of cardiac tamponade: Is left anterior minithoracotomy really safe and effective? *Journal of Emergency Practice and Trauma* 2017; 3(2): 53-58. doi: 10.15171/jept.2017.04.

Abstract

Objective: Cardiac tamponade is a life-threatening clinical entity that requires an emergency treatment. Cardiac tamponade can be caused both by benign and malignant diseases. A variety of methods have been described for the treatment of these cases from needle-guided pericardiocentesis, balloon-based techniques to surgical pericardiectomy. The Authors report their experience in surgical management of cardiac tamponade and an exhaustive review of literature.

Methods: This study involved 61 patients (37 males and 24 females) with an average age of 61.80 ± 16.32 years. All patients underwent emergency surgery due to the presence of cardiac tamponade.

Results: Cardiac tamponade was caused by a benign disease in 57.40% of patients. In cancer patients group, lung cancer, breast cancer and malignant pleural mesothelioma were the most common neoplasms (17-27, 87%). The average preoperative size of pericardial effusion at M-2D echocardiography was 30.15 ± 5.87 mm. Postoperative complications were observed in 11 patients (18%). The reoperation rate was 3.3% (2 patients) due to relapsed cardiac tamponade. 30-day mortality rate was 3.3%. Overall cumulative survival was 29.9 ± 20.1 months. Twenty-nine patients (47.5%) died during the follow up period. By dividing the population into two groups, group B (benign) and group M (malignant), there was a statistically significant difference ($P < 0.001$) in terms of survival.

Conclusion: In conclusions, anterior minithoracotomy for surgical treatment of cardiac tamponade has to be held into account in patients both with benign diseases and malignancies.

Keywords: Cardiac tamponade, Minithoracotomy, Pericardial malignancies, Overall survival

Introduction

Cardiac tamponade is a life-threatening clinical entity that requires an emergency treatment (1). It is characterized by hemodynamic abnormalities resulting from an increased pericardial pressure due to the accumulation of fluid (serum, blood, chyle, pus) leading to a restriction of the filling rate, a reduction in stroke volume and cardiac output (2).

Cardiac tamponade can be caused by pericarditis (idiopathic, viral), iatrogenic injury (percutaneous procedures, post-CABG), thoracic trauma, neoplasms (thoracic and extrathoracic ones), uremia, cirrhosis, collagen diseases, vasculitis, systemic lupus erythematosus, tuberculosis, Dressler syndrome, aortic dissection, oozing ventricular, aortic or ventricular blow-out (3). The diagnostic triad of cardiac tamponade, or Beck's triad, is the reduction of arterial blood pressure, increased venous pressure and quiet heart (4). Clinical signs of cardiac tamponade include hypotension, tachycardia, pulsus paradoxus, increased jugular pressure (Kussmaul's sign), muffled heart sounds, decreased ECG voltages and increased cardiac silhouette

on plain chest radiograph (2).

A variety of methods have been described for the treatment of these cases from needle-guided pericardiocentesis (5), balloon-based techniques to surgical pericardiectomy (6,7), aiming to detention of cardiac compression and prevention of re-accumulation (8).

Surgical techniques are usually associated with a lower risk of recurrence, especially in cancer patients. In Literature, minimally invasive (video-assisted thoracoscopic pericardial window) and invasive surgical accesses (subxiphoid pericardiectomy, pericardiectomy via median sternotomy or via left anterior minithoracotomy) (9-11) are described.

Methods

This study involved 61 patients (37 males and 24 females) observed from 2010 to 2015 with an average age of 61.80 ± 16.32 years (Table 1). All patients underwent emergency surgery due to the presence of cardiac tamponade. Diagnosis was clinical (arterial hypotension, tachycardia, dyspnoea, Kussmaul's sign, pulsus paradoxus) and radiographic (M- and 2D-mode echocardiography, computed



tomography (CT) angiography of the chest). In our department, all patients undergo a preoperative CT angiography of the chest in order to exclude any myocardial or aortic bulb injury (ventricular blow out or oozing, lacerations of the coronary vessels). In fact, in the presence of these lesions, patient management is entrusted to cardiac surgeons.

All patients underwent routine blood chemistry and blood gas analysis in order to complete diagnostic iter. On account of the emergency, all patients with pericardial effusion with hemodynamic impairment were quickly sent for surgery, a pleuro-pericardial window. The surgical technique involves a 4-6 cm left anterior minithoracotomy at the fourth intercostal space with patient in 45 degrees left lateral decubitus position. The angle allows a better exposure of the pericardial sac. After opening the pleural cavity, an intrapleural pericardiotomy ahead the left phrenic nerve is done, allowing a gradual and cautious detension of the pericardial sac. At the end of the pericardial drainage, a 3 × 3 cm piece of serous is picked up. The rationale is to perform a histological analysis of tissue and to pack an effective means between the pericardium and the left mediastinal pleura. After surgery, a chest drainage is placed. The average time of the intervention was 36 ± 21 minutes.

All data are presented as means with standard deviations and their minimum and maximum values. Categorical variables are presented as absolute (N) and percentage (%). The analysis of survival was performed with the use of Kaplan and Meier's method with relative curves. These were compared with the method of logarithmic regression. *P* values less than 0.05 were considered statistically significant.

Results

On admission, the cause of cardiac tamponade was unknown in most of patients (33-54, 10%). In two patients, cardiac tamponade was the first sign of an unknown metastatic tumor disease (lung adenocarcinoma and cardiac lymphoma). In the remaining cases, cardiac tamponade was secondary to the presence of a tumor within or outside the chest (one patient with metastatic carcinoma of the penis) or to a thoracic trauma (3-4, 92%).

Histologically, a benign disease was the cause of cardiac tamponade in 57.40% of patients (35 patients), such as refractory pericarditis (26-43, 33%), hydropericardium from decompensated cirrhosis or chronic renal insufficiency. In cancer patients group, lung cancer, breast cancer and malignant pleural mesothelioma were the most common neoplasms (17-27, 87%). Also, mediastinal tumors (thymoma, lymphoma, synovial sarcoma) may cause secondary cardiac tamponade (Table 2).

The average preoperative size of the pericardial effusion at M-2D echocardiography was 30.15 ± 5.87 mm. However, the amount of pericardial effusion can not be correlated to the onset of cardiac tamponade; in fact, in our experience, we have seen cases of conspicuous pericardial effusion without hemodynamic impairment due to the

onset of compensatory mechanisms such as pulmonary hypertension. The average hospital stay of the patients was 14.5 ± 9.6 days. The reason is to be found in patients' comorbidities and post-operative controls. In fact, all were echocardiographically screened (average postoperative pericardial effusion thickness: 3.8 ± 5.4 mm) and only, in the presence of resolution of the pericardial effusion, chest tube was removed (average time: 10.4 ± 6.4 days) (Table 1).

Postoperative complications were observed in 18% of

Table 1. General population characteristics

Drugs	No.	Percent
Sex		
Male	37	60.70
Female	24	39.30
Age	61.80	(18-94)
Hospital stay	14.5 ± 9.6	(6-60)
Preoperative fluid collection width	30.15 ± 5.87	(18.00-42.00)
Postoperative fluid collection width	3.8 ± 5.4	(0.00-33.00)
Chest drain permanence	10.4 ± 6.4	(4.00-45-00)
Complications ^a	11	18.00
Re-do surgery	2	3.30
Perioperative death	2	3.30
Cumulative OS ^b	29.90 ± 20.10	(0.00-67.00)
Group B	58.4 ± 2.88	
Group M	15.94 ± 2.93	
Death	29	47.5
Disease-related death	22	36.1

^a4 patients atrial fibrillation, 2 patients ventricular fibrillation, 2 patients relapsed cardiac tamponade, 2 patients respiratory failure, 1 patient anemia.

^b*P* < 0.001.

Table 2. Cardiac tamponade etiology

	No.	Percent
Etiology		
Benign	35	57.40
Malignant	26	42.60
Disease		
Chronic pericarditis	12	19.70
Pulmonary adenocarcinoma	6	9.80
Pulmonary squamous carcinoma	5	8.20
Breast cancer	3	4.90
Malignant pleural mesothelioma	3	4.90
Hydropericardium	5	8.20
Cardiac lymphoma	1	1.60
Non Hodgkin lymphoma	3	4.90
Penis cancer	1	1.60
Acute pericarditis	14	23.00
Thymoma	3	4.90
Thoracic trauma	3	4.90
Synovial sarcoma	1	1.60
Chylopericardium	1	1.60

patients (11 patients). Most cases were cardiac complications (atrial fibrillation, ventricular fibrillation, relapsed cardiac tamponade). Two cases of respiratory failure and one of anemia were also recorded. In our experience, there was no mention of post-operative cardiac herniations secondary to the pericardial window procedure.

The reoperation rate was 3.3% (2 patients) due to relapsed cardiac tamponade. In one case, the second surgical access was a median sternotomy.

Although packing a pleuro-pericardial window represents a surgical emergency, the 30-day mortality rate was only 3.3% (2 patients).

All patients observed from 2010 to 2015 were subjected to follow-up. Overall cumulative survival of the general population was 29.90 ± 20.10 months. Twenty-nine patients (47.5%) died during the follow up period. In 22 (75.87%) of these, death was due to the same disease causing the episode of cardiac tamponade. By dividing the population into two groups, group B (benign) and group M (malignant) there was a statistically significant difference ($P < 0.001$) in terms of survival. In fact, an average of 58.4 ± 2.88 (95% CI: 52.72 to 64.04) months was reported for group B patients and an average of 15.94 ± 2.93 (95% CI: 33.96 to 47.96) months for group M patients, respectively (Figure 1). This discrepancy is mainly due to the etiology of cardiac tamponade. In cancer patients, this hemodynamic manifestation could be the evolution of metastatic disease characterized by a poor and a dismal prognosis.

Discussion

Cardiac tamponade is a life-threatening clinical entity that may result in a rapidly fatal cardiogenic shock (1). Presentation of cardiac tamponade can range from a minimally symptomatic effusion to a state of complete cardiovascular decompensation. In fact, it may be silent (echocardiographic tamponade), may present with classic symptoms, Beck's triad (4) (clinical tamponade), or may be the cause of a hemodynamic collapse (terminal tamponade). The first two represent the most common conditions and, as

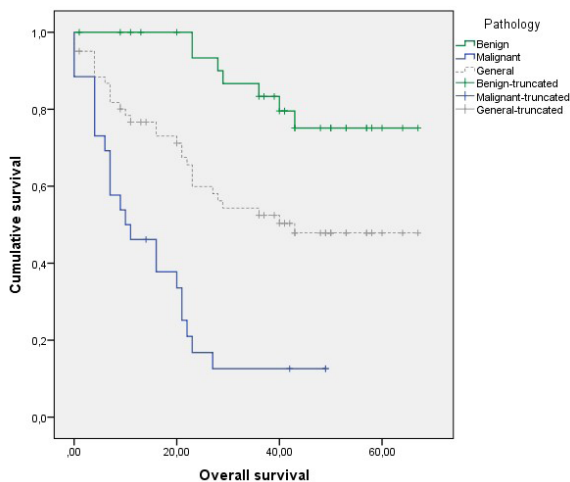


Figure 1. Probability of survival after cardiac tamponade (group B vs. group M).

reported by Tsang et al, they reach a percentage higher than 90% (5). Cardiac tamponade is associated with widespread low electrocardiographic voltages (12) due to changes in the electro-mechanical pulse and diffusion abnormalities of body impedance (13). These findings (low QRS complexes) recover up to 81% of cases (14,15) (Figure 2). Echocardiography is the main diagnostic test for the diagnosis of cardiac tamponade. The examination, performed in M- and 2D-mode, allows to evaluate the effusion thickness, the cardiac kinesis and indirect signs of hemodynamic dysfunction (Figure 3).

Cardiac tamponade can be caused by pericarditis (idiopathic, viral), iatrogenic injury (percutaneous procedures, post-CABG), thoracic trauma, neoplasms (thoracic and extrathoracic ones), uremia, cirrhosis, collagen diseases, chilopericardium (16), vasculitis, systemic lupus erythematosus (17), tuberculosis, hypothyroidism (18,19), Dressler syndrome, aortic or coronaric dissection (20), ventricular oozing, aortic or ventricular blow-out (3).

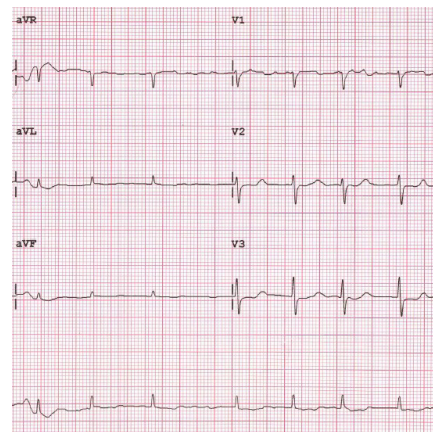


Figure 2. Cardiac tamponade: ECG findings (our personal case).

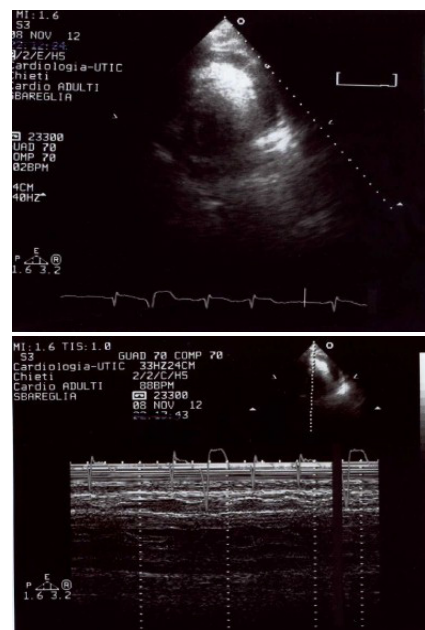


Figure 3. Cardiac tamponade: Echocardiographic findings (our personal case).

Allen et al (21), in a series of patients with cardiac tamponade, reported that more than 60% of the cases were from cancer, while the remaining from inflammatory processes and uremic states.

In our study, data seem to be in slight contrast. In fact, 57.40% of cases were due to benign diseases (chronic or acute refractory pericarditis), while the remainings from neoplasms. Among these latter, lung cancer (squamous cell carcinoma and adenocarcinoma) was the predominant one (18.0%), followed by malignant pleural mesothelioma, breast cancer and mediastinal tumors.

However, our results are confident with Literature, since more than half of secondary neoplasms of the pericardium are to be referred to lung cancer and breast cancer. The actual incidence of pericardial and myocardial metastatic diseases varies between 1% and 18% of all cancers (22).

Pericardial effusions are less common than pleural ones in cancer patients; although, their acute onset may rapidly deteriorate clinical conditions and significantly influence on prognosis.

Cardiac tamponade is a hemodynamic emergency that requires a rapid and timely intervention. But what is the gold standard of treatment is a discussed issue today. A variety of methods have been described from the needle-guided pericardiocentesis (5), balloon-based techniques to surgical pericardiectomy (6,7).

Needle-guided pericardiocentesis, considered the standard of treatment, is a rapid method for drainage. It may be adopted in hemodynamically unstable patients, in intensive care units or in patients who are unsuitable for surgery due to poor clinical conditions. It is well-tolerated in all age groups, including children (23), and it can be quickly performed in unstable patients to relieve symptoms (24). Moreover, it presents low mortality, low complications, but high recurrence rates.

Pericardiocentesis is life-saving and it is indicated for 20 mm or more effusions (diastolic width). The most dangerous complications are myocardial or coronaric lacerations but safety has been implemented with the adoption of echocardiographic or fluoroscopic guidance.

Maisch et al (25), in the European Society of Cardiology guidelines, reported major complication rates of about 1.3%-1.6%. Among these, cardiac perforations (0.9%) and arrhythmias (0.6%) are the most recurrent. Minor complications include pneumothorax, vasovagal response with transient hypotension, non-sustained supraventricular tachycardia and pleuropericardial fistula (5,26). Procedure-related mortality is low (<1%), while overall complications may vary from 4% to 20% (27,28). At the same time, Kopecky et al (29) and Celermajer et al (30) reported recurrence rates ranging from 19% to 24%. Finally, the procedure also allows to leave pericardial indwelling catheters for drainage or for locoregional chemotherapy (31-33).

Surgical procedures for pericardial drainage are: subxifoid pericardial window, transthoracic pericardial window (left anterior submammary minithoracotomy) and pericardiectomy via median sternotomy. The potential advantages

of a surgical approach are direct visualization, exploration of the entire pericardium, a complete drainage, biopsy of the pericardium for histological examination and the placement of a larger caliber drainage (34,35).

Subxifoid pericardial window is simple and reproducible (36). Kurimoto et al (37) also proposed the opportunity to perform a blind finger-assisted subxifoid pericardiectomy, highlighting the good efficacy of the procedure.

Video-assisted thoracoscopic pericardial window has many advantages: minor trauma, the ability to perform wider pericardial resections, the best visualization of anatomical structures and the possibility of posterior pericardial collection drainage (38). Muhammad (39) reported no intra and postoperative complications and mortality. Also, Georghiou et al (40) described no peri-procedural complications, but video-assisted surgery is still contraindicated in patients with impaired respiratory function contraindicating single-lung ventilation (9). In addition, pediatric cases with thoracoscopic access have been described (41,42). A modified video-assisted thoracoscopy technique was described by Monaco et al (43).

The creation of a pericardial window (subxifoid or transthoracic) is preferable in cancer patients in order to allow a permanent drainage. Our choice to perform a transthoracic pericardial window through a minithoracotomy finds comfort with papers in Literature. Olsen et al (44) believe the procedure is quick and simple. No cases of intra- or postoperative deaths are reported. Gregory et al (45), however, reported a mortality rate of 8%. Transthoracic surgery is rapid and it does not require a selective pulmonary intubation (Carlens' or Robertshaw's tube), as opposed for video thoracoscopic access, which could lead to the onset of a hemodynamic overload or a tachyarrhythmia due to selective intubation. In our study, we observed an overall mortality rate of 3.3% (one case of cardiac lymphoma and one case of malignant pleural mesothelioma); either due to the onset of electro-mechanical cardiac complications (ventricular fibrillation). Morbidity rate of 11.74% (7/11) in cancer patients. Celik et al (46) reported a median overall survival of 10.41 ± 1.79 months for cancer patients, while in our study we observed a survival rate of 15.94 ± 3.86 . In addition, we observed a low recurrence rate (3.3%), one in a cancer patient, and this data is significantly lower than those reported in literature both for pericardiocentesis and surgical cases. Regarding these cases, we believe the origin is to be found in the rapid establishment of post surgical adhesions leading to an altered drainage and therefore a failure of the pericardial window. Both episodes occurred within 30 days after surgery suggesting the onset of a post pericardiectomy syndrome. This clinical entity is classified as a specific form of iatrogenic or traumatic pericarditis and it is characterized by recurrent post surgical pericardial effusion. The syndrome is usually self-limited and it presents a variable incidence from 1% to 17.8% (47,48). Nishimura et al believe that causes are due to immune factors interfering with host response (49).

Conclusion

In conclusion, we believe the transthoracic surgical treatment of cardiac tamponade has to be held into account in patients both with benign diseases and malignancies. Our results, in terms of perioperative morbidity and mortality, are quite comparable to patients undergoing minimally invasive or percutaneous procedures. Moreover, low mortality and recurrence rates demonstrate pericardial window via anterior minithoracotomy can be considered a safe and effective method in the treatment of cardiac tamponade.

Authors' contributions

All authors contributed to data collection, text arrangement and study design.

Ethical issues

The article does not contain any research with human participants performed by the authors. For this type of study, no formal consent was required. It is an anonymous one.

References

- Sagristà-Sauleda J, Mercé AS, Soler-Soler J. Diagnosis and management of pericardial effusion. *World J Cardiol* 2011; 3(5): 135-43. doi: 10.4330/wjc.v3.i5.135.
- Seferović PM, Ristić AD, Imazio M, Maksimović R, Simeunović D, Trincherio R, et al. Management strategies in pericardial emergencies. *Herz* 2006; 31(9): 891-900. doi: 10.1007/s00059-006-2937-0.
- LeWinter MM, Tischler MD. Pericardial diseases. In: Bonow RO, Mann DL, Zipes DP, Libby P, eds. *Braunwald's Heart Disease: A Textbook of Cardiovascular Medicine*. 9th ed. Philadelphia, PA: Saunders Elsevier; 2011.
- Beck CS. Two cardiac compression triads. *JAMA* 1935; 104(9): 714-6. doi: 10.1001/jama.1935.02760090018005.
- Tsang TS, Enriquez-Sarano M, Freeman WK, Barnes ME, Sinak LJ, Gersh BJ, et al. Consecutive 1127 therapeutic echocardiographically guided pericardiocenteses: clinical profile, practice patterns, and outcomes spanning 21 years. *Mayo Clin Proc* 2002; 77(5): 429-36. doi: 10.4065/77.5.429.
- Vaitkus PT, Herrmann HC, LeWinter MM. Treatment of malignant pericardial effusion. *JAMA* 1994; 272(1): 59-64. doi: 10.4065/77.5.429.
- Swanson N, Mirza I, Wijesinghe N, Devlin G. Primary percutaneous balloon pericardiectomy for malignant pericardial effusion. *Catheter Cardiovasc Interv* 2008; 71(4): 504-7. doi: 10.1002/ccd.21431.
- Mercé J, Sagristà-Sauleda J, Permanyer-Miralda G, Soler-Soler J. Should pericardial drainage be performed routinely in patients who have a large pericardial effusion without tamponade? *Am J Med* 1998; 105(2): 106-9. doi: 10.1016/s0002-9343(98)00192-2.
- Georghiou GP, Stamler A, Sharoni E, Fichman-Horn S, Berman M, Vidne BA, et al. Video-assisted thoracoscopic pericardial window for diagnosis and management of pericardial effusions. *Ann Thorac Surg* 2005; 80(2): 607-10. doi: 10.1016/j.athoracsur.2005.02.068.
- Fortuño Andrés JR, Alguersuari Cabisco A, Falcó Fages J, Castañer González E, Bermudez Bencerrey P. Radiological approach to cardiac tamponade. *Radiologia* 2010; 52(5): 414-24. doi: 10.1016/j.rx.2010.05.011. [In Spanish].
- Liberman M, Labos C, Sampalis JS, Sheiner NM, Mulder DS. Ten-year surgical experience with nontraumatic pericardial effusions: a comparison between the subxyphoid and transthoracic approaches to pericardial window. *Arch Surg* 2005; 140(2): 191-5. doi: 10.1001/archsurg.140.2.191.
- Eisenberg MJ, de Romeral LM, Heidenreich PA, Schiller NB, Evans GT Jr. The diagnosis of pericardial effusion and cardiac tamponade by 12-lead ECG. A technology assessment. *Chest* 1996; 110(2): 318-24. doi: 10.1378/chest.110.2.318.
- Karatay CM, Fruehan CT, Lighty GW Jr, Spear RM, Smulyan H. Acute pericardial distension in pigs: effect of fluid conductance on body surface electrocardiogram QRS size. *Cardiovasc Res* 1993; 27(6): 1033-8. doi: 10.1093/cvr/27.6.1033.
- Bruch C, Schmermund A, Dages N, Bartel T, Caspari G, Sack S, et al. Changes in QRS voltage in cardiac tamponade and pericardial effusion: reversibility after pericardiocentesis and after anti-inflammatory drug treatment. *J Am Coll Cardiol* 2001; 38(1): 219-26. doi: 10.1016/s0735-1097(01)01313-4.
- Gumrukcuoglu HA, Odabasi D, Akdag S, Ekim H. Management of cardiac tamponade: a comparative study between echo-guided pericardiocentesis and surgery—a report of 100 patients. *Cardiol Res Pract* 2011; 2011: 197838. doi: 10.4061/2011/197838.
- Barbetakis N, Asteriou C, Konstantinou D, Giannoglou D, Tsilikas C, Giannoglou G. Spontaneous chyloous cardiac tamponade: a case report. *J Cardiothorac Surg* 2010; 5: 11. doi: 10.1186/1749-8090-5-11.
- Maharaj SS, Chang SM. Cardiac tamponade as the initial presentation of systemic lupus erythematosus: a case report and review of the literature. *Pediatr Rheumatol Online J* 2015; 13: 9. doi: 10.1186/s12969-015-0005-0.
- Hellmann AR, Kostro J, Dziedzic R, Hellmann M, Dudziak M. Cardiac tamponade as the first manifestation of primary hypothyroidism. *Kardiologia Pol* 2015; 73(9): 786. doi: 10.5603/kp.2015.0168.
- Sinha A, Yeruva SL, Kumar R, Curry BH. Early cardiac tamponade in a patient with postsurgical hypothyroidism. *Case Rep Cardiol* 2015; 2015: 310350. doi: 10.1155/2015/310350.
- Goh AC, Lundstrom RJ. Spontaneous coronary artery dissection with cardiac tamponade. *Tex Heart Inst J* 2015; 42(5): 479-82. doi: 10.14503/THIJ-14-4260.
- Allen KB, Faber LP, Warren WH, Shaar CJ. Pericardial effusion: subxyphoid pericardiostomy versus percutaneous catheter drainage. *Ann Thorac Surg* 1999; 67(2): 437-40. doi: 10.1016/s0003-4975(98)01192-8.
- Gassman HS, Meadows R, Baker LA. Metastatic tumors of the heart. *Am J Med* 1955; 19(3): 357-65. doi: 10.1016/0002-9343(55)90124-8.
- Tsang TS, El-Najdawi EK, Seward JB, Hagler DJ, Freeman WK, O'Leary PW. Percutaneous echocardiographically guided pericardiocentesis in pediatric patients: evaluation of safety and efficacy. *J Am Soc Echocardiogr* 1998; 11(11): 1072-7. doi: 10.1016/s0894-7317(98)70159-2.
- Fitch MT, Nicks BA, Pariyadath M, McGinnis HD, Manthey DE. Videos in clinical medicine. Emergency pericardiocentesis. *N Engl J Med* 2012; 366(12): e17. doi: 10.1056/nejmvcm0907841.
- Maisch B, Seferović PM, Ristić AD, Erbel R, Rienmüller R, Adler Y, et al. Guidelines on the diagnosis and management

- of pericardial diseases executive summary; The Task force on the diagnosis and management of pericardial diseases of the European society of cardiology. *Eur Heart J* 2004; 25(7): 587-610. doi: 10.1016/j.ehj.2004.02.002.
26. Wong B, Murphy J, Chang CJ, Hassenein K, Dunn M. The risk of pericardiocentesis. *Am J Cardiol* 1979; 44(6): 1110-4.
 27. Ainsworth CD, Salehian O. Echo-guided pericardiocentesis: Let the bubbles show the way. *Circulation* 2011; 123(4): e210-1. doi: 10.1161/circulationaha.110.005512.
 28. Fejka M, Dixon SR, Safian RD, O'Neill WW, Grines CL, Finta B, et al. Diagnosis, management, and clinical outcome of cardiac tamponade complicating percutaneous coronary intervention. *Am J Cardiol* 2002; 90(11): 1183-6. doi: 10.1016/s0002-9149(02)02831-x.
 29. Kopecky SL, Callahan JA, Tajik AJ, Seward JB. Percutaneous pericardial catheter drainage: report of 42 consecutive cases. *Am J Cardiol* 1986; 58(7): 633-5. doi: 10.1016/0002-9149(86)90290-0.
 30. Celermajer DS, Boyer MJ, Bailey BP, Tattersall MH. Pericardiocentesis for symptomatic malignant pericardial effusion: a study of 36 patients. *Med J Aust* 1991; 154(1): 19-22.
 31. Tanaka Y, Tsuboi K, Yamamoto A, Tsuda S, Tsujii S, Yagi K, et al. Long-term survival of a breast cancer patient with carcinomatous pleuritis and carcinomatous cardiac tamponade successfully treated by multimodality therapy. *Gan To Kagaku Ryoho* 2015; 42(4): 489-92. [In Japanese].
 32. Lestuzzi C, Berretta M, Tomkowski W. 2015 update on the diagnosis and management of neoplastic pericardial disease. *Expert Rev Cardiovasc Ther* 2015; 13(4): 377-89. doi: 10.1586/14779072.2015.1025754.
 33. Sun T, Zhang Y, Shen Y, Hu K, Zuo M. A case of advanced lung cancer with malignant pericardial effusion treated by intrapericardial Cinobufacini injection instillation. *Biosci Trends* 2014; 8(4): 235-9. doi: 10.5582/bst.2014.01073.
 34. McDonald JM, Meyers BF, Guthrie TJ, Battafarano RJ, Cooper JD, Patterson GA. Comparison of open subxiphoid pericardial drainage with percutaneous catheter drainage for symptomatic pericardial effusion. *Ann Thorac Surg* 2003; 76(3): 811-5. doi: 10.1016/s0003-4975(03)00665-9.
 35. Buchanan CL, Sullivan VV, Lampman R, Kulkarni MG. Pericardiocentesis with extended catheter drainage: an effective therapy. *Ann Thorac Surg* 2003; 76(3): 817-20. doi: 10.1016/s0003-4975(03)00666-0
 36. Watarida S, Shiraishi S, Matsubayashi K, Imura M, Nishi T. Pericardial-peritoneal window for chronic exudative pericarditis using a subxiphoidal approach: report of three cases. *Surg Today* 2002; 32(5): 410-3. doi: 10.1007/s005950200064.
 37. Kurimoto Y, Hase M, Nara S, Yama N, Kawaharada N, Morishita K, et al. Blind subxiphoid pericardiectomy for cardiac tamponade because of acute hemopericardium. *J Trauma* 2006; 61(3): 582-5. doi: 10.1097/01.ta.0000236060.37952.ce
 38. Uramoto H, Hanagiri T. Video-assisted thoracoscopic pericardiectomy for malignant pericardial effusion. *Anticancer Res* 2010; 30(11): 4691-4.
 39. Muhammad MI. The pericardial window: is a video-assisted thoracoscopy approach better than a surgical approach? *Interact Cardiovasc Thorac Surg* 2011; 12(2): 174-8. doi: 10.1510/icvts.2010.243725.
 40. Georghiou GP, Porat E, Fuks A, Vidne BA, Saute M. Video-assisted pericardial fenestration for effusions after cardiac surgery. *Asian Cardiovasc Thorac Ann* 2009; 17(5): 480-2. doi: 10.1177/0218492309348505.
 41. Pérez-Etchepare E, Al Makki A, Varlet F, López M. Thoracoscopic treatment in pericardial tamponade. *Cir Pediatr* 2012; 25(3): 166-8.
 42. Agrawal V, Saxena A, Sethi A, Acharya H, Sharma D. Thoracoscopic pericardiectomy for management of purulent pneumococcal pericarditis in a child. *Asian J Endosc Surg* 2012; 5(3): 145-8. doi: 10.1111/j.1758-5910.2011.00129.x.
 43. Monaco F, Barone M, David A, Risitano DC, Lentini S. Cardiac tamponade: a modified video-assisted thoracoscopic approach. *Chir Ital* 2009; 61(3): 321-6. [In Italian].
 44. Olsen PS, Sørensen C, Andersen HO. Surgical treatment of large pericardial effusions. Etiology and long-term survival. *Eur J Cardiothorac Surg* 1991; 5(8): 430-2. doi: 10.1016/1010-7940(91)90189-q.
 45. Gregory JR, McMurtrey MJ, Mountain CF. A surgical approach to the treatment of pericardial effusion in cancer patients. *Am J Clin Oncol* 1985; 8(4): 319-23.
 46. Celik S, Celik M, Aydemir B, Tanrikulu H, Okay T, Tanrikulu N. Surgical properties and survival of a pericardial window via left minithoracotomy for benign and malignant pericardial tamponade in cancer patients. *World J Surg Oncol* 2012; 10: 123. doi: 10.1186/1477-7819-10-123.
 47. Kuvin JT, Harati NA, Pandian NG, Bojar RM, Khabbaz KR. Postoperative cardiac tamponade in the modern surgical era. *Ann Thorac Surg* 2002; 74(4): 1148-53. doi: 10.1016/s0003-4975(02)03837-7.
 48. Miller RH, Horneffer PJ, Gardner TJ, Rykiel MF, Pearson TA. The epidemiology of the postpericardiectomy syndrome: a common complication of cardiac surgery. *Am Heart J* 1988; 116(5 Pt 1): 1323-9. doi: 10.1016/0002-8703(88)90457-7.
 49. Nishimura RA, Fuster V, Burgert SL, Puga FJ. Clinical features and long-term natural history of the postpericardiectomy syndrome. *Int J Cardiol* 1983; 4(4): 443-50. doi: 10.1016/0167-5273(83)90194-8.