

Accepted Manuscript

The hippocampal longitudinal axis – relevance for underlying tau and TDP-43 pathology?

Albert Llado, Adrià Tort-Merino, Raquel Sanchez-Valle, Neus Falgas, Mircea Balasa, Bea Bosch, Magda Castellvi, Jaume Olives, Anna Antonell, Michael Hornberger



PII: S0197-4580(18)30203-3

DOI: [10.1016/j.neurobiolaging.2018.05.035](https://doi.org/10.1016/j.neurobiolaging.2018.05.035)

Reference: NBA 10271

To appear in: *Neurobiology of Aging*

Received Date: 29 March 2018

Revised Date: 24 May 2018

Accepted Date: 25 May 2018

Please cite this article as: Llado, A., Tort-Merino, A., Sanchez-Valle, R., Falgas, N., Balasa, M., Bosch, B., Castellvi, M., Olives, J., Antonell, A., Hornberger, M., The hippocampal longitudinal axis – relevance for underlying tau and TDP-43 pathology?, *Neurobiology of Aging* (2018), doi: 10.1016/j.neurobiolaging.2018.05.035.

This is a PDF file of an unedited manuscript that has been accepted for publication. As a service to our customers we are providing this early version of the manuscript. The manuscript will undergo copyediting, typesetting, and review of the resulting proof before it is published in its final form. Please note that during the production process errors may be discovered which could affect the content, and all legal disclaimers that apply to the journal pertain.

Title: The hippocampal longitudinal axis – relevance for underlying tau and TDP-43 pathology?

Albert Llado^{1*}, Adrià Tort-Merino¹, Raquel Sanchez-Valle¹, Neus Falgas¹, Mircea Balasa^{1,2},
Bea Bosch¹, Magda Castellvi¹, Jaume Olives¹, Anna Antonell¹, Michael Hornberger^{3,4}.

1. Alzheimer's Disease and Other Cognitive Disorders Unit, Neurology Service, Hospital Clínic, Institut d'Investigacions Biomèdiques August Pi i Sunyer (IDIBAPS), Barcelona, Spain.

2. Global Brain Health Institute Trinity College Dublin. Ireland.

3. Norwich Medical School, University of East Anglia, Norwich, UK

4. Norfolk and Suffolk NHS Foundation Trust, Norwich, UK

***Corresponding author:**

Dr Albert Llado, MD, PhD,

Alzheimer's disease and other cognitive disorders unit, Neurology Service, Hospital Clinic
Barcelona

C/Villarroel, 170, 08036 Barcelona, Catalonia, Spain.

Tel.: +34 932275785;

Fax: +34 932275783;

E-mail: allado@clinic.cat

Keywords: Alzheimer's disease, tau, TDP-43, MRI, semantic variant of progressive primary aphasia, frontotemporal dementia, memory, hippocampus

Abstract

Recent studies suggest that hippocampus has different cortical connectivity and functionality along its longitudinal axis. We sought to elucidate the possible different pattern of atrophy in longitudinal axis of hippocampus between Amyloid/Tau pathology and TDP-43-pathies.

Seventy-three presenile subjects were included: Amyloid/Tau group (33 Alzheimer's disease (AD) with confirmed CSF biomarkers), probable TDP-43 group (7 semantic variant progressive primary aphasia, 5 *GRN* and 2 *C9orf72* mutation carriers) and 26 healthy controls. We conducted a region-of-interest voxel-based morphometry analysis on the hippocampal longitudinal axis, by contrasting the groups, covarying with CSF biomarkers ($A\beta_{42}$, total tau, p-tau) and covarying with episodic memory scores. Amyloid/Tau pathology affected mainly posterior hippocampus while anterior left hippocampus was more atrophied in probable TDP-43pathies. We also observed a significant correlation of posterior hippocampal atrophy with AD CSF biomarkers and visual memory scores. Taken together, these data suggest that there is a potential differentiation along the hippocampal longitudinal axis based on the underlying pathology, which could be used as a potential biomarker to identify the underlying pathology in different neurodegenerative diseases.

1. Introduction

The hippocampus has long been regarded as a homogenous structure, critically involved in episodic memory and disproportionate atrophy on structural MRI in medial, basal and lateral temporal lobe has been included as a neuronal injury biomarker for the pathophysiological process of Alzheimer's disease (AD) in the diagnostic National Institute on Aging and Alzheimer's Association (NIA-AA) criteria (Albert *et al.*, 2011; McKhann *et al.*, 2011). This should be not surprising as the hippocampus is a medial temporal lobe structure critically involved in episodic memory and spatial navigation, which are some of the main symptoms in AD (Squire *et al.*, 2004; Serino *et al.*, 2014). Similarly, on a pathological level, amyloid and tau pathology converge in the medial temporal lobe in AD and have been strongly linked with the progression of the disease and clinical symptomology. It is therefore surprising to find that other proteinopathies (eg. frontotemporal dementia) have been shown to present at times with a similar degree of hippocampal atrophy than AD, despite different clinical presentations (Hornberger and Piguet, 2012; Irish *et al.*, 2014, Ramanan *et al.*, 2017). Indeed, behavioural variant frontotemporal dementia and semantic variant of primary progressive aphasia (svPPA) patients can show significant changes in the hippocampus (Hornberger *et al.*, 2012; Chapleau *et al.*, 2016). Importantly not all these dementias show significant episodic memory deficits, in particular svPPA patients present mainly deficits in semantic memory tasks while the other cognitive functions, such as non-verbal episodic memory and spatial navigation abilities are relatively more intact (Tan *et al.*, 2014). This discrepancy suggests that the hippocampus might be not as homogenous in its function and vulnerability to different proteinopathies as previously thought.

Recent data from healthy young humans, monkeys and rats suggest that there is a clear anatomical and functional differentiation of the hippocampus along its longitudinal axis (Poppenk and Moscovitch, 2011; Poppenk *et al.*, 2013; Strange *et al.*, 2014). The findings

suggest that the cortical connectivity of the anterior and posterior hippocampus might be different, suggesting that different cognitive specialisation might be harboured along the longitudinal axis of the hippocampus pending their cortical connectivity (Chase *et al.*, 2015; Moscovitch *et al.*, 2016). More specifically, Poppenk *et al.*, suggest that anterior and posterior hippocampus connectivity to cortical networks bias them towards pattern completion and separation, respectively. Such functionality would be reflected in coarse, global representations in anterior hippocampus and fine-grained, local representations in posterior hippocampus (Poppenk *et al.*, 2013). Such longitudinal differentiation of the hippocampus on an anatomical and functional level might have potentially significant implications for AD and related dementias. More specifically, for diagnostic purposes the hippocampus is seen more as a homogenous structure and hippocampal atrophy in putative AD is usually only established via visual inspection of more anterior hippocampus, with the posterior hippocampus rarely being considered (Scheltens *et al.*, 1992). Even more concerning is the fact that the hippocampal long-axis and connected regions might be differentially affected across dementias or proteinopathies (eg. tau, amyloid, TDP-43), which is currently not taken into account diagnostically or for treatment outcome measures.

The longitudinal axis differentiation in the hippocampus might explain the conundrum of why different dementias with hippocampal atrophy show varying degrees of episodic memory deficits. It would suggest that more posterior hippocampus is important for detailed episodic memory and spatial navigation and hence creating the symptomology in the patients. By contrast, more anterior hippocampal regions are less specific for episodic memory or indeed have a more global role in episodic or even semantic memory which does not cause clinically significant episodic memory problems (Zeidman and Maguire, 2016). A final important notion emerging from this is that therefore the longitudinal axis of the hippocampus might be more vulnerable to certain types of underlying protein pathology (eg.

amyloid, tau, TDP-43). Indeed, recent findings suggest that there is a distinct vulnerability of brain networks in Alzheimer's disease, due to the interaction of amyloid and tau (Chetelat 2013; Khan *et al.*, 2014). Similarly, brain network vulnerability related to medial temporal lobe changes have also been observed in svPPA, which is mainly associated to TDP-43 pathology (Snowden *et al.*, 2007; Bejanin *et al.*, 2017). However, few studies to date have specifically addressed whether the hippocampal long-axis might be differentially affected across such proteinopathies and how such a differentiation might relate to biomarkers and cognitive function (Barnes *et al.*, 2006; Lindberg *et al.*, 2017).

In this study we address this shortcoming directly by investigating atrophy pattern in the longitudinal axis of the hippocampus in biomarker confirmed Amyloid/Tau and probable TDP-43 groups. We hypothesised that the longitudinal hippocampal axis would be i) differentially affected by proteinopathy status (Amyloid/Tau *vs.* probable TDP-43) with Amyloid/Tau affecting more posterior hippocampus and TDP-43 affecting more anterior hippocampus; ii) CSF tau and amyloid biomarkers would correlate more with posterior hippocampus; and iii) neuropsychological episodic memory scores would correlate more with posterior hippocampus.

2. Material and methods

2.1 Participants

Seventy-three participants were retrospectively selected from the Early-onset Dementia Cohort and the Genetic counselling program for familial dementias (PICOGEN) both at the Alzheimer's Disease and Other Cognitive Disorders Unit from Hospital Clinic Barcelona (Spain) including early-onset mild cognitive impairment (MCI) due to Alzheimer's disease, early-onset AD (EOAD), svPPA, *GRN* and *C9orf72* mutation carriers and age-matched healthy controls. The study protocol includes clinical and complete neuropsychological

evaluations, structural MRI, genetic markers and a spinal tap to determine CSF biomarkers. Diagnoses were established by an interdisciplinary clinical committee formed by neurologists and neuropsychologists.

Global selection criteria were age at onset of symptoms <65 years and a score of 20 or above on the Mini Mental State Examination (MMSE). MCI patients showed impairment on one or more cognitive domains and had preserved activities of daily living, as measured by the Functional Activities Questionnaire (FAQ score <6; Pfeffer *et al.*, 1982). All of them fulfilled NIA-AA clinical diagnostic criteria for MCI due to AD (Albert *et al.*, 2011). AD patients fulfilled NIA-AA clinical diagnostic criteria for Dementia due to AD (McKhann *et al.*, 2011) and they were in the mild stage of the disease (Global Deterioration Scale of 4). All MCI and AD patients had a typical AD CSF biomarkers profile in agreement with the internal values of our laboratory (Antonell *et al.*, 2011). SvPPA patients met clinical diagnostic criteria for svPPA (Gorno-Tempini *et al.*, 2011) and six of them had a normal AD CSF profile (only 1 case had no information about amyloid status). Available symptomatic genetic frontotemporal lobar degeneration with predicted TDP-43 neuropathology were included: five *GRN* mutation carriers (three of them diagnosed as non-fluent variant of primary progressive aphasia (Gorno-Tempini *et al.*, 2011) and two as behavioural variant of frontotemporal dementia (Rascovsky *et al.*, 2011) and two *C9orf72* mutations carriers, both with diagnosis of behavioural variant of frontotemporal dementia (Rascovsky *et al.*, 2011). Three of genetic patients had normal AD CSF biomarkers profile (four cases had no information about amyloid status). Finally, healthy controls were recruited as research volunteers and defined as individuals with no cognitive complaints, no evidence of cognitive impairment in the neuropsychological tests and normal AD CSF biomarkers profile.

Global exclusion criteria included prior history of mental illness, significant head injury, cerebrovascular disease or alcohol and other drug abuse. Disease duration was estimated as

the number of years elapsed since the reported onset of symptoms until participants underwent MRI.

The participants were classified into three groups according to their predicted underlying neuropathology:

1. Amyloid/Tau Group (33 patients): this group included 18 early-onset MCI due to AD (14 single domain amnesic MCI and 4 multidomain amnesic MCI) and 15 EOAD. Because only the vast majority of the early-onset MCI who subsequently progressed to AD have a typical CSF biomarkers profile and EOAD patients are often misdiagnosed if the diagnosis is solely based on clinical data (Balasa *et al.*, 2011, 2014), we only selected cases who according to NIA-AA diagnostic criteria have at least one amyloid positive biomarker (decreased A β ₄₂ CSF levels) plus one neuronal injury positive biomarker (increased total tau and/or phosphorylated tau (p-tau) CSF levels). Thus, all our Amyloid/Tau Group patients met criteria to MCI due to AD with high likelihood or probable AD dementia with high evidence of the AD pathophysiological process (Albert *et al.*, 2011; McKhann *et al.*, 2011).

2. Probable TDP-43 group (14 patients): this group included patients with high probability of TDP-43 pathology, such as svPPA, and *GRN* or *C9orf72* mutation carriers which in clinical-pathological correlation studies were mainly associated with TDP-43 proteinopathy (Snowden *et al.*, 2007, 2015). In nine patients concomitant AD pathology was excluded by normal AD CSF biomarkers.

3. Control group (26 healthy controls): we selected only healthy controls with a normal AD CSF biomarkers profile to exclude preclinical AD patients and possible structural changes which could be seen in this phase of the disease.

A comprehensive neuropsychological battery was administered to all subjects by a trained neuropsychologist, including MMSE (Folstein *et al.*, 1975), as a measure of global cognition and assessments of memory, executive functions, language, gnosis and praxis. Cognitive cut-

off scores were defined taking into account the age and education of the patients, and were considered abnormal if they were more than 1.5 standard deviations below the mean. As we previously mentioned, the MMSE was used to select the patients. As our interest was to assess the correlation between hippocampal atrophy and different types of memory we selected the following tests for the correlational analysis: Free and Cued Selective Reminding Test (FCSRT) (Grober and Buschke, 1987) to assess episodic verbal memory and Landscape test (Valls-Pedret *et al.*, 2011) and CERAD Constructional Praxis Recall (Fillenbaum *et al.*, 2011) to assess visual memory.

2.2 APOE and biochemical CSF biomarkers

The APOE genotype was determined using PCR amplification and the HhaI restriction enzyme.

All the subjects underwent a spinal tap, during the morning. The samples were centrifuged and stored in polypropylene tubes at -80°C within 2 h. Levels of $\text{A}\beta_{42}$, total tau, and p-tau were measured by experienced laboratory personnel using commercial sandwich ELISA kits (Fujirebio Europe, Gent, Belgium)

2.3 Image acquisition and voxel-based morphometry (VBM) analysis

All participants were examined on a 3T MRI scanner (Magnetom Trio Tim, Siemens Medical Systems, Germany) with the same imaging protocol. A high-resolution 3D structural data set (T1-weighted, MP-RAGE, repetition time = 2300 ms, echo time = 2.98 ms, 240 slices, field-of-view = 256 mm, matrix size = 256x256, slice thickness = 1 mm) was acquired for all subjects.

3D T1-weighted sequences were analysed using FSL-VBM, a voxel-based morphometry analysis (Ashburner and Friston, 2000; Good *et al.*, 2001), which is part of the FSL software

package <http://www.fmrib.ox.ac.uk/fsl/fslvbm/index.html> (Smith *et al.*, 2004). Following brain extraction, tissue segmentation was carried out using FMRIB's Automatic Segmentation Tool (FAST) (Zhang *et al.*, 2001). The resulting grey matter partial volume maps were aligned to the MNI standard space (MNI52) using the nonlinear registration approach with FNIRT (Anderson *et al.*, 2007a, 2007b), which uses a b-spline representation of the registration warp field (Rueckert *et al.*, 1999). To correct for local expansion or contraction, the registered partial volume maps were modulated by dividing them by the Jacobian of the warp field. Importantly, the Jacobian modulation step did not include the affine part of the registration, which means that the data was normalized for head size as a scaling effect. The modulated images were then smoothed with an isotropic Gaussian kernel with a standard deviation of 3 mm (FWHM: 8mm).

First of all, a voxel-wise general linear model was applied to investigate differences in whole brain grey matter intensity between groups via permutation-based non-parametric testing (Nichols and Holmes, 2002) with 5000 permutations per contrast. Then, given our selected hypothesis we created regions of interest for the anterior and posterior hippocampus by including the first and last third of the hippocampus for the left and right hemispheres. The mask was created based on the Harvard-Oxford probabilistic atlas for the hippocampus. There are currently no clear guidelines as to what constitutes anterior and posterior hippocampus, so the mask was simply divided in thirds manually to define anterior and posterior; therefore our approach was to be quite conservative by only including the most anterior and posterior thirds of the HC. A voxel-wise general linear model was applied to investigate differences in grey matter intensity via permutation-based non-parametric testing (Nichols and Holmes, 2002) with 500 permutations per contrast. As a first step, differences in hippocampal grey matter intensity between groups (Amyloid/Tau group and probable TDP-43 group) and controls were assessed. Group comparisons between groups and controls were

tested for significance at $p < .01$, corrected for multiple comparisons via Family-wise Error (FWE) correction across space. A cluster extent threshold of 20 contiguous voxels was applied for group comparisons.

Next, correlations between different CSF biomarkers (t-tau, p-tau and $A\beta_{42}$) and performance on 3 memory tests (FCSRT, Landscape test and CERAD Constructional Praxis Recall) and regions of hippocampal grey matter atrophy were investigated in patients combined with controls. This procedure has previously been used in other studies (Irish *et al.*, 2014) to detect brain-behavioural relationships, and serves to achieve greater variance in difference scores, thereby increasing the statistical power. Here we apply this methodology to detect hippocampal-cognitive relationships. Furthermore, in the CSF correlation analyses as groups were constituted on the basis of positive (Amyloid/Tau group) versus negative (probable TDP-43 group and controls) biomarkers, we also analysed the correlations between different CSF biomarkers and regions of hippocampal grey matter atrophy in each group alone. For statistical power, a covariate only statistical model with a [1] t-contrast was used, providing an index of association between grey matter intensity and performance on cognitive test. All correlations between CSF biomarkers and cognitive test and hippocampal atrophy were tested for significance at $p < .01$ or $p < .05$, corrected for multiple comparisons via FWE correction across space. The same cluster extent threshold of 20 contiguous voxels was applied for these correlations.

Anatomical locations of significant results were overlaid on the MNI standard brain, with maximum coordinates provided in MNI stereotaxic space.

2.4 Statistical analysis

Demographic, cognitive, genetic and CSF biomarkers characteristics are reported as means and standard deviations or proportions when appropriate. Data were analysed using SPSS

22.0 (IBM, Chicago, Ill., USA). Kolmogorov-Smirnov tests were used to check for normality of distribution. Normally distributed scores were compared across groups using ANOVAs. Non-normally distributed scores were compared across groups using Kruskal-Wallis tests. When significant differences were detected a Mann-Whitney U test was used to compare specific groups. Chi-squared test was used to compare sex and APOE distribution across groups.

2.5 Ethics statement

All participants gave written informed consent. The study was approved by the Hospital Clinic Barcelona Ethics Committee and carried out in compliance with the ethical standards laid down in the 1964 Declaration of Helsinki and its later amendments.

3. Results

3.1 Demographics, cognition, *APOE* and CSF biomarkers

Demographics, neuropsychological data, *APOE* genotype and CSF biomarkers for the different groups are displayed in Table 1. There were no significant differences between groups in age and sex. Additionally, patient groups were as well matched for disease duration.

APOE 4 was more frequent in the Amyloid/Tau group compared to the probable TDP-43 group and controls ($p < 0.05$), but no differences were found between the probable TDP-43 group and controls.

Neuropsychological testing revealed cognitive differences between groups (Table 1). Briefly, both patient groups were impaired compared to controls on MMSE ($p < 0.05$), but did not differ significantly from each other. In both patient groups, impairments were also observed on FCSRT, Landscape test and CERAD Constructional Praxis Recall (all p values < 0.05)

compared to controls. Direct comparison between the two patient groups displayed more impairment on Landscape test and CERAD Constructional Praxis Recall (p values < 0.05) in the Amyloid/Tau group, but there was no difference in FCSRT.

As expected from the selection criteria all AD CSF biomarkers were significantly altered in Amyloid/Tau group compared with probable TDP-43 group and controls ($p < 0.001$).

3.2 Voxel-based morphometry results

3.2.1 Group comparisons

Compared to controls, Amyloid/Tau group and probable TDP-43 group showed extensive atrophy including frontal, temporal, parietal and occipital regions (Supplementary Figure 1A and 1B). Direct comparison of the Amyloid/Tau and probable TDP-43 groups revealed greater atrophy in the precuneus in Amyloid/Tau group (Supplementary Figure 1C). The reverse contrast revealed greater atrophy in the left anterior temporal lobe, extending into inferior frontal and ventromedial prefrontal cortices in the probable TDP-43 group (Supplementary Figure 1D).

Compared to controls, Amyloid/Tau group showed atrophy in anterior and posterior hippocampus bilaterally, although this atrophy was more extended in the posterior regions (Figure 1A and Table 2).

Compared to controls, the probable TDP-43 group showed atrophy in the anterior and posterior left hippocampus but only in the anterior region of the right hippocampus (Figure 1B, Table 2). Finally, direct comparison of the Amyloid/Tau and probable TDP-43 groups revealed greater atrophy in the right posterior hippocampus in Amyloid/Tau group (Figure 1C: Table 2 and 3). The reverse contrast revealed greater atrophy in the left anterior hippocampus in the probable TDP-43 group (Figure 1C: Table 2 and 3).

3.2.2 CSF biomarker correlations

In whole sample AD CSF biomarkers were correlated with the atrophy of posterior regions of the hippocampus. More specifically, total tau was correlated with the posterior left side (Figure 2A, table 4) and p-tau and A β_{42} with the posterior hippocampus bilaterally (Figure 2B and 2C, table 4). However, when we analysed the correlations between different CSF biomarkers and regions of hippocampal grey matter atrophy in each group to separate we found no correlations.

3.2.3 Cognitive correlations

Immediate free recall and delayed free recall of FCSRT were correlated with atrophy involving all analysed regions of the hippocampus (i.e., anterior and posterior), although the atrophy was more extensive in the posterior regions (Figure 3A and 3B, Table 5). Immediate total recall and delayed total recall scores of FCSRT were correlated with atrophy involving bilateral posterior hippocampus and anterior left hippocampus (Table 5). The Landscape test was associated with bilateral posterior hippocampus (Figure 3C, Table 5), whereas we only detected atrophy in left posterior hippocampus associated with CERAD Constructional Praxis Recall (Figure 3D, Table 5).

In a post-hoc analysis, we explored whether any cognitive measure would be more related to the anterior hippocampal atrophy. The rationale for this analysis was to explore if we can also observe a cognitive differentiation across the longitudinal axis. To this purpose we correlated the total score of the Boston Naming Test (BNT), a semantic language test, with hippocampal atrophy. The results showed that a low score in BNT was clearly associated with greater anterior left hippocampal atrophy (Supplementary Figure 2, Supplementary Table 1).

4. Discussion

The aim of the current study was to assess hippocampal atrophy along its longitudinal axis as a function of different underlying pathologies. Our results clearly show that AD (Amyloid/Tau group) affects anterior and posterior hippocampus with a clear emphasis on the posterior hippocampus. By contrast, probable TDP-43 pathies mainly showed anterior HC changes. In addition, atrophy correlations with cognitive tests showed that visual memory (Landscape test and CERAD Constructional Praxis Recall) correlated with posterior hippocampus, whereas verbal memory (FCSRT) correlated with both anterior and posterior hippocampal atrophy. More importantly, we also observed a correlation between posterior hippocampal atrophy and CSF AD biomarker levels. Taken together, these data suggest that there is a potential differentiation along the hippocampal longitudinal axis based on the underlying pathology.

To our knowledge, there are few studies to explore exclusively the pattern of hippocampal atrophy along its longitudinal axis in biomarker confirmed AD, probable TDP-43 pathies and controls using VBM analysis. In a previous study by volumetric magnetic resonance imaging, Chan *et al.*, (Chan et al., 2001a) described a marked difference in the distribution of temporal lobe atrophy between svPPA and AD. Similar to our data they found an anteroposterior gradient in the distribution of temporal lobe atrophy, with more marked atrophy anteriorly, in svPPA. However, in AD there was symmetrical atrophy of the entorhinal cortex, hippocampus, and amygdala, with no evidence of an anteroposterior gradient in the distribution of temporal lobe or hippocampal atrophy. These differences with our results could be explained by a different used methodology and a lower number of AD patients evaluated without biological AD confirmation. In another different approach Lindberg et al., have conducted shape analysis of hippocampus on clinically diagnosed dementia patients and controls. They found more atrophy in left hippocampal body with relative sparing of the hippocampal head in AD. On the other hand, in the same study, compared to controls, svPPA

displayed severe atrophy of the whole left hippocampus, although in concordance to our data, they found, more limited posterior pathology in milder cases (Lindberg *et al.*, 2012). Our findings also are in concordance to data from a study based on pathologically confirmed cases, which Barnes *et al.* show more pronounced atrophy of the anterior than posterior part of hippocampus in svPPA compared to controls in a volumetric magnetic resonance imaging (Barnes *et al.*, 2006).

Our findings fit well with the framework proposed by Ranganath and Ritchey (Ranganath and Ritchey, 2012), based on anatomic and functional data from humans, monkeys and rats, which hypothesises that the hippocampus is involved in two cortical systems that harbor different cognitive/memory functions. On the one hand, the posterior medial system which includes regions more implicated in AD such the parahippocampal cortex, retrosplenial cortex, anterior thalamic nuclei, mammillary bodies, pre- and parasubiculum and components of the default mode network (including the posterior cingulate, precuneus, angular gyrus and ventromedial prefrontal cortex) is clearly linked to the posterior hippocampus. On the other hand, the anterior-temporal system, including the perirhinal cortex, temporopolar cortex, lateral orbitofrontal cortex and amygdala, would be particularly connected to the anterior hippocampus (Ranganath and Ritchey, 2012; Aggleton, 2012; Poppenk *et al.*, 2013). In concordance with our data these two cortical systems would mainly be differently affected by different disease/proteinopathies. More specifically and also in concordance to our findings in whole brain patterns of atrophy between groups the posterior medial system should be more vulnerable to Alzheimer's disease pathophysiology whereas the anterior temporal system would be more vulnerable to TDP-43 pathologies such as svPPA, behavioural variant of frontotemporal dementia and Amyotrophic lateral sclerosis-Frontotemporal dementia. This hypothesis is also in concordance with the disproportionate atrophy of the anterior hippocampus in svPPA (Chan *et al.*, 2001b; Chapleau *et al.*, 2016) and the fact that AD and

svPPA differentially affect brain metabolism (La Joie *et al.*, 2014). Interestingly, there is a strong similarity between brain regions specifically affected in AD and svPPA and brain regions that are specifically connected with the posterior versus anterior hippocampus respectively (La Joie *et al.*, 2014). The clear correlation between all AD CSF biomarkers with atrophy of posterior regions of hippocampus also suggests that these regions would be more vulnerable to Amyloid/Tau pathology. Similar to our data, Lindberg *et al.* found elevated p-tau and low A β_{42} levels in CSF are mostly associated with the volume changes of the posterior subiculum, a subfield of the hippocampus, in 302 cognitively normal elderly participants, 183 patients with subjective cognitive decline and 171 patients with amnesic MCI (Lindberg *et al.*, 2017).

Our data also nicely dovetails with the different patterns of cognitive deficits reported in AD and svPPA. More specifically, the hallmark symptoms of episodic memory and spatial navigation are more clearly related to posterior hippocampal regions. This is particularly true for visual memory tests such as the Landscape tests and CERAD Constructional Praxis Recall, which require a high degree of detail to correctly recall. Interestingly, the verbal recall test (FCSRT) correlated with both anterior and posterior hippocampus, suggesting that the verbal nature and more reliance on semantics relies also on anterior hippocampal regions. This fits nicely with current models of episodic memory and also links with theoretical models suggesting that the anterior hippocampus is more related to broader or generic information retrieval than posterior regions which allow a higher degree of details (Maguire and Mullally, 2013; Zeidman and Maguire, 2016; Moscovitch *et al.*, 2016). In concordance to our data, Lindberg *et al.* also described mild memory dysfunction was mostly associated with the volume changes of the posterior subiculum (Lindberg *et al.*, 2017). We further explored this notion in a post-hoc analysis showing that a semantic test (BNT) correlated exclusively with anterior left hippocampal atrophy. The post-hoc findings also relate to the clinical symptomatology of many TDP-43opathies, which show varying degrees of semantic

impairment and concomitant anterior hippocampus changes (Hornberger *et al.*, 2012; Yew *et al.*, 2013). Clinically, these findings suggest that the reliance of verbal episodic memory tests might not be advisable as they are not specific underlying pathology, in contrast to more visual episodic memory tests.

In terms of the pathology, it is interesting that these different anterior and posterior hippocampal networks should be differentially susceptible to the underlying pathology. Our findings could seem contradictories to neuropathological studies that have shown that the earliest site of cortical tau-pathology is in the transentorhinal and then entorhinal cortex, which is adjacent to the anterior part of the hippocampus (Braak and Braak, 1991) and studies in preclinical patients that have also shown that the lateral entorhinal cortex and the anterior hippocampal system is earliest affected by AD-pathology (Khan *et al.*, 2014). Indeed, the entorhinal cortex is located closer to anterior hippocampus and it is therefore not clear why posterior hippocampus would be more affected in AD. One speculation is that the anatomical connectivity of the entorhinal cortex is actually very strong with the retrosplenial cortex and posterior hippocampus (Vann *et al.*, 2009). Therefore posterior regions might be more vulnerable than anterior hippocampus. Still, this remains clearly speculation for now, however a very recent study indicates indeed such a pattern (Jacobs *et al.*, 2018). Nevertheless, this clearly needs to be further investigated in the future. Indeed such pathological vulnerability for different hippocampal regions could have significant implications for dementia diagnosis and its specific therapeutic approaches. Specifically, which hippocampal regions should be employed for best diagnostic and treatment outcome measures? Based on our results, we suggest that the hippocampal long-axis affection could be used as a potential biomarker to identify the underlying pathology (tau, TDP-43) which to date is still highly controversial. Indeed, in particular for behavioural variant of frontotemporal dementia patients who usually have a 50:50 distribution of underlying tau and

TDP-43 pathology (Mackenzie *et al.*, 2010) this would be highly informative, as current intervention trials cannot determine the underlying pathology in those cases. Still, it would be somewhat ironic if the longitudinal axis of the hippocampus would emerge as potential imaging biomarker for behavioural variant of frontotemporal dementia, as hippocampal atrophy and associated episodic memory are still seen as quite controversial and might even preclude a diagnosis of behavioural variant of frontotemporal dementia (Rascovsky *et al.*, 2011). The current findings might overcome this problem by showing that behavioural variant of frontotemporal dementia patients can have hippocampal atrophy in particular anteriorly due to TDP-43 pathology and virtually no visual episodic memory problems, whereas those with tau pathology will have more posterior hippocampal atrophy and episodic memory problems. Indeed, recent controversial findings showing that a subgroup of behavioural variant of frontotemporal dementia patients might have episodic memory problems (Hornberger *et al.* 2010; Bertoux *et al.* 2014) would be indicative of underlying tau pathology, although this clearly needs to be investigated further in the future.

Despite these promising findings, a number of methodological issues in our study warrant consideration. Firstly, given that our patients had not yet pathological confirmation, we cannot definitively confirm the underlying disease pathology in each group, although it is unlikely due to the availability and confirmation via biomarkers. A second limitation of this study concerns the age of the patients. All of them have early-onset dementia and we cannot ensure that the pathophysiological process in these cases is the same as in late-onset dementia. However, we selected this sample to avoid the overlap of different pathologies present in many late-onset cases. Finally, this was a retrospective study, and therefore some of the cognitive and biomarker data were not available for some participants.

5. Conclusion

Our results show that Amyloid/Tau pathologies affected mainly posterior hippocampus while that anterior hippocampus is more atrophied in TDP-43 pathies. These specific hippocampal long-axis affectations have also specific cognitive and biomarker correlations. We also suggest that this differentially hippocampal impact could be used as a potential biomarker to identify the underlying pathology in different neurodegenerative diseases. For the future, it would be important to corroborate our findings and also investigate whether such longitudinal specific changes might improve disease detection at a presymptomatic stage of the investigated pathologies.

Acknowledgements:

The authors thank patients, their relatives and healthy controls for their participation in the research.

Author Disclosures:

Authors state that there are no conflicts of interest to disclose.

Funding:

This work was supported by Spanish Ministry of Economy and Compititiveness-Instituto de Salud Carlos III and Fondo Europeo de Desarrollo Regional (FEDER), Unión Europea, “Una manera de hacer Europa” (PI14/00282 to Dr. A. Lladó), Hospital Clinic Barcelona (“sabbatical leave” to Dr. A. Lladó), PERIS 2016-2020 Departament de Salut de la Generalitat de Catalunya (SLT002/16/00408 to Dr Sanchez-Valle) and Fundació Marató de TV3, Barcelona, Spain (Grant 20143810 to Dr Sanchez-Valle) and CERCA Programme/Generalitat de Catalunya. Dr Anna Antonell received funding from Departament de Salut de la Generalitat de Catalunya (PERIS 2016-2020 SLT002/16/00329). Dr. Neus Falgàs received

funding from Hospital Clinic Barcelona (Ajut Josep Font). MH is funded by the Alzheimer's Research UK, Wellcome Trust, Medical Research Council and BBSRC.

ACCEPTED MANUSCRIPT

References:

Aggleton JP. Multiple anatomical systems embedded within the primate medial temporal lobe: implications for hippocampal function. *Neurosci Biobehav Rev.* 2012;36(7):1579-96. doi: 10.1016/j.neubiorev.2011.09.005.

Albert MS, DeKosky ST, Dickson D, Dubois B, Feldman HH, Fox NC, Gamst A, Holtzman DM, Jagust WJ, Petersen RC, Snyder PJ, Carrillo MC, Thies B, Phelps CH. The diagnosis of mild cognitive impairment due to Alzheimer's disease: Recommendations from the National Institute on Aging-Alzheimer's Association workgroups on diagnostic guidelines for Alzheimer's disease. *Alzheimers Dement;* 2011;7:270-279. doi: 10.1016/j.jalz.2011.03.008.

Anderson, JLR, Jenkinson M, Smith S. Non-linear optimisation: FMRIB technical report TR07JA1. 2007a

Anderson, JLR, Jenkinson M, Smith S. Non-linear registration, aka spatial normalisation: FMRIB technical report TR07JA2. 2007b

Antonell A, Fortea J, Rami L, Bosch B, Balasa M, Sanchez-Valle R, Iranzo A, Molinuevo JL, Lladó A. Different profiles of Alzheimer's disease cerebrospinal fluid biomarkers in controls and subjects with subjective memory complaints. *J Neural Transm* 2011;118: 259-262. doi: 10.1007/s00702-010-0534-0

Ashburner J, Friston KJ. Voxel-Based Morphometry—The Methods. *NeuroImage* 2000;11:805-21

Balasa M, Gelpi E, Antonell A, Rey MJ, Sanchez-Valle R, Molinuevo JL, Lladó A. Clinical features and APOE genotype of pathologically proven early-onset Alzheimer disease. *Neurology* 2011; 76: 1720-5. doi: 10.1212/WNL.0b013e31821a44dd.

Balasa M, Sanchez-Valle R, Antonell A, Bosch B, Olives J, Rami L, Castellví M, Molinuevo JL, Lladó A. Usefulness of Biomarkers in the Diagnosis and Prognosis of Early-Onset Cognitive Impairment. *J Alzheimers Dis* 2014;40:919-27. doi: 10.3233/JAD-132195.

Barnes J, Whitwell JL, Frost C, Josephs KA, Rossor M, Fox NC. Measurements of the amygdala and hippocampus in pathologically confirmed Alzheimer disease and frontotemporal lobar degeneration. *Arch Neurol* 2006;63:1434-1439.

Bejanin A, Desgranges B, La Joie R, Landeau B, Perrotin A, Mézenge F, Belliard S, de La Sayette V, Eustache F, Chételat G. Distinct white matter injury associated with medial temporal lobe atrophy in Alzheimer's versus semantic dementia. *Hum Brain Mapp* 2017;38:1791-1800. doi: 10.1002/hbm.23482

Bertoux M, de Souza LC, Corlier F, Lamari F, Bottlaender M, Dubois B, Sarazin M. Two distinct amnesic profiles in behavioral variant frontotemporal dementia. *Biol Psychiatry* 2014;75(7):582-8. doi: 10.1016/j.biopsych.2013.08.017

Braak H, Braak E. Neuropathological staging of Alzheimer-related changes. *Acta Neuropathol* 1991;82:239-259

Chan D, Fox NC, Scahill RI, Crum WR, Whitwell JL, Leschziner G, Rossor AM, Stevens JM, Cipolotti L, Rossor MN. Patterns of temporal lobe atrophy in semantic dementia and Alzheimer's disease. *Ann Neurol* 2001a;49(4):433-42.

Chan D, Fox NC, Jenkins R, Scahill RI, Crum WR, Rossor MN. Rates of global and regional cerebral atrophy in AD and frontotemporal dementia. *Neurology* 2001b;57:1756-63.

Chapleau M, Aldebert J, Montembeault M, Brambati SM. Atrophy in Alzheimer's

Disease and Semantic Dementia: An ALE Meta-Analysis of Voxel-Based Morphometry Studies. *J Alzheimers Dis* 2016;54(3):941-955. DOI:10.3233/JAD-160382

Chase HW, Clos M, Dibble S, Fox P, Grace AA, Phillips ML, Eickhoff SB. Evidence for an anterior-posterior differentiation in the human hippocampal formation revealed by meta-analytic parcellation of fMRI coordinate maps: focus on the subiculum. *Neuroimage* 2015;113:44-60. doi: 10.1016/j.neuroimage.2015.02.069.

Chetelat G. Alzheimer disease: Abeta-independent processes-rethinking preclinical AD. *Nat Rev Neurol* 2013;9:123-4. doi: 10.1038/nrneurol.2013.21.

Fillenbaum GG, Burchett BM, Unverzagt FW, Rexroth DF, Welsh-Bohmer B. Norms for CERAD constructional praxis recall. *Clin Neuropsychol* 2011;25:1345-58. doi: 10.1080/13854046.2011.614962.

Folstein MF, Folstein SE, McHugh PR. "Mini-mental state". A practical method for grading the cognitive state of patients for the clinician. *J Psychiatr Res* 1975;12:189-198.

Good CD, Johnsrude I, Ashburner J, Henson RNA, Friston KJ, Frackowiak RSJ. Cerebral Asymmetry and the Effects of Sex and Handedness on Brain Structure: A Voxel-Based Morphometric Analysis of 465 Normal Adult Human Brains. *NeuroImage* 2001;14:685-700.

Gorno-Tempini ML, Hillis AE, Weintraub S, Kertesz A, Mendez M, Cappa SF, Ogar JM, Rohrer JD, Black S, Boeve BF, Manes F, Dronkers NF, Vandenberghe R, Rascovsky K, Patterson K, Miller BL, Knopman DS, Hodges JR, Mesulam MM, Grossman M. Classification of primary progressive aphasia and its variants. *Neurology* 2011;76:1006-1014. doi: 10.1212/WNL.0b013e31821103e6.

Grober E, Buschke H. Genuine memory deficits in dementia. *Dev Neuropsychol*. 1987;3,

13-36.

Hornberger M, Piguet O, Graham AJ, Nestor PJ, Hodges JR. How preserved is episodic memory in behavioral variant frontotemporal dementia? *Neurology* 2010;74: 472–479. doi: 10.1212/WNL.0b013e3181cef85d.

Hornberger M, Piguet O. Episodic memory in frontotemporal dementia: a critical review. *Brain* 2012;135:678-92. doi: 10.1093/brain/aws011.

Hornberger M, Wong S, Tan R, Irish M, Piguet O, Kril J, Hodges JR, Halliday G. In vivo and post-mortem memory circuit integrity in frontotemporal dementia and Alzheimer's disease. *Brain* 2012;135:3015-25. doi: 10.1093/brain/aws239.

Irish M, Piguet O, Hodge JR, Hornberger M. Common and unique gray matter correlates of episodic memory dysfunction in frontotemporal dementia and Alzheimer's disease. *Human Brain Mapping* 2014;35:1422–1435. doi: 10.1002/hbm.22263.

Jacobs HIL, Hedden T, Schultz AP, Sepulcre J, Perea RD, Amariglio RE, Papp KV, Rentz DM, Sperling RA, Johnson KA. Structural tract alterations predict downstream tau accumulation in amyloid-positive older individuals. *Nat Neurosci* 2018;21(3):424-431. doi: 10.1038/s41593-018-0070-z

Khan UA, Liu L, Provenzano FA, Berman DE, Profaci CP, Sloan R, Mayeux R, Duff KE, Small SA. Molecular drivers and cortical spread of lateral entorhinal cortex dysfunction in preclinical Alzheimer's disease. *Nat Neurosci* 2014;17:304-11. doi: 10.1038/nn.3606.

La Joie R, Landeau B, Perrotin A, Bejanin A, Egret S, Pelerin A, Mézenge F, Belliard S, de La Sayette V, Eustache F, Desgranges B, Chételat G. Intrinsic connectivity identifies the hippocampus as a main crossroad between Alzheimer's and semantic

dementia-targeted networks. *Neuron* 2014;81:1417-28. doi: 10.1016/j.neuron.2014.01.026

Lindberg O, Walterfang M, Looi JC, Malykhin N, Ostberg P, Zandbelt B, Styner M, Paniagua B, Velakoulis D, Orndahl E, Wahlund LO. Hippocampal shape analysis in Alzheimer's disease and frontotemporal lobar degeneration subtypes. *J Alzheimers Dis*. 2012;30(2):355-65. doi: 10.3233/JAD-2012-112210.

Lindberg O, Martensson G, Stomrud E, Palmqvist S, Wahlund LO, Westman E, Hansson O. Atrophy of the Posterior Subiculum Is Associated with Memory Impairment, Tau- and Abeta Pathology in Non-demented Individuals. *Front Aging Neurosci* 2017;9:306. 2017;9:306. doi: 10.3389/fnagi.2017.00306.

Mackenzie IR, Neumann M, Bigio EH, Cairns NJ, Alafuzoff I, Kril J, Kovacs GG, Ghetti B, Halliday G, Holm IE, Ince PG, Kamphorst W, Revesz T, Rozemuller AJ, Kumar-Singh S, Akiyama H, Baborie A, Spina S, Dickson DW, Trojanowski JQ, Mann DM. Nomenclature and nosology for neuropathologic subtypes of frontotemporal lobar degeneration: an update. *Acta neuropathologica* 2010;119: 1-4. doi: 10.1007/s00401-009-0612-2.

Maguire EA, Mullally SL. The hippocampus: a manifesto for change. *J Exp Psychol Gen* 2013;142:1180-9. doi: 10.1037/a0033650.

McKhann GM, Knopman DS, Chertkow H, Hyman BT, Jack CR, Jr., Kawas CH, Klunk WE, Koroshetz WJ, Manly JJ, Mayeux R, Mohs RC, Morris JC, Rossor MN, Scheltens P, Carrillo MC, Thies B, Weintraub S, Phelps CH. The diagnosis of dementia due to Alzheimer's disease: Recommendations from the National Institute on Aging-Alzheimer's Association workgroups on diagnostic guidelines for Alzheimer's disease. *Alzheimers Dement* 2011;7:263-269. doi: 10.1016/j.jalz.2011.03.005.

Moscovitch M, Cabeza R, Winocur G, Nadel L. Episodic Memory and Beyond: The Hippocampus and Neocortex in Transformation. *Annu Rev Psychol* 2016;67:105-34. doi: 10.1146/annurev-psych-113011-143733.

Nichols TE, Holmes AP. Nonparametric permutation tests for functional neuroimaging: a primer with examples. *Human Brain Mapping* 2002;15:1-25.

Pfeffer RI, Kurosaki TT, Harrah CH, Chance JM, Filos S. Measurement of functional activities in older adults in the community. *J Gerontol* 1982;37:323–329.

Poppenk J, Moscovitch M. A hippocampal marker of recollection memory ability among healthy young adults: contributions of posterior and anterior segments. *Neuron* 2011;72:931-7. doi: 10.1016/j.neuron.2011.10.014.

Poppenk J, Evensmoen HR, Moscovitch M, Nadel L. Long-axis specialization of the human hippocampus. *Trends Cogn Sci* 2013;17:230-40. doi: 10.1016/j.tics.2013.03.005.

Ramanan S, Bertoux M, Flanagan E, Irish M, Piguet O, Hodges JR, Hornberger M. Longitudinal Executive Function and Episodic Memory Profiles in Behavioral-Variant Frontotemporal Dementia and Alzheimer's Disease. *J Int Neuropsychol Soc* 2017;23(1):34-43. doi: 10.1017/S1355617716000837.

Ranganath C, Ritchey M. Two cortical systems for memory-guided behaviour. *Nat Rev Neurosci*. 2012;13:713-26. doi: 10.1038/nrn3338.

Rascovsky K, Hodges JR, Knopman D, Mendez MF, Kramer JH, Neuhaus J, van Swieten JC, Seelaar H, Dopper EG, Onyike CU, Hillis AE, Josephs KA, Boeve BF, Kertesz A, Seeley WW, Rankin KP, Johnson JK, Gorno-Tempini ML, Rosen H, Prioleau-Latham CE, Lee A, Kipps CM, Lillo P, Piguet O, Rohrer JD, Rossor MN, Warren JD, Fox NC, Galasko D, Salmon DP, Black SE, Mesulam M, Weintraub S, Dickerson BC,

Diehl-Schmid J, Pasquier F, Deramecourt V, Lebert F, Pijnenburg Y, Chow TW, Manes F, Grafman J, Cappa SF, Freedman M, Grossman M, Miller BL. Sensitivity of revised diagnostic criteria for the behavioural variant of frontotemporal dementia. *Brain* 2011;134: 2456–2477. doi: 10.1093/brain/awr179.

Rueckert D, Sonoda LI, Hayes C, Hill DLG, Leach MO, Hawkes DJ. Nonrigid registration using free-form deformations: application to breast MR images. *Medical Imaging, IEEE Transactions* 1999;18:712–721.

Scheltens P, Leys D, Barkhof F, Huglo D, Weinstein HC, Vermersch P, Kuiper M, Steinling M, Wolters EC, Valk J. Atrophy of the medial temporal lobes on MRI in "probable" Alzheimer's disease and normal ageing: diagnostic value and neuropsychological correlates. *J Neurol Neurosurg Psychiatry* 1992;55:967-972.

Serino S, Cipresso P, Morganti F, Riva G. The role of egocentric and allocentric abilities in Alzheimer's disease: a systematic review. *Ageing Res Rev* 2014;16:32-44. doi: 10.1016/j.arr.2014.04.004.

Smith SM, Jenkinson M, Woolrich MW, Beckmann CF, Behrens TEJ, Johansen-Berg H, Bannister PR, De Luca M, Drobnjak I, Flitney DE, Niazy RK, Saunders J, Vickers J, Zhang Y, De Stefano N, Brady JM, Matthews PM. Advances in functional and structural MR image analysis and implementation as FSL. *NeuroImage* 2004;23:S208–S219.

Snowden J, Neary D, Mann D. Frontotemporal lobar degeneration: clinical and pathological relationships. *Acta Neuropathol* 2007;114: 31–38.

Snowden JS, Adams J, Harris J, Thompson JC, Rollinson S, Richardson A, Jones M, Neary D, Mann DM, Pickering-Brown S. Distinct clinical and pathological phenotypes in frontotemporal dementia associated with MAPT, PGRN and C9orf72 mutations.

Amyotroph Lateral Scler Frontotemporal Degener 2015;16:497-505. doi: 10.3109/21678421.2015.1074700.

Squire LR, Stark CE, Clark RE. The medial temporal lobe. *Annu. Rev. Neurosci* 2004;27, 279–306.

Strange BA, Witter MP, Lein ES, Moser EI. Functional organization of the hippocampal longitudinal axis. *Nat Rev Neurosci*. 2014;15:655-69. DOI:10.1038/nrn3785

Tan RH, Wong S, Kril JJ, Piguet O, Hornberger M, Hodges JR, Halliday GM. Beyond the temporal pole: limbic memory circuit in the semantic variant of primary progressive aphasia. *Brain* 2014;137:2065-76. doi: 10.1093/brain/awu118.

Valls-Pedret C , Olives J, Bosch B, Caprile C, Castellví M, Molinuevo JL, Rami L. [Landscape test for assessing visual memory in Alzheimer's disease]. *Rev Neurol* 2011;53(1):1-7.

Vann SD, Aggleton JP, Maguire EA. What does the retrosplenial cortex do? *Nat Rev Neurosci*. 2009;10(11):792-802. doi: 10.1038/nrn2733.

Yew B, Alladi S, Shailaja M, Hodges JR, Hornberger M. Lost and forgotten? Orientation versus memory in Alzheimer's disease and frontotemporal dementia. *J Alzheimers Dis* 2013;33(2):473-81. doi: 10.3233/JAD-2012-120769.

Zeidman P, Maguire EA. Anterior hippocampus: the anatomy of perception, imagination and episodic memory. *Nat Rev Neurosci* 2016;17(3):173-82. doi: 10.1038/nrn.2015.24.

Zhang Y, Brady M, Smith S. Segmentation of brain MR images through a hidden Markov random field model and the expectation-maximization algorithm. *Medical Imaging, IEEE Transactions* 2001;20: 45–57.

Figure legends

Figure 1: VBM analysis showing hippocampal regions of significant grey matter intensity decrease between (A) Amyloid/Tau group vs healthy controls, (B) probable TDP-43 group vs healthy controls (C) Amyloid/Tau group and probable TDP-43 group. In (C) red voxels show regions that were greater atrophied in Amyloid/Tau group and Blue voxels regions that were greater atrophied in probable TDP-43 group. The voxels of hippocampal mask without significant differences between groups were shown in white. All results were significant in the analysis with $p < 0.01$ corrected with a cluster threshold of 20 contiguous voxels. Clusters are overlaid on the MNI standard brain.

Figure 2: VBM results showing hippocampal regions of significant grey matter intensity decrease which correlate with total tau (negative correlation) (A), p-tau (negative correlation) (B) and $A\beta_{42}$ (positive correlation) (C) in the CSF analysis. As described in methods, correlations between different CSF biomarkers and regions of hippocampal grey matter atrophy were investigated in patients combined with controls ($n=68$). The voxels of hippocampal mask without significant differences between groups were shown in white. All results were significant in the analysis with $p < 0.05$ corrected with a cluster threshold of 20 contiguous voxels. Clusters are overlaid on the MNI standard brain.

Figure 3: VBM results showing hippocampal regions of significant grey matter intensity decrease which correlate with different memory test: FCSRT-IFR: FCSRT-Immediate Free Recall (A), FCSRT-DFR: FCSRT-Delayed Free Recall (B), Landscape test (C) and CERAD Constructional Praxis Recall (D). As described in methods, correlations between FCSRT

(n=64), Landscape test (n=60) and CERAD Constructional Praxis Recall (n=43) and regions of hippocampal grey matter atrophy were investigated in patients combined with controls. The voxels of hippocampal mask without significant differences between groups were shown in white. FCSRT-IFR and FCSRT-DFR were significant in the analysis with $p < 0.01$ corrected and Landscape test and CERAD Constructional Praxis Recall were significant in the analysis with $p < 0.05$ corrected. All shown cluster have a threshold of 20 contiguous voxels. Clusters are overlaid on the MNI standard brain.

Supplementary material

Supplementary Table 1: VBM results showing hippocampal regions of significant grey matter intensity decrease which correlate with Boston Naming Test score.

Supplementary Figure 1:

VBM analysis showing regions of significant grey matter intensity decrease in the whole brain between (A) Amyloid/Tau group vs healthy controls, (B) probable TDP-43 group vs healthy controls (C) Amyloid/Tau group vs probable TDP-43 group and (D) probable TDP-43 group vs Amyloid/Tau group. Results were significant in the analysis with $p < 0.01$ corrected in A, B and D. Results were significant in the analysis with $p < 0.05$ corrected in C. Clusters are overlaid on the MNI standard brain.

Supplementary Figure 2:

VBM results showing hippocampal regions of significant grey matter intensity decrease which correlate with Boston Naming Test score. This result was significant in the analysis with $p < 0.01$ corrected. All shown cluster have a threshold of 20 contiguous voxels. Clusters are overlaid on the MNI standard brain. The voxels of hippocampal mask without significant differences between groups were shown in white.

Table 1. Demographic characteristics, cognition data, *APOE* genotype and CSF biomarkers for different groups and controls.

Parameters	Amyloid/Tau group n=33	Probable TDP-43 group n=14	Healthy Controls n=26
Gender (male/Female)	14/19	7/7	6/20
Age (years)	59.7±4.5	58.4±4.8	57.6±3.9
Disease duration (years)	2.8±1.2	2.7±2.3	NA
MMSE	24.3±2.6 ^f	25.9±3.3 ⁱ	28.9±1.1
FCSRT-Immediate Free Recall ^a	7.5±5.1 ^f	10.5±10.7 ⁱ	29.5±6.0
FCSRT-Immediate Total Recall ^a	19±10.9 ^f	17.0±16.5 ⁱ	44.0±4.0
FCSRT-Delayed Free Recall ^a	2.1±2.3 ^f	4.6±5.1 ⁱ	11.7±2.3
FCSRT-Delayed Total Recall ^a	5.6±4.3 ^f	6.3±6.6 ⁱ	14.9±1.6
Landscape test ^b	37.2±6.2 ^{f,h}	42.1±4.7 ⁱ	46.5±3.2
CERAD Constructional Praxis Recall ^c	3.2±2.9 ^{f,h}	7.0±3.2 ⁱ	10.3±0.7
<i>APOE</i> ^d	63.3% ^{f,h}	8.3%	26.9%
$A\beta_{42}$ ^e	396.0±93 ^{f,h}	802.4±186.8	845.5±223.4
Total-tau ^e	842.6±460.9 ^{f,h}	305.3±133.4 ⁱ	218.1±49.1
P-tau ^e	114.7±37.1 ^{f,h}	43.3±11.8	50.6±10.5

All values are displayed as mean ± standard deviation or proportion. The CSF biomarkers values are expressed in pg/ml.

^a Data missing for 9 subjects (3 from Amyloid/Tau Group, 4 from probable TDP43 group and 2 from Healthy Control group)

^b Data missing for 13 subjects (4 from Amyloid/Tau Group, 5 from probable TDP43 group and 4 from Healthy Control group)

^c Data missing for 30 subjects (13 from Amyloid/Tau Group, 11 from probable TDP43 group and 6 from Healthy Control group)

^d Data missing for 3 subjects (all of them from the probable TDP43 group)

^e Data missing for 5 subjects (all of them from the probable TDP43 group)

^f Significant differences between AD group and control group (P values < 0.05).

^h Significant differences between AD group and probable TDP43 group (P values < 0.05).

ⁱ Significant differences between probable TDP-43 group and control group (P values < 0.05).

Table 2. Voxel-based morphometry results showing hippocampal regions of significant grey matter intensity decrease between different patient groups and healthy controls.

Contrast	Regions	Hemisphere	MNI			Number of voxels	T z-score
			x	y	z		
Amyloid/Tau group vs healthy controls*	Posterior	Right	27	47	31	234	2.8961
	Posterior	Left	57	46	31	202	2.8961
	Anterior	Right	30	59	23	171	2.8961
	Anterior	Left	59	60	22	41	2.6459
Probable TDP43 group vs healthy controls*	Anterior	Left	57	59	21	276	2.8961
	Anterior	Right	30	60	23	117	2.8961
	Posterior	Left	56	46	31	99	2.8961
Amyloid/Tau group vs probable TDP-43 group*	Posterior	Right	30	48	31	82	2.3793
Probable TDP-43 group vs Amyloid/Tau group*	Anterior	Left	57	59	21	253	2.8961

* Results corrected at $P < 0.01$; only clusters with at least 20 contiguous voxels included. MNI=Montreal Neurological Institute.

Table 3. Qualitative summary of patterns of hippocampal atrophy along its longitudinal axis between patient groups.

Hemisphere	Segment	Amyloid/Tau group vs probable TDP-43 group	Probable TDP-43 group vs Amyloid/Tau group
Right	Anterior Hippocampus	-	-
	Posterior Hippocampus	↓	-
Left	Anterior Hippocampus	-	↓↓
	Posterior Hippocampus	-	-

All results are corrected at $P < 0.01$

↓: cluster size smaller than 100 voxels

↓↓: cluster size bigger than 200 voxels

-: No significative difference between groups.

Table 4. Voxel-based morphometry results showing hippocampal regions of significant grey matter intensity decrease which correlate with different CSF AD biomarkers.

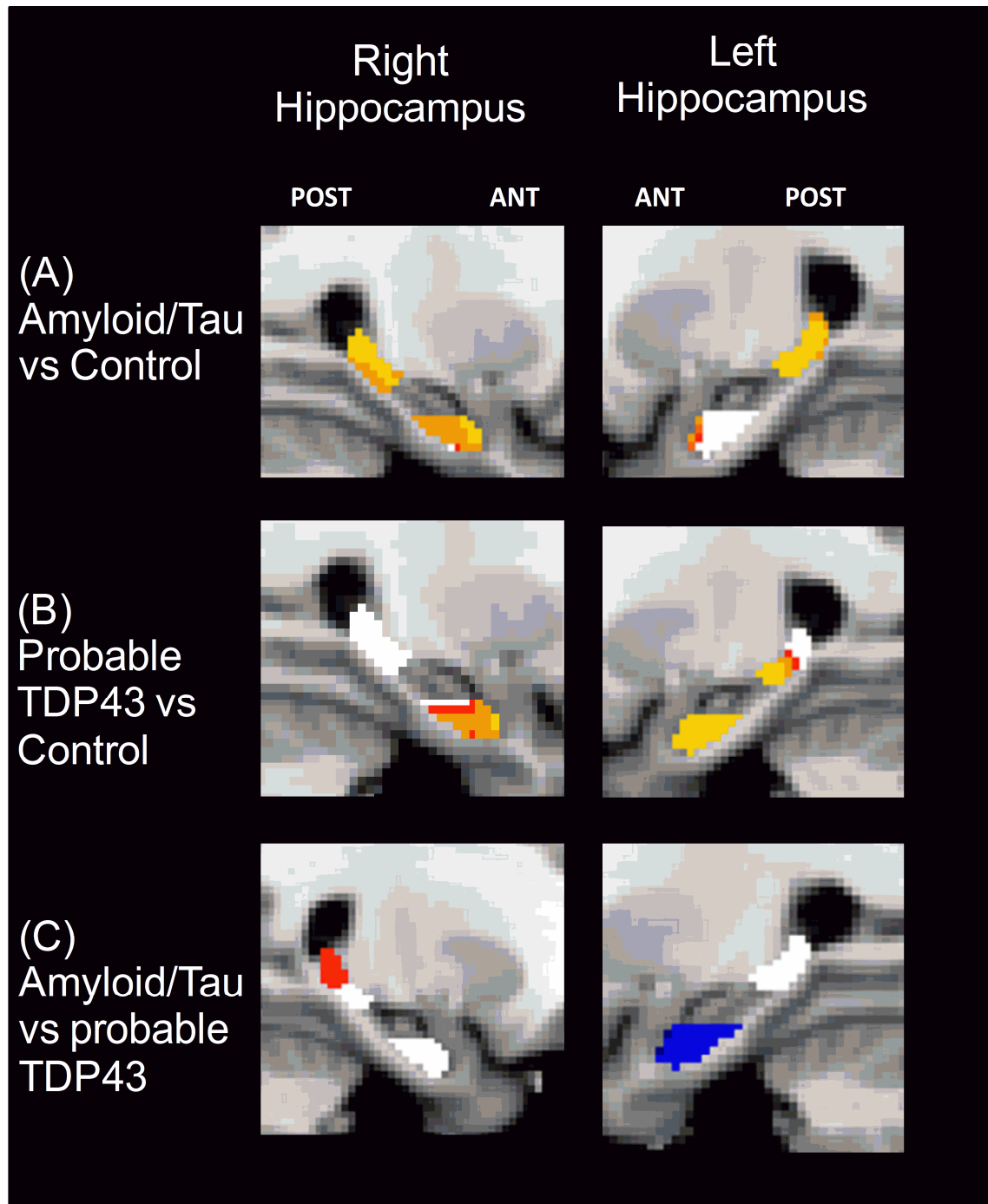
Parameters	Regions	Hemisphere	MNI			Number of voxels	T z-score
			x	y	z		
Total tau CSF*	Posterior	Left	56	47	33	78	1.9935
P-tau CSF*	Posterior	Left	56	47	33	65	1.6663
	Posterior	Right	34	43	38	46	1.6663
A β ₄₂ CSF*	Posterior	Right	30	43	36	136	2.3793
	Posterior	Left	56	47	33	37	1.9935

* Results corrected at $P < 0.05$. Only clusters with at least 20 contiguous voxels included.
MNI+Montreal Neurological Institute.

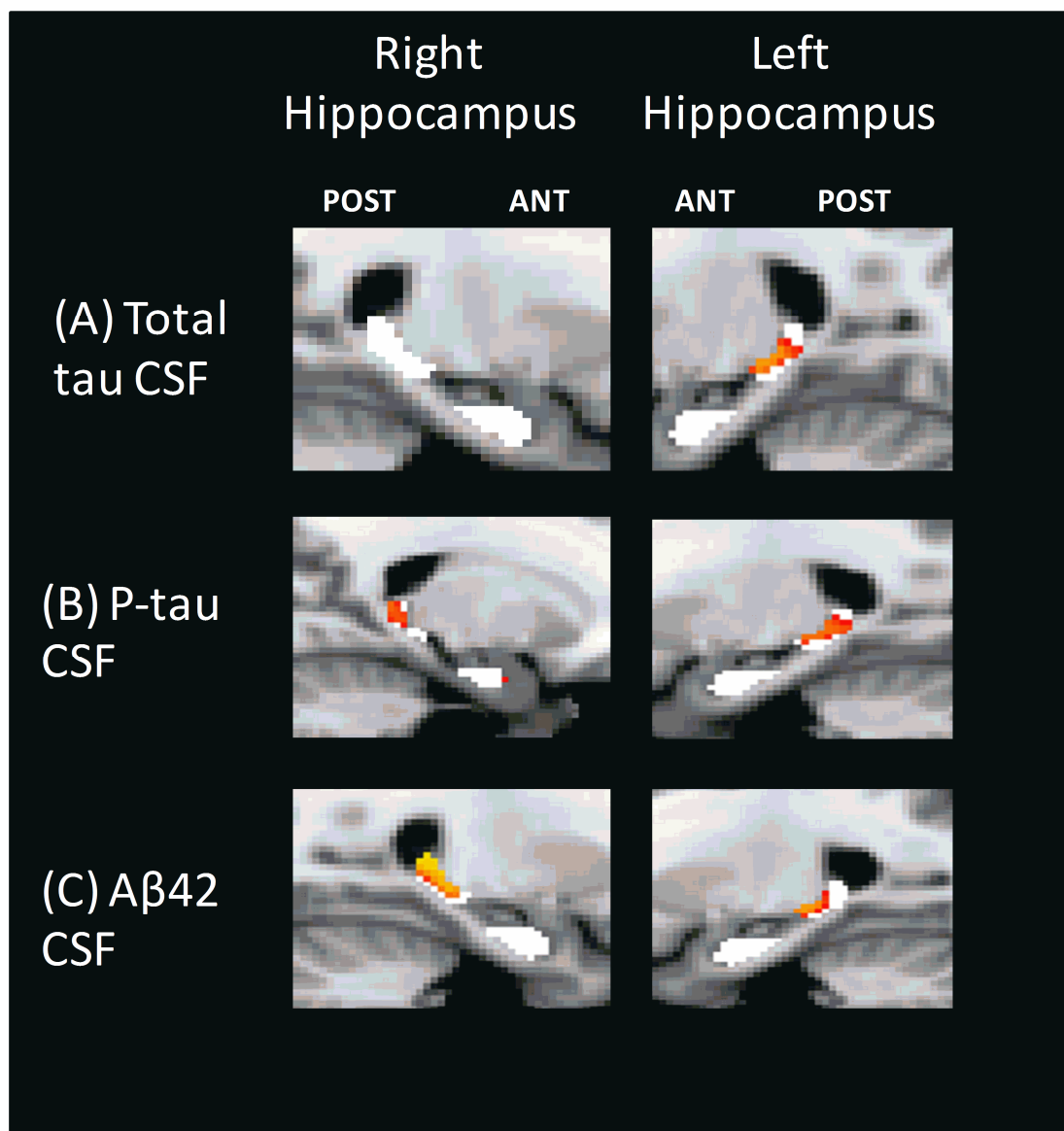
Table 5. Voxel-based morphometry results showing hippocampal regions of significant grey matter intensity decrease which correlate with different cognitive test.

Parameters	Regions	Hemisphere	MNI			Number of voxels	T z-score
			x	y	z		
FCSRT-Immediate Free Recall*	Posterior	Right	31	47	30	196	2.8961
	Posterior	Left	58	45	31	191	2.8961
	Anterior	Left	57	59	21	100	2.8961
	Anterior	Right	30	61	23	27	2.8961
FCSRT-Immediate Total Recall*	Posterior	Left	58	45	31	192	2.8961
	Posterior	Right	33	48	31	191	2.8961
	Anterior	Left	57	59	21	174	2.8961
FCSRT-Delayed Free Recall*	Posterior	Right	31	47	30	209	2.8961
	Posterior	Left	58	45	31	198	2.8961
	Anterior	Left	58	59	21	81	2.8961
	Anterior	Right	30	61	23	29	2.6459
FCSRT-Delayed Total Recall*	Posterior	Left	58	45	31	189	2.8961
	Posterior	Right	28	45	34	162	2.8961
	Anterior	Left	58	60	22	69	2.8961
Landscape Test**	Posterior	Right	27	46	32	78	1.6663
	Posterior	Left	57	47	32	77	1.9935
CERAD Constructional Praxis Recall**	Posterior	Left	57	47	33	127	2.3793

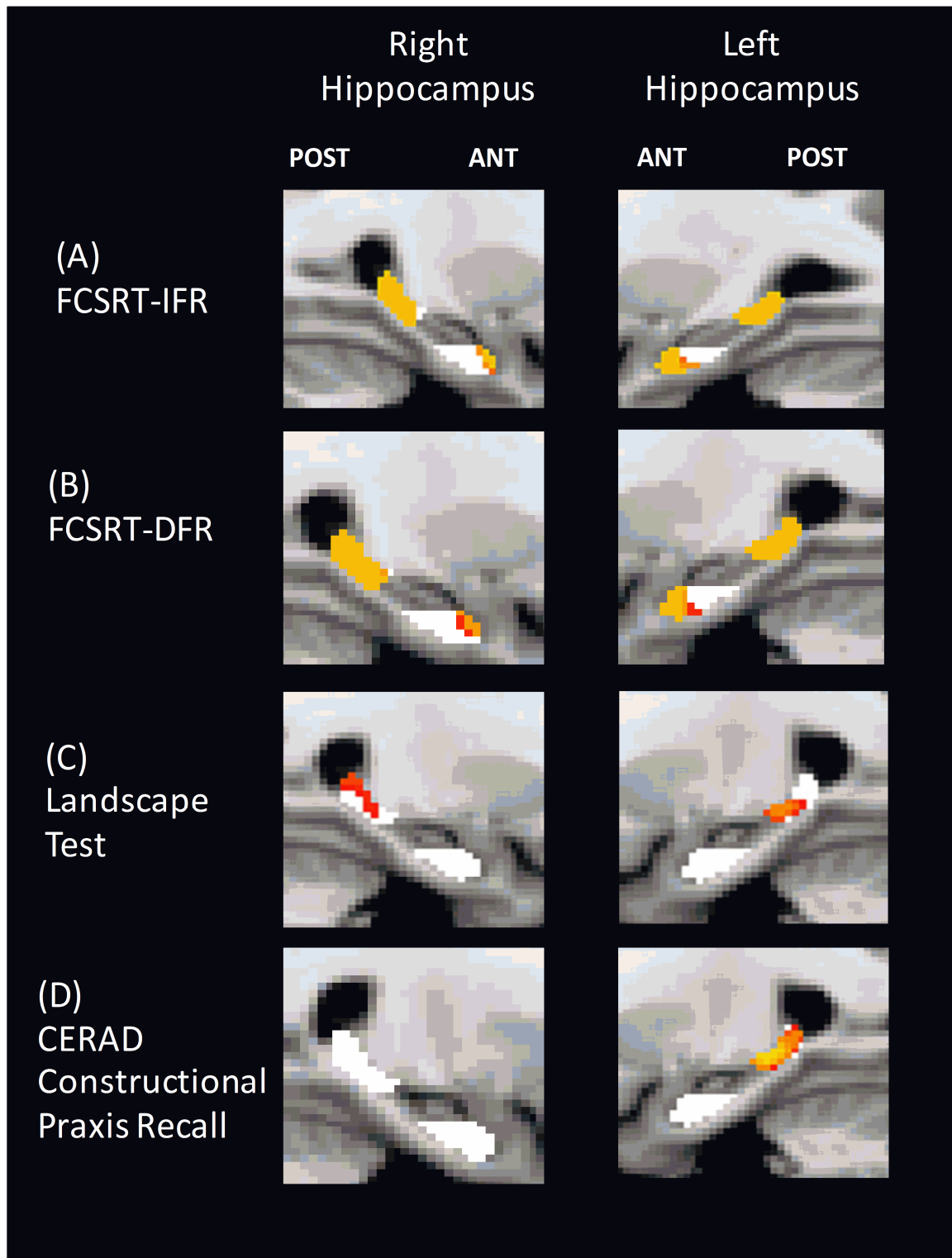
* Results corrected at $P < 0.01$ or ** $P < 0.05$; only clusters with at least 20 contiguous voxels included. MNI+Montreal Neurological Institute.



A



ACCEPTED



Highlights

- Hippocampus could have distinct vulnerability to different proteinopathies.
- Amyloid/Tau pathology affected mainly posterior hippocampus.
- Anterior left hippocampus was more atrophied in TDP-43 pathies.
- Visual memory scores correlated with posterior hippocampal atrophy.
- The hippocampal atrophy pattern (longitudinal axis) could be a new biomarker.