



Title	Spontaneous Echo Contrast and Thrombus Formation at the Carotid Bifurcation After Carotid Endarterectomy
Author(s)	Kawabori, Masahito; Yoshimoto, Tetsuyuki; Ito, Masaki; Fujimoto, Shin; Mikami, Taisei; Muraki, Mutsuko; Kaneko, Sadao; Nakayama, Naoki; Kuroda, Satoshi; Houkin, Kiyohiro
Citation	Neurologia medico-chirurgica, 52(12), 885-891 https://doi.org/10.2176/nmc.52.885
Issue Date	2012-12
Doc URL	http://hdl.handle.net/2115/70778
Rights(URL)	https://creativecommons.org/licenses/by-nc-nd/4.0/
Type	article
File Information	E19_52_3024.pdf



[Instructions for use](#)

Spontaneous Echo Contrast and Thrombus Formation at the Carotid Bifurcation After Carotid Endarterectomy

Masahito KAWABORI,^{1,2} Tetsuyuki YOSHIMOTO,² Masaki ITO,² Shin FUJIMOTO,²
Taisei MIKAMI,³ Mutsuko MURAKI,⁴ Sadao KANEKO,²
Naoki NAKAYAMA,¹ Satoshi KURODA,¹ and Kiyohiro HOUKIN¹

Departments of ¹Neurosurgery and ³Health Science,
Hokkaido University Graduate School of Medicine, Sapporo, Hokkaido;
Departments of ²Neurosurgery and ⁴Neurophysiology,
Kashiwaba Neurosurgical Hospital, Sapporo, Hokkaido

Abstract

Spontaneous echo contrast (SEC) consists of numerous microechoes swirling in the cardiovascular lumen and is usually seen during blood stasis in dysfunctional left atrium. However, SEC and consecutive local thrombus formation at the carotid artery early after carotid endarterectomy (CEA) have not been reported. This study retrospectively investigated the clinical importance and therapeutic strategy of postoperative SEC and thrombus formation in 113 consecutive patients who underwent CEA between 2001 and 2009. Ultrasonography was routinely performed preoperatively, intraoperatively, and 1 day and 1 week after the operation. If SEC and/or thrombus was detected at any time after the operation, follow-up ultrasonography was performed at short intervals, once a week for inpatients and once every 1–2 months for outpatients. Eight of the 113 patients (7%) had SEC after the operation from Day 1 to 12 (mean 7.2 days), and 6 of these 8 patients developed local de novo thrombus formation at the site of SEC from Day 6 to 33 (mean 14.7 days). The maximum luminal narrowing by the thrombi were 26–62% (mean 37%). After administering anticoagulant therapy, all thrombi disappeared from Day 13 to 190 (mean 57 days) from CEA. SEC seen after CEA is highly associated with consecutive local thrombus formation. Postoperative geometric blood stasis with the absence of intima may be the causative factor for its development.

Key words: carotid endarterectomy, thrombosis, ultrasonography, spontaneous echo contrast, anticoagulant therapy

Introduction

Spontaneous echo contrast (SEC) is an echogenic smoke-like swirling pattern of blood flow often seen in the conditions of blood stasis and low velocity blood flow. SEC frequently develops in a dilated and dysfunctional left atrium and left atrial appendage during atrial fibrillation, and carries a high risk of local thrombus formation and thromboembolism.^{1,17,18,24} SEC has also been reported in the carotid artery,^{20,26} but SEC after carotid endarterectomy (CEA) with consecutive local thrombus formation has not been reported. This study retrospectively analyzed clinical records to clarify the clinical importance and therapeutic strategy of SEC and local

thrombus formation in the postoperative carotid artery after CEA.

Patients and Methods

This study included 113 consecutive patients, 95 men and 18 women aged 46 to 83 years (mean \pm standard deviation 68.6 ± 7.5 years), who underwent CEA from January 2001 to December 2009 in Kashiwaba Neurosurgical Hospital. CEA was generally considered appropriate for treatment of more than 70% stenosis on angiography calculated according to the North American Symptomatic Carotid Endarterectomy Trial method. However, if thrombosis from the carotid artery was strongly suspected as the cause of the symptom, CEA was performed even for moderate stenosis (50–70%). Computed tomography (CT), magnetic resonance (MR)

imaging, MR angiography (1.5-T scanner), and cerebral angiography were performed on all patients before and after surgery. All patients were followed up in our outpatient clinic. Hypertension was defined as systolic pressure of 140 mmHg or higher, diastolic pressure of higher than 90 mmHg, or current use of antihypertensive agents. Diabetes mellitus was defined as a hemoglobin A1C value of 6.5% or greater or current use of antiglycemic medications. Patients with serum low density lipoprotein cholesterol levels of 140 mg/dl or greater, or current use of lipid-lowering agent were considered as having hyperlipidemia. Current smoking was defined as any tobacco smoking on a daily basis within 3 months before admission. Cardiac complications were investigated by the cardiologists in this hospital on the basis of history, physical examination, chest roentgenography, and electrocardiography, and ambulatory 24-hour electrocardiography for patients who were suspected of having cardiac disease. The study protocol was approved by the ethics committee of the Kashiwaba Neurosurgery Hospital, and oral informed consent was obtained from each patient or guardian.

Sonographic examination was performed by the same experienced technician. High resolution B-mode sonography of both carotid arteries was performed with a sonographic scanner (Vivid 7; GE Healthcare, Milwaukee, Wisconsin, USA) equipped with a linear array 10-MHz transducer. The dynamic range of the gray scale images was 72 dM. A long axis image of the common and internal carotid arteries was visualized. SEC was defined as dynamic smoke-like microechoes within the vascular lumen near the carotid bifurcation with characteristic swirling motion distinct from white noise artifact. SEC was investigated initially under the high gain setting and then a lower gain setting. After every sonographic examination, two observers (M.K., M.M.) checked the data and independently judged the presence of SEC, and a third observer (T.Y.) was involved if the initial 2 observers did not agree. De novo mural thrombus was defined as a relatively echo-dense mass adjacent to blood clearly distinguished from arterial wall structures and was not observed at the latest echo examination (M.M.). Ultrasonography was routinely performed preoperatively, intraoperatively, and 1 day and 1 week after the operation. If SEC was seen at any time after the operation, follow-up ultrasonography was performed at short intervals, once a week for inpatients and once every 1–2 months for outpatients.

Surgical procedures were described previously.^{10–12,23,28} Briefly, the common carotid artery and its bifurcation were exposed in the usual fashion.

Heparin (2000–3000 U) was administered prior to the carotid clamping to achieve activated coagulation time of more than 200 seconds. Arteriotomy was performed and a three-way internal shunt tube was inserted. The atherosclerotic plaque was carefully dissected and removed under the operating microscope. After confirming total removal of the atherosclerotic plaque, the stay suture was inserted at the distal end of the intima to avoid flipping. The arteriotomy was closed primarily with a running suture using 6–0 nylon. Intraoperative ultrasonography was then performed with the transducer placed directly on the external surface of the sutured artery to detect any problems, such as residual intima, flapping of the distal end, or acute thrombus formation. Antiplatelet agent, already administered preoperatively, was only discontinued on the day of the operation and restarted from the day after the operation. We generally use cilostazol as the antiplatelet agent because this drug is known to improve internal vascular layer function.

All values are expressed as mean \pm standard deviation. Multivariate logistic regression analysis was used to identify predictors for thrombus formation. A value of $p < 0.05$ was considered statistically significant.

Results

The postoperative courses are summarized in Fig. 1. Eight of 113 patients (7%) had SEC from 1 to 12 days (mean 7.2 days) after the operation. Six of these 8 patients developed local de novo thrombus formation, which could not be seen at the latest ultrasonography examination (Table 1). Local de novo thrombus was found between 6 and 33 days (mean 14.7 days) after the operation. The de novo thrombi were located at the ventral side of the operated internal carotid artery in 2 patients, and the ventro-lateral side in 4 patients. The maximum stenosis caused by the de novo thrombus ranged from 26% to 62% (mean 37%). None of these 6 patients developed any neurological symptom. Not all thrombi disappeared after the antiplatelet therapy, as some showed gradual progression. We decided to use anticoagulant therapy using heparin and warfarin. First, we administered 10000 U/day of heparin intravenously, and 2 mg of warfarin orally to achieve adequate anticoagulation. Subsequently, the thrombi became smaller, and all thrombi disappeared from 13 to 190 days (mean 57 days) after the operation. The prothrombin time-international ratio (PT-INR) at the time of thrombus disappearance was 1.4 to 2.0 (mean 1.8).

The clinical data and basic characteristics of the

patients who developed postoperative thrombus and who did not are summarized in Table 2. However, we could not identify any predictors significant for thrombus formation by the multivariate logistic regression analysis. All patients were followed up at our outpatient department after the operation, and we have not encountered any reappearance of the thrombus or restenosis of the carotid artery requiring reoperation.

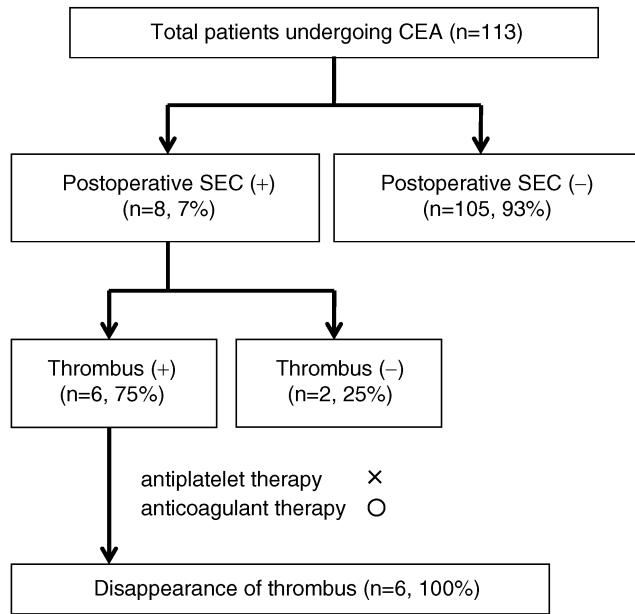


Fig. 1 Scheme of the postoperative courses of the patients who underwent carotid endarterectomy (CEA). Spontaneous echo contrast (SEC) was found in 8 of 113 patients and local de novo thrombus occurred in 6 of these 8 patients. Since all patients who developed thrombus had already taken antiplatelet administration, anticoagulant therapy using heparin and warfarin was started and disappearance of the thrombus was achieved.

Illustrative Case 6: A 64-year-old man was admitted to our hospital for incidental internal carotid artery stenosis which was found at screening ultrasonography for diabetes. He had 90% stenosis of the right carotid artery and underwent CEA. The operation was performed without problems. Intraoperative ultrasonography showed no abnormality. However, routine ultrasonography taken 1 day after CEA revealed that slight high signal swirling at the ventro-lateral portion of the operated carotid artery suggesting SEC (Fig. 2A–C). Power and color Doppler sonography showed that the main stream of the carotid artery was located on the opposite caudal side, and marked decrease of the blood flow and blood stasis was seen at the ventro-lateral portion of the operated carotid artery (Fig. 2D). Six days after CEA, marked de novo thrombosis formation was found at the ventral side of the carotid artery where the blood stasis was seen previously (Fig. 2E, F). Three-dimensional CT angiography taken at this time showed absence of the blood flow at the ventral portion of the operated carotid artery (Fig. 2G). He had no symptom at that time but we were afraid that this thrombosis might cause further ischemic events, so heparin and warfarin therapy were rapidly administered because he had already taken antiplatelet agent. The thrombosis began to decrease after the administration of anticoagulant therapy. The carotid thrombus had completely disappeared 13 days after operation and the PT-INR was raised to 1.4 (Fig. 2H, I). He was discharged from hospital and has not since shown any recurrence of thrombus at the site of carotid artery.

Discussion

SEC was originally documented in the dilated and dysfunctional left atrium and left atrial appendage during atrial fibrillation, and is known to be associated with higher risk of thromboembolism and

Table 1 Features of the 6 patients who developed thrombus formation after spontaneous echo contrast (SEC)

Case No.	Appearance of SEC (days)	Appearance of thrombosis (days)	% Stenosis	Symptoms	Lesion of thrombosis	Disappearance of thrombosis (days)	PT-INR at the time of thrombosis disappearance (days)
1	12	33	62	–	ventro-lateral	190	1.9
2	9	9	35	–	ventro-lateral	22	2.0
3	7	7	33	–	ventral	68	1.9
4	7	11	27	–	ventral	18	1.4
5	7	22	26	–	ventral	32	2.2
6	1	6	36	–	ventral	13	1.4
Mean ± SD	7.2 ± 3.6	14.7 ± 10.7	36.5 ± 13.2			57 ± 68.0	1.8 ± 0.3

PT-INR: prothrombin time-international ratio, SD: standard deviation.

Table 2 Baseline characteristics of the study population

Characteristics	Patients with thrombosis (n = 6)	Patients without thrombosis (n = 107)	p Value
Age, mean \pm SD, yrs	67.7 \pm 26.3	68.2 \pm 7.6	0.384
Male, n (%)	6 (100)	89 (83)	0.850
Body mass index, mean \pm SD	23.7 \pm 9.0	24.0 \pm 3.1	0.809
Diabetes mellitus, n (%)	2 (33)	39 (36)	0.333
Hypertension, n (%)	5 (83)	83 (78)	0.922
Hyperlipidemia, n (%)	4 (67)	51 (48)	0.546
Current smoking, n (%)	3 (50)	53 (50)	0.810
Coronary artery disease, n (%)	2 (33)	22 (21)	0.984
Peripheral artery disease, n (%)	1 (17)	4 (4)	0.217
Atrial fibrillation, n (%)	0 (0)	4 (4)	0.891
ICA stenosis, mean \pm SD, %	71 \pm 27	81 \pm 17	0.122
Contralateral ICA occlusion, n (%)	0 (0)	4 (4)	0.969
Contralateral ICA stenosis (>70%), n (%)	1 (17)	8 (7)	0.970
Preoperative statin medication, n (%)	1 (17)	36 (33)	0.620

ICA: internal carotid artery, SD: standard deviation.

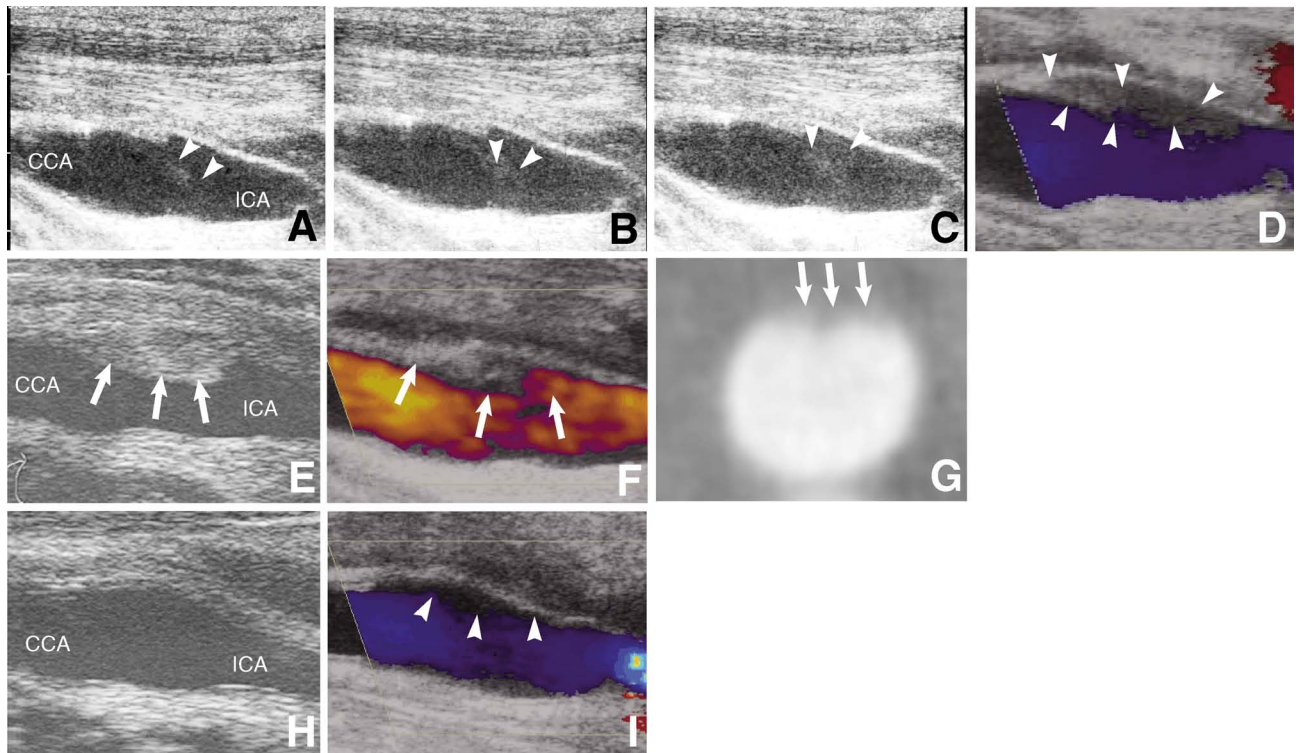


Fig. 2 Postoperative course of a 64-year-old man (Case 6). A–C: Ultrasonography scans taken 1 day after carotid endarterectomy (CEA) revealing slight high signal swirling (arrowheads) at the ventral portion of the operated carotid artery suggesting spontaneous echo contrast. D: Color Doppler sonography scan showing the main stream of the carotid artery located on the opposite medio-caudal side, and marked decrease of the blood flow (arrowheads) at the ventro-lateral portion of the operated carotid artery. E: Ultrasonography scan taken 6 days after CEA showing marked de novo thrombosis formation (arrows) at the ventral side of the carotid artery where slow blood flow was previously seen. F: Power Doppler sonography scan showing absence of the blood flow (arrows) at the thrombosis. G: Three-dimensional computed tomography angiogram taken 6 days after CEA showing absence of the blood flow (arrows) at the ventral portion of the operated carotid artery suggesting acute thrombus. H, I: Ultrasonography scan taken 13 days after CEA showing the carotid thrombosis had completely disappeared with anticoagulant therapy (H), but color Doppler sonography scan showing local blood stasis was still present at the ventro-lateral portion of the carotid artery (I, arrowheads). CCA: common carotid artery, ICA: internal carotid artery.

cerebrovascular disease.²⁻⁴⁾ The mechanism creating carotid and even intracardiac SEC is not completely clear, but blood stasis is considered to be one of the major factors of its development. Blood stasis may cause a reversible increase in echogenicity of the blood, as agitated whole blood, which was initially anechoic, became echogenic within a few minutes and lost echogenicity when agitated again.²⁴⁾ All 9 patients with dynamic intracavitary echoes in the left ventricular apex had severe apical wall motion abnormality due to myocardial infarction or dilated cardiomyopathy, and 7 of the 9 patients had echocardiographic evidence of associated mural thrombus in the apex.^{17,18)} Amorphous echo consisting of numerous microechoes curling up slowly were found in the enlarged left atrium in 27 of 116 patients with rheumatic mitral valve disease and left atrial thrombus was discovered in 13 of these 27 patients.¹⁾ With advances in sonographic technology, especially transesophageal echocardiography, SEC has been frequently observed in the left atrium in patients with nonvalvular atrial fibrillation, and is closely associated with regional thrombus formation and remote embolisms. Many studies have supported the concept that the red cell aggregation causes SEC, which is a normal property of human red cells under the low shear reversible phenomenon, and reflects the equilibrium between adhesive and repulsive forces. Although many investigators have been incredulous about the relationship between SEC and platelets, some recent studies have reported increased platelet activity in the blood from patients with SEC.^{15,29)}

The mechanism of carotid SEC is strongly suspected to involve regional blood stasis, as with intracardiac SEC, because this study could actually show low flow velocity and blood stasis with the color Doppler technique at the site where SEC had developed. The blood flow at the carotid bifurcation may not be uniform and turbulence may be frequent at this lesion. Red blood cell and/or platelet aggregation with fibrin formation at the site of blood stasis may cause carotid SEC. This blood stasis mechanism was also seen in a previous report which frequently observed SEC in the carotid artery where the blood flow was impaired, such as the depression of an ulcer and the open areas between plaques.²⁰⁾ Postoperative anatomical structure, e.g. the angle, the diameter, and the condition of the proximal/distal end of the operated carotid artery, may cause imbalance of the blood flow in the operated carotid artery and result in blood stasis. This study could not find any blood stasis by carotid ultrasonography examination in 105 patients who did not show SEC. However, the precise mechanism by which blood

stasis and SEC/thrombus formation were collocated at the ventral to ventro-lateral portion of the operated carotid artery remains unclear.

The mechanism of the development of consecutive local thrombus formation at the site of SEC is also considered to be strongly associated with this blood stasis. In all the cases in this study, the location of the thrombus was the same as that of the previous SEC. Decrease in SEC was associated with the development of thrombus. Together with this blood stasis, absence of the intima caused by the surgical procedure is also considered to be a cause of the thrombus formation.²⁸⁾ In this study, most of the thrombi were located collateral to the carotid artery treated by arteriotomy. Although the precise mechanisms are still unknown, the geometric changes and the degree of injury to the blood vessels may be much higher in these areas. Injured blood vessels tend to express many coagulative factors at the surface, so activated red blood cells and the efficacy of anticoagulant, but not antiplatelet, therapy may also suggest that the coagulation system is important in thrombus development. However, the present preliminary study could not identify specific factors which caused the development of SEC and thrombus in our patients. Further study is necessary to elucidate the mechanisms.

One of the other interesting points of this study is that we have not encountered any restenosis of the carotid artery in our 113 patients. Restenosis is thought to occur in about 10% of patients in the first year after CEA and in 20% during longer follow-up periods.^{5-9,14,16,19,21,22,25,27)} Inflammation of the endothelial cell is known to be central in the mechanism of restenotic plaque development, which is followed by white blood cell attractant, adhesion molecule expression, and finally active interactions of leukocyte-endothelial cells. Leukocytes and endothelial cells are said to activate each another through adhesion molecules and release various inflammatory cytokines and chemokines. Monocytes migrate into the endothelium through adhesion molecules, then ingest lipids to become foam cells. Accumulation of foam cells and reactive proliferation of the vascular smooth muscles finally result in formation of atherosclerotic plaque.¹³⁾ Early postoperative thrombus, which is rich in inflammation cells, may be important in activating endothelial cells, so treatment of this thrombus may be one of the reasons for the absence of restenosis.

We recognize that there are many limitations in this study. First, the number of patients is still very small for drawing any specific conclusion. A larger series is necessary to prove this phenomenon. Second, the natural history of the postoperative throm-

bus is not clear. If injured intima is one of the causes of the development of the thrombus, the time course of the intimal recovery may reduce thrombus. If so, we are adopting overtreatment to administer warfarin for these patients. However, gradual enlargement of the thrombus at the subacute stage made us afraid of new thromboembolism in these patients. We believe that early administration of the anticoagulant therapy avoided any upcoming thromboembolism. So far, we have not encountered any adverse events from the anticoagulant therapy. Close follow-up monitoring of the PT-INR may avoid unwanted side effects. In the future, decrease and cessation of warfarin at the outpatient department should also be considered.

Postoperative ultrasonography after CEA was very useful to detect SEC and consecutive thrombus formation. Anticoagulant, but not antiplatelet, therapy was effective for resolution. However, further study is necessary to investigate the natural history and therapeutic protocol.

Disclosure

The authors report no conflict of interest concerning the materials or methods used in this study or the findings specified in this paper.

References

- 1) Beppu S, Izumi S, Miyatake K, Nagata S, Park YD, Sakakibara H, Nimura Y: Abnormal blood pathways in left ventricular cavity in acute myocardial infarction. Experimental observations with special reference to regional wall motion abnormality and hemostasis. *Circulation* 78: 157-164, 1988
- 2) Bernhardt P, Schmidt H, Hammerstingl C, Luderitz B, Omran H: Patients with atrial fibrillation and dense spontaneous echo contrast at high risk: a prospective and serial follow-up over 12 months with transesophageal echocardiography and cerebral magnetic resonance imaging. *J Am Coll Cardiol* 45: 1807-1812, 2005
- 3) Black IW, Chesterman CN, Hopkins AP, Lee LC, Chong BH, Walsh WF: Hematologic correlates of left atrial spontaneous echo contrast and thromboembolism in nonvalvular atrial fibrillation. *J Am Coll Cardiol* 21: 451-457, 1993
- 4) Chimowitz MI, DeGeorgia MA, Poole RM, Hepner A, Armstrong WM: Left atrial spontaneous echo contrast is highly associated with previous stroke in patients with atrial fibrillation or mitral stenosis. *Stroke* 24: 1015-1019, 1993
- 5) de Borst GJ, Zanen P, de Vries JP, van de Pavoordt ED, Ackerstaff RG, Moll FL: Durability of surgery for restenosis after carotid endarterectomy. *J Vasc Surg* 47: 363-371, 2008
- 6) Fluri F, Engelter ST, Wasner M, Stierli P, Merlo A, Lyrer PA: The probability of restenosis, contralateral disease progression, and late neurologic events following carotid endarterectomy: a long-term follow-up study. *Cerebrovasc Dis* 26: 654-658, 2008
- 7) Frericks H, Kievit J, van Baalen JM, van Bockel JH: Carotid recurrent stenosis and risk of ipsilateral stroke: a systematic review of the literature. *Stroke* 29: 244-250, 1998
- 8) Gelabert HA, el-Massry S, Moore WS: Carotid endarterectomy with primary closure does not adversely affect the rate of recurrent stenosis. *Arch Surg* 129: 648-654, 1994
- 9) Hellings WE, Moll FL, de Vries JP, de Bruin P, de Kleijn DP, Pasterkamp G: Histological characterization of restenotic carotid plaques in relation to recurrence interval and clinical presentation: a cohort study. *Stroke* 39: 1029-1032, 2008
- 10) Hokari M, Kuroda S, Yasuda H, Nakayama N, Abe S, Iwasaki Y, Saito H: Lumen morphology in mild-to-moderate internal carotid artery stenosis correlates with neurological symptoms. *J Neuroimaging* 21: 348-354, 2011
- 11) Iwasaki M, Kuroda S, Nakayama N, Hokari M, Yasuda H, Saito H, Iwasaki Y: Clinical characteristics and outcomes in carotid endarterectomy for internal carotid artery stenosis in a Japanese population: 10-year microsurgical experience. *J Stroke Cerebrovasc Dis* 20: 55-61, 2011
- 12) Kawabori M, Kuroda S, Yasuda H, Hokari M, Nakayama N, Saito H, Iwasaki Y: Carotid endarterectomy for internal carotid artery stenosis associated with persistent primitive hypoglossal artery: efficacy of intraoperative multi-modality monitoring. *Minim Invasive Neurosurg* 52: 263-266, 2009
- 13) Krupinski J, Font A, Luque A, Turu M, Slevin M: Angiogenesis and inflammation in carotid atherosclerosis. *Front Biosci* 13: 6472-6482, 2008
- 14) Lal BK: Recurrent carotid stenosis after CEA and CAS: diagnosis and management. *Semin Vasc Surg* 20: 259-266, 2007
- 15) Mahony C, Spain C, Spain M, Evans J, Ferguson J, Smith MD: Intravascular platelet aggregation and spontaneous contrast. *J Ultrasound Med* 13: 443-450, 1994
- 16) Makihara N, Toyoda K, Uda K, Inoue T, Gotoh S, Fujimoto S, Yasumori K, Ibayashi S, Iida M, Okada Y: Characteristic sonographic findings of early restenosis after carotid endarterectomy. *J Ultrasound Med* 27: 1345-1352, 2008
- 17) Mikell FL, Asinger RW, Elsperger KJ, Anderson WR, Hodges M: Regional stasis of blood in the dysfunctional left ventricle: echocardiographic detection and differentiation from early thrombosis. *Circulation* 66: 755-763, 1982
- 18) Mikell FL, Asinger RW, Elsperger KJ, Anderson WR, Hodges M: Tissue acoustic properties of fresh left ventricular thrombi and visualization by two dimensional echocardiography: experimental observations.

- Am J Cardiol* 49: 1157–1165, 1982
- 19) Moore WS, Kempczinski RF, Nelson JJ, Toole JF: Recurrent carotid stenosis: results of the asymptomatic carotid atherosclerosis study. *Stroke* 29: 2018–2025, 1998
 - 20) Onozuka H, Muraki M, Mikami T, Yoshimoto T, Yoshizumi T, Kitaguchi M, Sugawara T, Tokuda K, Kaneko S, Kashiwaba T, Yamada S, Tsutsui H, Kitabatake A: Prevalence and clinical importance of spontaneous echo contrast within the carotid artery in patients with ischemic cerebrovascular disease. *J Ultrasound Med* 26: 169–177, 2007
 - 21) Reina-Gutierrez T, Serrano-Hernando FJ, Sanchez-Hervas L, Ponce A, Vega de Ceniga M, Martin A: Recurrent carotid artery stenosis following endarterectomy: natural history and risk factors. *Eur J Vasc Endovasc Surg* 29: 334–341, 2005
 - 22) Sadideen H, Taylor PR, Padayachee TS: Restenosis after carotid endarterectomy. *Int J Clin Pract* 60: 1625–1630, 2006
 - 23) Shichinohe H, Kuroda S, Asano T, Ushikoshi S, Ishikawa T, Houkin K, Murashita T, Iwasaki Y: [Novel stent/CEA strategy for patients with bilateral carotid artery stenosis and coronary artery disease: report of 2 cases]. *No Shinkei Geka* 33: 149–153, 2005 (Japanese)
 - 24) Sigel B, Coelho JC, Spigos DG, Flanigan DP, Schuler JJ, Kasprisin DO, Nyhus LM, Capek V: Ultrasonography of blood during stasis and coagulation. *Invest Radiol* 16: 71–76, 1981
 - 25) Szabo A, Brazda E, Dosa E, Apor A, Szabolcs Z, Entz L: Long-term restenosis rate of eversion endarterectomy on the internal carotid artery. *Eur J Vasc Endovasc Surg* 27: 537–539, 2004
 - 26) Terborg C, Brodhun M, Joachimski F, Fitzek C, Witte OW, Isenmann S: Aneurysm of the extracranial carotid artery with spontaneous echo contrast revealed by duplex sonography. *Ultraschall Med* 28: 216–218, 2007
 - 27) Yamada K, Kishiguchi T, Ito M, Otsuki H, Kohmura E, Taneda M, Hayakawa T: Restenosis following carotid endarterectomy—clinical profiles and pathological findings. *Neurol Med Chir (Tokyo)* 38 Suppl: 284–288, 1998
 - 28) Yoshimoto T, Aoyama T, Shirasaka T, Yoshizumi T, Kashiwaba T: Repeated thrombus formation immediately following carotid endarterectomy. *Neurol Med Chir (Tokyo)* 43: 192–196, 2003
 - 29) Zotz RJ, Muller M, Genth-Zotz S, Darius H: Spontaneous echo contrast caused by platelet and leukocyte aggregates? *Stroke* 32: 1127–1133, 2001
-
- Address reprint requests to: Masahito Kawabori, MD, Department of Neurosurgery, Hokkaido University Graduate School of Medicine, North 15 West 7, Kita-ku, Sapporo 060-8638, Japan.
e-mail: masahitokawabori@yahoo.co.jp