

Effect of Chondroitin Sulfate on Intraocular Pressure in Rats

Nicolás Belforte,¹ Pablo Sande,¹ Nuria de Zavalía,¹ Paul A. Knepper,² and Ruth E. Rosenstein¹

PURPOSE. To study the effect of intracameral injections of chondroitin sulfate (CS) on intraocular pressure (IOP), retinal function, and histology in rats.

METHODS. Acute or chronic injections of CS were performed unilaterally in the rat anterior chamber, whereas the contralateral eye was injected with vehicle. IOP was daily or weekly assessed by a tonometer. Retinal function was assessed by scotopic electroretinography (ERG) and the visual pathway by flash visual evoked potentials (VEPs), whereas the retinal and optic nerve head structure were examined by histologic analysis.

RESULTS. A single injection of 8 mg (but not 2 or 4 mg) CS induced a significant increase of IOP. The increase of IOP induced by a single injection of 8 mg CS lasted for 7 days, whereas chronic (weekly) administration during 10 weeks induced a significant and sustained increase in IOP compared with eyes injected with vehicle. A significant decrease of scotopic ERG a- and b- wave amplitude was observed after 6 and 10 weeks of CS administration. Moreover, a significant decrease in scotopic flash VEP N2-P2 component amplitude was observed in eyes treated with CS for 6 and 10 weeks. A significant loss of ganglion cell layer cells and optic nerve axons was observed in eyes receiving CS for 10 weeks.

CONCLUSIONS. These results suggest that exogenous CS simulates the accumulation of CS in primary open-angle glaucoma and that increased amounts of CS could play a key role in the IOP dysregulation characteristic of glaucoma. (*Invest Ophthalmol Vis Sci.* 2010;51:5768–5775) DOI:10.1167/iovs.10-5660

Glaucoma, a leading cause of irreversible visual loss, is characterized by loss of retinal ganglion cells (RGCs) and their axons. Intraocular pressure (IOP) is the most critical risk factor for primary open-angle glaucoma (POAG). In fact, nearly all glaucoma therapy relies on lowering the IOP level.^{1,2} Elevated IOP often results from alterations in aqueous humor dynamics because of changes in the trabecular meshwork (TM), leading to impaired drainage of aqueous humor.³ The TM

is a specialized tissue forming a biological filter for aqueous humor at the chamber angle and is the major site for regulation of the normal bulk flow of aqueous humor.⁴ The normal TM functions as a self-cleaning, unidirectional, pressure-sensitive, and low-flow (2.75 $\mu\text{L}/\text{min}$) filter.⁵ The TM is divided into the uveal meshwork, corneoscleral meshwork, and juxtacanalicular (JCT) regions. In the uveal and corneoscleral meshwork, sheets of trabecular beams that contain lamellae made of connective tissue or extracellular matrix (ECM) materials are lined by TM cells. In the JCT region, the cells are embedded in a loose ECM, and aqueous outflow resistance is believed to locate largely in the JCT/Schlemm's canal area.^{6,7}

It is likely that the pressure gradient and the resistance to aqueous outflow are altered in POAG. The ECM is a major component of the TM for maintaining aqueous humor outflow. Glycosaminoglycans (GAGs), key components of TM ECM, are long linear sugar chains composed of repeating disaccharide units.^{8,9} There are five main types of GAGs—chondroitin sulfate (CS), dermatan sulfate (DS), heparin/heparan sulfate (HS), keratan sulfate (KS), and hyaluronic acid (HA)—that vary depending on the identity of their disaccharide units. All GAGs, except HA, are sulfated in various positions and to various degrees. For instance, CS chains are commonly sulfated at the 4- and/or 6- hydroxyl positions, DS chains undergo 4- and 2-O-sulfation, whereas HS chains can be N-, 2-O-, 6-O-, and/or 3-O-sulfated.^{10,11} With the exception of HA, all GAG chains are covalently attached to and synthesized on core proteins to form proteoglycans as they move through the endoplasmic reticulum and Golgi apparatus.^{12,13} These are then integrated into the ECM, where they perform many functions, including cell matrix interactions, growth factor binding, and sequestration and maintenance of tissue structural integrity.^{9,13}

The GAG concentration of the TM and of the JCT has been determined by biochemical methods^{14–18} using sequential enzymatic degradation and by histologic staining.^{19–22} GAGs of the TM and of the JCT are considered significant contributors to aqueous outflow resistance in the normal or the POAG TM. Microscale analysis of single human TMs, using GAG-degrading enzymes, both biochemical¹⁸ and computer-aided microscopy studies,²² localized and quantitated the various types of GAGs in the JCT. HA and CS are the predominant types of GAGs in the normal human TM. In the POAG TM and JCT, HA is decreased and CS is increased, whereas the total concentration of GAGs is similar in normal and in POAG TM. Since 1954, based on the results of the infusion of testicular hyaluronidase (a GAG enzyme that degrades HA and CS) in bovine eyes, GAGs were considered to be a factor in aqueous outflow resistance^{23,24}; however, infusion of testicular hyaluronidase in the human eye does not decrease aqueous outflow resistance.^{25,26} In the rabbit,²⁷ dog,²⁸ and bovine²⁴ eye, but not in the primate eye,²⁹ removal of HA correlates with a decrease in aqueous outflow resistance. Thus, the evidence to date suggests that in nonprimate species, there is a GAG barrier to aqueous outflow that is sensitive to testicular hyaluronidase infusion. In primate

From the ¹Laboratory of Retinal Neurochemistry and Experimental Ophthalmology, Department of Human Biochemistry, School of Medicine, University of Buenos Aires, Buenos Aires, Argentina; and the ²Department of Ophthalmology and Visual Sciences, University of Illinois at Chicago, Chicago, Illinois.

Supported by grants from the University of Buenos Aires, CONICET, and the Agencia Nacional de Promoción Científica y Tecnológica (ANPCyT), Argentina.

Submitted for publication April 7, 2010; revised May 17, 2010; accepted June 11, 2010.

Disclosure: N. Belforte, None; P. Sande, None; N. de Zavalía, None; P.A. Knepper, None; R.E. Rosenstein, None

Corresponding author: Ruth E. Rosenstein, Departamento de Química Humana, Facultad de Medicina, UBA, Paraguay 2155, 5° P, (1121), Buenos Aires, Argentina; ruthr@fmed.uba.ar.

studies, the physiological evidence for the presence of a GAG barrier to aqueous outflow is inconclusive.²⁹⁻³¹ Nonetheless, François³² believed that excessive amounts of GAGs in POAG would impede aqueous outflow and increase aqueous outflow resistance. Certainly, ophthalmic viscosurgical devices (OVDs) used in ophthalmic surgery may cause a transient and occasionally significant postoperative increase in IOP.³³⁻³⁵ Moreover, the effect of sodium chlorate (a potent inhibitor of GAG chain sulfation) and β -xyloside (which inhibits the elongation of endogenous GAG chains) was recently assessed in anterior segment perfusion organ culture and in TM cells in culture. Both treatments significantly increased outflow facility in human and porcine eyes, supporting that GAGs play a key role in outflow resistance in human eyes.³⁶

These observations have led to numerous studies aimed at determining the functional role of GAGs in POAG. Biochemical analysis of GAGs from individual POAG TM showed a large decrease in HA and an increase in CS content in the TM.²² Similar results were reported in a rabbit model³⁷ and a primate model (DeSantis L, et al. *IOVS*. 1990;31:ARVO Abstract 99) of dexamethasone-induced ocular hypertension. These results suggest that CS could be important in the regulation of aqueous outflow and that an accumulation of CS in the TM may play a role in POAG. In fact, it was shown that a larger amount of CS in POAG juxtacanalicular connective tissue has a greater impact on outflow resistance than the TM concentration of HA.³⁸ In that context, the aim of the present work was to analyze the effect of increasing CS levels in the rat anterior chamber on IOP and the effect of a chronic treatment with CS on retinal function and histology.

MATERIALS AND METHODS

Animals

Male Wistar rats (average weight 200 ± 40 g), were housed in a standard animal room with food and water ad libitum under controlled conditions of humidity and temperature ($21^\circ\text{C} \pm 2^\circ\text{C}$). The room was lit by fluorescent lights that were turned on and off automatically every 12 hours, with the lights on from 6:00 am to 6:00 pm. All animal procedures were conducted in strict accordance with the ARVO Statement for the Use of Animals in Ophthalmic and Vision Research.

Rats were anesthetized with ketamine hydrochloride (50 mg/kg) and xylazine hydrochloride (0.5 mg/kg) administered intraperitoneally. CS was obtained from Sigma Chemical Co. (St. Louis, MO; catalog no. C9819), isolated from bovine trachea, and composed by 77% CS type A, 10% CS type B, and $\leq 6\%$ proteins, according to the manufacturer.

Using a Hamilton syringe with a 30-gauge needle, 20 μL of 0.1, 0.2, and 0.4 g/mL corresponding to 2, 4, and 8 mg of CS in saline solution was injected into one eye of each anesthetized rat, and an equal volume of vehicle (saline solution) was injected in the fellow (control) eye. The eyes were focused under a surgical microscope (model OMNI MDU XY; Carl Zeiss, Oberkochen, Germany) with coaxial light. The needle moved through the corneoscleral limbus to the anterior chamber with the bevel down. When the tip of the bevel reached the anterior chamber, the liquid progressively increased the chamber's depth, separating the needle from the iris and avoiding needle-lens contact. Applications were made slowly but using a force sufficient to just empty the syringe content (adjusted to 20 μL). In the chronic protocol, injections were applied at the corneoscleral limbus beginning from hour 12 and changing the site of the next injection from hour to hour by rotating the head to achieve better access to the limbus. Injections and IOP assessments were performed after application of 1 drop of 0.5% proparacaine hydrochloride to each eye. Rats showing cataract and animals with phthisis bulbi were excluded from the experiments. In addition, almost all the animals developed localized corneal edema at the site of the injection that lasted less than 24 hours. No differences in the incidence of these ocular complications

were detected between CS and saline-injected eyes. IOP assessments were performed at least 24 hours after injections. A tonometer (TonoPen XL; Mentor, Norwell, MA) was used to assess IOP in conscious, unanesthetized rats as previously described.³⁹ All IOP determinations were assessed by operators who were masked with respect to the treatment applied to each eye. Animals were wrapped in a small towel and held gently, with one operator holding the animal and another making the readings. Five IOP readings were obtained from each eye by using firm contact with the cornea and omitting readings obtained as the instrument was removed from the eye. Differences among readings were less than 10% (SE). The mean of these readings was recorded as the IOP for this eye and this day. Mean values from each rat were averaged, and the resultant mean value was used to compute the group mean IOP \pm SE. IOP measurements were performed at the same time each day or week (between 11:00 am and 12:00 pm) to correct for diurnal variations in IOP.³⁹

Electroretinography

Electroretinographic activity was assessed in dark-adapted rats as previously described.⁴⁰ Briefly, after 6 hours of dark adaptation, rats were anesthetized with intraperitoneal injection of ketamine hydrochloride and xylazine hydrochloride under dim red illumination. Phenylephrine hydrochloride (2.5%) and 1% tropicamide (Alcon Laboratories, Buenos Aires, Argentina) were used to dilate the pupils, and the cornea was intermittently irrigated with balanced salt solution (Alcon Laboratories) to maintain the baseline recording and to prevent exposure keratopathy. Rats were placed facing the stimulus at a distance of 20 cm. All recordings were completed within 20 minutes of the induction of anesthesia, and animals were kept warm during and after the procedure. A reference electrode was placed through the ear, a grounding electrode was attached to the tail, and a gold electrode was placed in contact with the central cornea. A 15-W red light was used to enable accurate electrode placement. This maneuver did not significantly affect dark adaptation and was switched off during the electrophysiological recordings. Electroretinograms (ERGs) were recorded from both eyes simultaneously, and 10 responses to flashes of unattenuated white light (5 ms, 0.2 Hz) from a photic stimulator (light-emitting diodes) set at maximum brightness ($9 \text{ cd} \cdot \text{s}/\text{m}^2$ without a filter) were amplified, filtered (1.5-Hz low-pass filter, 1000 high-pass filter, notch activated) and averaged (BIO-PC; Akonic, Buenos Aires, Argentina). The a-wave was measured as the difference in amplitude between the recording at onset and the trough of the negative deflection, and the b-wave amplitude was measured from the trough of the a-wave to the peak of the b-wave. Electrophysiological responses were averaged for each run. Runs were repeated three times at 5-minute intervals to confirm consistency, and the mean of these three runs was used for subsequent analysis. Mean peak latencies and peak-to-peak amplitudes of the responses from each group of rats were compared.

Flash Visual-Evoked Potentials

For recording of scotopic flash visual-evoked potentials (VEPs), two stainless steel electrodes were surgically placed 4 mm lateral to the interhemispheric fissure and 5.6 mm behind the bregma (active electrode). Reference electrodes were placed 2 mm lateral to the midline and 2 mm before the bregma. A ground electrode was placed in the animal tail. Both electrodes were isolated and fixed with dental acrylic, and the skin was sutured with nylon 5-0. Five days after electrode implantation, VEPs were assessed as follows: after 6 hours of dark adaptation, rats were anesthetized, pupils were dilated, and the cornea was intermittently irrigated as previously described, under dim red illumination. All recordings were completed within 20 minutes of the induction of anesthesia, and animals were kept warm during and after the procedure. Each eye was registered individually, with the contralateral eye occluded, and a 70 stimuli average was registered. Eyes were stimulated with unattenuated white light (1 Hz) from a photic stimulator (light-emitting diodes) set at maximum brightness, amplified, filtered (0.5-Hz low-pass filter, 100 high-pass filter, notch activated),

and averaged (BIO-PC; Akonic). Amplitude between the N2 deflection and the P2 peak was assessed, and N2 latency was measured from onset to the second negative peak.

Light Microscopy

Eyes were enucleated after overdose of anesthetic and were immersed immediately in a fixative containing 4% paraformaldehyde and 1% glutaraldehyde in 0.1 M phosphate buffer (pH 7.2) for 1 hour. The nictitans membrane was maintained in each eye to facilitate orientation. The cornea and the lens were carefully removed, and the posterior portions were fixed for an additional 12-hour period in the same fixative. A cross-section of the optic nerve from control and CS-treated eyes was removed 1.5 mm posterior to the globe and postfixed in 1% osmium tetroxide in phosphate buffer. Nerves were processed into epoxy resin, sectioned at 1 μm , and stained with 1% toluidine blue. Eyecups were dehydrated in an alcohol series and embedded in paraffin. Sections (4- μm thick) were cut along the horizontal meridian through the optic nerve head and stained with hematoxylin and eosin.

Image Analysis

Microscopic images were digitally captured with a microscope (Eclipse E400; Nikon, Tokyo, Japan [illumination: 6-V halogen lamp, 20 W, equipped with a stabilized light source]) and a camera (SSC-DC50; Sony, Tokyo, Japan). The microscope was set up properly for Koehler illumination. The camera output was digitized into a 520×390 pixel matrix (each pixel with 0–255 gray levels) with a video capture card (WinView 601; Leadtek Research Inc., Taipei, Taiwan), displayed on a computer monitor, and saved as an image of 24-bit RGB in .bmp format. The digitized images were transferred to a Scion Image for Windows analysis system (Beta 4.0.2; Scion Corporation, Frederick, MD).

Retinal morphometry was evaluated as described by Takahata et al.,⁴¹ with minor modifications. Three sections were randomly selected from each eye. Nine microscopic images at 1 mm from the temporal edge of the optic disc were digitally analyzed. The light microscope was adjusted to level 4, and a $40\times$ CF E achromat objective was used. At the magnification used, each pixel of the image corresponded to 0.31 μm , and each field in the monitor represented a tissue area of 19318.7 μm^2 . The thickness (in μm) of the inner plexiform layer (IPL), inner nuclear layer (INL), outer nuclear layer (ONL), and total retina was measured. The number of cells in the ganglion cell layer (GCL) was expressed as cells per 100 μm . For each eye, results obtained from three separate sections were averaged, and the mean of five eyes was recorded as the representative value for each group. No attempt was made to distinguish cell types in the GCL for enumeration of cell number. Morphometric analysis was performed by observers masked to the protocol used in each eye.

Optic Nerve Morphometry

Optic nerve axon counting was evaluated as described by Levkovich-Verbin et al.⁴² with minor modifications. To measure the density and fiber diameter distributions, images were captured with a $100\times$ achromat objective from five spaced nerve regions. At the magnification used, each pixel of the image corresponded to 3.2 μm , and each field in the monitor represented a tissue area of 4095 μm^2 . These captured images were edited to eliminate nonaxonal images, and the size of each axon with its myelin sheath (diameter) and the density of axons per square millimeter were calculated for each image. The axon number/field in the CS-treated groups was compared with that of the control fellow eye. The number of axons counted in five images from each nerve was approximately 10% of the total optic nerve area. The counting process was performed by observers masked to the protocol used in each nerve.

Statistical Analysis

Statistical analysis of results was made by a Student's *t*-test or by a two-way analysis of variance (ANOVA) followed by Student's *t*-test or Dunnett's test.

RESULTS

Figure 1 depicts IOP values from eyes injected with vehicle or CS (2, 4, and 8 mg), assessed 24 hours after injections. A slight but not significant increase of IOP was observed in eyes injected with 2 or 4 mg CS, whereas 8 mg CS significantly augmented this parameter. To analyze the temporal course of CS effect on IOP, 10 rats were injected with a single injection of 8 mg CS in one eye, and the contralateral eye was injected with vehicle. IOP was assessed in both eyes of these animals before the injection, (day 0) and then it was assessed daily beginning from 24 hours after injections, as shown in Figure 2. The injection of CS induced an almost twofold increase of IOP over the contralateral eye that lasted for 7 days. On day 8 after injection, IOP in the CS-injected eyes reached control values. To study the effect of chronic administration of CS on IOP, 10 rats were injected once a week with CS (in one eye) or vehicle (in the contralateral eye). IOP was assessed at 7-day intervals in both eyes of each animal, before the new injection. The mean IOP values from these animals assessed weekly are shown in Figure 3. The IOP of CS-treated eyes reached a steady state level that was significantly higher than that of saline-injected eyes and lasted the duration of the study (10 weeks). Both in the acute and in the chronic study, a high degree of group consistency in IOP values was found in CS-injected eyes. All eyes, without any exception, responded with an increase of this parameter after the injection of CS.

The functional state of the retinas from eyes weekly injected with vehicle or CS was analyzed by scotopic electroretinography. The average amplitudes of scotopic ERG a- and b-waves of 10 rats injected with vehicle in one eye and CS in the contralateral eye during 6 weeks are depicted in Figure 4A; representative scotopic ERG traces are shown in Figure 4A (lower). These parameters were significantly reduced in eyes receiving CS. Similar studies were performed after 10 weeks of treatment with vehicle or CS (Fig. 4B). Further reduction of ERG a- and b-wave amplitudes was observed in the eyes injected with CS for 10 weeks. Treatment with CS for 6 or 10 weeks did not affect ERG a- and b-wave latencies compared with eyes injected with vehicle. After 3 weeks of vehicle or CS treatment, no changes in ERG a- and b-wave amplitude were detected (data not shown).

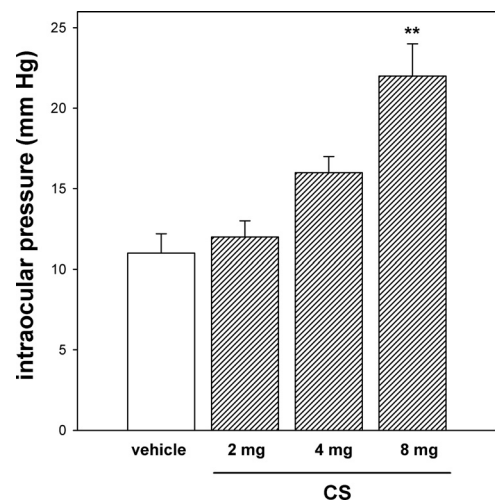


FIGURE 1. Effect of a single intracameral injection of CS on rat IOP. Eyes were injected with vehicle or CS (2–8 mg) 24 hours before IOP assessment. A significant increase of this parameter was observed in eyes injected with 8 (but not 2 or 4) mg CS. Data are mean \pm SEM ($n = 10$ eyes/group). ** $P < 0.01$, by Dunnett's test.

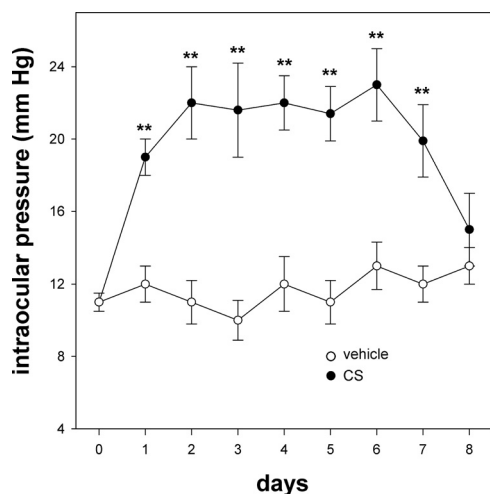


FIGURE 2. Tonometry measurements of IOP in eyes treated with a single intracameral injection of saline solution or CS. Injections were performed at day 0, and IOP was assessed in both experimental groups every day up to day 8. Data are mean \pm SEM ($n = 10$ eyes/group). ** $P < 0.01$, by Student's t -test compared with IOP in saline-injected eyes at the same intervals after injection.

To assess the function of the visual pathway, flash VEPs were recorded after 3, 6, and 10 weeks of ocular hypertension induced by weekly injections of CS. A significant decrease in the VEP N2-P2 component amplitude was observed in eyes injected with CS for 6 and 10 weeks compared with vehicle-injected eyes, without noteworthy changes in latency, as shown in Figure 5 (left). Representative waveforms of VEPs for all groups are also shown in Figure 5 (right). No changes in VEP N2-P2 component amplitude were observed after 3 weeks of ocular hypertension induced by CS (data not shown). ERG and VEP responses in noninjected eyes were identical with those of vehicle-injected eyes (data not shown).

Significant changes were observed in the retina and the optic nerve head of eyes injected with CS for 10 weeks. Although total retinal, IPL, INL, and ONL thickness did not change between vehicle- and CS-injected eyes (data not shown), a significant loss of GCL cells in CS-injected eyes for 10 weeks was observed (Fig. 6). The mean number of GCL cells/100 $\mu\text{m} \pm$ SE from the control group was 9.2 ± 0.5 , whereas in CS-injected eyes it was 5.9 ± 0.7 ($P < 0.01$; $n = 5$ retinas/group). At 3 or 6 weeks of treatment with vehicle or CS, no histologic alterations at the retina or the optic nerve were observed (data not shown). The optic nerve head from eyes treated with CS for 10 weeks exhibited an overall loss of staining uniformity and integrity (Fig. 7). Axons in control optic nerve were generally uniform in shape (rounded) and showed a variable size (Fig. 7A). In contrast, in CS-treated eyes (Fig. 7B), spacing between bundles of axons increased. Individual axons of treated optic nerve also exhibited distention and distortion that resulted in a departure from the circular morphology of normal axons. To analyze the influence of axon diameter on ocular hypertension-induced axon loss, the number of axons in each size group from 0.05 to 0.6 μm was compared in both experimental groups (Fig. 7C). Significant loss of large- and medium-diameter axons, but not small-diameter axons, was observed.

DISCUSSION

Acute injection of CS in the rat anterior chamber significantly increased IOP compared with vehicle-injected eyes in a dose-dependent manner. A single injection of 8 mg CS maintained

elevated levels of IOP for 7 days. Although the intraocular fate of the injected CS is still unknown, the slow decrease of IOP observed after a single injection suggested that it might have left the anterior chamber by the bulk flow or might have been degraded by a local chondroitinase activity. Given that the CS-induced increase in IOP was transient, weekly injections of CS were performed to maintain a sustained increase in IOP. As shown herein, the IOP of eyes treated weekly with CS reached a steady state level that lasted for the duration of the study (10 weeks), which was similar to that provoked by a single injection of CS and which was significantly higher than that from vehicle-injected eyes.

CS- and HA-containing OVDs, such as viscoelastic solution (Viscoat 3.0% HA-4.0% CS; Alcon Laboratories) have become almost essential tools in human anterior segment surgery to reduce tissue trauma and endothelial cell loss and to serve as a space maintainer. However, it is well known that those agents are responsible for causing or exacerbating a transient, but occasionally significant, postoperative IOP elevation. Given that viscoelastic agents containing HA but lacking CS, such as sodium hyaluronate (Healon [1% HA], Healon 5 [2.3% HA], and Healon GV [1.4% HA]; Abbott Medical Optics, Santa Ana, CA), also increase IOP in humans, the hypertensive effect of viscoelastic solution (Viscoat 3.0% HA-4.0% CS; Alcon Laboratories) could be attributed primarily to HA. The hypertensive effect of HA injections in the eye anterior chamber was demonstrated in several species, such as rabbit⁴³ and rat.³⁹ To our knowledge, the effect of CS on rat IOP was not previously examined. It has been shown that the intracameral administration of CS increases IOP in cats but not in rabbits.⁴⁴ However, though repeated injections of CS (9 mg/eye) into the cat anterior chamber increase 4 to 7 mm Hg above that of control eyes, an almost 100% (~ 10 mm Hg) increase was observed in rat eyes injected with CS (8 mg/eye) compared with vehicle-injected eyes. Because the rat eye anterior chamber is very shallow, the higher hypertension provoked by CS in the rat than in the cat eye could be attributed to the fact that actual intracameral concentrations of CS in the rat eye should be higher than those achieved in the cat eye. In addition, a lower ability of CS washout in rats cannot be ruled out.

In a previous report we showed that chronic injections of HA significantly increase rat IOP.³⁹ The efficacy of CS in increasing rat IOP was similar to that obtained through HA

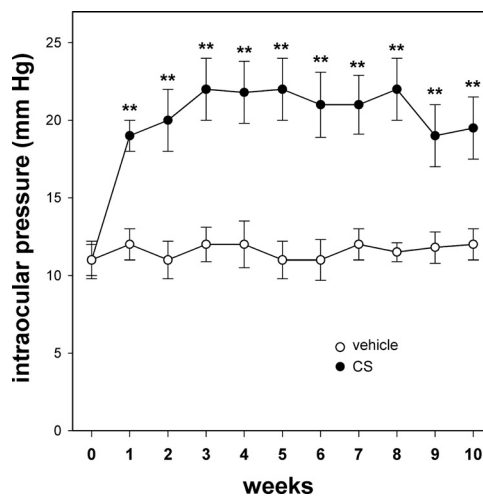


FIGURE 3. Effect of chronic administration of CS on rat IOP. Intracameral injections of saline solution or CS were performed weekly, after the assessment of IOP. Data are mean \pm SEM ($n = 20$ eyes/group). ** $P < 0.01$, by Student's t -test compared with the corresponding IOP values of saline-injected eyes.

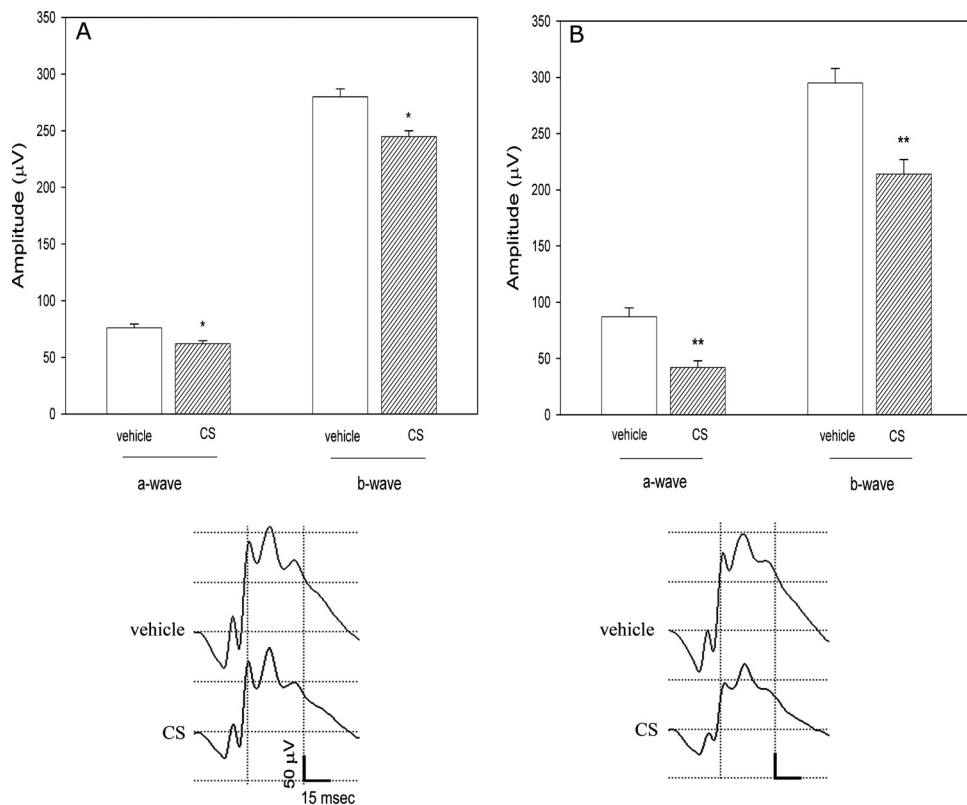


FIGURE 4. Scotopic ERGs in rats injected with vehicle or CS. (A) Animals were injected weekly with CS in one eye and saline solution in the contralateral eye for 6 weeks. (B) Effect of 10-week treatment with vehicle or CS. (A, B, top) Average amplitudes of scotopic ERG a- and b-waves. (A, B, bottom) Representative scotopic ERG traces. A significant reduction in the scotopic ERG a- and b-wave amplitude was observed in eyes injected with CS for 6 and 10 weeks. No changes between intact and vehicle-injected eyes were observed. Data are mean \pm SEM ($n = 20$ eyes/group). * $P < 0.05$, ** $P < 0.01$ by Student's test.

injections. However, to reach a similar level of ocular hypertension, a higher concentration of CS (8 mg/eye) than of HA (0.25 mg/eye) was needed. The domain of HA is concentration dependent and forms a continuous polymer network at a 1-mg/mL concentration. In contrast, the CS domain is limited and forms a bottle brush configuration without a polymer network. In addition, numerous CS binds to a single HA backbone to form the typical proteoglycan aggregate. Therefore, the amount of CS required to increase IOP is expected to be much greater than that of HA, and our results confirm the existing knowledge of the polymerization of HA and the aggregation properties of CS. Besides structural differences, differences in the turnover rate of these two GAGs could account for this observation. Despite the relatively high concentrations of CS needed to induce a sustained ocular hypertension, no signs

of inflammation were observed in eyes chronically injected with CS.

It has been suggested that GAGs may reduce the functional diameter of the flow channels through the deep corneoscleral intertrabecular spaces or may regulate flow through the juxtacanalicular basement membrane. Thus, it seems possible that intracamerally injected CS could act similarly to endogenous CS (e.g., by impeding the normal outflow of aqueous humor). It is well known that ocular hypertension plays a causal, albeit not necessarily exclusive, role in glaucomatous visual loss. In fact, not all experimental models of chronic ocular hypertension cause the same alterations at the retina or the optic nerve head level. Therefore, the following experiments were performed to assess functional and histologic consequences of chronic ocular hypertension induced by CS injections.

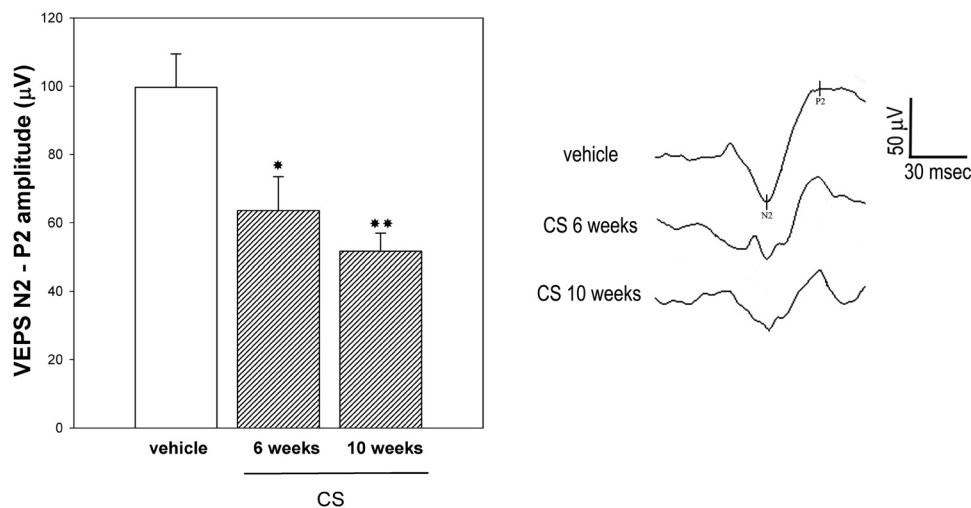
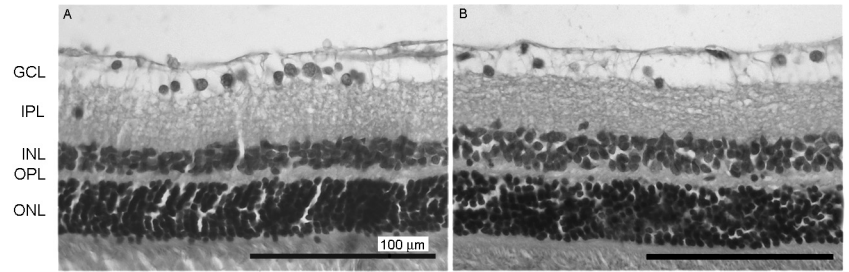


FIGURE 5. Flash VEPs in rats injected with vehicle or CS. Animals were injected weekly with CS in one eye or saline solution in the contralateral eye for 6 or 10 weeks. Left: average amplitudes of VEP N2-P2 component amplitude. Right: representative VEP traces. A significant reduction in flash VEP N2-P2 component was observed in eyes injected with CS for 6 and 10 weeks. No changes between intact and vehicle-injected eyes for 6 or 10 weeks were observed. Data are mean \pm SEM ($n = 20$ eyes/group). * $P < 0.05$, ** $P < 0.01$ by Dunnett's test.

FIGURE 6. Light micrographs of transverse sections of a retina from a rat, in which one eye was injected with saline solution (A) and the contralateral eye was injected with CS for 10 weeks (B). Note the diminution of the GCL in the eye injected with CS. The other retinal layers showed a normal appearance. Hematoxylin and eosin stain.



Several observations support that some components of the flash ERG can be affected in experimental models of glaucoma. The present results support this observation because chronic injections of CS induced a significant decrease in the scotopic ERG a- and b-wave amplitudes evident at 6 weeks of treatment. In addition, the fact that a further decrease in these parameters was observed after 10 weekly injections of CS suggests a progressive retinal dysfunction associated with chronic ocular hypertension. In agreement with these results, in the three-vein episcleral/limbal vein occlusion model for inducing glaucomatous pathology in the rat eye, a significant decrease in ERG a- and b-wave amplitude was observed.⁴⁵ Similar changes

in flash ERG were described in the DBA/2 mouse with angle-closure glaucoma⁴⁶ and in eyes chronically injected with HA in the anterior chamber.⁴⁰ Furthermore, Viswanathan et al.⁴⁷ showed changes in the uniform field ERG that correlate with pattern ERG responses produced by a laser-induced glaucoma in monkeys, and a significant reduction of scotopic ERG b-wave amplitude was described in Brown Norway rats with hypertonic saline injection into an episcleral vein.⁴⁸

Although VEPs reflect the activity of all cells in the pathway from photoreceptors to visual cortex, including RGCs and their axons, few studies have previously assessed VEPs in rodent experimental models of glaucoma. Glaucoma

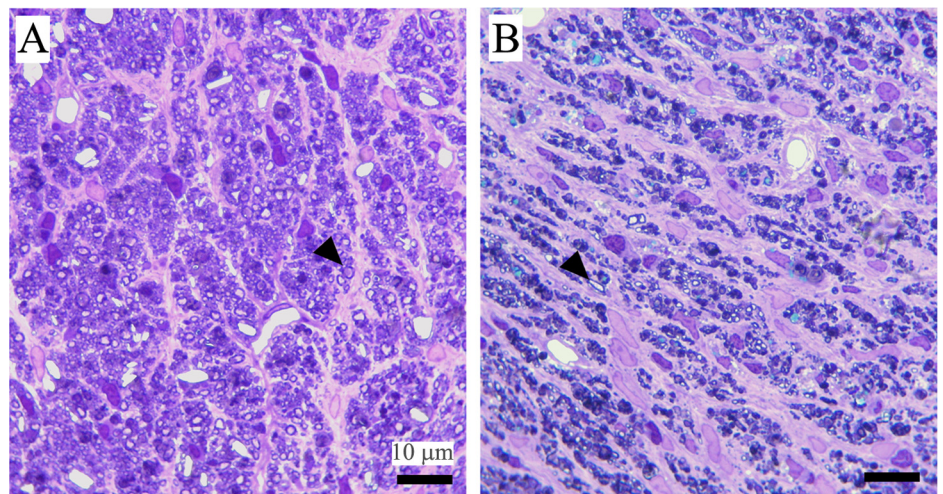
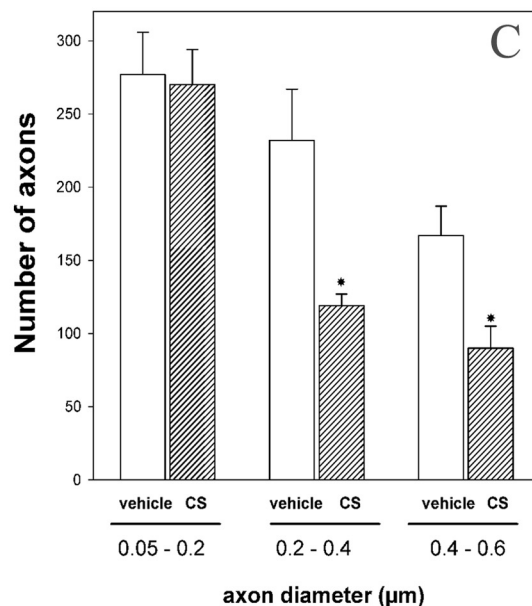


FIGURE 7. Images of optic nerve cross-sections in (A) control eye and (B) CS-treated eye. (A) Healthy, intact optic nerve. Note the homogeneity of the staining. In vehicle-injected eyes, individual axons were generally uniform in shape (*arrowhead*), generally rounded, and packed together tightly to form the fibers of the healthy nerve. In the nerve of the treated eye (B), a less stained area (*arrowhead*) indicates a nerve alteration. Disease in individual axons was characterized by axonal distention and distortion that resulted in a departure from the circular morphology of normal axons (*arrowheads*). There is a predominance of small-diameter axons. Toluidine blue stain. (C) Axonal diameter distribution in eyes injected with vehicle or CS for 10 weeks. A significant decrease in the number of middle and large, but not small, axons was observed in CS-injected eyes. Data are mean \pm SEM ($n = 5$ eyes/group). * $P < 0.05$, by Student's test.



has been reported to affect VEPs by causing both reductions in amplitude⁴⁹ and increases in latency.⁵⁰ However, only modest delays in the VEP response of eyes with glaucomatous damage were shown more recently.⁵¹ The present results indicate a significant decrease in flash VEP N2-P2 amplitude but not latency in eyes exposed to ocular hypertension induced by CS, possibly because of decreased input to the visual cortex or to alterations at the cortical levels. In agreement with these results, VEP amplitudes are reduced in monkeys with experimental glaucoma.⁵² Although species differences in the neural generators of these flash VEP components may exist, they appear to be generated in the cortex. Therefore, it is tempting to speculate that chronic injections of CS could affect optic nerve postsynaptic, in addition to ganglion cell and optic nerve head, responses.

The retinal dysfunction described herein seems to be dependent on time of hypertension. A greater decrease in ERG and VEPs was observed at 10 weeks than at 6 weeks of ocular hypertension, and no changes in these parameters were observed after 3 weeks of treatment with CS.

As for the retinal architecture, significant damage confined to the GCL and optic nerve axons was observed in CS-injected eyes after 10 weeks of treatment. In control eyes, morphology compatible with a healthy, intact optic nerve was observed. Individual axons were generally uniform in shape and packed together tightly to form the fibers of the nerve. In contrast, an overall loss of nerve integrity and an alteration of axon shape were observed in hypertensive eyes. In addition, a significant decrease in axon number was evident; large axons were significantly more vulnerable than small-diameter fibers. It seems unlikely that this result may be attributable to axon shrinkage because no shift of axonal diameter distribution to smaller sizes was evident in CS-injected eyes. This loss of uniformity at the level of individual axons probably underlies the overall loss of uniformity and nerve integrity. In agreement, a preferential loss of large optic nerve axons was demonstrated in other models of rat and monkey experimental glaucoma.^{42,53}

It seems improbable that CS-induced hypertension could provoke significant ischemia. In general, the magnitude of hypertension needed to induce retinal ischemia is much higher than that achieved after the injection of CS. For example, it was shown that blood flow in the rabbit optic nerve head was not reduced by an elevation of the IOP lower than 50 mm Hg.⁵⁴ Furthermore, the increase in IOP induced by CS is similar to or lower than that obtained in other experimental models of glaucoma in rats.^{40,55-57} On the other hand, it is well known that the consequences of retinal ischemia are more severe in periods close to the ischemic episode. If our results were the consequence of ischemic causes, it may be presumed that retinal function and histology should change immediately after the first injection. This was not the case because 6 and 10 weeks of ocular hypertension were needed to induce significant retinal dysfunction and histologic changes, respectively.

In summary, the present results indicate that weekly injections of CS induced a moderate and sustained IOP elevation, which, in turn, provoked significant alterations in retinal function and histology compatible with human open-angle glaucoma alterations. Moreover, taken together with evidence showing increased levels of CS in the human TM of glaucoma patients, the present results support that increased levels of CS could be a causal factor in glaucomatous neuropathy.

Based on results reported herein that showed a significant increase in rat IOP, as well as functional and histologic alterations induced by CS that reproduced the primary features of human glaucoma together with the increase of CS in TM from glaucoma patients, it seems likely that ECM CS could play a key role in the IOP dysregulation characteristic of glaucoma.

References

- Gordon MO, Beiser JA, Brandt JD, et al. The Ocular Hypertension Treatment Study: baseline factors that predict the onset of primary open-angle glaucoma. *Arch Ophthalmol*. 2002;120:714-720.
- Le A, Mukesh BN, McCarty CA, Taylor HR. Risk factors associated with the incidence of open-angle glaucoma: the visual impairment project. *Invest Ophthalmol Vis Sci*. 2003;44:3783-3789.
- Gabelt BT, Kaufman PL. Changes in aqueous humor dynamics with age and glaucoma. *Prog Retin Eye Res*. 2005;24:612-637.
- Knepper PA, Yue BYJT. Abnormal trabecular meshwork outflow. In: Levin LA, Albert DM, eds. *Ocular Disease: Mechanisms and Management*. Philadelphia: Saunders/Elsevier; 2010:171-177.
- Brubaker RF. Flow of aqueous humor in humans: the Friedenwald Lecture. *Invest Ophthalmol Vis Sci*. 1991;32:3145-3166.
- Johnson M. What controls aqueous humor outflow resistance? *Exp Eye Res*. 2006;82:545-557.
- Ethier CR. The inner wall of Schlemm's canal. *Exp Eye Res*. 2002;74:161-172.
- Davies JA, Fisher CE, Barnett MW. Glycosaminoglycans in the study of mammalian organ development. *Biochem Soc Trans*. 2001;29:166-171.
- Sasisekharan R, Raman R, Prabhakar V. Glycomics approach to structure-function relationships of glycosaminoglycans. *Annu Rev Biomed Eng*. 2006;8:181-231.
- Silbert JE, Sugumaran G. Biosynthesis of chondroitin/dermatan sulfate. *IUBMB Life*. 2002;54:177-186.
- Sugahara K, Kitagawa H. Heparin and heparan sulfate biosynthesis. *IUBMB Life*. 2002;54:163-175.
- Prydz K, Dalen KT. Synthesis and sorting of proteoglycans. *J Cell Sci*. 2000;113:193-205.
- Scott JE. Extracellular matrix, supramolecular organisation and shape. *J Anat*. 1995;187:259-269.
- Knepper PA, Farbman AI, Telser AG. Aqueous outflow pathway glycosaminoglycans. *Exp Eye Res*. 1981;32:265-277.
- Acott TS, Westcott M, Passo MS, Van Buskirk EM. Trabecular meshwork glycosaminoglycans in human and cynomolgus monkey eyes. *Invest Ophthalmol Vis Sci*. 1985;26:1320-1329.
- Acott TS, Kingsley PD, Samples JR, Van Buskirk EM. Human trabecular meshwork organ culture: morphology and glycosaminoglycan synthesis. *Invest Ophthalmol Vis Sci*. 1988;29:90-100.
- Johnson DH, Knepper PA. Microscale analysis of the glycosaminoglycans of human trabecular meshwork: a study in perfusion organ cultured eyes. *J Glaucoma*. 1994;3:58-69.
- Knepper PA, Goossens W, Hvizd M, Palmberg PF. Glycosaminoglycans of the human trabecular meshwork in primary open-angle glaucoma. *Invest Ophthalmol Vis Sci*. 1996;37:1360-1367.
- Grierson I, Lee WR. Acid mucopolysaccharides in the outflow apparatus. *Exp Eye Res*. 1975;21:417-431.
- Knepper PA, McLone DG. Glycosaminoglycans and outflow pathways of the eye and brain. *Pediatr Neurosci*. 1985;12:240-251.
- Gong H, Freddo TF, Johnson M. Age-related changes of sulfated proteoglycans in the normal human trabecular meshwork. *Exp Eye Res*. 1992;55:691-709.
- Knepper PA, Goossens W, Palmberg PF. Glycosaminoglycan stratification in normal and primary open-angle glaucoma juxtacanalicular tissue. *Invest Ophthalmol Vis Sci*. 1996;37:2414-2425.
- Barany EH. In vitro studies of the resistance to flow through the angle of the anterior chamber. *Acta Soc Med Upsal*. 1953;59:260-276.
- Barany EH, Scotchbrook S. Influence of testicular hyaluronidase on the resistance to flow through the angle of the anterior chamber. *Acta Physiol Scand*. 1954;30:240-248.
- Pedler C. The relationship of hyaluronidase to aqueous outflow resistance. *Trans Ophthalmol Soc UK*. 1956;76:51-63.
- Grant WM. Experimental aqueous perfusion in enucleated human eyes. *Arch Ophthalmol*. 1963;69:783-801.
- Knepper PA, Farbman AI, Telser AG. Exogenous hyaluronidases and degradation of hyaluronic acid in the rabbit eye. *Invest Ophthalmol Vis Sci*. 1984;25:286-293.

28. Van Buskirk MS, Brett J. The canine eye: in vitro dissolution of the barriers to aqueous outflow. *Invest Ophthalmol Vis Sci.* 1978;17:258-263.
29. Hubbard WC, Johnson M, Gong H, et al. Intraocular pressure and outflow facility are unchanged following acute and chronic intracameral chondroitinase ABC and hyaluronidase in monkeys. *Exp Eye Res.* 1997;65:177-190.
30. Peterson WS, Jocson VL. Hyaluronidase effects on aqueous outflow resistance. *Am J Ophthalmol.* 1974;77:573-577.
31. Sawaguchi S, Yue B, Yeh P, Tso M. Effects of intracameral injection of chondroitinase ABC in vivo. *Arch Ophthalmol.* 1992;110:110-117.
32. Francois J. The importance of mucopolysaccharides in intraocular pressure. *Invest Ophthalmol.* 1975;14:173-176.
33. Tognetto D, Cecchini P, Ravalico G. Survey of ophthalmic viscosurgical devices. *Curr Opin Ophthalmol.* 2004;15:29-32.
34. Rainer G, Menapace R, Schmid KE, et al. Natural course of intraocular pressure after cataract surgery with sodium chondroitin sulfate 4%-sodium hyaluronate 3% (Viscoat). *Ophthalmology.* 2005;112:1714-1718.
35. Arshinoff SA, Albiani DA, Taylor-Laporte J. Intraocular pressure after bilateral cataract surgery using Healon, Healon5, and Healon GV. *J Cataract Refract Surg.* 2002;28:617-625.
36. Keller KE, Bradley JM, Kelley MJ, Acott TS. Effects of modifiers of glycosaminoglycan biosynthesis on outflow facility in perfusion culture. *Invest Ophthalmol Vis Sci.* 2008;49:2495-2505.
37. Knepper PA, Collins JA, Frederick R. Effects of dexamethasone, progesterone, and testosterone on IOP and GAGs in the rabbit eye. *Invest Ophthalmol Vis Sci.* 1985;26:1093-1100.
38. Knepper PA, Fadel JR, Miller AM, et al. Reconstitution of trabecular meshwork GAGs: influence of hyaluronic acid and chondroitin sulfate on flow rates. *J Glaucoma.* 2005;14:230-238.
39. Benozzi J, Nahum LP, Campanelli JL, Rosenstein RE. Effect of hyaluronic acid on intraocular pressure in rats. *Invest Ophthalmol Vis Sci.* 2002;43:2196-2200.
40. Moreno MC, Marcos HJ, Oscar Croxatto J, et al. A new experimental model of glaucoma in rats through intracameral injections of hyaluronic acid. *Exp Eye Res.* 2005;81:71-80.
41. Takahata K, Katsuki H, Kume T, et al. Retinal neuronal death induced by intraocular administration of a nitric oxide donor and its rescue by neurotrophic factors in rats. *Invest Ophthalmol Vis Sci.* 2003;44:1760-1766.
42. Levkovitch-Verbin H, Quigley HA, Martin KR, Valenta D, Baumrind LA, Pease ME. Translimbal laser photocoagulation to the trabecular meshwork as a model of glaucoma in rats. *Invest Ophthalmol Vis Sci.* 2002;43:402-410.
43. Harooni M, Freilich JM, Abelson M, Refojo M. Efficacy of hyaluronidase in reducing increases in intraocular pressure related to the use of viscoelastic substances. *Arch Ophthalmol.* 1998;116:1218-1221.
44. Zhu MD, Cai FY. Development of experimental chronic intraocular hypertension in the rabbit. *Aust N Z J Ophthalmol.* 1992;20:225-234.
45. Bayer AU, Danias J, Brodie S, et al. Electroretinographic abnormalities in a rat glaucoma model with chronic elevated intraocular pressure. *Exp Eye Res.* 2001;72:667-677.
46. Bayer AU, Neuhardt T, May AC, et al. Retinal morphology and ERG response in the DBA/2NNia mouse model of angle-closure glaucoma. *Invest Ophthalmol Vis Sci.* 2001;42:1258-1265.
47. Viswanathan S, Frishman IJ, Robson JG. The uniform field and pattern ERG in macaques with experimental glaucoma: removal of spiking activity. *Invest Ophthalmol Vis Sci.* 2000;41:2797-2810.
48. Chauhan BC, Pan J, Archibald ML, LeVatte TL, Kelly ME, Tremblay F. Effect of intraocular pressure on optic disc topography, electroretinography, and axonal loss in a chronic pressure-induced rat model of optic nerve damage. *Invest Ophthalmol Vis Sci.* 2002;43:2969-2976.
49. Papst N, Bopp M, Schnaudigel OE. Pattern electroretinogram and visually evoked cortical potentials in glaucoma. *Graefes Arch Clin Exp Ophthalmol.* 1984;22:29-33.
50. Towle VL, Moskowitz A, Sokol S, Schwartz B. The visual evoked potential in glaucoma and ocular hypertension: effects of check size, field size, and stimulation rate. *Invest Ophthalmol Vis Sci.* 1983;24:175-183.
51. Grippo TM, Hood DC, Kanadani FN, et al. A comparison between multifocal and conventional VEP latency changes secondary to glaucomatous damage. *Invest Ophthalmol Vis Sci.* 2006;47:5331-5336.
52. Johnson MA, Drum BA, Quigley HA, Sanchez RM, Dunkelberger GR. Pattern-evoked potentials and optic nerve fiber loss in monocular laser-induced glaucoma. *Invest Ophthalmol Vis Sci.* 1989;30:897-907.
53. Glovinsky Y, Quigley HA, Dunkelberger GR. Retinal ganglion cell loss is size dependent in experimental glaucoma. *Invest Ophthalmol Vis Sci.* 1991;32:484-491.
54. Okuno T, Oku H, Sugiyama T, Yang Y, Ikeda T. Evidence that nitric oxide is involved in autoregulation in optic nerve head of rabbits. *Invest Ophthalmol Vis Sci.* 2002;43:784-789.
55. Shareef SR, Garcia-Valenzuela E, Salierno A, Walsh J, Sharma SC. Chronic ocular hypertension following episcleral venous occlusion in rats. *Exp Eye Res.* 1995;61:379-382.
56. Morrison JC, Moore CG, Deppmeier LM, Gold BG, Meshul CK, Johnson EC. A rat model of chronic pressure-induced optic nerve damage. *Exp Eye Res.* 1997;64:85-96.
57. Ueda J, Sawaguchi S, Hanyu T, et al. Experimental glaucoma model in the rat induced by laser trabecular photocoagulation after an intracameral injection of India ink. *Jpn J Ophthalmol.* 1998;42:337-344.