

UNIVERSITÀ DEGLI STUDI DI UDINE
CORSO DI DOTTORATO DI RICERCA IN SCIENZE E TECNOLOGIE CLINICHE
CICLO XXIV



TESI DI DOTTORATO DI RICERCA

CHOROIDAL NEOVASCULARIZATION MANAGEMENT IN PATHOLOGICAL MYOPIA

DOTTORANDO

Dott. Alessandro Papayannis

RELATORI

Chiar.mo Prof. Francesco Maria Bandello

Chiar.mo Prof. Francesco Saverio Ambesi Impiombato

CORRELATORI

Dott. Maurizio Battaglia Parodi

Dott. Pierluigi Iacono

Introduction

Myopia is one of the leading causes of visual impairment in the world especially from 20-50 years of age.¹ Prevalence rates of myopia vary between 2 and 33%, depending on the race and age of the analyzed population.²⁻¹¹ The prevalence of myopia has been reported to reach 1.7% to 2.1% of the general population of United States,⁹ but is higher in Asia and Middle East¹⁰⁻¹²

Myopia can be classified as simple (physiologic) and degenerative (or pathologic). Eyes with simple myopia have a refractive error of less than 6 diopters, and lack pathological changes, whereas eyes with degenerative myopia present a refractive error of at least 6 diopters in association with degenerative changes occurring especially in the posterior segment of the globe.³⁻⁶

The pathogenesis of degenerative myopia is still unclear, but both hereditary and environmental factors seem to play a role. Degenerative myopia (DM) may be determined by genetic factors to a greater extent than simple myopia and the genetic profile of degenerative myopia might differ from that of simple myopia.

Multiple loci for susceptibility to myopia have been mapped, most of which are autosomal dominant.¹³ These loci include MYP3 (603221) on 12q, MYP5 (608474) on 17q, MYP6 (608908) on 22q12, MYP7 (609256) on 11p13, MYP8 (609257) on 3q26, MYP9 (609258) on 4q12, MYP10 (609259) on 8p23, MYP11 (609994) on 4q22-q27, MYP12 (609995) on 2q37.1, MYP14 (610320) on 1p36, MYP15 (612717) on 10q21.1, MYP16 (612554) on 5p15.33-p15.2, MYP17 (formerly MYP4) (608367) on 7p15, MYP19 (613969) on 5p15.1-p13.3, and MYP20 (614166) on 13q12.12. An autosomal recessive locus, MYP18 (255500), maps to 14q21-q24. X-linked loci include MYP1 (310460) on Xq28 and MYP13 (300613) on Xq23-q25.

Furthermore, DM occurs commonly in association with Marfan, Ehlers-Danlos, Down and Sticklers syndromes.

Environmental factors include close work, emotional stress, and increasing formal education. Prolonged accommodation and intraocular pressure are suspected of influencing axial elongation in eyes with decreased scleral resistance.¹⁴⁻¹⁷

Many factors including scleral growth and remodelling, along with vitreous synthesis might be involved in the development of myopia.¹⁷⁻²⁰

Choroidal Neovascularization

A major cause of visual loss in myopic eyes is the development of choroidal neovascularization (CNV). The prevalence of CNV has been reported between 5% and 10%,²¹⁻²² with subfoveal location being quite frequent, accounting for 58-74% of cases, whereas juxtafoveal CNV has been described in 32% of cases.² Myopic CNV are generally small (< 1 disc area), flat, greyish with hyperpigmented margin. Most of CNV are less than 1000 μ in diameter,²³ perhaps in relationship with the underlying attenuation of the blood supply from the thinner choroid. Moreover, myopic CNV are type II (located in the subretinal space between the sensory retina and the retinal pigment epithelium) in most cases, as opposed to CNV associated with age-related macular degeneration, which are mostly type I (situated in the sub-retinal pigment epithelium space).^{24,25} CNV may occur adjacent to a lacquer crack, in an area of geographic atrophy of the retinal pigment epithelium (RPE), or also in an area of generalized attenuation of RPE and choroid.²⁵ Among myopic patients with pre-existing CNV, more than 30% will develop CNV in the fellow eye within 8 years.²⁶ Fluorescein angiography (FA) may demonstrate abnormally slow choroidal and retinal blood flow in myopic patients and is helpful in identifying and locating the site of choroidal neovascularization. Characteristic pattern of myopic CNV is an early hyperfluorescence, with little to moderate leakage in the late phases. In particular, myopic CNV shows a minimal or absent leakage not exceeding the border of the lesion in 77% to 96% of cases.²⁴⁻²⁶

Natural History of CNV

Previous reports about the natural history of myopic CNV have been conflicting, because this kind of lesion has been often reported to have a relatively self-limiting course in the short-term follow-up. Even though the short-term visual prognosis may be relatively good, long-term visual outcome is frequently poor. A recent survey showed that visual acuity does not significantly change during the first 3 years from CNV onset, but gets worse after 5 years.²⁷ Nevertheless, visual acuity at 5 years after the onset of CNV decreased to $\leq 20/200$ in 89% of the eyes and in 96% of the eyes after 10 years.²⁸ The long-term bad prognosis related to myopic CNV has been recently confirmed by another survey.²⁹

Treatment of CNV

Laser photocoagulation has been successfully applied in extrafoveal and juxtafoveal CNV.³⁰⁻³² A randomized controlled trial employing krypton red laser photocoagulation demonstrated that 40% in the treated group compared to 13% in the observed group had a visual acuity improvement of at least 2 lines.³² Rate of CNV recurrence was high, reaching the value of 31.4% of cases, especially during the first 12 months of follow-up. Another important concern regarding laser photocoagulation of CNV is the expansion of the atrophic scar, especially towards the myopic crescent, which happens in 92-100% of cases and can bring about a severe visual deterioration when involves the foveal centre.^{30,32,33} Laser photocoagulation is not indicated when CNV has subfoveal location, in order to avoid the damage of the foveal centre, and other therapeutic options including surgical approach and photodynamic therapy. Surgical interventions are comprised of surgical removal of CNV and macular translocation. Surgical removal of CNV has been reported to be able to improve visual acuity in a variable number of patients, but is burdened with a recurrence rate varying from 18% to 57%, with possible expansion of RPE atrophy.³⁵⁻³⁷ The rationale of macular translocation is to displace sensory retina originally lying over the subfoveal CNV onto a healthy RPE. Limited macular translocation has the advantage of less tissue manipulation, but has the disadvantage of less foveal displacement in comparison to macular translocation with 360° retinotomy. Overall, it seems that best long-term results may be achieved by means of macular translocation with 360° degree retinotomy.³⁶⁻³⁸ Macular translocation surgery may be associated with severe complications including retinal detachment, proliferative vitreoretinopathy, macular hole, and corneal astigmatism.

VIP trials have demonstrated that photodynamic therapy with verteporfin is effective in retaining quality of vision by stabilizing or improving visual acuity and contrast sensitivity.^{39,40} In particular, the median visual acuity was stable in the verteporfin-treated group, whereas patients in the placebo group lost almost 2 lines after the first year of follow-up. Such a benefit was maintained at 24 months when the median visual acuity of the treated and the placebo patients had changed from baseline by +0.2 lines and -1.6 respectively. Overall, vision turned out to be improved of at least 1 line from baseline at month 24 in 39% of verteporfin-treated patients compared with 13% of controls; an improvement of at least 3 lines was noted in 12% of treated patients as opposed to no placebo-given patient.

Photodynamic therapy with verteporfin has been found beneficial also for patients presenting recurrent CNV after thermal laser treatment.⁴¹

Typical aspects of photodynamic therapy for CNV in degenerative myopia are the absence of the hypofluorescent ring surrounding the CNV and the possible early bridging of multiple foci of CNV.⁴²

Anti-VEGF Treatment

The advent of anti-vascular endothelium growth factor (VEGF) treatment has completely changed the current management of degenerative myopia-related CNV. Many studies have clinically showed that anti-VEGF approach can halt the progression of the myopic CNV, promoting a variable visual acuity improvement.⁴³⁻⁶²

The rationale on the basis of anti-VEGF therapy is related to the histopathological evidence that myopic CNV can express VEGF and that VEGF aqueous level in eyes hosting myopic CNV can be reduced after intravitreal injection of bevacizumab⁶³⁻⁶⁴ Moreover, many practical experiences have been reported describing the positive effects of anti-VEGF approach for CNV related to DM on FA, optical coherence tomography (OCT), and clinical features. Overall, all the published clinical trials markedly differ regarding the characteristics of CNV included, the length of follow-up, the treatment regimen selected, the molecule injected. Moreover, most of the studies included subfoveal myopic CNV.

Therefore, many questions are still opened regarding the most appropriate management of CNV secondary to DM. In particular, very limited data are currently available regarding the long-term effects of anti-VEGF approach. Furthermore, there is no clear indication for the best anti-VEGF molecule, the best treatment regimen, and the best monitoring procedure over the follow-up. Lastly, limited data are available concerning the anti-VEGF treatment effects for non-subfoveal myopic CNV.

Long-term Effects of anti-VEGF therapy for subfoveal myopic CNV

In an attempt to assess the effects of intravitreal bevacizumab in the treatment of subfoveal myopic CNV in the long-term, we designed an open-label, prospective, clinical trial.⁶⁰ Thirty eyes with treatment-naïve subfoveal myopic CNV were included and followed-up. Best-corrected visual acuity (BCVA) on Early Treatment Diabetic Retinopathy Study (ETDRS) charts, fluorescein angiography (FA), and OCT were performed at baseline and, thereafter, monthly for 24 months.

Intravitreal bevacizumab was administered on an as-per-needed basis. Additional injections were administered in cases having any of the following: persistent dye leakage on FA, detection of any type of fluid on OCT, or presence of a new subretinal hemorrhage on biomicroscopic fundus examination.

Resolution or cessation of CNV activity on OCT was defined as the absence of SRF/IRF, whereas resolution or CNV closure on FA was defined as the absence of leakage.

Primary outcome measures included the change in mean BCVA and the proportion of eyes improving by three lines or greater.

Secondary outcome measures included the change in mean central macular thickness on OCT and the proportion of eyes with resolution of intraretinal/subretinal fluid on OCT and leakage on fluorescein angiography over the follow-up. A correlation between final BCVA and CNV duration was also calculated.

Mean BCVA improved from 54.8 ± 14.8 (ETDRS letters \pm SD) to 59.03 ± 17.0 at 3 months, subsequently stabilizing to 58.63 ± 18.52 at 12 months and 59.25 ± 20 at 24 months (Table 1). A statistically significant difference was detected only at the 1-month examination. BCVA at 24 months showed a 3-line improvement in 36.6% of cases and at least a 1-line increment in 43.3% of cases (Table 2). Mean central macular thickness (CMT) showed no significant reduction from baseline (216.8 ± 86 μ m) up to the end of 24 months (205 ± 77.8 μ m). At the last visit, a complete CNV closure was obtained in 93% of cases while intraretinal/subretinal fluid was detected on OCT in 13% of cases.

The mean number of intravitreal bevacizumab injections was 4.73 (range, 1–10) at the end of 12 months and 5.9 (range, 1–13) at the end of the 24 months. No negative side-effects were registered over the follow-up. In addition, regression analysis between the change in mean BCVA over 24 months and the duration of the disease before the treatment by anti-VEGF confirmed that the early treatment offers the greater chance of maintaining or improving the visual function.

This study with intravitreal bevacizumab as anti-VEGF molecule for naive subfoveal myopic CNV reveal positive results in the long-run, with visual improvement in about 1/3 of eyes and stabilization in about 2/3 of eyes.

Best Treatment Drug: Bevacizumab vs Ranibizumab

Only recently the first randomized comparative clinical trial evaluating the efficacy and safety of bevacizumab versus ranibizumab for the treatment of CNV secondary to DM has been published by Gharbyia et al.⁵⁵ At 6-month examination, endpoint of the study, no difference in the efficacy of ranibizumab versus bevacizumab could be demonstrated. Ranibizumab group and bevacizumab group achieved a comparable improvement in the BCVA of 3.4 and 3.0 lines, respectively, and both drugs were similarly effective in reducing the retinal thickness. These results are consistent with the existing data of recent studies on ranibizumab, which have 12 months of follow-up and show visual improvement from 1.5 to 3 lines, with about one quarter of subjects gaining at least 3 lines of BCVA.⁵¹⁻⁵⁴ Similarly, studies employing bevacizumab achieved a visual improvement between 1.9 and 3 lines, with 70% of subjects gaining more than 1 line.⁴³⁻⁵⁰

In an attempt to assess if any treatment effect is related to a specific anti-VEGF molecule, we designed a prospective randomized interventional study in order to compare intravitreal bevacizumab (IVB) and ranibizumab (IVR) in the treatment of subfoveal myopic CNV.

Forty-eight patients affected by subfoveal myopic CNV were randomized either to IVB or IVR. Re-treatments were performed on a pro-re-nata basis in monthly examinations over a 18-month follow-up. The primary outcome measures were the change in mean BCVA, and the proportion of eyes improving in BCVA by > 1 and > 3 lines at the 18-month examination. Twenty-five eyes underwent IVB, and 23 received IVR.

BCVA on ETDRS charts, FA, and OCT were performed at baseline and, thereafter, monthly for 18 months. All intravitreal injections were administered on an as-per-needed basis. After the first treatment, further re-treatment were performed when the following features were identified: persistent dye leakage on FA, detection of any type of fluid on OCT, or presence of a new subretinal hemorrhage on biomicroscopic fundus examination.

Resolution or cessation of CNV activity on OCT was defined as the absence of SRF/IRF, whereas resolution or CNV closure on FA was defined as the absence of leakage.

At baseline, the mean BCVA values were 0.59 ± 0.32 in the IVR and 0.61 ± 0.28 in the IVB groups (Table 3). At 1-month examination, BCVA showed a statistically significant improvement in both groups with a mean value of 0.42 ± 0.37 and 0.53 ± 0.27 , in the IVR and IVB groups respectively (Figure 2). A positive trend was subsequently preserved over the entire follow-up.

In comparison to the baseline, a statistically significant improvement in BCVA was observed at the 18-month examination, with a final mean BCVA of 0.40 ± 0.38 and 0.44 ± 0.32 in the IVR and IVB groups respectively. No statistically significant difference was observed between the IVR and IVB groups over the entire follow-up with respect to the BCVA. At the end of the 18-month follow-up, a significant improvement of 1.7 lines and 1.8 lines compared to baseline were noticed in IVR and IVB subgroups, respectively.

A 3-line gain or higher was noted in 30% of eyes in IVR subgroup and 44% of eyes in IVB subgroup with no statistically difference in the proportion between the two groups (Table 4).

With regard to CMT, the IVR group showed a statistically significant ($p=0.002$) reduction from 1-month examination on ($192 \pm 98 \mu\text{m}$) in comparison to the baseline value ($257 \pm 96 \mu\text{m}$). On the other hand, the IVB group achieved a statistically significant reduction ($p=0.005$) in mean CMT compared to the baseline value ($218 \pm 64 \mu\text{m}$) only at the 3-month examination ($183 \pm 69 \mu\text{m}$) (Figure 3).

Post-treatment FA and OCT analysis performed at 18-month examination revealed that in the IVR group a complete suspension of CNV activity was recognized in 100% of subjects. In the same specific time point, 4 eyes (16%) in the IVB group showed leakage on FA or SRF/IRF on OCT.

A significantly lower number of injections were administered in IVR subgroup (2.5 ± 1.6) compared to IVB subgroup (4.7 ± 2.2) ($p < 0.001$).

Thus, both IVR and IVB turned out to be effective in the therapy of subfoveal myopic CNV. Both molecules achieved similar visual outcomes, even though IVR showed a slightly greater efficacy in terms of the mean number of injections and CNV stabilization.

Effects of Treatment Regimen

The treatment regimen used in the management of myopic CNV includes two main protocols: the pro-re-nata regimen and the treatment with loading phase followed by monthly injections or by three consecutive injections. Overall, the PRN regimen is attractive because it attempt to block the CNV' growing by administering fewer injections and reducing in parallel the risk deriving from procedure, e.g. retinal break, infection or retinal detachment. In fact, the PRN regimen is the protocol mainly adopted in the current clinical practice. Although, no RCT has been carried out to compare the efficacy and safety of the two protocols, the functional and anatomical outcomes seems comparable. Recently, Ruiz-Moreno et al published two retrospective, non-randomized, multicentre studies on large case series comparing the two regimens over 1-year of follow-up and using intravitreal bevacizumab. A similar and statistically significant improvement in the BCVA and in the central foveal thickness were noted in both groups during the course of the study with no difference between the two groups.⁶⁵⁻⁶⁶

In an attempt to cast some light on this topic, we designed a prospective clinical trial comparing eyes receiving the loading phase vs eyes undergoing from the beginning PRN treatment.

30 patients referred for subfoveal CNV related to PM from July 2007 to January 2009 were prospectively enrolled in the study. At baseline each patient underwent a complete ophthalmological examination, including BCVA assessment on standard ETDRS LogMAR charts at 4m, slit lamp examination, tonometry, dilated fundus examination, FA and OCT examination. FA was performed using scanning laser ophthalmoscopy (HRA, Heidelberg, Germany) at the baseline, at 1 and 3-month examination and subsequently in a quarterly basis. Additional FA was performed whenever OCT was questionable. Re-treatments criteria included detection of any type of fluid on OCT, presence of new subretinal haemorrhage on biomicroscopy and/or presence of leakage on FA. At 1-month examination, eyes presenting signs of CNV activity received 2 monthly consecutive additional IVRI and completed the loading phase.

According to this re-treatment algorithm, the patients were categorized into two subgroups: eyes showing complete resolution of CNV activity at 1-month examination and receiving a single injection plus pro-re-nata regimen (PRN Group); eyes with active myopic CNV at 1 month and receiving a complete loading phase of three consecutive injections followed by a pro-re-nata regimen (LOAD+PRN Group).

Twenty-seven patients completed the planned visit over the 18-month of follow-up. Fifteen patients were included in the PRN Group and 12 were included in the LOAD+PRN (Table 5).

At the baseline, the mean BCVA values were 0.75 ± 0.28 (LogMAR+SD) and 0.73 ± 0.27 in the PRN Group and LOAD+PRN Group, respectively (Table 6). At 1-month examination, the BCVA showed a statistically significant improvement in both groups. Subsequently, the PRN Group showed a further improvement to 0.48 ± 0.28 at 3 months and thereafter a statistically significant BCVA gain was preserved up to the end of the study with a mean final value of 0.47 ± 0.29 . On the other hand, the LOAD+PRN Group failed to maintain the initial statistically significant improvement and a substantial stabilization was observed from the 3-month examination on with a mean final value of 0.63 ± 0.36 . No statistically significant difference was observed between the two groups over the whole follow-up with respect to the BCVA.

At the end of 18 months, 58% and 25% of eyes in the LOAD+PRN group and 86% and 73% of the PRN Group showed a BCVA improvement of >1 and >3 lines, respectively (Table 7). Five eyes (49%) and 1 eye loss >1 and >3 lines in the LOAD+PRN group, respectively. Only 1 eye in the PRN Group loss 1 single line. Considering the central macular thickness (CMT) and the greatest linear dimension (GLD), a meaningful anatomical improvement was noted at 1-month visit and in each scheduled examination in comparison to the baseline values in both groups (Table 8).

However, whereas the CMT values were comparable in both groups at the baseline and in all following visits, the two groups differed significantly in the GLD over the whole follow-up with the greater values registered in the LOAD+PRN group (Table 9).

The mean number of injections administered at the end of follow-up were 1.3 ± 0.5 and 4.4 ± 1 in the PRN Group and in the LOAD+PRN Group, respectively. Five patients (33%) in the PRN Group received 1 additional injection during the first six months of follow-up. Over the following 12 months no patient required additional injection. In the LOAD+PRN Group, 10 patients (83%) required additional injections over the following months with 5, 3 and 2 eyes requiring 1, 2 and 3 additional injections, respectively. Only by the fifteenth month, no eyes required additional doses. No significant ocular or systemic adverse effects were registered over the course of the follow-up in both groups.

Post-treatment analysis at 18-month examination evidenced that the two groups presented a baseline statistically significant differences with regard to mean age, GLD of the CNV, time interval from symptoms onset.

All baseline data including time interval between symptoms onset and diagnosis, baseline BCVA, CMT, GLD and age were combined in a multiple stepwise regression analysis in order to evaluate the predictor variables on the final BCVA values.

The parameters age (p: 0.01) and baseline BCVA (p: 0.001) were identified as the explanatory variable. Specifically, older patients with lower baseline BCVA showed the lower chance of obtaining a visual acuity recovery.

The question of the optimal dose and treatment regimen in myopic CNV management is not completely resolved. There is no unequivocal evidence suggesting PRN treatment is more effective than a loading phase followed by an as-needed variable dosage regimen.

In the current study, the two dosing treatment regimens achieved a similar effect in BCVA improvement. According to our protocol and considering that in a high percentage of cases 1 or 2 injections are sufficient for stabilizing the neovascular lesion, the loading phase may be reserved to CNV with high activity and showing persistent leakage on FA or OCT subsequently to the first injection.

Effects of myopic CNV location

As previously stated, in studies with at least 1 year follow-up a significant improvement in the visual acuity may be encountered in eyes with subfoveal myopic CNV receiving intravitreal bevacizumab or ranibizumab.

There are only few investigations regarding the effect of therapy with anti-VEGF in CNV with extrafoveal and juxtafoveal location. Ikuno et al recorded a positive outcome of intravitreal bevacizumab in a prospective study on a large series of patients with myopic CNV including eyes with subfoveal (43%), juxtafoveal (49%) and extrafoveal (8%) CNV.⁴⁷ However, the authors did not specify the visual acuity values associated with the 5 extrafoveal CNV cases and the 31 juxtafoveal CNV cases. Most of the other surveys considered in the population study subfoveal and juxtafoveal CNV and did not provide a subgroup analysis. Thus, limited data are available in the current literature about the effect of anti-VEGF treatment for non-subfoveal CNV.

We have analyzed the effects of the intravitreal therapy for juxtafoveal and extrafoveal myopic CNV in two different investigations, obtaining interesting results.

Juxtafoveal myopic CNV

The effects of anti-VEGF treatment for juxtafoveal myopic CNV was determined by means of a prospective randomized clinical investigation, comparing the visual acuity outcomes of laser treatment (LT), photodynamic therapy (PDT) with verteporfin, and intravitreal bevacizumab (IVB) in patients with juxtafoveal choroidal neovascularization secondary to DM.

Fifty-four patients were randomized to PDT, LT, or IVB injection (Table 10). IVB subgroup received 1.25 mg of IVB at baseline, and re-treatments were performed if persistent intraretinal or subretinal fluid evaluated on OCT, or if CNV leakage was detected on FA. PDT subgroup received treatment following the Verteporfin in Photodynamic Therapy Study Group guidelines. LT subgroup was submitted to direct LT and received PDT treatment if subfoveal CNV recurrence or progression was detected on fluorescein angiography.

Primary outcome measure was considered the change in BCVA at the end of the 2-year follow-up; secondary outcomes was proportion of eyes developing a foveal involvement.

The mean BCVA decreased in the PDT subgroup from 0.52 ± 0.24 (LogMAR) at baseline to 0.72 ± 0.25 at the end of the study ($P=.002$) (Table 11).

LT subgroup showed substantial stabilization from mean baseline BCVA (0.45 ± 0.27) to the 24-month (0.56 ± 0.34) examination values.

BCVA in IVB subgroup increased from 0.6 ± 0.3 at baseline to 0.42 ± 0.35 at the end of the study ($P=0.006$). No side-effects were registered over the follow-up.

Aggiungere proporzione (Table 12)

During the first year of follow-up CNV recurrence with subfoveal extension were registered in 9 eyes (53%) in the LT group, which were re-treated using PDT in accordance with the study protocol; a foveal extension developed in 13 eyes (72%) of the PDT group. In the bevacizumab group 4 patients revealed a CNV foveal extension. Overall, 80% of subfoveal CNV recurrence occurred during the first 6 months of follow-up and no subfoveal CNV recurrence were detected in the second year.

In essence, over a course of two years follow-up, a significant improvement in BCVA was demonstrated in eyes receiving the bevacizumab treatment whereas the PDT group showed a progressive visual acuity worsening and the laser group obtained a substantial stabilization. In addition, the IVB lowered the risk of secondary foveal involvement in comparison to laser treatment or PDT.

Extrafoveal myopic CNV

The effects of anti-VEGF therapy for extrafoveal PM-related CNV were analysed through an open label, interventional, prospective trial. Fifteen patients affected by extrafoveal myopic CNV were treated with IVB injections and followed up 24 months.

Best-corrected visual acuity (BCVA) assessment on Early Treatment Diabetic Retinopathy Study (ETDRS) charts, FA, and OCT were performed at baseline and, thereafter, monthly for 24 months.

Intravitreal bevacizumab was administered on an as-per-needed basis. After the initial treatment, additional injections were administered in cases having any of the following: persistent dye leakage on FA, detection of any type of fluid on OCT, or presence of a new subretinal hemorrhage on biomicroscopic fundus examination.

Primary outcome measure were the mean change in BCVA and the proportion of eyes gaining at least 3 lines of ETDRS charts at the end of the planned follow-up of 24 months. Secondary outcomes included the effect of the IVB on central macular thickness (CMT), size of the CNV, and extension to the fovea.

The mean BCVA changed from 0.47 (logMAR) at baseline to 0.36 ($p=0.035$) at 1-month examination, and to 0.26 and 0.22 at 12- and 24-month examination, respectively ($p < 0.001$).

A functional improvement of at least 3 ETDRS lines was achieved by 7 eyes (46.6%) at the 24-month examination; one eye (6%) showed a BCVA deterioration of 1 line, whereas an improvement of 1-2 lines was registered in 7 eyes (46.6%).

The mean CMT improved from 313 ± 44 μm to 266 ± 61 μm at 1-month examination ($p=0.027$), to 263 ± 69 μm at the 12-month examination ($p=0.030$), and to 254 ± 63 μm at the 24-month examination ($p=0.008$).

Similarly, mean CNV size decreased from 348 ± 117 μm^2 at baseline and to 257 ± 114 μm^2 after 1 month ($p=0.047$), to 259 ± 109 μm^2 after 12 months ($p=0.048$), and to 251 ± 104 μm^2 after 24 months ($p>0.029$).

Finally, IVB prevented a foveal CNV extension in all cases and a mean number of 3 and 3.4 IVB injections were administered during the first year and the 2 years of follow-up, respectively.

In essence, also in eyes with juxtafoveal and extrafoveal CNV secondary to DM, a treatment based on intravitreal bevacizumab administration seems lead to a beneficial effect on the visual acuity over a 2 years of follow-up avoiding in the most part of patients a secondary foveal involvement.

Monitoring procedure: Fluorescein angiography and OCT

In the management of CNV secondary to AMD, the PrONTO study demonstrated that a scheduled treatment regimen consisting of a loading phase followed by a monthly treatment administered on the basis of specific re-treatment criteria resulted in a functional and anatomical improvement and was associated with a lower number of injections compared to a monthly fixed regimen. Re-treatment criteria included a loss of five letters or more on a standardized visual acuity chart with evidence of any subretinal fluid on OCT, an increase in central retinal thickness of 100 μm or more on OCT, any evidence of new hemorrhage; new classic CNV, or detection of fluid on OCT persisting 1 month after an injection.⁶⁸⁻⁶⁹

The analysis of the literature shows that in the clinical practice for the management of anti-VEGF therapy in myopic CNV, most of authors employs as a elective re-treatment criteria the presence of intra/subretinal fluid on OCT examination or the evidence of leakage from CNV on fluorescein angiography, without considering the coexisting of a visual acuity loss. Few authors include among the re-treatment criteria the loss of visual acuity in absence of a concomitant accumulation of fluid on OCT or leakage on FA. Even more rarely, the re-treatment criteria includes the simultaneous presence of a visual acuity loss and signs of CNV activity.⁴⁴⁻⁶⁶

These heterogeneous and different approaches probably reflects the lack of information from multi-center clinical trials able to elucidate and define the treatment guidelines.

The approach based only on CNV findings lead us to consider an important issue related to monthly re-evaluation of CNV activity for deciding the re-treatment.

Retinal FA is the standard examination for the evaluation of CNV associated to DM. Despite the important information provided, FA is burdened by some relatively minor side-effects, including nausea, allergic reaction and fever and other more serious ones, such as anaphylactic shock. In addition, FA is unattractive because it is unpleasant for the patient, expensive and is more time-consuming for doctors and assistants.

For all these reasons, OCT could play a useful role as an imaging technique in view of its non-invasive nature and more rapid operation. Furthermore, OCT provides ultrastructural morphological details not attainable through FA examination.

However, myopic CNV is not associated with marked signs of exudation, intraretinal oedema, neurosensory detachment or retinal pigment epithelium detachment and this could limit the role of OCT assessment.²¹

So, while in the management of CNV related to AMD, the OCT examination has shown its value in monitoring the activity of the lesion and guiding the re-treatment with anti-VEGF⁶⁸⁻⁶⁹, a similar approach has not yet been validated for monitoring CNV activity associated with DM.

In the absence of clear guidelines on the role of OCT examination, we designed a study to evaluate the agreement between FA and spectral domain OCT in detecting the activity of myopic subfoveal CNV during treatment with intravitreal bevacizumab injection.

Thirty-four patients with subfoveal myopic CNV eligible to receive IVB injection were prospectively enrolled in the study and underwent a complete ophthalmological examination, including FA and spectral domain-OCT at baseline and at all planned monthly visits. After the first IVB injection, additional re-treatments were performed following detection of fluid on SD-OCT and/or presence of leakage on FA. FA and OCT were performed on the same day by two experienced, independent examiners masked to the purpose of the study. After carefully examination of OCT and FA images, the examiner recorded the signs of CNV activity and the inter-rater agreement kappa analysis was performed to examine the concordance between FA and SD-OCT evaluation. Sensitivity and specificity were also calculated.

At the baseline, the FA and SD-OCT were in agreement in 26/34 cases with a K value of 0.23; sensitivity and specificity were respectively 77.4 and 66.7. Of the remaining eight cases, 7 eyes presented leakage on FA and absence of fluid on SD-OCT examination, while 1 case showed intraretinal fluid on SD-OCT and absence of leakage on FA. At the 1-month examination, specificity and K value improved and a concordance was reached in 30/34 cases. At the 3 and 4-month examination a discordance was noted in six cases. From the 5-month examination on, a correspondence was achieved in at least 30/34 cases and reached a perfect match in nine sessions.

As already stated in previous studies, FA and OCT showed a weak correlation in the diagnostic phase, while FA remained the most appropriate examination in order to detect the CNV activity. OCT achieved a meaningful agreement with FA during the follow-up phase when CNV activity showed a progressive reduction secondary to IVB treatment suggesting that the OCT may play a role in monitoring the CNV activity and the re-treatment-related decisions.

Although an improvement in the agreement between the two methods was observed, we cannot assert that this translates into greater reliability OCT examination as indicator of CNV activity.

It is well known that the myopic CNV is not always associated with intra-or subretinal exudation and in confirmation of this feature in the our study the OCT examination did not reveal the presence of the retinal fluid in each comparison.

The best agreement between the two techniques therefore results only from a greater number of inactive cases recognize on FA.

Considering the morphological features of CNV associated with DM, we recommend caution in relying entirely on OCT examination for the assessment of the activity of the neovascular lesion.

Conclusion

There is a mounting evidence that the anti-VEGF therapy has assumed a role as first therapeutic indication and has modified our approach to the management of therapy for CNV secondary to DM. However, the evidence do not derive from multicenter randomized clinical trials but has been realized by the efforts of the clinicians in an attempt to modify the natural course of this serious complication occurring in the almost 10% of patients affected by PM.

The final impact of the anti-VEGF therapy on the natural history of myopic CNV is not yet well understood. Although the large part of studies reports promising results, it is not yet possible to draw definitive recommendations on the most efficacious treatment regimen and protocol, on the most appropriate re-treatment criteria and on the most effective drug. In addition, it is unknow whether the retinal changes induced by treatment, for example, the perilesional chorioretinal atrophy expansion or the formation of marginal cracks can influence negatively the visual function. Since it is difficult to imagine the development of a large randomized controlled clinical trial, only the combination of information derived from each single study may help us to understand how to manage the anti-VEGF treatment in myopic CNV.

TABLES

Table 1 Combined Data of the BCVA and CMT Over the Course of Follow-up						
Characteristic	Baseline	1 Month	3 Months	6 Months	12 Months	24 Months
BCVA in letters (mean \pm SD)	54.8 \pm 14.8	58.5 \pm 14.6	59.03 \pm 17	58.0 \pm 15.8	58.6 \pm 18.5	59.2 \pm 20
P	—	0.0089	0.07	0.23	0.15	0.11
CMT in mm (mean \pm SD)	216.8 \pm 86	214.5 \pm 83	197 \pm 89	190 \pm 75	209 \pm 78	205 \pm 77
P	—	0.79	0.07	0.07	0.71	0.57

A statistically significant improvement in BCVA was registered at the 1-month examination. From the 3-month examination on, a stabilization of the mean BCVA values was observed in comparison with the baseline value. The mean CMT showed no statistically significant reduction from the baseline value up to the end of 24 months

Table 2 Frequency Distribution of Changes in Visual Acuity from Baseline to 24-Month Examination	
Change in Visual Acuity	Number of patients (%)
≥ 3 lines increase	11 (36)
≥ 1 line to , < 3 lines increase	4 (13)
Change between > 1 and < 1 line	5 (16)
≥ 1 line to , < 3 lines decrease	8 (26)
≥ 3 lines decrease	2 (6.6)

By the 24-month examination, one third of patients gained at least 3 lines of BCVA, and another one third stabilized their initial BCVA.

Table 3
Baseline characteristics

Baseline characteristics	Ranibizumab Group (n=23)	Bevacizumab Group (n=25)	p value
AGE (mean years \pm SD)	65 \pm 13	61 \pm 12	>0.05*
SEX (Female:Male)	18:5	20:5	>0.05 ⁺
BCVA (mean logMAR \pm SD)	0.61 \pm 0.28	0.59 \pm 0.32	>0.05*
CNV AREA (mean mm ³ \pm SD)	1.527 \pm 1.190	1.778 \pm 1.167	>0.05*
CMT (mean μ m \pm SD)	257 \pm 96	218 \pm 64	>0.05*

BCVA: best-corrected visual acuity, CMT: central macular thickness, *: unpaired t test, ⁺: Fisher's exact test

Table 4
Frequency distribution of change in best-corrected visual acuity (BCVA) over 18 months follow-up.

BCVA (LogMAR)	Ranibizumab Group (n = 23)	Bevacizumab Group (n = 25)
\geq 3 lines increase	7	11
\geq 1 line to < 3 lines increase	8	3
Change between > 1 and < 1 line	4	5
\geq 1 line to < 3 lines decrease	3	6
\geq 3 lines decrease	1	0

At the 18-month examination, 30% of the IVR eyes and 44% of the IVB eyes showed a BCVA gain of at least 3 lines. Overall, 65% of the IVR eyes and 56% of the IVB eyes gained at least 1 line. The latter difference of 11% between the two groups was not statistically significant. In addition, no statistically significant difference was noted between the two groups when proportions of eyes losing at least 1 or 3 lines were considered

Table 5 Baseline characteristic of patients.			
Baseline characteristics	PRN Group	Loading Phase Group	P value
Number of patients	15	12	n.s.
Mean age	57±9.8	Mean: 68.3±8	0.005
Gender	10 F / 5 M	9 F / 3 M	0.07
Mean BCVA (logMAR)	0.75±0.28	0.73±0.27	0.85
Mean CMT (µm)	337±73	371±111	0.35
Mean GLD (µm)	1126±387	1784±904	0.017
Time interval from symptoms onset and diagnosis (days)	8.6±4.4	25.8±11	0.0001
A statistically significant difference between the two groups was observed with regard to age, GLD of CNV, time interval from symptoms onset and diagnosis (days). [BCVA: best-corrected visual acuity, CMT: central macular thickness, GLD: greatest linear dimension]			

Table 6						
Mean changes in the best-corrected visual acuity (BCVA) over the course of follow-up.						
LogMAR BCVA (mean \pm SD)	Baseline	1 month	3 months	6 months	12 months	18 months
PRN Group	0.75 \pm 0.28	0.54 \pm 0.27	0.48 \pm 0.28	0.48 \pm 0.28	0.47 \pm 0.29	0.47 \pm 0.29
p value		0.0003	0.0001	0.0001	0.0001	0.0001
Loading Phase Group	0.73 \pm 0.27	0.61 \pm 0.32	0.60 \pm 0.37	0.60 \pm 0.36	0.61 \pm 0.36	0.62 \pm 0.36
p value		0.002	0.06	0.07	0.14	0.14
PRN Group vs Loading Phase Group (p value)	0.85	0.54	0.32	0.35	0.26	0.26
<p>A statistically significant improvement in mean BCVA was noted in both groups at 1-month. Subsequently, PRN Group preserved a statistically significant increase in the BCVA whereas Loading Phase Group showed a substantial stabilization in comparison to the baseline value. No statistically significant difference was observed between the two groups over the whole follow-up.</p>						

Change in Visual Acuity	LOAD+PRN Group	PRN Group
≥ 3 lines increase	3	11
≥ 1 line increase	7	13
No change	0	1
≥ 1 line decrease	5	1
≥ 3 lines decrease	1	0

CMT (mean ± SD)	Baseline	1 month	3 months	6 months	12 months	18 months
PRN Group	337 ± 73	262 ± 85	252 ± 80	241 ± 74	228 ± 56	217 ± 46
p value		0.005	0.001	0.0005	0.0001	0.0001
LOAD+PRN Group	371 ± 111	294 ± 103	265 ± 85	282 ± 92	276 ± 100	269 ± 91
p value		0.009	0.001	0.001	0.001	0.001
PRN vs LOAD+PRN Group (p value)	0.35	0.37	0.68	0.21	0.13	0.06

A statistically significant improvement in the mean CMT was registered from 1-month examination up to the end of 18 months in both groups. No statistically significant difference was observed between the two groups during the whole follow-up.

Table 9						
Mean changes in the greatest linear dimension (GLD) over the course of follow-up.						
GLD (mean±SD)	Baseline	1 month	3 months	6 months	12 months	18 months
PRN Group	1126 ± 387	993± 368	917 ± 337	878 ± 373	837 ± 368	809 ± 334
p value		0.001	0.001	0.0008	0.0002	0.0001
LOAD+PRN Group	1784 ± 904	1670 ± 843	1644 ± 843	1602 ± 823	1559 ± 814	1529 ± 808
p value		0.007	0.006	0.005	0.005	0.002
PRN vs LOAD+PRN Group (p value)	0.017	0.009	0.009	0.005	0.005	0.004
A statistically significant improvement in the mean GLD was registered from 1-month examination up to the end of 18 months in both groups. A statistically significant difference was observed between the two groups during the whole follow-up with the smaller values observed in the PRN Group.						

Table 10 Demographic Characteristics of the Patients Randomized to Laser Treatment, PDT, and Bevacizumab			
Characteristic	Laser Treatment (17 Eyes)	PDT (18 Eyes)	Bevacizumab (19 Eyes)
Women, No. (%)	13 (76)	13 (72)	11 (57)
Mean age, years	44.5	48.1	50.8
Refractive error, mean, D	-10.2	-9.2	-9.6
Hypertension, No. (%)	2 (11)	2 (11)	1 (5)
Baseline BCVA, mean (SD), logMAR (a)	0.45 (0.27)	0.52 (0.24)	0.61 (0.3)
BCVA, best-corrected visual acuity; D, diopters; PDT, photodynamic therapy.			
(a) Best-corrected visual acuity showed no statistically significant difference among the 3 groups at baseline.			

Table 11					
Change in BCVA During the 24 Months of Follow-up (a)					
Examination, mo	BCVA, logMAR			P Value	
	PDT	LT	Bevacizumab	LT vs PDT	Bevacizumab vs PDT
Baseline	0.52	0.45	0.6		
3	0.51	0.46	0.4b		
6	0.49	0.41	0.4b		
9	0.67c	0.39	0.4b	<.05	<.05
12	0.67cd	0.47e	0.4b,f	<.05	<.05
18	0.68c	0.49	0.42b	NS	<.05
24	0.72c,d	0.56e	0.42b,f	NS	<.05
Abbreviations: BCVA, best-corrected visual acuity; NS, non significant; PDT, photodynamic therapy.					
(a) At baseline, no statistically significant difference was registered among the subgroups. From the 3-month examination, a statistically significant improvement of BCVA was recorded in the bevacizumab group. At the 1-year follow-up, the PDT group showed a worsening in BCVA, the laser treatment group maintained the baseline mean BCVA, whereas only the bevacizumab group showed a statistically significant BCVA improvement. At the 24-month examination, a worsening in BCVA was registered both in the PDT group (reaching statistically significant difference) and in the laser treatment group (without statistically significant difference), whereas the bevacizumab group retained its visual improvement.					
(b) Statistically significant improvement in BCVA from baseline in the bevacizumab group from the 3-month examination on.					
(c) Statistically significant worsening in BCVA from baseline in the PDT group from the 9-month examination on.					
(d) Statistically significant (P.05) difference compared with baseline (for worsening).					
(e) Statistically non significant difference compared with baseline.					
(f) Statistically significant (P.05) difference compared with baseline (for improvement).					

Table 12 Frequency of Mean Changes in Best-Corrected Visual Acuity From Baseline to the 24-Month Examination (a)					
Group	Lines of Gain or Loss, No. (%) of Eyes				
	<-3	<-1	0	>1	>3
Photodynamic therapy	8 (44)	13 (72)	1 (5.5)	4 (22)	1 (5.5)
Laser treatment	7 (41)	10 (59)	1 (6)	6 (35)	2 (12)
Intravitreal bevacizumab	1 (5)	4 (21)	2 (11)	13 (68)	7 (36)

(a) Stabilization or improvement of best-corrected visual acuity was registered in 27.5%, 41%, and 79% of the photodynamic therapy, laser treatment, and bevacizumab groups, respectively

Month	Sensitivity	Specificity	Kappa value	Number of cases showing complete agreement	Proportion of eyes showing complete agreement (%)	OCT+/FAG-	FAG+/OCT-
Baseline	77.4	66.7	0.23	26	76	1	7
1 M	73.3	100	0.75	30	88	0	4
2 M	69.2	100	0.73	30	88	0	4
3 M	61.5	95.2	0,60	28	82	1	5
4 M	62.5	88.4	0,51	28	82	3	3
5 M	80	100	0,87	33	97	0	1
6 M	78.5	100	0.81	31	91	0	3
7 M	87.5	100	0,91	33	97	0	1
8 M	85.7	92.5	0,74	31	91	2	1
9 M	77.8	96	0,76	31	91	1	2
10 M	66.6	100	0,78	33	97	0	1
11 M	66.6	100	0,78	33	97	0	1
12 M	71.4	96.3	0.71	31	91	1	2
13 M	100	100	1	34	100	0	0
14 M	100	100	1	34	100	0	0
15 M	100	100	1	34	100	0	0
16 M	100	100	1	34	100	0	0
17 M	100	100	1	34	100	0	0
18 M	100	96	0.92	33	97	1	0
19 M	100	100	1	34	100	0	0
20 M	100	100	1	34	100	0	0
21 M	100	100	1	34	100	0	0
22 M	100	100	1	34	100	0	0
23 M	100	87	0.54	30	88	4	0
24 M	100	94.1	0.63	32	94	2	0

FIGURES

Figure 1. Correlation between change in mean BCVA over 24 months and symptom duration before treatment with IVB. Overall, an early treatment seems to increase the probability of obtaining better stabilization or improvement in visual function.

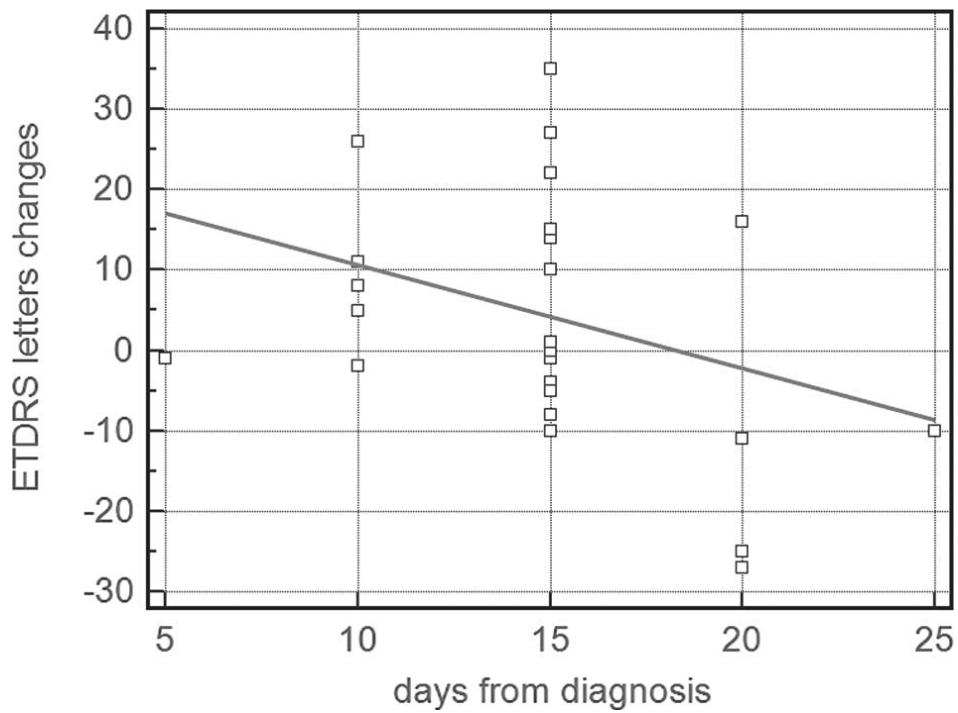


Figure 2: a statistically significant improvement in BCVA was noted in both groups at the 1-month examination. A positive trend was subsequently preserved over the follow-up. At the 18-month examination a mean improvement of 1.8 lines in the ranibizumab group and 1.7 lines in the bevacizumab group was registered

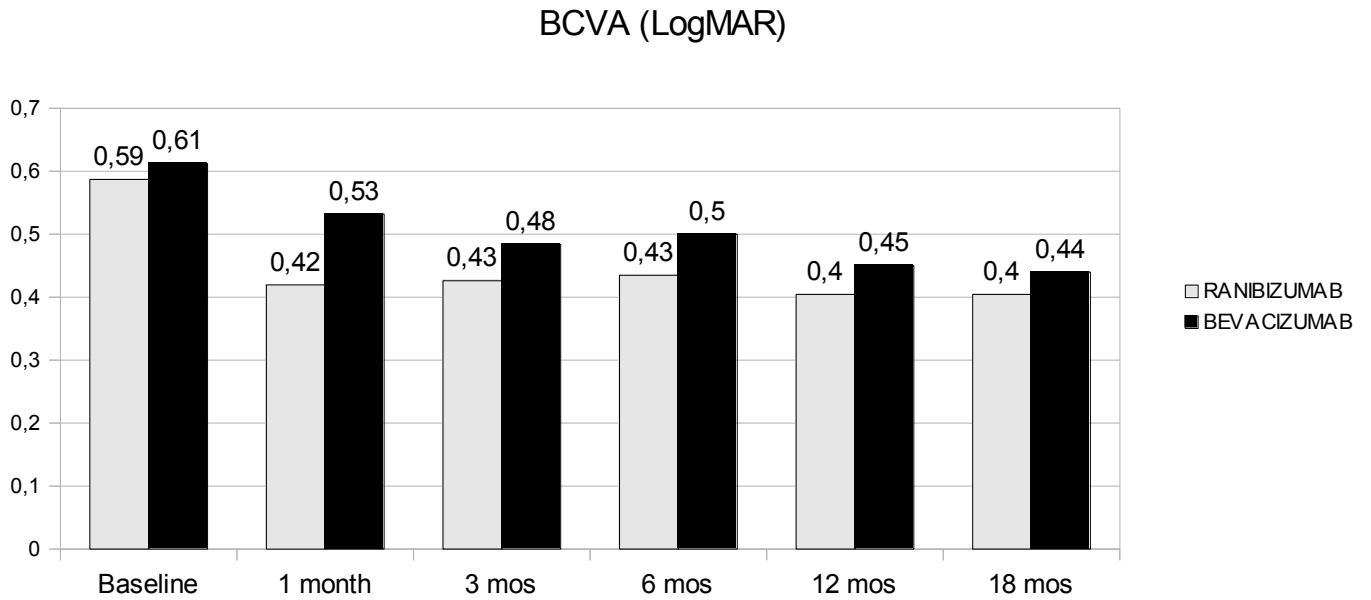
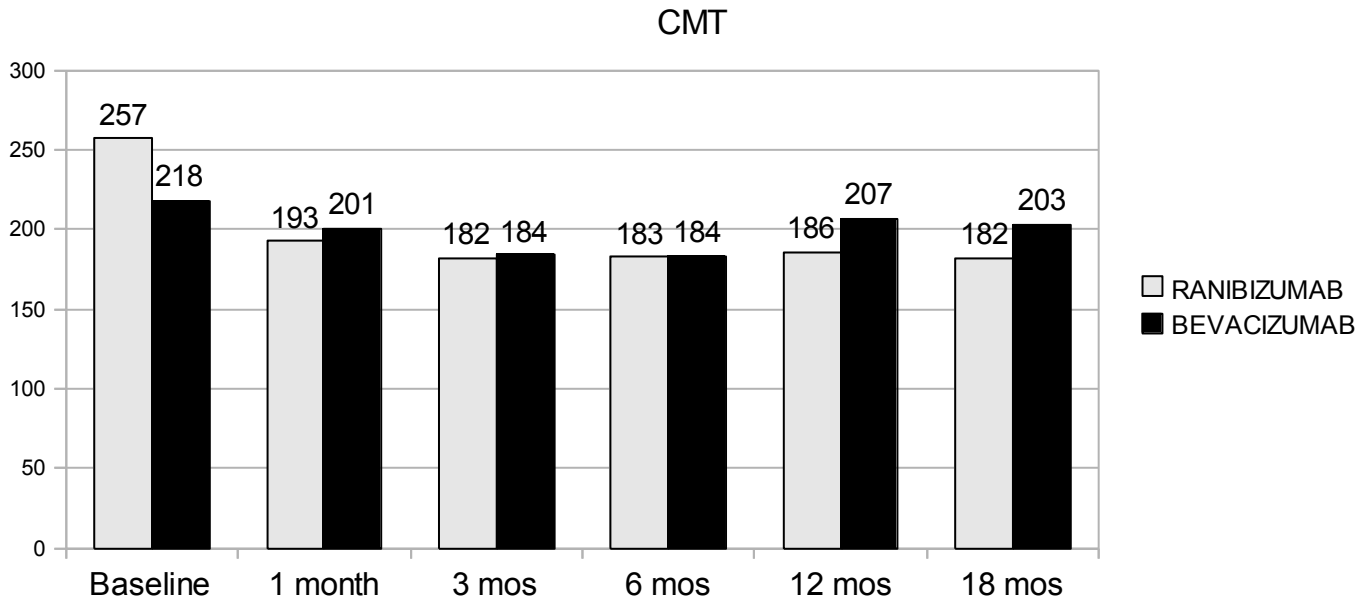


Figure 3: A statistically significant difference in comparison to the mean baseline CMT was registered from the 1-month examination in the Ranibizumab group. A statistically significant difference was also observed at the 3- and 6-month visits in the Bevacizumab group; at 12 and 18 months, the CMT was shown to have stabilized in comparison with the baseline value.



REFERENCES

1. Ghafour IM, Allan D, Foulds WS. Common causes of blindness and visual handicap in the west of Scotland. *Br J Ophthalmol*.1983;67:209-213.
2. Sperduto RD, Seigel D, Roberts J, Rowland M. Prevalence of myopia in the United States. *Arch Ophthalmol* 1983;101:405-407.
3. Sorsby A, Sheridan M, Leary GA, Benjamin B. Vision, visual acuity and ocular refraction of young men. *Br J Ophthalmol* 1960;1:1394-1398.
4. Lee KE, Klein BEK, Klein R. Changes in refractive error over a 5-year interval in the Beaver Dam Eye Study. *Invest Ophthalmol Vis Sci*. 1999;40:1645-1649.
5. Curtin BJ. The etiology of myopia. In: *The Myopias: Basic Science and Clinical Management*. Philadelphia. Harper and Row. 1985,61-113.
6. Curtin BJ. Pathology. In: *The Myopias: Basic Science and Clinical Management*. Philadelphia. Harper and Row. 1985,247-267.
7. Raab MF, Garoon I LaFranco FP. Myopic macular degeneration. *Int Ophthalmol Clin* 1981;21:51-59.
8. Ghafour IM, Allan D, Foulds WS. Common causes of blindness and visual handicap in the west of Scotland. *Br J Ophthalmol* 1983;67:209-213.
9. Tokoro T. *Atlas of posterior fundus changes in pathologic myopia*. New York. Springer Verlag. 1998;1-2.
10. Curtin BJ. The nature of pathologic myopia. In: *The Myopias: Basic Science and Clinical Management*. Philadelphia. Harper and Row. 1985,237-245.
11. Lam CS, Goldschmidt E, Edwards MH. Prevalence of myopia in local and international schools in Hong Kong. *Optom Vis Sci* 2004;81:317-322.
12. Tokoro K. On the definition of pathologic myopia in group studies. *Acta Ophthalmol* 1988;66:107-108.
13. <http://omim.org/entry/160700>
14. Pruett RC. Progressive myopia and intraocular pressure: What is the linkage? *Acta Ophthalmol* 1988;suppl 185:117-127.
15. Quinn GE, Berlin JA, Young TL, et al. Association of intraocular pressure and myopia in children. *Ophthalmology* 1995;102:180-185.
16. Kennedy RH. Progression of myopia. *Trans Am Ophthalmol Soc*. 1995;93.755-800.
17. Curtin BJ, Teng CC. Scleral changes in pathological myopia. *Trans Am Acad Ophthalmol Otolaryngol* 1957;62:777-790.

18. Komai Y, Ushiki T. The three-dimensional organization of collagen fibrils in the human cornea and sclera. *Invest Ophthalmol Vis Sci* 1991;32:2244-2258.
19. Curtin BJ. Myopia: A review of its etiology, pathogenesis and treatment. *Surv Ophthalmol* 1970;15:1-17.
20. Curtin BJ, Karlin DB. Axial length measurements and fundus changes of the myopic eye. *Am J Ophthalmol* 1971; 71: 42–53.
21. Grossniklaus HE, Green WR. Pathologic findings in pathologic myopia. *Retina* 1992; 12: 127–133.
22. Ohno-Matsui K, Yoshida T, Futagami S, Yasuzumi K, Shimada N, Kojima A *et al.* Patchy atrophy and lacquer cracks predispose to the development of choroidal neovascularisation in pathological myopia. *Br J Ophthalmol* 2003; 87: 570–573
23. Hampton GR, Kohen D, Bird AC. Visual prognosis of disciform degeneration in myopia. *Ophthalmology* 1983;90:923-926.
24. Gass JDM. Biomicroscopic and histopathologic consideration regarding the feasibility of surgical excision of subfoveal neovascular membranes. *Am J Ophthalmol* 1994;118:285-294.
25. Gass JDM. *Stereoscopic Atlas of Macular Diseases: diagnosis and treatment.* Mosby-Year Book Inc. St Louis. 1997:126-129.
26. Avila MP, Weiter JJ, Jalkh AE *et al.* Natural history of choroidal neovascularization in degenerative myopia. *Ophthalmology* 91, 1573-1581 (1984).
27. Yoshida T, Ohno-Matsui K, Ohtake Y, *et al.* Long-term visual prognosis of choroidal neovascularization in high myopia. *Ophthalmology* 2002;109:712-719.
28. Yoshida T, Ohno-Matsui K, Yasuzumi K, *et al.* Myopic choroidal neovascularization. A 10 year follow-up. *Ophthalmology* 2003;110:1297-1305.
29. Hayashi K, Ohno-Matsui K, Shimada N, Moriyama M, Kojima A, Hayashi W, Yasuzumi K, Nagaoka N, Saka N, Yoshida T, Tokoro T, Mochizuki M. Long-term pattern of progression of myopic maculopathy: a natural history study. *Ophthalmology*. 2010 Aug;117(8):1595-611, 1611.e1-4.
30. Jalkh AE, Weiter JJ, Trempe CL, *et al.* Choroidal neovascularization in degenerative myopia: Role of laser photocoagulation. *Ophthalmic Surg* 1987;18:721-725.
31. Deutman AF, Hendrikse F. Traitment des neovaisseaux sous-retiniens dans la myopie degenerative. *Ophtalmologie* 1989;3:299-301.
32. Soubrane G, Pison J, Bornert P, *et al.* Neovaisseaux sous-retiniens de la myopie degenerative: Resultats de la photocoagulation. *Bull Soc Ophtalmol Fr* 1986;86:269-272.

33. Brancato R, Pece A, Avanza P, Raddizzani E. Photocoagulation scar expansion after laser therapy for choroidal neovascularization in degenerative myopia. *Retina* 1990;10:239-243.
34. Uemura A, Thomas MA. Subretinal surgery for choroidal neovascularization in patients with high myopia. *Arch Ophthalmol* 2000;118:344-350.
35. Hamelin N, Glacet-Bernard A, Brindeau C, et al. Surgical treatment of subfoveal neovascularization in myopia: Macular translocation versus surgical removal. *Am J Ophthalmol* 2002;133:530-536.
36. Riuiz-Moreno JM, de la Vega C. Surgical removal of subfoveal choroidal neovascularization in highly myopic patients. *Br J Ophthalmol* 2001;85:1041-1043.
37. Ohji M, Fujikado T, Hosoata J, et al. Foveal translocation: A comparison of two techniques. *Sem Ophthalmol* 1998;13:52-61.
38. Fujikado T, Ohji M, Hosoata J, et al. Comparison of visual function after foveal translocation with 360 degree retinotomy and with scleral shortening in a patient with bilateral myopic neovascular maculopathy. *Am J Ophthalmol* 2000;130:525-527.
39. Verteporfin in Photodynamic Therapy (VIP) Study Group. Photodynamic therapy of subfoveal choroidal neovascularization in pathologic myopia with verteporfin. 1-year results of a randomized clinical trial-VIP report No. 1. *Ophthalmology* 2001; 108:841-852.
40. Verteporfin Therapy in subfoveal choroidal neovascularization in pathologic myopia. 2-year results of a randomised clinical trial –VIP report No. 3. *Ophthalmology* 2003;110:667-673.
41. Bandello F, Lanzetta P, Battaglia Parodi M, Roman-Pognuz D, Saviano S, Ravalico G. Photodynamic therapy of subfoveal recurrences after laser photocoagulation of extrafoveal choroidal neovascularization in pathologic myopia. *Graefes Arch Clin Exp Ophthalmol*. 2003;241:567-70.
42. Lanzetta P, Parodi MB, Ambesi-Impiombato M, Ravalico G, Bandello F. Early neovascular bridging after photodynamic therapy of myopic choroidal neovascularization. *Graefes Arch Clin Exp Ophthalmol*. 2004;242:840-4.
43. Sakaguchi H, Ikuno Y, Gomi F et al. Intravitreal injection of bevacizumab for choroidal neovascularization associated with pathological myopia. *Br J Ophthalmol* 2007; 91:161-165.
44. Ruiz-Moreno JM, Montero JA, Gomez-Ulla F, Ares S. Intravitreal bevacizumab to treat subfoveal choroidal neovascularisation in highly myopic eyes: 1-year outcome. *Br J Ophthalmol* 2009; 93:448-451.
45. Chan WM, Lai TY, Chan KP et al. Intravitreal bevacizumab (Avastin) for myopic choroidal neovascularisation: 1-year results of a prospective pilot study. *Br J Ophthalmol* 2009; 93:150-4.

46. Gharbiya M, Allievi F, Mazzeo L, Gabrieli CB. Intravitreal bevacizumab treatment for choroidal neovascularization in pathologic myopia: 12-month results. *Am J Ophthalmol* 2009; 147:84-93.
47. Ikuno Y, Sayanagi K, Soga K et al. Intravitreal bevacizumab for choroidal neovascularization attributable to pathological myopia: one-year results. *Am J Ophthalmol* 2009; 147:94-100.
48. Hayashi K, Ohno-Matsui K, Shimada N et al. Intravitreal bevacizumab on myopic choroidal neovascularization that was refractory to or had recurred after photodynamic therapy. *Graefes Arch Clin Exp Ophthalmol* 2009; 247:609-618.
49. Ruiz-Moreno JM, Gomez-Ulla F, Montero JA et al. Intravitreal bevacizumab to treat subfoveal choroidal neovascularization in highly myopic eyes: short term results. *Eye* 2009; 23:334-348.
50. Rensch F, Spandau UH, Schlichtenbrede F et al. Intravitreal bevacizumab for myopic choroidal neovascularization. *Ophthalmic Surg Lasers Imaging* 2008; 39:182-185.8.
51. Silva RM, Ruiz-Moreno JM et al. Short-term efficacy and safety of intravitreal ranibizumab for myopic choroidal neovascularization. *Retina* 2008; 28:1117-23.
52. Lai TY, Chan WM et al. Intravitreal ranibizumab for the primary treatment of choroidal neovascularization secondary to pathologic myopia. *Retina* 2009;29(6):750-6.
53. Varano M, Tedeschi M, Oddone F, Perillo L, Coppè AM, Parravano M. Microperimetric retinal changes in myopic choroidal neovascularization treated with intravitreal ranibizumab. *Retina* 2010; 30:413-7.
54. Silva RM, Ruiz-Moreno JM, Rosa P, Carneiro A, Nascimento J, Rito LF et al. Intravitreal ranibizumab for myopic choroidal neovascularization: 12-month results. *Retina* 2010; 30:407-12.
55. Gharbiya M, Giustolisi R, Allievi F, Fantozzi N, Mazzeo L, Scavella V et al. Choroidal neovascularization in pathologic myopia: intravitreal ranibizumab versus bevacizumab--a randomized controlled trial. *Am J Ophthalmol* 2010; 149:458-64.
56. Lalloum F, Souied EH, Bastuji-Garin S, Puche N, Querques G, Glacet-Bernard A et al. Intravitreal ranibizumab for choroidal neovascularization complicating pathologic myopia. *Retina* 2010; 30:399-406.
57. Voykov B, Gelisken F, Inhoffen W et al. Bevacizumab for choroidal neovascularization

- secondary to pathologic myopia: Is there a decline of the treatment efficacy after 2 years? *Graefes Arch Clin Exp Ophthalmol* 2010; 248:543-50.
58. Ikuno Y, Nagai Y, Matsuda S et al. Two-year visual results for older Asian women treated with photodynamic therapy or bevacizumab for myopic choroidal neovascularization. *Am J Ophthalmol*. 2010; 149:140-6.
59. Ruiz-Moreno JM, Montero JA. Intravitreal bevacizumab to treat myopic choroidal neovascularization: 2-year outcome. *Graefes Arch Clin Exp Ophthalmol*. 2010; 248:937-41.
60. Iacono P, Battaglia Parodi M, Papayannis A, et al. Intravitreal bevacizumab therapy on an as-per-needed basis in subfoveal choroidal neovascularization secondary to pathological myopia: 2-year outcomes of a prospective case series. *Retina*. 2011;31:1841-7.
61. Baba T, Kubota-Taniai M, Kitahashi M, Okada K, Mitamura Y, Yamamoto S. Two-year comparison of photodynamic therapy and intravitreal bevacizumab for treatment of myopic choroidal neovascularisation. *Br J Ophthalmol* 2010; 94:864-70.
62. Calvo-Gonzalez C, Reche-Frutos J, Donate J, Fernandez-Perez C, Garcia-Feijoo J. Intravitreal ranibizumab for myopic choroidal neovascularization: factors predictive of visual outcome and need for retreatment. *Am J Ophthalmol*. 2011 Mar;151(3):529-34.
63. Watanabe D, Takagi H, Suzuma K, Oh H, Ohashi H, Honda Y. Expression of connective tissue growth factor and its potential role in choroidal neovascularization. *Retina*. 2005;25:911-8.
64. Chan WM, Lai TY, Chan KP, Li H, Liu DT, Lam DS, Pang CP. Changes in aqueous vascular endothelial growth factor and pigment epithelial-derived factor levels following intravitreal bevacizumab injections for choroidal neovascularization secondary to age-related macular degeneration or pathologic myopia. *Retina*. 2008;28:1308-13.
65. Ruiz-Moreno JM, Montero JA, Amat-Peral P. Myopic choroidal neovascularization treated by intravitreal bevacizumab: comparison of two different initial doses. *Graefes Arch Clin Exp Ophthalmol*. 2011;249:595-9.
66. Ruiz-Moreno JM, Montero JA, Arias L, Araiz J, Gomez-Ulla F, Silva R, Piñero DP. Three versus one intravitreal bevacizumab injections as initial protocol to treat myopic choroidal neovascularization. *Acta Ophthalmol*. 2011 Apr 6.
67. Parodi MB, Iacono P, Papayannis A, Sheth S, Bandello F. Laser photocoagulation, photodynamic therapy, and intravitreal bevacizumab for the treatment of juxtafoveal choroidal neovascularization secondary to pathologic myopia. *Arch Ophthalmol*. 2010;128:437-42.

68. Fung AE, Lalwani GA, Rosenfeld PJ et al. An optical coherence tomography-guided, variable dosing regimen with intravitreal ranibizumab (Lucentis) for neovascular age-related macular degeneration. *Am J Ophthalmol.* 2007;143:566-83.
69. Lalwani GA, Rosenfeld PJ, Fung AE et al. A variable-dosing regimen with intravitreal ranibizumab for neovascular age-related macular degeneration: year 2 of the PrONTO Study. *Am J Ophthalmol.* 2009;148:43-58.