

Impaired Cerebral Perfusion in Multiple Sclerosis: Relevance of Endothelial Factors

Lucia Monti¹, Lucia Morbidelli² and Alessandro Rossi³

¹Unit of Neuroimaging and Neurointervention, Department of Neurological and Neurosensory Sciences, "Santa Maria alle Scotte" General Hospital, University Hospital of Siena, Siena, Italy.

²Department of Life Sciences, University of Siena, Siena, Italy. ³Unit of Neurology and Clinical Neurophysiology, Department of Neurological and Neurosensory Sciences, University Hospital of Siena, Siena, Italy.

Biomarker Insights
Volume 13: 1–10
© The Author(s) 2018
Reprints and permissions:
sagepub.co.uk/journalsPermissions.nav
DOI: 10.1177/1177271918774800



ABSTRACT: Magnetic resonance imaging techniques measuring in vivo brain perfusion and integrity of the blood-brain barrier have developed rapidly in the past decade, resulting in a wide range of available methods. This review first discusses their principles, possible pitfalls, and potential for quantification and outlines clinical application in neurological disorders. Then, we focus on the endothelial cells of the blood-brain barrier, pointing out their contribution in regulating vascular tone by production of vasoactive substances. Finally, the role of these substances in brain hypoperfusion in multiple sclerosis is discussed.

KEYWORDS: Endothelial factors, multiple sclerosis, cerebral hypoperfusion, magnetic resonance perfusion

RECEIVED: January 14, 2018. **ACCEPTED:** April 7, 2018

TYPE: Review

FUNDING: The author(s) received no financial support for the research, authorship, and/or publication of this article.

DECLARATION OF CONFLICTING INTERESTS: The author(s) declared no potential conflicts of interest with respect to the research, authorship, and/or publication of this article.

CORRESPONDING AUTHOR: Lucia Monti, Unit of Neuroimaging and Neurointervention, Department of Neurological and Neurosensory Sciences, "Santa Maria alle Scotte" General Hospital, University Hospital of Siena, Viale Bracci, 2 – 53100 Siena, Italy. Email: l.monti@ao-siena.toscana.it

Introduction

Multiple sclerosis (MS) is an autoimmune disease driving inflammatory and degenerative processes that damage the central nervous system (CNS). The main pathological hallmarks of MS lesions in the brain and spinal cord are inflammation, demyelination, partial remyelination, axon loss, and reactive gliosis.¹ In addition, breakdown of the blood-brain barrier (BBB), causing failure in the regulation of paracellular permeability, as well as cerebral hypoperfusion, has also been well documented.^{2–4}

In 1980, the first magnetic resonance imaging (MRI) images of white matter lesions were proposed,⁵ and until now, the MRI has been focused on the quantification of lesion load, cerebral atrophy, and gray and white matter quantitative ratio^{6,7} as surrogate of an anatomic-pathological pattern in vivo. Although significant effort has been made over the past decades to develop innovative image processing algorithms, to improve exhaustive morphological MRI quantitative methods, the utility of the results obtained for understanding pathophysiology has remained limited.

The morphological evaluation neither increased the understanding of MS pathophysiology nor discriminated the MS phenotypes. In fact, it is unknown whether brain atrophy resulting from neuropil deconstruction is due to inflammation process or primary neurodegenerative progression.⁸

As Reich⁹ has recently claimed concerning MS neuroimaging studies, "the implication of accumulated evidence for understanding disease pathophysiology and, hence the overall significance of these imaging findings, are doubtful." Therefore, it needs to go beyond the only morpho-volumetric evaluation of lesion or the degenerative consequences of MS disease.

The relatively new concept of neurovascular unit (NVU) helps to clarify the hemodynamic changes due to the intricate interplay between cerebral blood flow (CBF) and vasoactive factors. Several studies have demonstrated the importance of endothelial factors, their neurovascular interaction, and that vascular changes are also highly conducive to neurodegenerative changes and clinical impairment.^{10–13} Cerebral hypoperfusion and vascular factors are strictly involved in neurovascular dysfunction, vascular oxidative stress, and relative tissue hypoxia, well in advance of any demyelinating lesions. Changes in capillary resistance and neurovascular function may, in fact, represent important common denominators for conditions that increase the risk of developing both demyelinating lesions and progressive MS forms. Functional MRI (fMRI), especially diffusion and perfusion MRI, is able to assess the temporal dynamic evolution of lesions and detect pathophysiological changes beyond the lesions shown in conventional images. As will be discussed below, most of the impediments that have limited the use of MRI perfusion can now be overcome to allow for the integration of these methods into modern neuroimaging protocols.

Cerebral Hypoperfusion: Current Concepts

Cerebral perfusion is defined as the volume of blood flowing through a given volume of tissue per unit of time. The "Bohr-Kety-Crone-Renkin" equation describes the relationship between CBF and the availability of oxygen in brain tissue.^{14–16}

The term "flow-diffusion" refers to freely diffusible substances through a hypothetical homogeneous brain volume, which is identically perfused. In the brain tissue, on the contrary,



the flux of erythrocytes through cortical brain capillaries is highly inhomogeneous, as are the extraction properties. Cerebral hypoperfusion is a medical condition in which the brain experiences a decrease in blood supply. In experimental ischemia, neuronal electrical activity is jeopardized when CBF is lower than the CBF threshold of 20 mL/100 mL per minute.¹⁵ Below CBF levels of 8 to 12 mL/100 mL per minute, additionally reduced oxygen availability leads to the failure of ion homeostasis across cell membranes and to permanent brain tissue damage.^{14,16} The main perfusion parameters that are clinically measurable are the CBF, the cerebral blood volume (CBV), and the mean transit time (MTT). Stemming from an extensive “literature puzzle,” brain hypoperfusion has been demonstrated in many cerebral pathologies without reaching the critical CBF threshold that leads to cerebral ischemia.¹⁶

Cerebral Perfusion: MRI Quantification Issues

The complex mechanisms of biochemical communication among NVU¹⁷ components (neurons, astrocytes, pericytes, and endothelial cells) modulate the blood supply to the neuronal needs. Endothelial factors (ie, ET family), as well as other vascular factors (vascular endothelial growth factor [VEGF], nitric oxide [NO], asymmetric dimethylarginine [ADMA], etc.), play a crucial role in the coupling or uncoupling of the binomial NVU/CBF entity. Therefore, neurovascular coupling itself underlies neuroimaging techniques and provides a hemodynamic map (hypoperfusion/hyperperfusion) related to mitochondrial functions and neuronal activity.^{13,18–23}

The aim of several studies is to integrate biochemical mechanisms with imaging results, the first step of which is to understand how the imaging techniques could represent the NVU/CBF coupling or uncoupling.^{24–27}

The MRI perfusion imaging methods realize functional map which are cerebral hemodynamic snapshots.

The advantage of using an MRI-based perfusion imaging method²⁴ is that, in addition to its non-invasiveness, there is the possibility of using different MRI sequences based on exogenous contrast gadopentetic acid (Gd-DTPA; dynamic susceptibility enhancement [DSE], dynamic contrast enhancement [DCE]) or endogenous tracer (intravoxel incoherent motion, arterial spin labeling [ASL] with different acquisition methods, namely, continuous ASL, pseudo-continuous ASL, pulsed ASL). These options allow for the combined longitudinal assessment of tissue perfusion and morphofunctional features.^{26–30}

Cerebral perfusion imaging by quantitative MRI exogenous contrast agent

Over the past 100 years, several techniques have been devised to measure CBF. From the very early invasive measurements, human CBF assessment has been complemented by the efforts to develop quantification techniques such as radioactive ¹³³Xe, positron emission tomography, or single-photon emission

computed tomography.^{30–36} Despite their low spatial resolution, these techniques led to the proof of hyperperfusion during acute inflammation and hypoperfusion in the quiescent phases in animal models of MS. Nevertheless, the ultimate goal of a totally noninvasive method that enables the mapping of CBF with high temporal and spatial resolution over the wide range of relevant blood flows has not been attained. The general model used for perfusion quantification is based on the principles of nondiffusible tracer kinetics and relies on the assumption that with intact BBB, the tracer remains intravascular. Considering a bolus of contrast tracer injected, its concentration within a given volume of interest (VOI) at a later time t can be defined according to the following functions: (1) transport function, reflecting the distribution of transit times through the voxel, which is dependent on the vascular structure and flow; (2) residue function, which is the fraction of tracer still present in the VOI at time t following an ideal instantaneous unit bolus injection; and (3) arterial input function (AIF) corresponding to the concentration of contrast agent in the feeding vessel to the VOI at time t . The Gd-DTPA concentration is measured through its effect on magnetic resonance (MR) signal intensity. It is assumed as/to be necessary that the contrast agent concentration time curve corresponds to changes in regional MR signal intensity. The MRI perfusion sequences used are termed DSC and DCE. With exogenous contrast medium, the DSC sequence shows a decrease in signal intensity on T2-weighted images, whereas DCE sequence evidence increases in signal intensity on T1-weighted images. At present, the so-called AIF^{26,35,37–39} is central to quantification of CBF. The DSC acquisition achieves perfusion parameters such as CBF, CBV, MTT, and time to peak (TTP), which are always relative and indirect perfusion parameters.

The advantages of DSC are few minutes of acquisition time, possible quantitative measurement (through deconvolution of the measured tissue curves by an AIF and not under 8 mL/min/100 g), useful for emergency setting, and has no age limitation (children). During clinical practice, the DSC perfusion map (CBF, CBV, MTT, TTP) does not permit, as discussed above, quantitative perfusion values but demonstrates critical hemodynamic disturbances in a number of clinical setting. The main clinical applications of DSC are acute stroke assessment, tumor grading, differential diagnosis among chronic cerebrovascular diseases, infections, demyelinating lesions, and tumors.²⁷ The evaluation of mismatch between CBV and CBF in ischemia areas can assess areas of reversible ischemia vs irreversible infarction: decreased CBF associated with normal or increased CBV suggests reversible ischemia, whereas reduced CBF and CBV are indicative of irreversible infarction. This semiquantitative perfusion map associated with other MRI acquisitions such as diffusion-weighted MRI (DWI) and MR angiography can optimize the diagnosis of acute stroke in an emergency setting without ionized radiation (perfusion computed tomography [CT]).

The CBV semiquantitative evaluation achieves differential diagnosis between tumor recurrence vs radiation necrosis or infection vs tumors or tumor-like MS lesions vs tumors. Disadvantages of DSC consist of under- and/or overestimation of relative cerebral blood volume (rCBV) due to high magnetic susceptibility caused by hemoglobin catabolic molecules (hemorrhagic areas) or due to parenchymal contrast medium leakage caused by high BBB permeability. In enhancing high-grade gliomas with substantial BBB breakdown, typical Gd-based contrast agents extravasate, reducing T2* DSC-MRI signal intensity loss by signal intensity increase in regions where T1 effects are significant.⁴⁰ The DSC perfusion parameters cannot be corrected when the hemorrhagic areas are present, whereas parenchymal contrast medium leakage can be avoided by preload contrast medium administration before DSC acquisition. The DSC leads to hemodynamic evaluation, although it does not supply information about BBB permeability. On the contrary, DCE furnishes information about not only perfusion but also permeability parameters.

Tracer kinetic modeling of DCE sequence is able to measure 4 parameters involved in a 2-compartment exchange model: fractional plasma volume, fractional interstitial volume, plasma flow, and K-trans (permeability-surface index). To measure the above perfusion parameters, mathematical models such as Toft and Patlak are used. The Toft model calculates bidirectional exchange flow (intravascular-interstitial space) and therefore BBB permeability.^{41,42} As shown by Heye et al, the Toft model is able to measure K-trans even with mild BBB permeability changes. There are, however, some critical aspects to be considered when measuring K-Trans: (1) capillary surface area (capillary density and size, and microvessel pathology) and (2) temporal resolution (the latter being longer than the tissue blood compartment transit time).⁴²⁻⁴⁶

K-trans is the result of the leakage of contrast medium across the BBB related to plasmatic contrast concentration and is tightly linked to CBF. Using the Patlak method, based on 2-compartment analysis, only unidirectional transport of contrast agent across the BBB from the blood plasma into the extravascular has been considered.^{42,43,45}

However, for both models, AIF, high plasmatic volume, and MRI parameters (acquisition time, precontrast longitudinal relaxation time T1, dose of contrast medium, and field stability) need to be set in order to achieve accuracy in measuring BBB permeability. Indeed, the characteristic of acquisition parameters such as acquisition time has to be calibrated in function of the disease to be studied. Depending on the brain disease, the choice of the models and acquisition time improve the BBB permeability measure.

To demonstrate late permeability phenomena and not underestimate the permeability of small lesions or normal-appearing white matter (NAWM), the Toft method requires a long acquisition time. In animal models, diffuse signal

enhancement in parts of lesions has been observed up to 5 hours after injection. This observation suggests that other mechanisms may become manifest several hours after injection.^{42,45} In humans, during clinical practice, acquisition time has to be as long as possible to capture slow interstitial uptake when BBB is not so altered as to permit a contrast leakage few minutes after the contrast intravenous injection (tumors, infective processes, active MS lesions, etc.). Indeed, in diseases such as dementia, small vessel disease, MS, and so on, NAWM may demonstrate altered permeability values only if the acquisition time is long enough.⁴⁶⁻⁴⁸ To summarize, it is known that the demonstration of new MS lesions during MR follow-up and MS lesion load does not always correlate to disability outcomes⁴⁹ or that annual progression of atrophy is not always associated with benign MS.^{50,51} Volumetric MRI, MR spectroscopy, and quantification of magnetic transfer ratio (MTR) in MS have contributed to demonstrate the consequence of a long-lasting neuroinflammation rather than MS prognosis or MS pathophysiology. On the contrary, quantification of BBB permeability could demonstrate the existence of ongoing subclinical disease activity even in the absence of relapses or MRI activity. The DCE perfusion analysis focused on BBB permeability may predict conversion from optic neuritis to MS 2 years earlier and, by differentiating MS from optic neuritis, may constitute an early prognostic factor in the pathogenesis of MS.⁵¹

Cerebral perfusion imaging by quantitative MRI endogenous contrast agent

Arterial spin labeling is a quantitative cerebral perfusion measurement technique that harnesses blood water as an endogenous contrast agent and thus, uniquely, is entirely noninvasive.²⁹ Radiofrequency pulses "labeled" hydrogen proton spins in arterial blood water. These act as an endogenous tracer and CBF maps are acquired: the tagged spins reaching the region of interest are proportional to CBF. In other terms, the CBF depends on changes in tissue longitudinal relaxation (T1) caused by the exchange of water between blood and tissue. The subtraction between the control image (protons not labeled) and the labeled image results in a perfusion-weighted image and is then quantified into the CBF map.

As in the physiological literature, in ASL maps, the quantification of CBF (based on the time delay between labeling and imaging) is expressed in mL/100g per minute.

Arterial spin labeling sequence can be summarized in 3 phases: labeling, postlabeling, and read-out of signal. It is crucial to synchronize the time of image acquisition and the arrival of labeled bolus to the target tissue named postlabeling delay (PLD). The arrival of labeled hydrogen proton spin bolus is influenced by arterial transit time (ATT), which is the velocity of blood.

In fact, arterial occlusive pattern or arterial-venous fistula may increase or decrease ATT, respectively, and may affect CBF

analysis. The critical aspects of ASL are to optimize the PLD and to consider ATT (different among neonates, children, and adults), low S/N ratio (only 16% of signal intensity is useful to create the CBF map after the subtraction of image control and labeled image), high signal intensity due to large vessels, and magnetization transfer of energy to stationary tissues. The advantages of ASL perfusion are the absolute quantification of CBF, the short sequence acquisition time (few minutes), and the absence of contrast medium administration and ionizing radiation.²⁹ As far as perfusion studies using MRI are concerned, the blood oxygenation level-dependent (BOLD) signal needs to be mentioned. The BOLD signal is the standard technique used to generate images in fMRI studies and relies on the close relationship between CBF and NVU function.

Both the BOLD and ASL reflect different aspects of the dynamic variation of cerebral perfusion. The first is based on the reduction of signal intensity (T2-weighted images) due to magnetic susceptibility to deoxyhemoglobin (neuronal activity correlated to O₂ consumption), whereas the latter obtains increased signal intensity (T1-weighted images) from excited blood protons (CBF) in the target tissue. The BOLD signal depends also on CBF, although it does not express it directly, whereas ASL gives absolute CBF quantification. In other terms, BOLD reflects the neurovascular coupling, ie, the temporal and regional linkage between neural activity and metabolic rate of oxygen consumption, CBF, and CBV.

The BOLD signal can be quantified by mathematical and mechanistic modeling tests and may represent a putative biomarker of brain perfusion variations.^{52–54}

BBB Permeability and Quantitative Functional MRI

Tofts and Kermode⁴⁵ demonstrated that BBB permeability in MRI corresponds to the leakage of Gd-DTPA as measured after a bolus injection and dynamic MRI sequences.

As these authors demonstrated, it has been shown by using DCE that the leakage space measurements (enhanced areas) correspond to Gd-DTPA dispersion in extracellular space.

In patients with MS, subtle BBB permeability change by K-trans (mL/100 g per minute), has been shown in normal-appearing white matter and gray matter and may represent an early prognostic factor in this disease.¹⁴ The BBB permeability measured by using DCE (K-trans) is significantly higher in periventricular NAWM and thalamic gray matter in patients with MS compared with healthy controls. Moreover, BBB permeability values are lower in patients undergoing immunomodulatory treatment, whereas they are higher in the presence of MS relapse activity. However, in the quiescent phase, areas prone to the development of new MS lesions, such as periventricular NAWM, present higher K-trans values. Indeed, K-trans evaluation applied to a larger MS patient group of clinically isolated syndrome or optic neuritis could predict the development toward MS disease and potentially assume a prognostic value.^{41,51}

We can speculate that knowing the exact value of minimal BBB permeability change that precedes the acute event and the CBF changes preceding the BBB permeability alteration permit us to define the disease perfusion biomarker.

Studies by high MR fields (3T and 7T) evidenced a perivascular hyperintensity on T2-weighted images as well as a slow intravascular flow many weeks before the enhancement lesion.⁵⁵

The authors speculated “a slow flow associated with leukocyte rolling and/or entrapment of contrast agent within the perivascular space without passage through the glia limitans.” Hypercellularity and minimal parenchymal edema around the vein could explain the early MRI signal changes on T2-weighted images before the evident BBB damage (enhanced lesion in standard MRI).⁵⁵

Improving time resolution and fMRI technique will overcome volumetric and morphologic quantifications, allowing for the discovery of not only “why,” but overall “when” the BBB permeability changes occur.

NVU/CBF Coupling

Over the past decade, research studies have left the neuron-centric view and focused on neuroglia or endothelial cells and, overall, on whole NVU rather than only a singular cellular element. Physical (pressure, flow, temperature, volume, Hb concentration, etc) and/or biochemical stimuli (vasoactive factors, inflammatory molecules, etc.) modulate cross-talking among NVU cellular elements: endothelial cells, pericytes, microglial cells, astrocytes, smooth muscle cells, extracellular matrix components, and neurons. All of these elements, through their intimate anatomical and biochemical relationship, detect the needs of neuronal supply and trigger the necessary responses (vasoconstriction and vasodilatation).^{10,56–62} Neurovascular unit (NVU), a dynamic entity changing in time and space and autoregulation of cerebral vascular tone, is one of the fundamental mechanisms for CNS homeostasis⁶³ (Figure 1).

It seems useful to recall here that brain endothelium differs fundamentally from other vascular endothelia in its capacity to regulate the passage of molecules and cells to and from the neural parenchyma. This selectivity resides in specialized features unique to the CNS endothelia, including the expression of tight intercellular junctions (TJ) that markedly limit paracellular permeability, in addition to a unique pattern of receptors to vasoactive molecules and low density of transcytosis vesicles that protect the CNS from potentially harmful compounds.^{56,57} Recently, Benjamin J Andreone et al⁶⁴ confirmed the relationship between low BBB permeability and low transcytosis vesicles. However, in addition, many other mechanisms operate for the low BBB permeability to macromolecules.⁵⁸ Furthermore, astrocytes are also important for^{59,60} either blood flow regulation⁶⁵ or the balance of endothelial TJ protein inducing increased BBB permeability.⁶⁶ Perivascular astrocytic endfeet constitute the anatomical and functional bridge between the endothelial and the neuronal “faces” of the BBB.

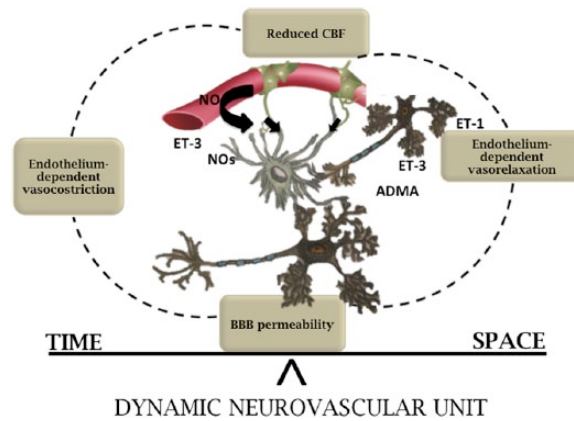


Figure 1. The NVU is an anatomic and functional entity changing in time and space. The tight relationship between biochemical messengers, cerebral blood flow, and NVU elements guarantees the NVU/CBF coupling. Physiologic conditions are the balance in space and time between BBB permeability and brain perfusion. BBB indicates blood-brain barrier; CBF, cerebral blood flow; NVU: neurovascular unit.

Astrocytes, through endothelium-astrocyte-neuron signaling pathway and inflammatory modulators such as prostaglandin E2 (PGE2), NO, VEGF, and so on contribute to BBB damage as well as to a “second barrier” with neuroprotective action during the MS inflammatory process.⁶⁷ Astrocytes seem to be the most versatile cells of NVU as they communicate simultaneously with both neurons and blood vessels. Leaving aside the role of each single element, it is apparent that NVU malfunction of one or more of its elements may have very serious consequences. Several authors have reported injuries in NVU components present in different acute^{19,61,63,68,69} and chronic^{62,70,71} cerebral conditions. In these pathological processes, it is possible to recognize the loss of permeability and selectivity of the BBB, inflammatory responses, cerebral hypoperfusion, and reduced clearance of toxic agents such as reactive oxygen species, inflammatory mediators, and misfolded proteins.⁷² Although much has been done, many questions concerning the role of each NVU component and their mutual interdependence still have no answers. Indeed, the functional “tight junction” between CBF supply and energy request/cellular activity is well combined under the new concept of NVU. The nosological distinction between neurodegenerative and neurovascular diseases begins not to be unyieldingly considered as the results of 2 different pathophysiologic mechanism, but as 2 faces of the same coin.¹⁷ In other words, the vascular aspect and inflammatory/degenerative patterns coexist in histology, MRI, and clinical evidence, and their relationship needs to be explained. Together, the vascular-derived insults might initiate and/or contribute to neuronal degeneration/inflammatory phenomena.⁷³

Brain perfusion in MS

In patients with MS, cerebral hypoperfusion was first observed about 30 years ago and it has become evident now that reduced cerebral perfusion, likely due to NVU malfunction and involving both the gray and white matter, is an integral feature of MS pathology.^{2,55} These findings may influence our understanding

of the underlying disease processes and be important for future therapeutic considerations. The relationship between MS lesions and the cerebral vasculature has long been recognized. Histopathologic evidence of vascular occlusion was described in the 1930s by Putnam,⁷⁴ suggesting that vascular inflammation precedes demyelination and could be a primary event in the evolution of the disease. Later, Wakefield et al⁷⁵ demonstrated fibrin deposition and thrombosis of vessels in the absence of cellular infiltration. Occlusive changes have also been confirmed in the retinal venules of patients who later developed MS.⁷⁶ Nevertheless, it is still unclear whether abnormal perfusion is a precursor of lesions or occurs independently of lesion development through a different mechanism. Among the mechanisms responsible for reduced perfusion in MS, vasoactive substances have been suspected to play a leading role. In animal models, the demyelinating lesion has been demonstrated at a vascular watershed such as the white-gray matter border, after 1 week from activation of innate immune mechanisms and not centered on the demyelinating injection site of lipopolysaccharide. This pathological pattern suggests that the immunological answer has been realized in an area where the vascular susceptibility to hypoxia is higher. In the same experiment, major oxygen administration can partially reduce superoxide and NO formation and cellular energy deficit by interrupting the hypoxia mechanism. In the animals that underwent inspired oxygen application, the demyelination process was reduced. If a relationship between demyelinating lesions and critical vascular watershed has been demonstrated, a vascular phase underpinning the disease progression has to be considered.⁷⁷ It is known that micro- and macro-circulation changes (eg, venous thrombosis, stroke) lead to enhanced BBB permeability and increased paracellular fluid (shown by white matter [WM] vasogenic edema on T2-weighted images) until critical oxygen availability (reduced ADC area on diffusion-weighted images). Enhanced BBB permeability, indirectly measured by MRI (ie, edema and reduced brain perfusion), is linked to (1) deregulation of brain vessels involving interactions of vasoactive

substances both at a receptor and at a signal transduction level and (2) endothelial transcellular or paracellular changes and/or endothelial TJ disruption. These events may represent general examples of either an effective pathological feature or NVU properties able to respond to injury.⁷⁸ Given the tight relationship between CBF and BBB permeability, as well as the tight relationship between brain vasoreactivity and function, it could be important to know brain hypoperfusion onset in MS disease. To know the onset of cerebral hypoperfusion in MS might clarify whether CBF reduction is the cause or the consequence of MS pathophysiologic process. Moreover, brain hypoperfusion or forerunning BBB permeability could identify translation from quiescent to acute phase in relapsing-remitting (RR)-MS and/or from RR-MS to progressive form. Indeed, RR-MS and secondary progressive MS (SP-MS) groups, showing a different correlation between a brain perfusion parameter such as CCT and MS duration disease as well as endothelin 1 (ET1) plasmatic concentration, could be considered as 2 different pathologic entities.⁴⁴ To try to understand when the neuroprotective process failed (MS progressive form) or is limited and partially reversed (MS RR form) could, in our view, be a helpful, alternative point of view and drive a different research hypothesis.

Brain perfusion in MS: cytotoxic or vasogenic edema

Cerebral hypoperfusion has been demonstrated in secondary progressive form (SP-MS) as well as in RR-MS patients, although ischemic threshold is not usually reached.

However, MRI demonstrated cytotoxic signs inside MS lesions in diffusion-weighted images, suggesting a pathologic vascular aspect, although there are more than one reasons able to explain it.

The reduction of apparent diffusion coefficient (ADC), cytotoxic sign, in MS acute demyelinating lesions could be due to (1) hypoxic changes leading to ischemic precondition expressed by hypoxia markers in oligodendrocytes such as hypoxia-inducible factor 1 and heat shock protein 70, (2) intramyelinic edema or myelin vacuolization and/or myelin breakdown reducing water movement in the extracellular space because fiber tract organization is reduced, and (3) the presence of a hypercellular inflammatory infiltrate and/or iron-laden macrophages. The most relevant thing to note is that reduction of ADC precedes the enhancement leakage in MS acute lesions demonstrating BBB breakdown.⁷⁹

Cerebral ischemic stroke is a pertinent model for understanding CBF/biochemical changes. Several studies relative to the ischemic process have demonstrated that the same molecules support different actions (protection or toxicity) depending on the time frame of the pathophysiologic pathway. Some examples are as follows: N-methyl-D-aspartate (NMDA) receptors induce acute excitotoxicity⁸⁰ in an early phase of ischemic

lesion, whereas in the late frame without NMDA signaling, chronic neuronal remodeling cannot take place.⁸⁰ High Mobility Group 1 (HMGB1) is an expression of acute cerebral ischemia, necrosis, and core infarct,⁸¹ while in the late stages reactive astrocytes release HMGB1 and promote angiogenesis and synaptic plasticity.^{82,83} Matrix metalloproteinases degrade and damage neurovascular substrates in the acute phase, although proteases are themselves critically important for neurovascular remodeling during the recovery phase.^{84,85}

Nevertheless, the molecular interaction and their exact time frames in regulating vessel reactivity and pathologic or regenerative process are not yet well known in stroke, MS, or other neurodegenerative diseases (Figure 2).

Brain perfusion and neurovascular signaling

In the nervous system, the coupling between brain vessels (CBF) and neurons is thought to be mediated by vasoactive mediators, among which are NO/ADMA and endothelins. Under normal brain perfusion, NO is constitutively produced by endothelial nitric oxide synthase (eNOS) at nanomolar concentrations, the enzyme activity being calcium and calmodulin dependent.⁸⁶ In an inflammatory environment such as the MS brain, the inducible form of NOS (iNOS) is upregulated, producing micromolar concentration of NO and nitrogen reactive species. Nitric oxide has 2 major effects on cerebral vessels, both of which may be involved in the pathogenesis of MS lesions, namely, vasodilation and alteration of the BBB. Vasodilation by itself may facilitate inflammation by decreasing the velocity of blood flow, thereby aiding leukocyte transmigration, the latter facilitated by NO-induced BBB breakdown. In addition, NO may cause conduction block, perhaps by impairing the function of sodium channels; demyelinated axons are particularly vulnerable to this effect. Furthermore, raised concentrations of NO and related reactive species may impair synaptic transmission, which, in addition to compromising transmission in motor and sensory pathways, may contribute to the loss of function in patients with MS.⁸⁶ Increased NO levels could drive the overproduction of its own inhibitor (ADMA) or counterbalancing vasoactive peptides such as ET1 and endothelin 3 (ET3), again produced by endothelial cells. ET1 vasoconstriction is mediated by A receptors: high ET1 concentration and high ET1 A receptor affinity promote a severe and prolonged vasoconstriction. However, concurrently, ET1-ETB receptor stimulation may induce vasodilation. ET3, in comparison with ET1, has a high affinity for B-receptor proportional to its concentration (ET3 [nM] vs ET1 [μ M]).^{87,88} Considering the prevalent brain endothelial origin of ET3 and its high affinity to B receptor (antagonist action of ET1 on receptor type A), ET3 could potentially have a role in neurovascular uncoupling due to endothelial dysfunction in patients with MS. Other modulating factors involved in NO pathway include ADMA, an endogenous inhibitor of NOS. Indeed,

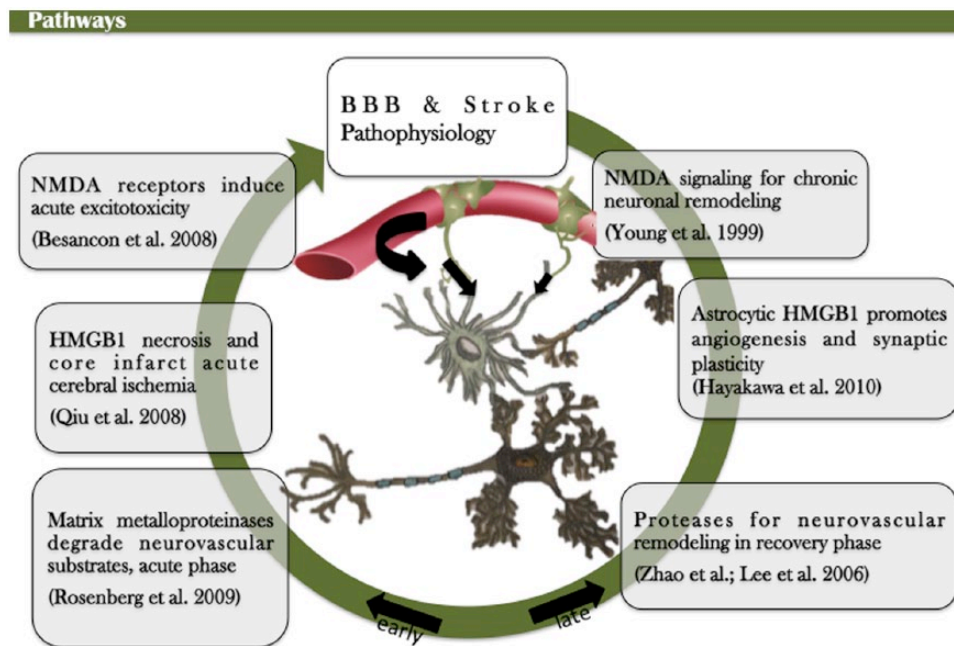


Figure 2. MRI perfusion in MS disease and endothelial factors. Different plasmatic titration of endothelial factors modulate the brain perfusion and model the space/time NVU modification: vasodilation (increased CBV, CBF, TTP and MTT) leading to hyperperfusion in active demyelinating lesion region of interest ROI (1), whereas a reduced brain perfusion is demonstrated (reduced TTP) in chronic and stable condition in normal-appearing WM and stable demyelinating lesion. BBB indicates blood-brain barrier; CBF, cerebral blood flow; CBV, cerebral blood volume; HMGB1, High Mobility Group 1; MTT, mean transit time; MRI, magnetic resonance imaging; MS: multiple sclerosis; NMDA, N-methyl-D-aspartate; NVU, neurovascular unit; TTP, time to peak.

elevation of ADMA has been demonstrated in patients with MS, although it not yet known whether its role is inflammatory or vasoactive or likely both. Even if high ADMA titration is associated with impaired vasodilation, no correlation with brain perfusion parameters (such as cerebral circulation time [CCT]) and plasmatic ADMA levels has been found.^{18,89,90} To identify biomarkers of chronic cerebral hypoperfusion inducing NVU changes and their putative brain injury and clinical disability is still a challenge (Figure 3). Cerebral hypoperfusion has been demonstrated in many pathologies (MS, small vessel disease, diabetes, Alzheimer disease, Binswanger disease, etc.).^{91–93} In MS, plasmatic NO, ET1, and ADMA are increased,⁹⁴ and it is generally suggested that this may contribute to cerebral hypoperfusion which, in turn, could contribute to the disease pathogenesis.⁴ Our hypothesis is, rather, that ADMA (by inhibiting both eNOS and iNOS) and ET1 (by opposing the NO-induced vasodilation) could express a compensatory response at least in early disease phase.¹⁸ In other terms, ET1 and ADMA overproduction, inducing brain vasoconstriction, could be an adaptive response to vascular-derived insults. On the contrary, in the later phase, their persistently high levels can cause functional/structural abnormalities of the brain microvasculature by inducing reduced vessel compliance. In our recent work, we have demonstrated that in SP-MS patients but not in RR-MS, a significant correlation between ET1 and CCT exists. In fact, in RR-MS the high levels ET1 may act to prevent astrocyte hypoxic stress and promote neuroprotective process.^{13,20,94} A different correlation between ET1

and uncoupling CBF/BBB may explain and focus the different prognosis between RR and SP/PP MS forms. Indeed, other behavior is shown in SP-MS patients: ET1 level is correlated with increasing CCT and is not related to disease duration, suggesting a complete progressive perfusion imbalance in SP-MS patients at the disease onset.

Conclusions

This review has highlighted the possibility of understanding the biochemical process underpinning BBB integrity and the coupling/uncoupling between CBF/NVU revealed indirectly by MRI perfusion analysis. Advanced imaging techniques, their integration with biochemical data, and the knowledge gained across several modalities (micro to macro scale; fast dynamics to long prospective studies; anatomical, molecular, and functional analyses) could enhance the understanding of the cellular and molecular biology of the NVU in health and MS disease.^{95–97}

The importance of interactions between the nervous, immune, and vascular systems is being increasingly recognized. Therefore, the concept of “the blood-brain barrier,” which currently describes exchange mechanisms across the blood-brain interfaces, should be extended to include reciprocal interactions between blood vessels and NVU.

Cerebral hypoperfusion and vascular factors may represent, in different time frames of MS disease, pathologic factors or neuroprotective processes alias recovery or progression of disease. The efforts in studying the structural, biochemical, and

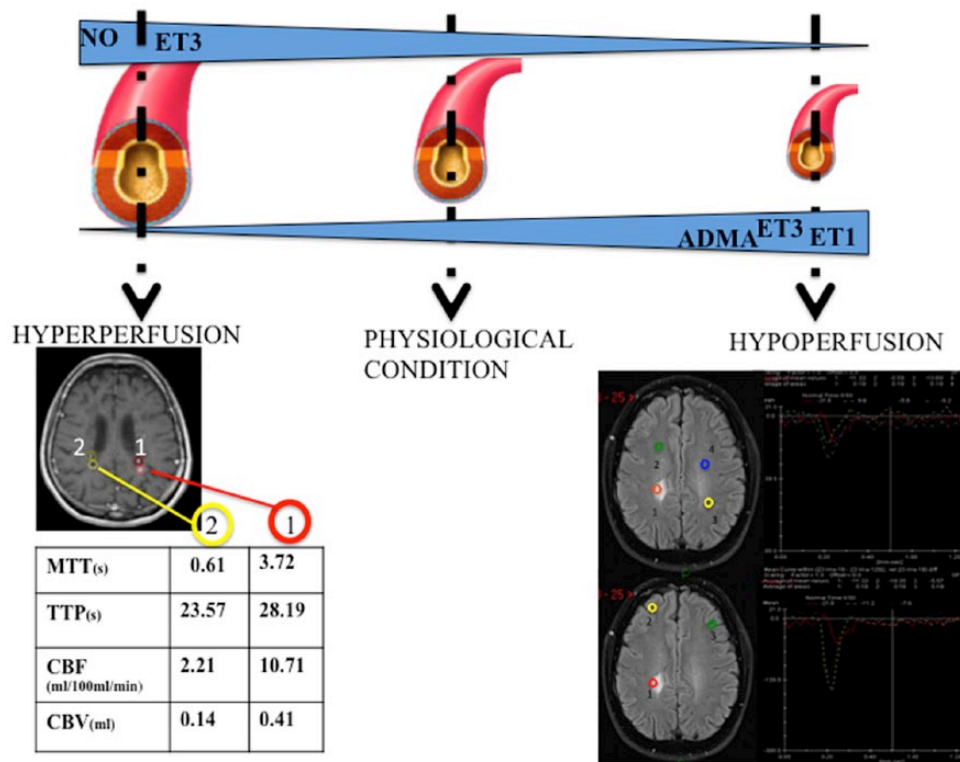


Figure 3. BBB and stroke pathophysiology. In different phases (early or late) of ischemic stroke, the same biochemical factors have opposite roles: neurotoxic vs neuroprotective effects. ADMA indicates asymmetric dimethylarginine; BBB, blood-brain barrier; CBF, cerebral blood flow; CBV, cerebral blood volume; ET1, endothelin 1; ET3, endothelin 3; HMGB1, High Mobility Group 1; MTT, mean transit time; NMDA, N-methyl-D-aspartate; NO, nitric oxide; TTP, time to peak.

functional modulation of CBF/NVU mechanisms during disease progression are often fragmented and compartmentalized inside a single discipline, and a multidisciplinary approach is aspired to. Far from driving MS pathogenesis toward a simple vascular cause, it is essential that cerebral hypoperfusion and its biochemical aspects be considered and commented in MS disease more than in the past.

Acknowledgements

I'd like to thank Mrs Eleonora Burrioni for image composing and Mrs Laura Combs for a careful revision of language and grammar of the text.

Author Contributions

This review is the product of the intellectual environment of whole team.

AR gave substantial contributions to the conception and design of this review. He contributed especially about neurological aspects and revised critically the review for important intellectual content.

LMor gave substantial contributions to the conception and design of this review. She contributed especially about biochemical aspects.

LMon gave substantial contributions to the conception design and interpretation of this review. She contributed especially about neuroradiological aspects. She wrote and revised the manuscript.

REFERENCES

- Halliday AM, Mc Donald WI. Pathophysiology of demyelination disease. *Br Med.* 1977;331:21–27.
- Monti L, Donati D, Menci E, et al. Cerebral circulation time is prolonged and not correlated with EDSS in multiple sclerosis patients: a study using digital subtracted angiography. *PLoS ONE.* 2015;10:e0116681.
- Varga AW, Johnson G, Babb JS, Herbert J, Grossman RI, Inglese M. White matter hemodynamic abnormalities precede sub-cortical gray matter changes in multiple sclerosis. *J Neurol Sci.* 2009;282:28–33.
- D'haeseleer M, Beelen R, Fierens Y, et al. Cerebral hypoperfusion in multiple sclerosis is reversible and mediated by endothelin-1. *Proc Natl Acad Sci U S A.* 2013;110:5654–5658.
- Young IR, Hall AS, Pallis CA, Legg NJ, Bydder GM, Steiner RE. Nuclear magnetic resonance imaging of the brain in multiple sclerosis. *Lancet.* 1981;2:1063–1066.
- Tortorella P, Rocca MA, Mezzapesa DM, et al. MRI quantification of gray and white matter damage in patients with early-onset multiple sclerosis. *J Neurol.* 2006;253:903–907.
- Shinohara RT, Sweeneybc EM, Goldsmith J, et al. Statistical normalization techniques for magnetic resonance imaging. *Neuroimage Clin.* 2014;6:9–19.
- Stys PK, Zamponi GW, van Minnen J, Geurts JGG. Will the real multiple sclerosis please stand up? *Nat Rev Neurosci.* 2012;13:507–514.
- Reich DS. Imag(in)ing multiple sclerosis: time to take better pictures. *J Neuroimmunol.* 2017;304:72–80.
- Stanimirovic DB, Friedman A. Pathophysiology of the neurovascular unit: disease cause or consequence? *J Cereb Blood Flow Metab.* 2012;32:1207–1221.
- Eilam R, Segal M, Malach R, Arnon R, Aharoni R. Astrocyte disruption of neurovascular communication is linked to cortical damage in an animal model of multiple sclerosis. *Glia.* 2018;66:1098–1117.
- Lan M, Tang X, Zhang J, Yao Z. Insights in pathogenesis of multiple sclerosis: nitric oxide may induce mitochondrial dysfunction of oligodendrocytes. *Rev Neurosci.* 2018;29:39–53.
- Hostenbacha S, D'haeseleera M, Kooijmanc R, De Keyser J. The pathophysiological role of astrocytic endothelin-1. *Prog Neurobiol.* 2016;144:88–102.
- Renkin EM. Regulation of the microcirculation. *Microvasc Res.* 1985;30:251–263.
- Jespersen SN, Østergaard L. The roles of cerebral blood flow, capillary transit time heterogeneity and oxygen tension in brain oxygenation and metabolism. *J Cereb Blood Flow Metab.* 2012;32:264–277.

16. Østergaard L, Jespersen SN, Mouridsen K, et al. The role of the cerebral capillaries in acute ischemic stroke: the extended penumbra model. *J Cereb Blood Flow Metab.* 2013;33:635–648.
17. Iadecola C. The neurovascular unit coming of age: a journey through neurovascular coupling in health and disease. *Neuron.* 2017;96:17–42.
18. Monti L, Morbidelli L, Bazzani L, Rossi A. Influence of circulating endothelin-1 and asymmetric dimethylarginine on whole brain circulation time in multiple sclerosis [published online ahead of print June 6, 2017]. *Biomark Insights.* doi:10.1177/1177271917712514.
19. Ruhrberg C, Bautch VL. Neurovascular development and links to disease. *Cell Mol Life Sci.* 2013;70:1675–1684.
20. Lima RR, Santana LNS, Fernandes RM, et al. Neurodegeneration and glial response after acute striatal stroke: histological basis for neuroprotective studies. *Oxid Med Cell Longev.* 2016;2016:3173564.
21. Spencer JJ, Bell JS, DeLuca GC. Vascular pathology in multiple sclerosis: reframing pathogenesis around the blood-brain barrier. *J Neurol Neurosurg Psychiatry.* 2017;89:42–52.
22. Garthwaite J. Concepts of neural nitric oxide-mediated transmission. *Eur J Neurosci.* 2008;27:2783–2802.
23. Wolters FJ, Zonneveld HL, Hofman A, et al. Cerebral perfusion and the risk of dementia: a population-based study. *Circulation.* 2017;136:8719–8728.
24. Wuelfel J, Friedemann P, Zipp F. Cerebral blood perfusion changes in multiple sclerosis. *J Neurol Sci.* 2007;259:16v20.
25. Morse OC, Singer JR. Blood velocity measurements in intact subjects. *Science.* 1970;170:440v441.
26. Calamante F, Thomas DL, Pell GS, Wiersma J, Turner R. Measuring cerebral blood flow using magnetic resonance imaging techniques. *J Cereb Blood Flow Metab.* 1999;19:701–735.
27. Ge Y, Law M, Johnson G, et al. Dynamic susceptibility contrast perfusion MR imaging of multiple sclerosis lesions: characterizing hemodynamic impairment and inflammatory activity. *Am J Neuroradiol.* 2005;26:1539–1547.
28. Martinez Sosa S, Smith KJ. Understanding a role for hypoxia in lesion formation and location in the deep and periventricular white matter in small vessel disease and multiple sclerosis. *Clin Sci.* 2017;131:2503–2524.
29. Alsop DC, Detre JA, Golay X, et al. Recommended Implementation of arterial spin-labeled perfusion MRI for clinical applications: a consensus of the ISMRM perfusion study group and the European consortium for ASL in dementia. *Magn Reson Med.* 2015;73:102–116.
30. Keil VC, Mädler B, Gielen GH, et al. Intravoxel incoherent motion MRI in the brain: impact of the fitting model on perfusion fraction and lesion differentiability. *J Magn Reson Imaging.* 2017;46:1187–1199.
31. Hamilton WF, Remington JW. Comparison of the time concentration curves in arterial blood of diffusible and non-diffusible substance when injected at a contrast rate and when injected instantaneously. *Am J Physiol.* 1947;148:35–39.
32. Ito H, Kanno I, Fukuda H. Human cerebral circulation: positron emission tomography studies. *Ann Nucl Med.* 2005;19:65–74.
33. Ibaraki M, Shimosegawa E, Miura S, et al. PET measurements of CBF, OEF, and CMRO2 without arterial sampling in hyperacute ischemic stroke: method and error analysis. *Ann Nucl Med.* 2004;18:35–44.
34. Heiss WD, Podreka I. Role of PET and SPECT in the assessment of ischemic cerebrovascular disease. *Cerebrovasc Brain Metab Rev.* 1993;5:235–263.
35. Wintermark M, Sesay M, Barbier E, et al. Comparative overview of brain perfusion imaging techniques. *Stroke.* 2005;36:e83–e99.
36. Hoeffner EG. Cerebral perfusion imaging. *J Neuroophthalmol.* 2005;25:313–320.
37. Roy CS, Sherrington CS. On the regulation of the blood-supply of the brain. *J Physiol.* 1890;11:85–158.
38. Lassen NA, Christensen MS. Physiology of cerebral blood flow. *Br J Anaesth.* 1976;48:719–734.
39. Lassen NA. Control of cerebral circulation in health and disease. *Circ Res.* 1974;34:749–760.
40. Boxerman JL, Prah DE, Paulson ES, Machan JT, Bedekar D, Schmainda KM. The role of preload and leakage correction in gadolinium-based cerebral blood volume estimation determined by comparison with MION as a criterion standard. *AJNR Am J Neuroradiol.* 2012;33:1081–1087.
41. Cramer SP, Simonsen H, Frederiksen JL, Rostrup E, Larsson HB. Abnormal blood-brain barrier permeability in normal appearing white matter in multiple sclerosis investigated by MRI. *Neuroimage Clin.* 2014;4:182–189.
42. Tofts PS, Kermode AG. Measurement of the blood-brain barrier permeability and leakage space using dynamic MR imaging. 1. Fundamental concepts. *Magn Reson Med.* 1991;17:357–367.
43. Heye AK, Thrippleton MJ, Armitage PA, et al. Tracer kinetic modelling for DCE-MRI quantification of subtle blood-brain barrier permeability. *Neuroimage.* 2016;125:446–455.
44. Heye AK, Culling RD, Valdés Hernández Mdel C, Thrippleton MJ, Wardlaw JM. Assessment of blood-brain barrier disruption using dynamic contrast-enhanced MRI. A systematic review. *Neuroimage Clin.* 2014;6:262–274.
45. Tofts PS, Kermode AG. Blood brain barrier permeability in multiple sclerosis using labelled DTPA with PET, CT and MRI. *J Neurol Neurosurg Psychiatry.* 1989;52:1019–1020.
46. Zhu XP, Li KL, Kamaly-Asl ID, et al. Quantification of endothelial permeability, leakage space, and blood volume in brain tumors using combined T1 and T2 contrast-enhanced dynamic MR imaging. *J Magn Reson Imaging.* 2000;11:575–585.
47. Sourbron S, Ingrisch M, Siefert A, et al. Quantification of cerebral blood flow, cerebral blood volume, and blood-brain-barrier leakage with DCE-MRI. *Magn Reson Med.* 2009;62:205–217.
48. Larsson HB, Courivaud F, Rostrup E, Hansen AE. Measurement of brain perfusion, blood volume, and blood-brain barrier permeability, using dynamic contrast-enhanced T(1)-weighted MRI at 3 tesla. *Magn Reson Med.* 2009;62:1270–1281.
49. Ebers GC, Scalfari A, Daumer M, Lederer C. Combined MRI lesions and relapses as a surrogate for disability in MS. *Neurology.* 2012;78:1367.
50. Gauthier SA, Berger AM, Liptak Z, et al. Rate of brain atrophy in benign vs early multiple sclerosis. *Arch Neurol.* 2009;66:234–237.
51. Cramer SP, Modvig S, Simonsen HJ, Frederiksen JL, Larsson HB. Permeability of the blood-brain barrier predicts conversion from optic neuritis to multiple sclerosis. *Brain.* 2015;138:2571–2583.
52. Mathias EJ, Plank MJ, David T. A model of neurovascular coupling and the BOLD response PART II. *Comput Methods Biomech Biomed Engin.* 2017;20:519–529.
53. Duffin J, Sobczyk O, Crawley A, et al. The role of vascular resistance in BOLD responses to progressive hypercapnia. *Hum Brain Mapp.* 2017;38:5590–5602.
54. Lundengård K, Cedersund G, Sten S, et al. Mechanistic mathematical modeling tests hypotheses of the neurovascular coupling in fMRI. *PLoS Comput Biol.* 2016;12:e1004971.
55. Absinta M, Nair G, Sati P, et al. Direct MRI detection of impending plaque development in multiple sclerosis. *Neurol Neuroimmunol Neuroinflamm.* 2015;2:e145.
56. Brightman MW, Klatzo I, Olsson Y, Reese TS. The blood-brain barrier to proteins under normal and pathological conditions. *J Neurol Sci.* 1970;10:215–239.
57. Reese TS, Karnovsky MJ. Fine structural localization of a blood-brain barrier to exogenous peroxidase. *J Cell Biol.* 1967;34:207–217.
58. Stewart PA. Endothelial vesicles in the blood-brain barrier: are they related to permeability? *Cell Mol Neurobiol.* 2000;20:149–163.
59. López-Bayghen E, Ortega A. Glial glutamate transporters: new actors in brain signaling. *IUBMB Life.* 2011;63:816–823.
60. Santello M, Cali C, Bezzi P. Gliotransmission and the tripartite synapse. *Adv Exp Med Biol.* 2012;970:307–331.
61. Armstead WM, Raghupathi R. Endothelin and the neurovascular unit in pediatric traumatic brain injury. *Neurol Res.* 2011;33:127–132.
62. Itoh Y, Toriumi H, Ebine T, et al. Disturbance in neurovascular unit plays a pivotal role in pathophysiology of small vessel disease in the brain. *Rinsho Shinkeigaku.* 2012;52:1365–1368.
63. Fernández-Klett F, Offenhauser N, Dirnagl U, et al. Pericytes in capillaries are contractile in vivo, but arterioles mediate functional hyperemia in the mouse brain. *Proc Natl Acad Sci U S A.* 2010;107:22290–22295.
64. Andreone BJ, Chow BW, Tata A, Lacoste B. Blood-brain barrier permeability is regulated by lipid transport-dependent suppression of caveolae-mediated transcytosis. *Neuron.* 2017;94:581–594.e5.
65. Takano T, Tian GF, Peng, et al. Astrocyte-mediated control of cerebral blood flow. *Nat Neurosci.* 2006;9:260–267.
66. Horng S, Therattil A, Moyon S, et al. Astrocytic tight junctions control inflammatory CNS lesion pathogenesis. *J Clin Invest.* 2017;127:3136–3151.
67. Argaw AT, Asp L, Zhang J, et al. Astrocyte-derived VEGF-A drives blood-brain barrier disruption in CNS inflammatory disease. *J Clin Invest.* 2012;122:2454–2468.
68. Bastide M, Ouk T, Plaisier F, Pétrault O, Stole S, Bordet R. Neurogliovascular unit after cerebral ischemia: is the vascular wall a pharmacological target. *Psychoneuroendocrinology.* 2007;32:S36–S39.
69. Koide M, Sukhotinsky I, Ayata C, Wellman GC. Subarachnoid hemorrhage, spreading depolarizations and impaired neurovascular coupling. *Stroke.* 2013;44:1934.
70. Carmeliet P. Blood vessels and nerves: common signals, pathways and diseases. *Nat Rev Genet.* 2003;4:710–720.
71. Busch S, Wu L, Feng Y, et al. Alzheimer's disease and retinal neurodegeneration share a consistent stress response of the neurovascular unit. *Cell Physiol Biochem.* 2012;30:1436–1443.
72. Tohidpour A, Morgun AV, Boitsova EB, et al. Neuroinflammation and infection: molecular mechanisms associated with dysfunction of neurovascular unit. *Front Cell Infect Microbiol.* 2017;7:276.
73. Zlokovic BV. Neurovascular pathways to neurodegeneration in Alzheimer's disease and other disorders. *Nat Rev Neurosci.* 2011;12:723–738.

74. Putnam T. The pathogenesis of multiple sclerosis: a possible vascular factor. *N Engl J Med.* 1933;209:786–790.
75. Wakefield AJ, More LJ, Difford J, McLaughlin JE. Immunohistochemical study of vascular injury in acute multiple sclerosis. *J Clin Pathol.* 1994;47:129–133.
76. Graham EM, Stanford MR, Sanders MD, et al. A point prevalence study of 150 patients with idiopathic retinal vasculitis: diagnostic value of ophthalmological features. *Br J Ophthalmol.* 1989;73:714–721.
77. Desai RA, Davies AL, Tachrount M, et al. Cause and prevention of demyelination in a model multiple sclerosis lesion. *Ann Neurol.* 2016;79:591–604.
78. Knowland D. Stepwise recruitment of transcellular and paracellular pathways underlies blood-brain barrier breakdown in stroke. *Neuron.* 2014;82:603–617.
79. Abou Zeid N, Pirko I, Erickson B, et al. Diffusion-weighted imaging characteristics of biopsy-proven demyelinating brain lesions. *Neurology.* 2012;78:1655–1662.
80. Young D, Lawlor PA, Leone P, Dragunow M, During MJ. Environmental enrichment inhibits spontaneous apoptosis, prevents seizures and is neuroprotective. *Nat Med.* 1999;5:448–453.
81. Qiu J, Nishimura M, Wang Y, et al. Early release of HMGB-1 from neurons after the onset of brain ischemia. *J Cereb Blood Flow Metab.* 2008;28:927–938.
82. Hayakawa K, Arai K, Lo EH. Role of ERK map kinase and CRM1 in IL-1beta-stimulated release of HMGB1 from cortical astrocytes. *Glia.* 2010;58:1007–1015.
83. Hayakawa K, Nakano T, Irie K, et al. Inhibition of reactive astrocytes with fluocitrate retards neurovascular remodeling and recovery after focal cerebral ischemia in mice. *J Cereb Blood Flow Metab.* 2010;30:871–882.
84. Rosenberg GA. Matrix metalloproteinases and their multiple roles in neurodegenerative diseases. *Lancet Neurol.* 2009;8:205–216.
85. Lee SR, Kim HY, Rogowska J, et al. Involvement of matrix metalloproteinase in neuroblast cell migration from the subventricular zone after stroke. *J Neurosci.* 2006;26:3491–3495.
86. Iadecola C. Untangling neurons with endothelial nitric oxide. *Circ Res.* 2016;119:1052–1054.
87. Schinelli S. Pharmacology and physiopathology of the brain endothelin system: an overview. *Curr Med Chem.* 2006;13:627–638.
88. Hammond TR, McEllin B, Morton PD, et al. Endothelin-B receptor activation in astrocytes regulates the rate of oligodendrocyte regeneration during remyelination. *Cell Rep.* 2015;13:2090–2209.
89. Kielstein JT, Donnerstag F, Gasper S, et al. ADMA increases arterial stiffness and decreases cerebral blood flow in humans. *Stroke.* 2006;37:2024–2029.
90. Teerlink T, Luo Z, Palm F, Wilcox CS. Cellular ADMA: regulation and action. *Pharmacol Res.* 2009;60:448–460.
91. Nunes Santiago A, Dias Fiuza Ferreira E, Weffort de Oliveira RM, Milani H. Cognitive, neurohistological and mortality outcomes following the four-vessel occlusion/internal carotid artery model of chronic cerebral hypoperfusion: the impact of diabetes and aging. *Behav Brain Res.* 2018;339:169–178.
92. Zhao BQ, Wang S, Kim HY, et al. Role of matrix metalloproteinases in delayed cortical responses after stroke. *Nat Med.* 2006;12:441–445.
93. Du SQ, Wang XR, Xiao LY, et al. Molecular mechanisms of vascular dementia: what can be learned from animal models of chronic cerebral hypoperfusion? *Mol Neurobiol.* 2017;54:3670–3682.
94. Buffo A, Rolando C, Ceruti S. Astrocytes in the damaged brain: molecular and cellular insights into their reactive response and healing potential. *Biochem Pharmacol.* 2010;79:77–89.
95. Sagare AP, Bell RD, Zlokovic BV. Neurovascular dysfunction and faulty amyloid β -peptide clearance in Alzheimer disease. *Cold Spring Harb Perspect Med.* 2012;2:a011452.
96. Besancon E, Guo S, Lok J, Tymianski M, Lo EH. Beyond NMDA and AMPA glutamate receptors: emerging mechanisms for ionic imbalance and cell death in stroke. *Trends Pharmacol Sci.* 2008;29:268–275.
97. Khalili M, Soltani M, Moghadam SA, Dehghan P, Azimi A, Abbaszadeh O. Effect of alpha-lipoic acid on asymmetric dimethylarginine and disability in multiple sclerosis patients: a randomized clinical trial. *Electron Physician.* 2017;9:4899–4905.