



Title	Effects of scatter correction processing on image quality of portable thoracic radiography in calves
Author(s)	Shimbo, Genya; Tagawa, Michihito; Matsumoto, Kotaro; Tomihari, Mizuki; Miyahara, Kazuro
Citation	Japanese Journal of Veterinary Research, 66(2), 105-112
Issue Date	2018-05
DOI	10.14943/jjvr.66.2.105
Doc URL	http://hdl.handle.net/2115/70496
Type	bulletin (article)
File Information	p105-112 Kazuro_Miyahara.pdf



[Instructions for use](#)

Effects of scatter correction processing on image quality of portable thoracic radiography in calves

Genya Shimbo¹⁾, Michihito Tagawa¹⁾, Kotaro Matsumoto²⁾,
Mizuki Tomihari²⁾ and Kazuro Miyahara^{1,*}

¹⁾ Veterinary Medical Center, Obihiro University of Agriculture and Veterinary Medicine, Inada, Obihiro, Hokkaido 080-8555, Japan

²⁾ Department of Veterinary Medicine, Division of Clinical Veterinary Medicine, Obihiro University of Agriculture and Veterinary Medicine, Inada, Obihiro, Hokkaido 080-8555, Japan

Received for publication, November 23, 2017; accepted, January 3, 2018

Abstract

Thoracic radiography provides diagnostic assistance in assessing the severity of lung lesions in bovine respiratory diseases. We investigated the effects of a novel scatter correction processing software on the image quality of portable thoracic radiography in calves: this scatter correction method was recently developed for mobile bedside chest radiography in humans. Thoracic radiographs of the caudodorsal region were obtained from 30 calves of various sizes. Scatter correction processing of a grid ratio of 3 : 1 or 8 : 1 was applied to each image. The delineation of caudal thoracic vertebral bodies, scapulae, proximal third of the ribs, pulmonary vessels, and the aortic arch, as well as overall image quality were graded by five veterinarians using 5-point scales. Three types of images (original and scatter-corrected with grid ratios of 3 : 1 and 8 : 1) were compared using visual grading characteristics analysis. Scatter correction with a grid ratio of 3 : 1 improved the overall image quality, at least for calves with a body thickness of ≤ 40 cm, and improved the delineation of some anatomical structures for larger calves. Scatter correction with a grid ratio of 8 : 1 did not improve the delineation of any anatomical structures examined for calves > 40 cm in thickness or the overall image quality for calves > 30 cm in thickness. The present findings support the efficacy of scatter correction processing with a grid ratio of 3 : 1 for portable thoracic radiography in calves.

Key Words: calf, image quality, portable, scatter correction processing, thoracic radiography

Introduction

Bovine respiratory disease (BRD) is one of the most common causes of morbidity and mortality in both pre-weaned and weaned calves, and has many negative long-term consequences, including decreased milk production, poor

reproductive performance, and poor growth, resulting in considerable economic loss^{12,22)}. The clinical diagnosis of BRD is usually based on clinical signs, increased rectal temperature, and abnormal lung sounds^{3,7)}.

Thoracic radiography can provide considerable assistance in diagnosing the severity of a lesion

*Corresponding author: Kazuro Miyahara, Veterinary Medical Center, Obihiro University of Agriculture and Veterinary Medicine, Inada, Obihiro, Hokkaido 080-8555, Japan
E-mail: miyahara@obihiro.ac.jp
doi: 10.14943/jjvr.66.2.105

associated with BRD^{6,8,17,28}). In calves, thoracic radiography can be performed using portable X-ray units capable of generating 80–100 kilovolts (kV) and 15–20 milliamperere (mA), such as many large-animal veterinarians commonly use^{2,6}). However, portable thoracic radiography faces a challenge in using anti-scatter grids. Because the focal spot and the grid are aligned manually, grid misalignment often occurs, and the complete benefit of using a grid is not realized. In addition, when a grid is used, the tube current (measured in milliamperere second: mAs) must be increased to compensate for the attenuation of scattered as well as some primary radiation by the grid. However, because portable units have low output, this means the exposure time must be lengthened, which increases the likelihood of motion artifacts. Conversely, when a grid is not used, the image contrast is reduced by the scattered radiation. These challenges in using grids also appear in mobile bedside chest radiography in human medicine, for which grid usage is controversial and inconsistent among practitioners^{11,18,24}). There have been several attempts to improve the image quality of mobile chest radiography by controlling grid alignment using hardware-based methods^{11,16}). However, these hardware-based alignment systems seem to be difficult to use in bovine radiography because the systems were designed for use in humans.

Recently, a novel software-based scatter correction method has been developed^{13,18,23,25}). The program estimates the amount of scattered radiation on the basis of the energy of the irradiated X-rays and the pixel values of the observed image and then subtracts the component due to the scattered X-rays¹⁴). Although the potential of this approach for contrast improvement and dose reduction in mobile chest radiography has been investigated using human chest phantoms^{18,23}), its effectiveness for portable thoracic radiography in calves remains unclear. The purpose of this study was to evaluate the effect of scatter correction processing on image quality in portable thoracic radiography in calves.

Materials and Methods

This study was approved by the Institutional Animal Care and Use Committee at the Obihiro University of Agriculture and Veterinary Medicine (Permit number: 28-189). Thirty healthy calves (29 females and 1 male) without clinical signs of respiratory disease were studied. The median age (range), body weight, and body thickness at the level of the last rib were 118.5 days (25–246), 124 kg (50.6–216), and 36.5 cm (20–44), respectively. The calves were classified into three categories based on body thickness; ≤ 30 cm ($n = 10$), 31–40 cm ($n = 11$), and > 40 cm ($n = 9$). During examination, the calves were restrained with a head halter in a chute, to which a flat-panel detector (FPD) system (CALNEO C 1417s and CONSOLE ADVANCE, Fuji Film Co., Ltd., Tokyo, Japan) was attached. Radiographic exposures were made with a portable X-ray unit (PORTA 380HF, JOB, Hyogo, Japan). The tube voltage, current, and source to image-receptor distance (SID) were set to 80 kV, 2.0 mAs, and 100 cm, respectively, in all experiments. The X-ray beam was collimated to cover the entire FPD (14 × 17 inch). Portable thoracic radiographs of the caudodorsal region were obtained from each calf. A software-based scatter correction algorithm (Virtual Grid, Fuji Film Co., Ltd.) was applied to the images using two settings (grid ratios of 3 : 1 and 8 : 1). The algorithm was calibrated to mimic the contrast enhancement of grids with the strip density = 40 lines/cm, interspace material = aluminum, and focusing distance = 100 cm. The remaining image processing parameters were used as recommended by the manufacturer, with density and contrast adjustments applied automatically. A total of 30 sets of images (original images, without scatter correction; VG3 images, with scatter correction for a grid ratio of 3 : 1; VG8 images, with scatter correction for a grid ratio of 8 : 1) were obtained (Fig. 1), and the exposure index (EI) of each original images were recorded. The EI was developed by the International Electrotechnical

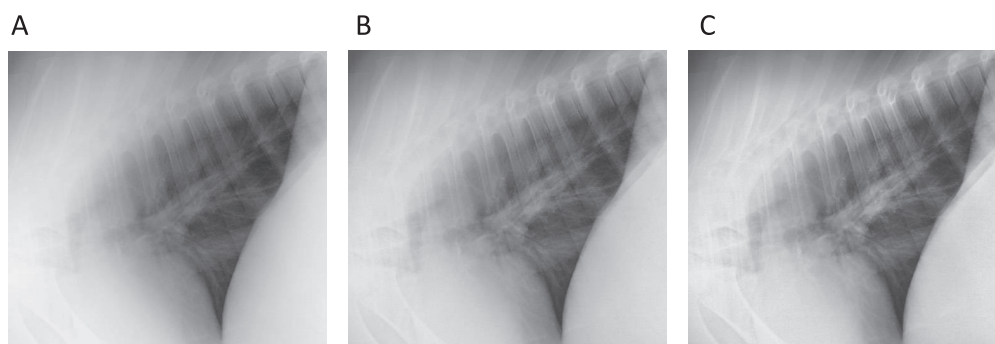


Fig. 1. Portable thoracic radiographs of a 27-cm-thick calf. (A) original image (with no scatter correction), (B) VG3 image, and (C) VG8 image.

Table 1. Definition of the delineation grading for relevant anatomical structures

Grading	Delineation of structures
5	The relevant structures are sharply demarcated and can be assessed surely.
4	The relevant structures are well demarcated to allow adequate assessment.
3	The relevant structures are demarcated, and an assessment is possible to a large extent.
2	The relevant structures are fairly demarcated, and an assessment is possible to some extent but not surely.
1	The relevant structures are poorly or not demarcated, and an assessment is not possible.

Commission in 2008, and is designed to generate a linear relationship between the index value and detector exposure⁵.

The images (DICOM format) were interpreted using OsiriX (Pixmeo, Gengeva, Switzerland) by five veterinarians who were blinded to the study aim and design. All three images of each calf were displayed simultaneously on two high-resolution (2 megapixel) liquid crystal 10-bit display monitors (RadiForce MX215, EIZO Corporation, Ishikawa, Japan) in a randomized order. One image was displayed on the left monitor and the other two on the right, at the same size. The evaluators were allowed to use processing tools, such as the window and level settings or magnification, as in standard clinical procedures. For image quality evaluation, visual grading analysis (VGA) was used in an absolute manner. VGA is a technique for assessing the image quality based on the visualization of clinically relevant normal structures¹⁵. The delineation of each of the following anatomical

structures was graded using a 5-point scale (Table 1): caudal thoracic vertebral bodies, scapulae, proximal third of the ribs, caudal lobar pulmonary vessels, and aortic arch. These structures were selected from both low- and high-attenuation areas. The images were then graded for overall diagnostic quality, using another 5-point scale (Table 2).

The differences in the image quality between the original and VG3 images or the original and VG8 images were analyzed using visual grading characteristics (VGC), which was introduced by Bath and Mansson because the analysis of rating data from ordinal scales requires non-parametric rank-invariant statistical analysis, and VGC fulfills this requirement¹. VGC handles visual grading data in a way similar to receiver operating characteristic (ROC) analysis, and the variations in the visual grading by the evaluators of two imaging techniques can be used to describe the variation between the two techniques in the same manner as in an ROC study. VGC analysis

Table 2. The grading system for overall image quality evaluation

Grading	Interpretation
5	excellent diagnostic quality
4	good, above average diagnostic quality
3	fair, acceptable diagnostic quality
2	poor, barely acceptable diagnostic quality
1	not of diagnostic quality

was performed in three steps. First, the numbers of images that scored each of the 5 points were assembled into 2×5 frequency tables, for the original and VG3 images or for the original and VG8 images. Second, the VGC data points were arranged according to the cumulative frequencies of images with score = 5, ≥ 4 , ≥ 3 , ≥ 2 , and ≥ 1 . Finally, the VGC points, including the origin, were plotted to produce VGC curves using software designed for obtaining ROC curves (ROCFIT: a web-based calculator for ROC curves; Baltimore: Johns Hopkins University [updated March 19, 2014; cited]. Available from: <http://www.rad.jhmi.edu/jeng/javarad/roc/JROCFITi.html>). As in an ROC curve, the origin of a VGC curve, by definition, is "0". The area under the curve (AUC_{VGC}), as well as the estimated standard deviation (SD) of AUC_{VGC} , were computed to quantify the difference in the image quality of the original and VG3 images or the original and VG8 images. A curve running along the diagonal, equivalent to an AUC_{VGC} of 0.5, indicates equality between the two techniques investigated. Larger AUC_{VGC} values (>0.5) indicate better image quality for the radiographic technique on the vertical axis of the plot. If $|AUC_{VGC} - 0.5| > 1.96 \text{ SD}$, the difference in the image quality was considered significant ($p < 0.05$)¹⁴. If $|AUC_{VGC} - 0.5| > 2.58 \text{ SD}$, the significance level was assigned as $p < 0.01$.

Results

The EI values for each body size are summarized in Table 3. The EI values increased

Table 3. Median EI values (interquartile range) for each body thickness

Body thickness (cm)	EI value
≤ 30	245 (216–288)
31–40	207 (165–237)
> 40	138 (93–174)

as the body size increased. Typical VGC curves are shown in Figure 2. The results of VGC analysis for specific anatomical structures are summarized in Table 4. The delineation of the caudal thoracic vertebrae and pulmonary vessels were significantly improved by the scatter correction processing, except in the VG8 images for calves >40 cm in thickness. The delineation of the scapulae was significantly improved in VG3 images for all size categories. However, in VG8 images, the delineation was not significantly improved for calves >30 cm in thickness. The delineation of the proximal third of the ribs was improved in VG3 images for calves ≤ 30 cm and in VG8 images for calves ≤ 40 cm. Scatter correction processing did not improve the delineation of the aortic arch for any size category. The overall image quality of VG3 images was significantly improved for calves ≤ 40 cm, however, that of VG8 images was improved only for calves <30 cm (Table 5). Scatter correction processing did not improve the overall image quality for calves >40 cm.

Discussion

The most common view of a radiographic image of the bovine thorax is the latero-lateral

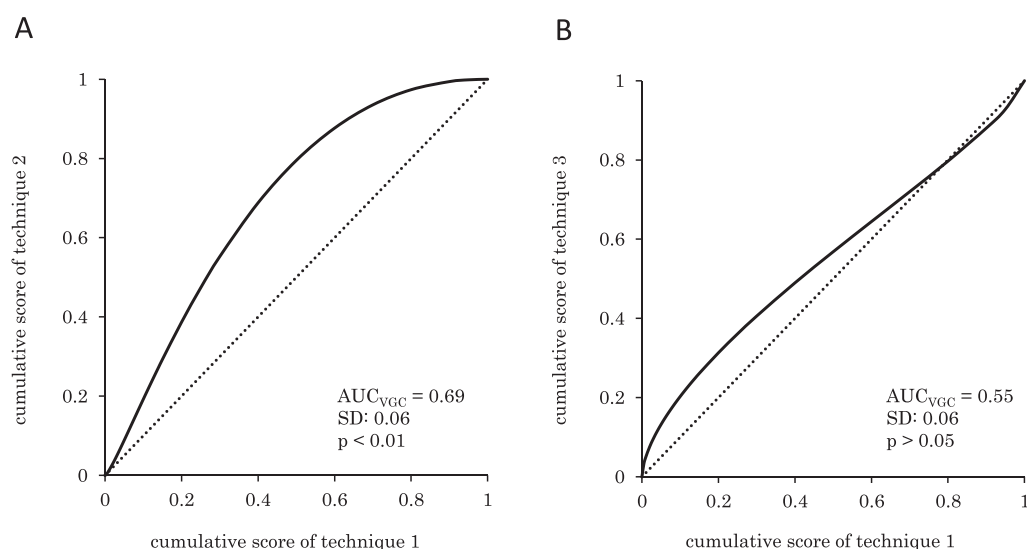


Fig. 2. Typical visual grading characteristics curves constructed from the scores for overall image quality of original images and VG3 images for calves ≤ 30 cm in thickness (A) or calves > 40 cm in thickness (B). The dotted line indicates the diagonal with equal performance.

Table 4. AUC_{VGC} (SD) for each anatomical structure, processing parameter, and body thickness

Anatomical structures	Processing Parameter	AUC_{VGC}		
		≤ 30 cm	31–40 cm	> 40 cm
Thoracic Vertebrae	VG3	0.63 (0.06)*	0.65 (0.05)**	0.64 (0.06)*
	VG8	0.65 (0.06)**	0.62 (0.06)*	0.62 (0.06)
Scapulae	VG3	0.66 (0.06)**	0.68 (0.05)**	0.64 (0.06)*
	VG8	0.62 (0.06)*	0.61 (0.06)	0.58 (0.06)
Ribs	VG3	0.62 (0.06)*	0.60 (0.06)	0.58 (0.06)
	VG8	0.66 (0.06)**	0.63 (0.06)*	0.58 (0.06)
Pulmonary vessels	VG3	0.71 (0.06)**	0.73 (0.05)**	0.66 (0.06)*
	VG8	0.72 (0.05)**	0.65 (0.06)**	0.55 (0.07)
Aortic arch	VG3	0.58 (0.06)	0.58 (0.06)	0.56 (0.07)
	VG8	0.60 (0.06)	0.55 (0.06)	0.56 (0.07)

* $P < 0.05$, ** $P < 0.01$ (vs original images)

VG3: scatter correction with a grid ratio of 3 : 1; VG8: scatter correction with a grid ratio of 8 : 1

horizontal view²¹) and a large (14 × 17 inch) film is required to obtain thoracic radiographs even for small calves. In one study, the scatter-to-primary ratio strongly depended on fields of view but weakly on tube voltage¹⁰. Therefore, although the tube voltage used in this study was relatively low (80 kV), scatter radiation is presumed to have been generated to a significant extent, with a consequent deterioration in image contrast. When using anti-scatter grids for portable radiography,

a decrease in the incident dose and grid misalignment are two major considerations^{16,27}. In digital radiography, the use of anti-scatter grids improves image quality without any need to increase tube current, as long as the incident dose is sufficient²⁰. This is the case when scatter correction processing is used¹³. Grid misalignment and the resulting grid cutoff, an undesirable absorption of the primary X-ray beam by the grid strips, are almost inevitable in portable

Table 5. AUC_{VGC} (SD) for overall image quality for each processing parameter and body thickness

Processing Parameter	AUC _{VGC}		
	≤30 cm	31–40 cm	>40 cm
VG3	0.69 (0.06)**	0.64 (0.05)*	0.55 (0.06)
VG8	0.64 (0.06)*	0.48 (0.06)	0.54 (0.06)

* $P < 0.05$, ** $P < 0.01$ (vs original images)

radiography¹⁶). Although a low-ratio (3 : 1) grid has wider angle tolerance²⁶, the contrast improvement factor of the grid decreases as the grid misalignment angle increases⁴. In contrast, scatter correction processing is free of grid cutoff²³. Indeed, the contrast-to-noise ratio for scatter correction-processed images did not change markedly even when the incidence angle became larger²⁵. For these reasons, although anti-scatter grids provided better image contrast than scatter correction processing when the tube-detector alignment is perfect^{13,23}, scatter correction processing seems to be suitable for portable thoracic radiography in calves.

In our study, compared with the original images, the use of scatter correction processing significantly improved the delineation of the anatomical structures examined of calves ≤30 cm, except for the aortic arch. In contrast, in addition to the aortic arch, the delineation of the scapulae in VG8 images of calves 31–40 cm and that of all structures examined in VG8 images of calves >40 cm were not improved, suggesting that contrast improvement did not outweigh the deterioration of image noise. The aortic arch is surrounded by the shoulders, which from the thickest part of the cranial thorax, and the scapulae are surrounded by forelimb musculature. Therefore, it is believed that the radiographic parameters used in this study (80 kV and 2 mAs) could not provide a sufficient incident dose to the image receptor for the scatter correction-processed images with a grid ratio of 8 : 1, for large calves or high-attenuation areas. In one study using human thoracic phantom, the EI values ≥250 were considered to be diagnostic range²³. Although the diagnostic range of the EI

value for thoracic radiography in calves are yet to be established, the EI values of the images of calves larger than 30 cm in thickness in this study appeared to be low. The X-ray unit used in this study had a maximum available tube setting of 80 kV and 15 mA, and exposure times longer than 0.13 s seemed to result in susceptibility to respiratory motion artifacts. Therefore, the radiation dose used in this study could not be increased. If a more powerful portable X-ray unit or shorter SID is used, the performance of scatter correction processing would be better because large patient anatomy implies a high scatter-to-primary ratio, and the use of grids is recommended for obese patients^{9,19}. The delineation of ribs for calves 31–40 cm was improved in VG8 images but not in VG3 images. This result cannot be explained by image noise. Variability in the superimposition of ribs or respiratory motion might affect the interpretation, although only the proximal third of the ribs was evaluated considering respiratory motion artifacts. The overall image quality was improved in VG3 images for calves ≤40 cm. For calves >40 cm, although the overall image quality was not significantly improved in VG3 images, the delineation of several anatomical structures was improved. Considering that the overall image quality of VG8 images was improved only for calves ≤30 cm, scatter correction with a grid ratio of 3 : 1 seems to be suitable for portable thoracic radiography in calves with radiographic technique used in this study.

This study has several limitations. First, the original images were readily distinguishable from scatter correction-processed images by observers because of their low contrast. Although the images

were displayed in random order to minimize this effect, this study could not be performed in a completely blinded manner. Second, the results concerning the grid performance for portable thoracic radiography in calves are applicable only to calves with a body thickness of ≤ 44 cm, which were the largest calves included in this study. As calves mature, their body thickness increases, limiting the penetration of X-rays. Therefore, the effect of scatter correction processing on image quality for larger calves would be reduced because of the lower incident dose to the image receptor. Third, we compared only two parameter settings of scatter correction. Several options are available in each parameter such as grid ratio, line density, or interspace material in the software, and therefore a more suitable setting could exist. However, the increase in the number of images lead to the burden on the evaluators, which could result in the inaccurate grading. Finally, the image quality was evaluated using VGC, which is based on the visibility of normal structures and does not assess diagnostic efficacy^{1,15}. Notably, one must be careful in generalizing the present findings to clinical settings.

In conclusion, scatter correction processing with a grid ratio of 3:1 improved the overall image quality of portable thoracic radiographs of the caudodorsal region, at least in calves with a body thickness of ≤ 40 cm, and improved the delineation of some anatomical structures in calves with a body thickness of 41–44 cm, which was the largest sizes included in this study. A grid ratio of 3:1 appeared more suitable than that of 8:1 because of the low output of the portable X-ray unit. Further studies should evaluate whether scatter correction processing actually improves diagnostic efficacy in patients with thoracic diseases.

References

- 1) Båth M, Månsson LG. Visual grading characteristics (VGC) analysis: a non-parametric rank-invariant statistical method for image quality evaluation. *Br J Radiol* 80, 169–176, 2007
- 2) Brown M, Brownrigg S. Equine and Large Animal Radiography. In: *Lavin's Radiography for Veterinary Technicians*. 5th ed. Brown M, Brown L. eds. Saunders, St. Louis. pp. 400–463, 2013.
- 3) Buczinski S, Forté G, Francoz D, Bélanger AM. Comparison of thoracic auscultation, clinical score, and ultrasonography as indicators of bovine respiratory disease in preweaned dairy calves. *J Vet Intern Med* 28, 234–242, 2014
- 4) Carlin MD, Nishikawa RM, MacMahon H, Doi K. The effect of x-ray beam alignment on the performance of antiscatter grids. *Med Phys* 23, 1347–1350, 1996
- 5) Cohen MD, Cooper ML, Piersall K, Apgar BK. Quality assurance: using the exposure index and the deviation index to monitor radiation exposure for portable chest radiographs in neonates. *Pediatr Radiol* 41, 592–601, 2011
- 6) Constable PD, Hinchcliff KW, Done SH, Gruenberg W. *Veterinary Medicine: A textbook of the diseases of cattle, horses, sheep, pigs and goats*, 11th ed. Saunders, St. Louis. pp. 845–1094, 2017
- 7) Divers TJ. Respiratory diseases. In: *Rebhun's Diseases of Dairy Cattle*, 2nd ed. Divers TJ, Peek SF. eds. Saunders, St. Louis. pp. 79–129, 2007.
- 8) Farrow CS. Bovine Pneumonia: Its Radiographic Appearance. *Vet Clin North Am Food Anim Pract* 15, 301–358, 1999
- 9) Fetterly KA, Schueler BA. Experimental evaluation of fiber-interspaced antiscatter grids for large patient imaging with digital x-ray systems. *Phys Med Biol* 52, 4863–4880, 2007
- 10) Fritz S, Jones AK. Guidelines for anti-scatter grid use in pediatric digital radiography. *Pediatr Radiol* 44, 313–321, 2014
- 11) Gauntt DM, Barnes GT. An automatic and accurate x-ray tube focal spot/grid alignment system for mobile radiography: system description and alignment accuracy. *Med Phys* 37, 6402–6410, 2010
- 12) Gorden PJ, Plummer P. Control, management, and prevention of bovine respiratory disease in dairy calves and cows. *Vet Clin North Am Food Anim Pract* 26, 243–259, 2010
- 13) Ichikawa H, Ono T, Sawane Y, Terabe M, Yamaguchi M, Shimada H. Examination for effectiveness of scatter correction in portable

1) Båth M, Månsson LG. Visual grading

- chest radiography. *Nihon Hoshasen Gijutsu Gakkai Zasshi* 72, 1207–1215, 2016.
- 14) Kawamura T, Naito S, Okano K, Yamada M. Improvement in image quality and workflow of x-ray examinations using a new image processing method, “Virtual Grid Technology”. *Fujifilm Research & Development* 60, 21–27, 2015
 - 15) Ludewig E, Richter A, Frame M. Diagnostic imaging-evaluating image quality using visual grading characteristic (VGC) analysis. *Vet Res Commun* 34, 473–479, 2010
 - 16) MacMahon H, Yasillo NJ, Carlin M. Laser alignment system for high-quality portable radiography. *Radiographics* 12, 111–120, 1992
 - 17) Masseur I, Fecteau G, Breton L, Hélie P, Beauregard G, Blond L. Radiographic detection of thoracic lesions in adult cows: a retrospective study of 42 cases (1995–2002). *Can Vet J* 49, 261–267, 2008
 - 18) Mentrup D, Jockel S, Menser B, Neitzel U. Iterative scatter correction for grid-less bedside chest radiography: performance for a chest phantom. *Radiat Prot Dosimetry* 169, 308–312, 2016
 - 19) Moore CS, Avery G, Balcam S, Needler L, Swift A, Beavis AW, Saunderson JR. Use of a digitally reconstructed radiograph-based computer simulation for the optimisation of chest radiographic techniques for computed radiography imaging systems. *Br J Radiol* 85, e630–639, 2012
 - 20) Moore CS, Wood TJ, Avery G, Balcam S, Needler L, Smith A, Saunderson JR, Beavis AW. Investigating the use of an antiscatter grid in chest radiography for average adults with a computed radiography imaging system. *Br J Radiol* 88, 20140613, 2015
 - 21) Morgan JP. *Techniques of Veterinary Radiography*, 5th ed. pp. 383–432, Wiley-Blackwell, Oxford, 1993.
 - 22) Poulsen KP, McGuirk SM. Respiratory disease of the bovine neonate. *Vet Clin North Am Food Anim Pract* 25, 121–137, 2009
 - 23) Renger B, Brieskorn C, Toth V, Mentrup D, Jockel S, Lohöfer F, Schwarz M, Rummeny EJ, Noël PB. Evaluation of dose reduction potentials of a novel scatter correction software for bedside chest x-ray imaging. *Radiat Prot Dosimetry* 169, 60–67, 2016
 - 24) Scott AW, Gauntt DM, Yester MV, Barnes GT. High-ratio grid considerations in mobile chest radiography. *Med Phys* 39, 3142–3153, 2012
 - 25) Suzuki R, Goto T, Ogawa H, Amimoto N. Evaluation of no-grid radiography using the digital scattered x-ray removal processing. *Proceedings of ECR 2016*. Vienna, March 2016. 10.1594/ecr2016/C-0416, 2016
 - 26) Takigawa A, Mukai N, Nishihara S. Evaluation of anti-scatter grids for bedside chest radiography. *Journal of The Society of Photographic Science and Technology of Japan* 61, 207–211, 1998. Japanese.
 - 27) Tanaka N, Naka K, Saito A, Morishita J, Toyofuku F, Ohki M, Higashida Y. Investigation of optimum anti-scatter grid selection for digital radiography: physical imaging properties and detectability of low-contrast signals. *Radiol Phys Technol* 6, 54–60, 2013
 - 28) Tegtmeier C, Arnbjerg J. Evaluation of radiology as a tool to diagnose pulmonic lesions in calves, for example prior to experimental infection studies. *J Vet Med B Infect Dis Vet Public Health* 47, 229–234, 2000