



Title	Morphology of the inferior border of the mandible: correct relation between the lowest position of the outer and inner contours of the cortex for a successful split
Author(s)	Matsushita, Kazuhiro; Donen, Masaki; Harata, Saori; Nagamine, Kyosuke; Tei, Kanchu
Citation	British journal of oral and maxillofacial surgery, 55(5), 540-541 <a href="https://doi.org/10.1016/j.bjoms.2017.03.012">https://doi.org/10.1016/j.bjoms.2017.03.012</a>
Issue Date	2017-06
Doc URL	<a href="http://hdl.handle.net/2115/70692">http://hdl.handle.net/2115/70692</a>
Rights	© 2017. This manuscript version is made available under the CC-BY-NC-ND 4.0 license <a href="http://creativecommons.org/licenses/by-nc-nd/4.0/">http://creativecommons.org/licenses/by-nc-nd/4.0/</a>
Rights(URL)	<a href="http://creativecommons.org/licenses/by-nc-nd/4.0/">http://creativecommons.org/licenses/by-nc-nd/4.0</a>
Type	article (author version)
File Information	Br. j. oral maxillofac. surg_55.pdf



[Instructions for use](#)

Morphology of the inferior border of the mandible: The relationship between the lowest position of the outer and inner contours of the cortex for a successful split

Kazuhiro Matsushita, DDS, PhD., Masaki Donen\*, DDS, PhD., Saori Harata, DDS, Kyosuke Nagamine, DDS, PhD., Kanchu Tei, DDS, PhD.

Department of Oral and Maxillofacial Surgery  
Division of Oral Pathobiological Science  
Graduate School of Dental Medicine, Hokkaido University  
N13 W7, Kita-ku, Sapporo, Hokkaido 060-8586, Japan.

\*Department of Dentistry and Oral surgery, Kushiro Red Cross Hospital  
21-14 Sin-ei cho, Kushiro, Hokkaido 085-8512, Japan.

Corresponding author: Kazuhiro Matsushita  
Tel/fax: +81-11-706-4283  
E-mail: matsushi@den.hokudai.ac.jp

Title:

Morphology of the inferior border of the mandible: The relationship between the lowest position of the outer and inner contours of the cortex for a successful split

## Abstract

For the secure sagittal split ramus osteotomy, the relationship between the outer and inner contours of the cortex at the inferior border of the mandible was evaluated. The lowest point of the outer contour is not always immediately below that of the inner contour, and the former is placed more lingually with respect to the latter in about 30% of all cases. This tendency is much more noticeable in the case of skeletal class I and II compared to class III. Therefore, it is important to examine the lowest point of the inferior border in every case and to carry the inferior part of the buccal cut onto the lingual side based on the morphology.

**Key words;** ramus osteotomy, inferior border.

## Introduction

To avoid an unfavourable sagittal split of the ramus and ensure post-operative stability, a short lingual osteotomy is one of the possible options<sup>1</sup>. To achieve a successful split, the vertical osteotomy should be performed on the buccal cortex and extended through the inferior border, including a few mm of the lingual cortex. However, the contour of the inner cortex does not always correspond to that of the outer cortex at the inferior border, and the lingual aspect would not be directly visible because of the inferior border. Therefore, the appropriate degree of lingual extension should be carefully estimated by observing the contour of the inner aspect of the cortex, and by paying attention to the subtle change in the cutting sensation. Once misjudgements regarding the appropriate degree of lingual extension occur, a split is performed sequentially on the buccal side of the inferior border and an unfavourable fracture may occur. In this study, the morphology of the inferior border of the mandible and the association with different skeletal classes were evaluated.

## Methods

The study involved 100 consecutive patients with jaw deformities who were treated at the Hokkaido university hospital from 1 January 2014 to 24 March 2015. We included data for both sides of the mandible of each patient, which involved analyses of 200 buccolingual relationships. The ages of the patients ranged from 16 to 59 years (mean: 27.4 years).

The buccolingual relationships were evaluated based on each patient's pre-operative coronal computed tomography (CT) scan. These scans were each reconstructed perpendicular to the Frankfurt plane through the contact points between the first and second molars. The buccolingual relationships were categorised into three groups according to the position of the lowest point of the outer contour with respect to that of the inner contour: lingual (Fig. 1), immediately-below (Fig. 2), and lateral groups .

Skeletal class of their original malocclusion was also evaluated. Skeletal class I, II, and III were defined as malocclusions involving ANB angle of between -1.0 SD and +1.0 SD, over +1.0 SD, and under -1.0 SD, respectively. The numbers of patients were 4, 8, and 88 in this order. The association between buccolingual relationships was examined by Fisher's exact test.

### Results

Of the 200 buccolingual relationships evaluated, 68% were classified as immediately-below and 32% were classified as lingual (Table 1). None of the buccolingual relationships was classified as lateral. The type of buccolingual relationship was associated with the skeletal class of the original malocclusion although the number of skeletal class I and II were small. The lingual relationship was seen more than immediately-below relationship in skeletal class I and II, and the opposite tendency was seen in the skeletal class III ( $p < 0.05$ ).

### Discussion

In the case with immediately-below relationship, lingual extension is not so difficult and even achieved without special intention. In the case with lingual relationship, however, sufficient lingual extension should be carried out with much considerable intention. To secure a desirable split, preoperative evaluation and intentional lingual extension, if required, are indispensable. In this study, the number of skeletal class III is much higher than other two classes, because Japanese patients with protognathia want treatment more frequently than those with retrognathia. Therefore, the number of skeletal class III exerts substantial impact on the percentage of overall frequency, and eventually 32% of all patients are lingual relationship, although this relationship is much higher in both skeletal class I and II. The frequency may differ among ethnic groups and further study is necessary in other ethnics, but this notion will be a reference for a successful sagittal split.

## Conflict of interest

The authors have no conflicts of interest to declare.

## References

1. Hunsuck EE. A modified intraoral sagittal splitting technic for correction of mandibular prognathism. *J Oral Surg* 1968;26:250-3.

## Legends

### Fig. 1.

Representative cases with lingual buccolingual relationships between the lowest position of the outer contour (arrow) and inner contour (arrow head) of the cortex. The relationship is defined as the position of the lowest point of the outer contour with respect to that of the inner contour.

### Fig. 2

Representative cases with immediately-below buccolingual relationships between the lowest position of the outer contour (arrow) and inner contour (arrow head) of the cortex.

### Table 1.

Overall frequencies of the three buccolingual relationships and differences according to the three skeletal classes of original malocclusion.

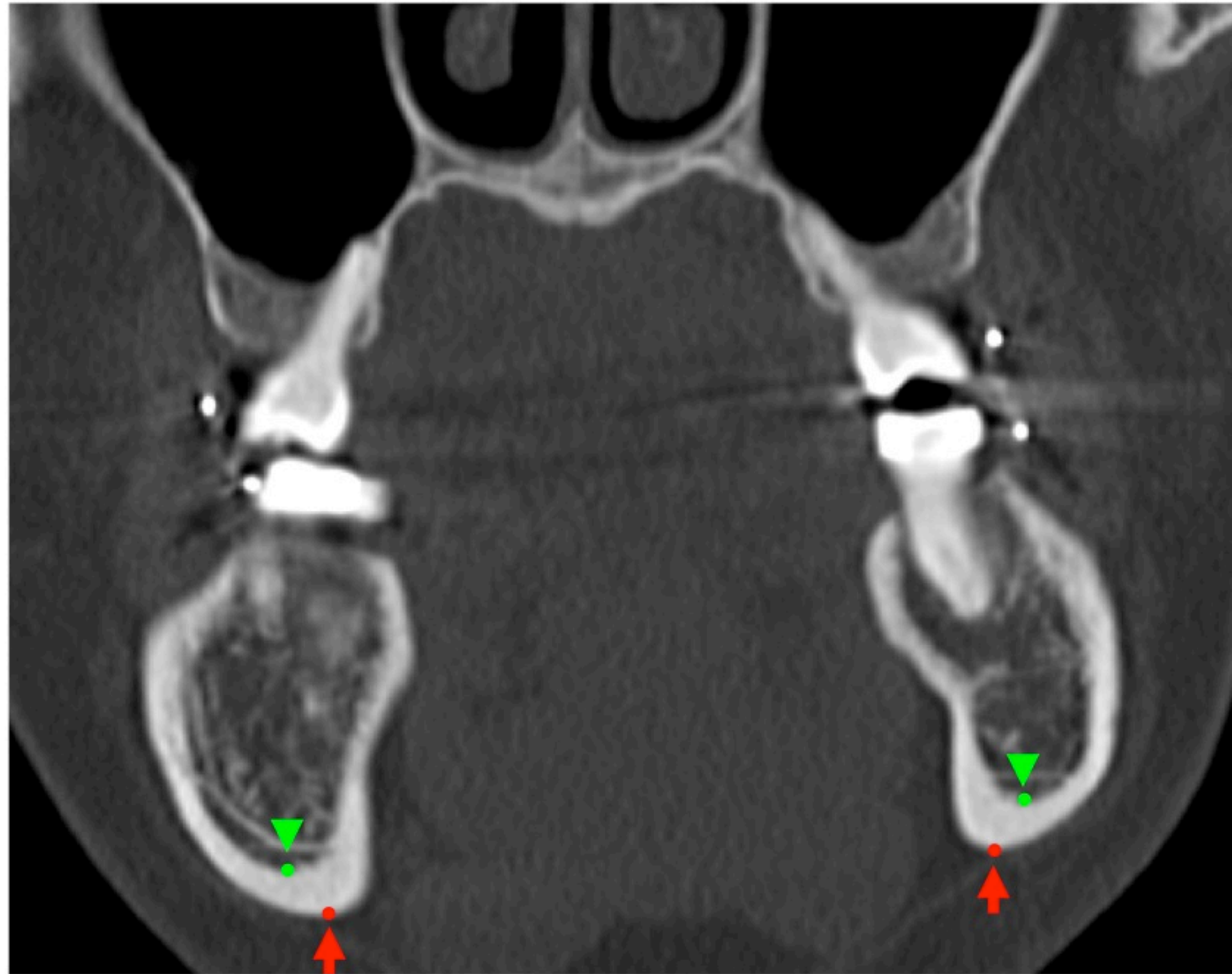

Fig. 1



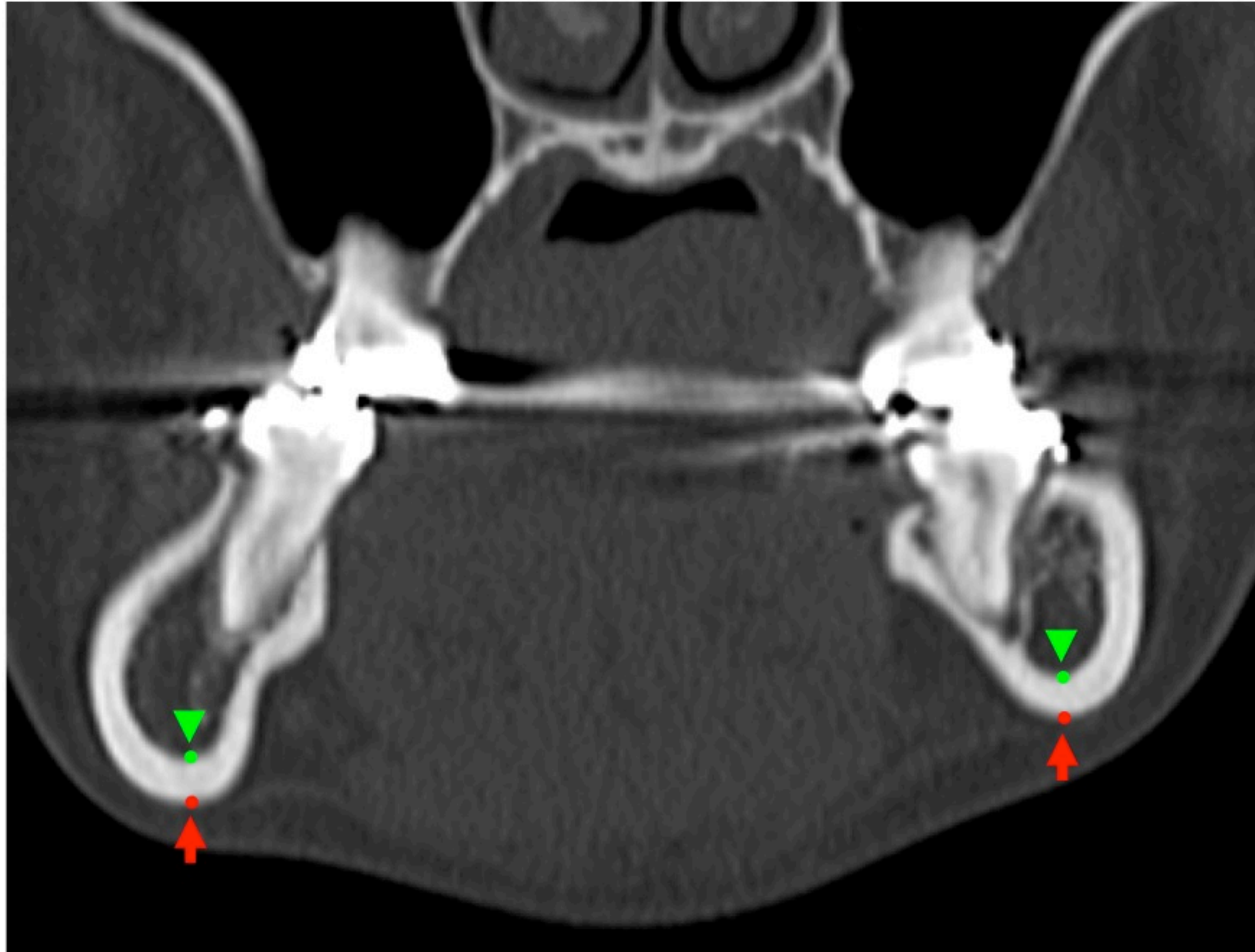


Fig. 2

Skeletal class	Relation		
	Immediately-below (n=136)	Lingual (n=64)	
I	2	6	
II	6	10	
III	128	48	

\*P<0.05