



**Goce Delčev University of Štip
Faculty of Medical Sciences**

POSTOPERATIVE COMPLICATIONS AFTER EXTRACION OF IMPACTED LOWER THIRD MOLAR

Author: Zlatko Maksimov

Co-author: Aleksandra Miteva

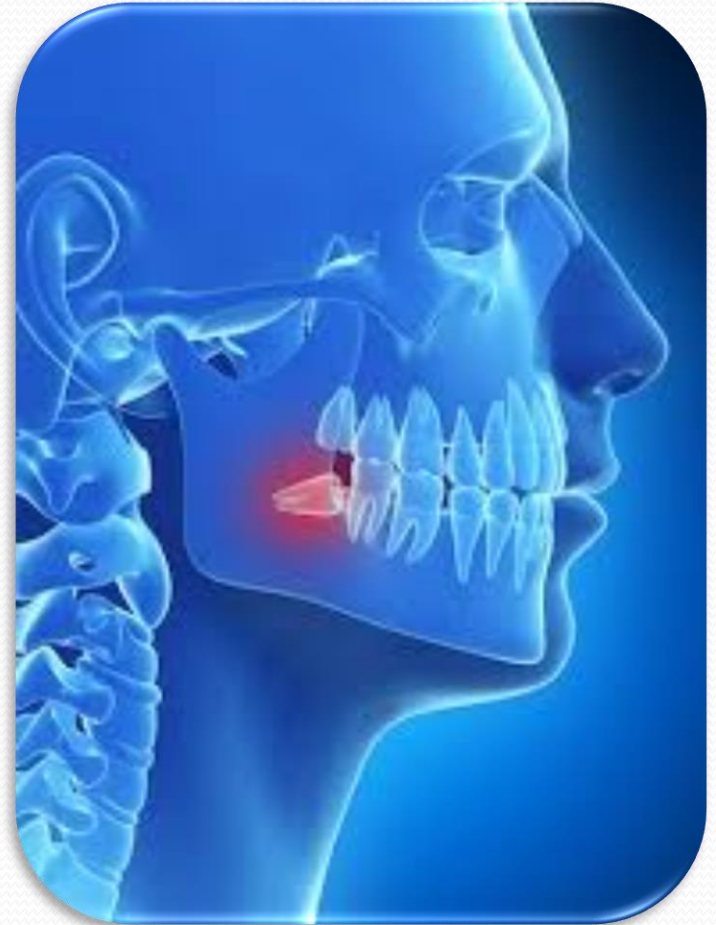
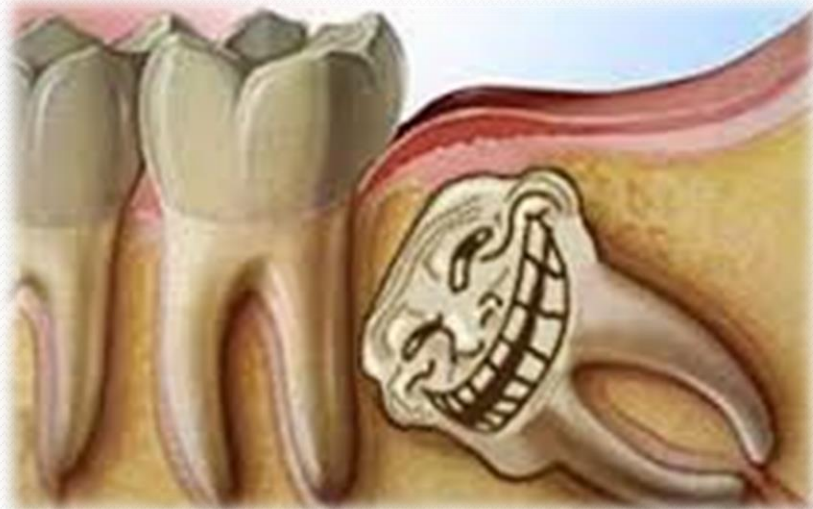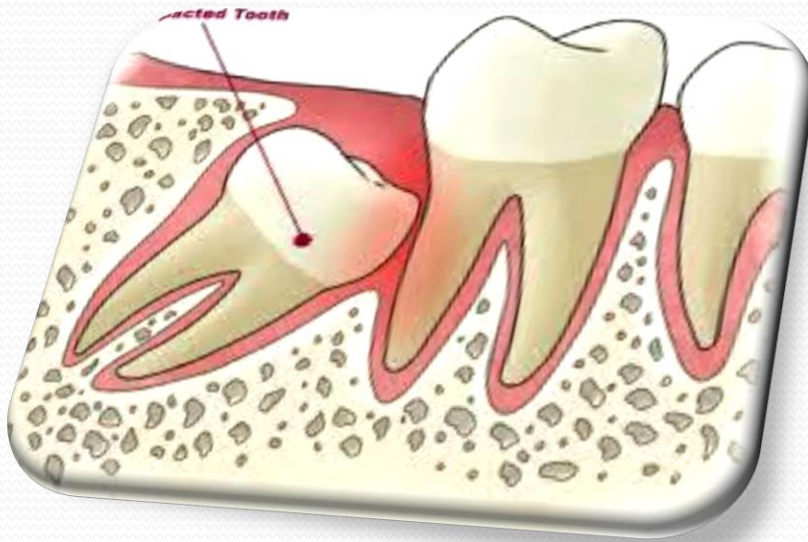
Mentor: Prof. d-r Cena Dimova

Impacted –Wisdom teeth meaning

The term impacted, retained, occluded tooth is a tooth that has not been protruded, and it's eruption is disabled in some ways.

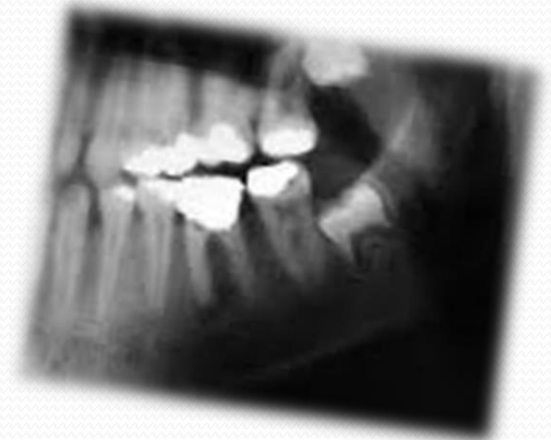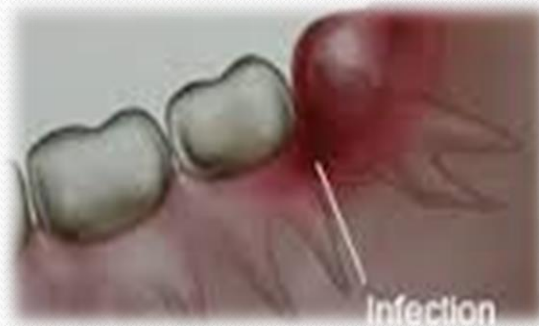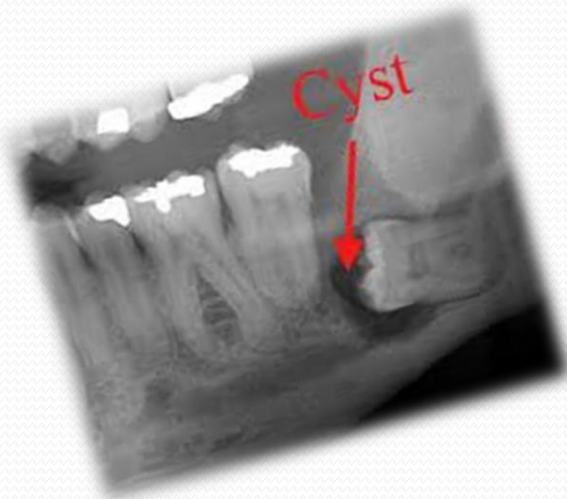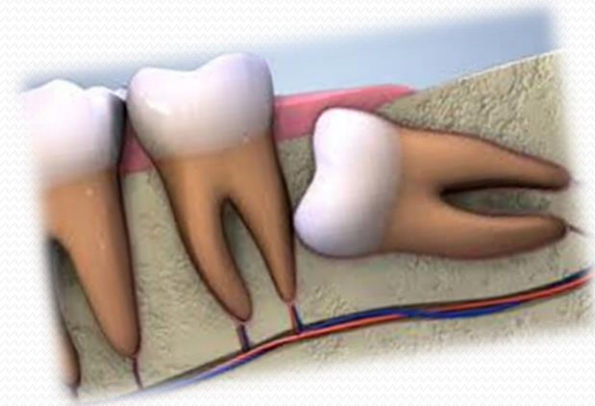
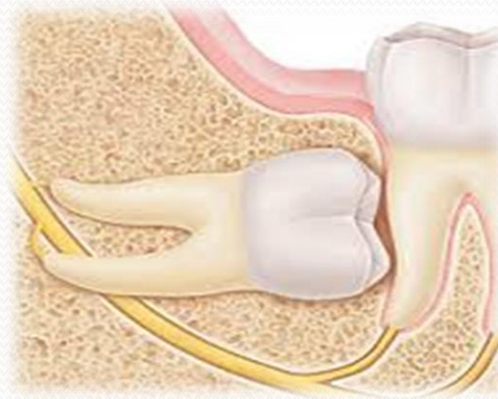
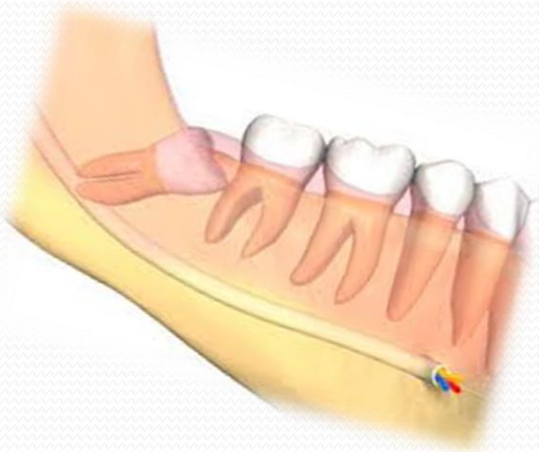
Wisdom teeth - 15 % of the population



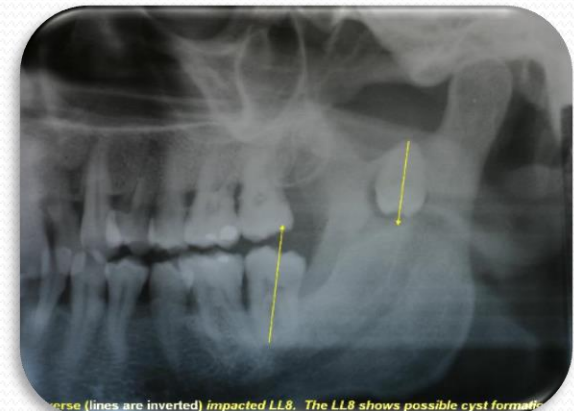
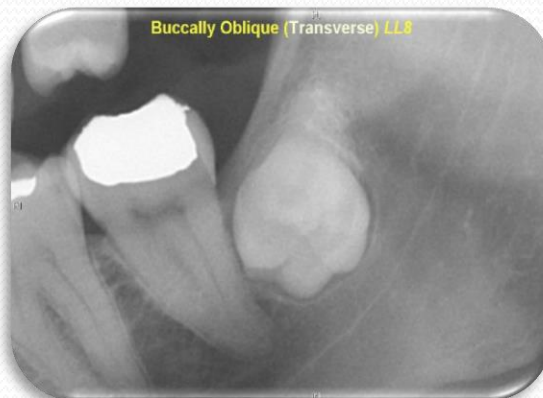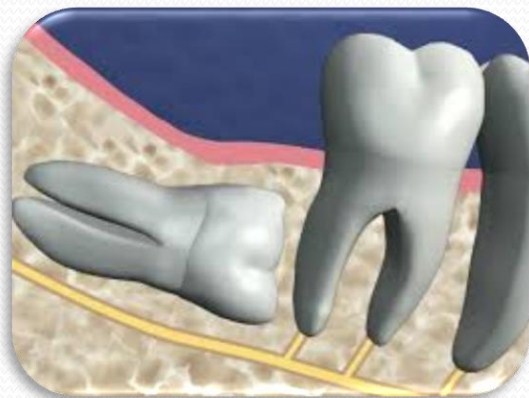
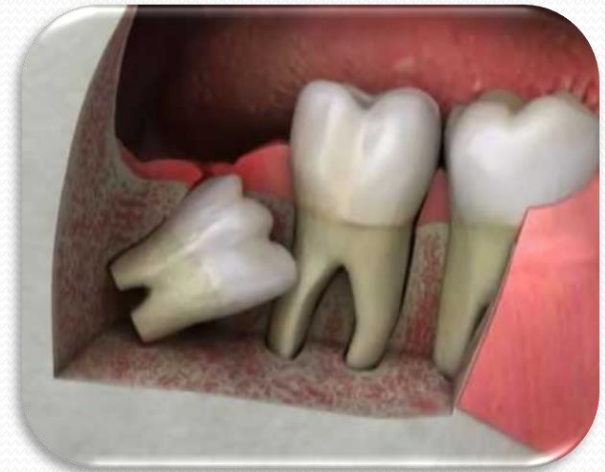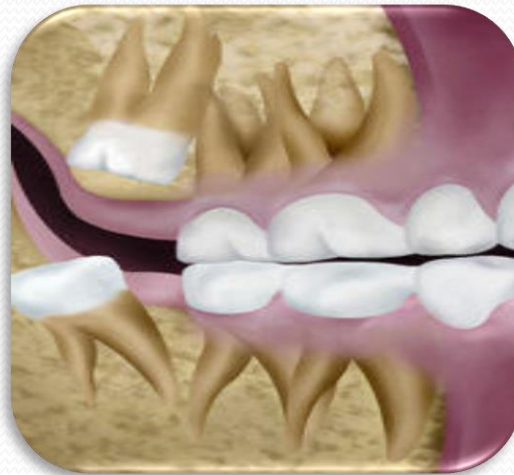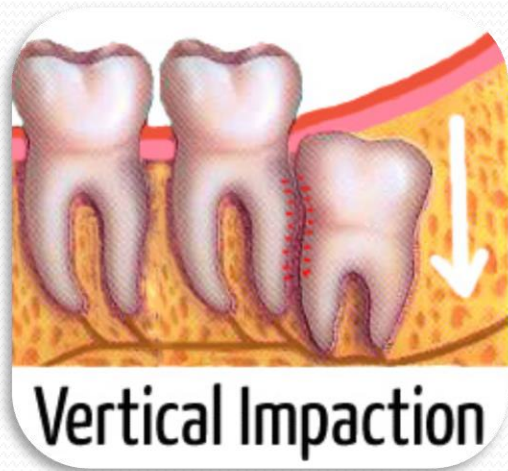
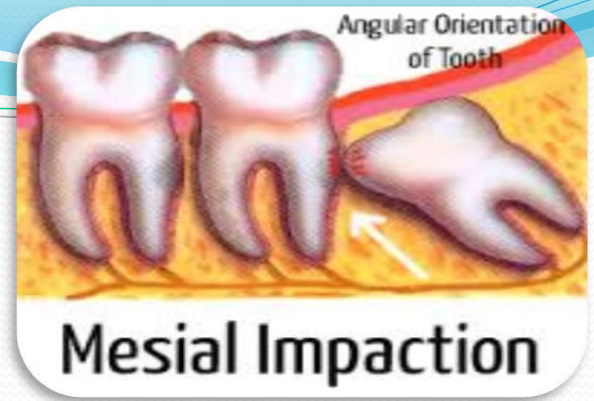


Impacted wisdom teeth

Causes

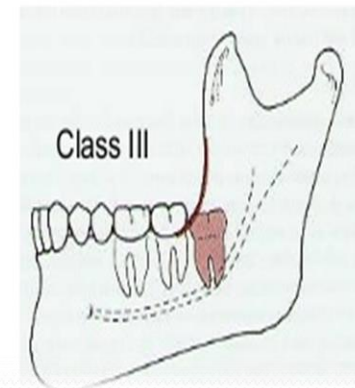
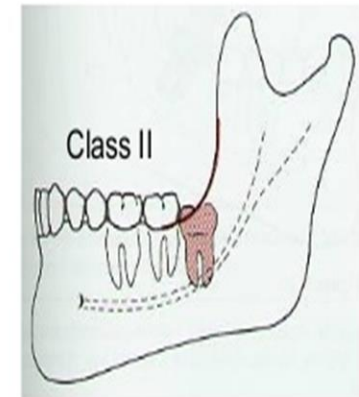
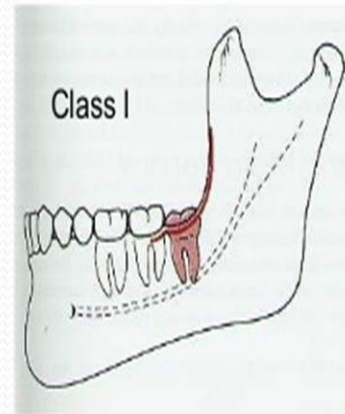


Lower wisdom teeth impactation in the lower jaw is usually described by **Winter** classification



Pell and Gregory classification

- The main criterion used to complete this classification of wisdom teeth in the lower jaw according to Pell and Gregory is the available space between distal surface of the lower second molar and the front edge of the ramus mandibule.



The most frequent postoperative complications after the extraction of an impacted third molar are:


- pain,
- swelling,
- bleeding,
- trismus,
- infections,
- prolonged healing of the wound,
- sensory disorders of n. alveolaris inferior.

PAIN

- It reaches its maximum in 3-5 hours after the intervention, at the moment when the anesthetic effect disappears.
- The pain should be minimal, and in all other cases it is a result of another complication.
- Mild antiseptics such as paracetamol, codeine, aspirin or if necessary use of non-steroidal anti-inflammatory drugs.
- If pain persists after 24-48 hours the cause agent should be found, and avoid covering the pain with stronger analgesics.

Swelling-edema

- Occurs as a result of a direct injury to blood and lymphatic vessels during the operative grip and accumulation of tissue fluid in the operated region, in rough handling and tightly seam joints.
- The most intense edema occurs after impacted third molar extraction and cystectomy and lasts from 3- 7 days.



● **Less frequent complications are:**

- displacement of the tooth,
- injury to a neighboring tooth or structures,
- injuries or disorders of the tempo-mandibular joint,
- mandible fracture,
- aspiration or ingestion of the tooth

AIM

- *The main aim was to determine how the surgical removal of impacted lower third molar affects the postoperative healing and quality of life. Determination of the most common complications that impair healing and quality of life is done*



Material and method

Detailed history and clinical examination

X-ray

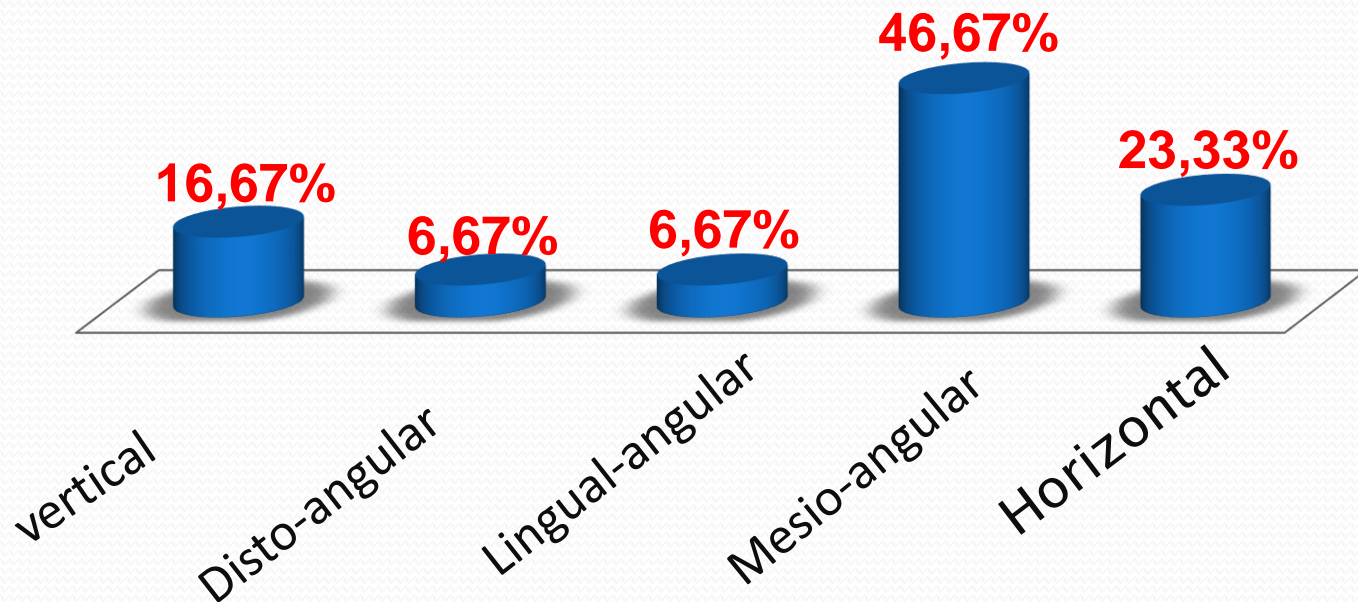
Control clinical examinations

In order to observe the most common complications of the subjects were called for checkup. Among subjects check-ups were performed in the first, second, seventh and tenth day after the intervention. During the examination by the subjects noted the presence of :

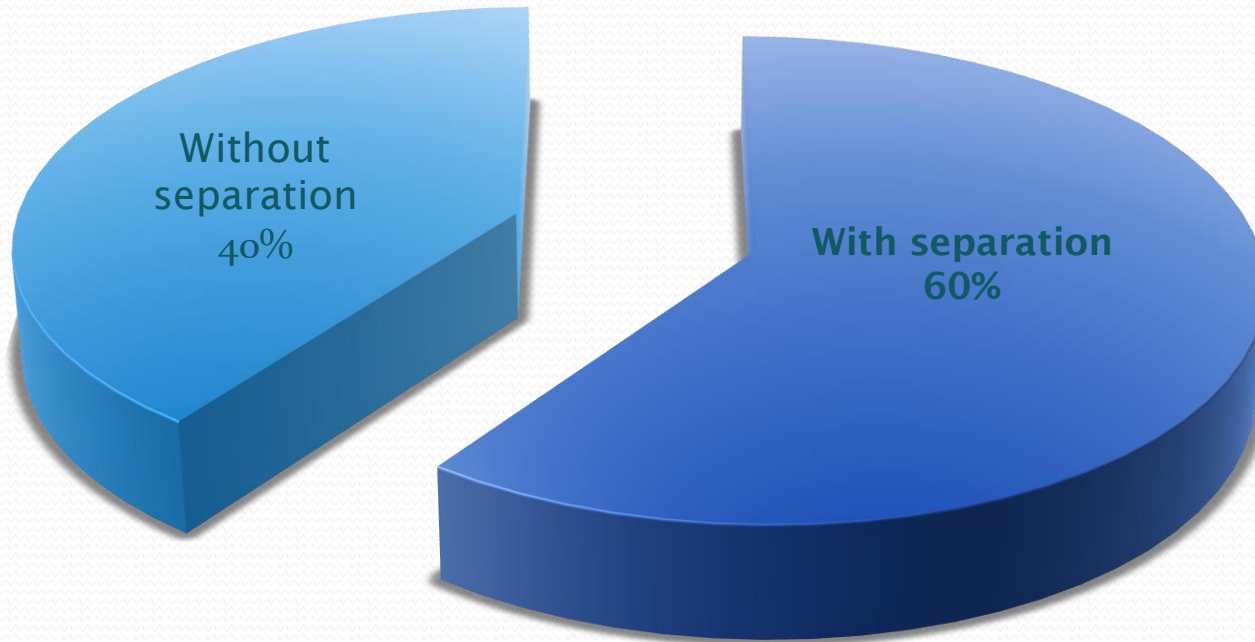
- pain,
- bleeding,
- discomfort,
- difficulty in opening of the mouth,
- swelling and
- redness.

RESULTS

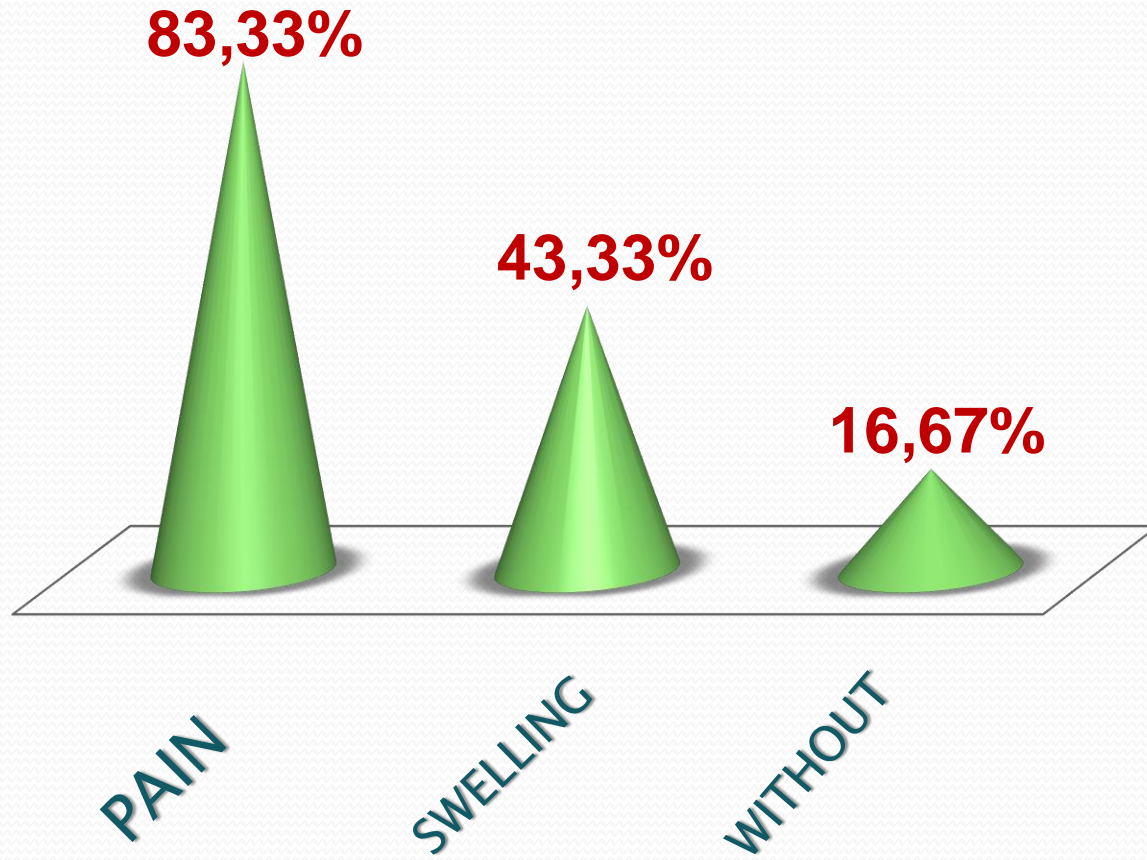
- During my research i discovered some very important statistics about the most frequent positions of impacted third molar or the extraction tehnique .



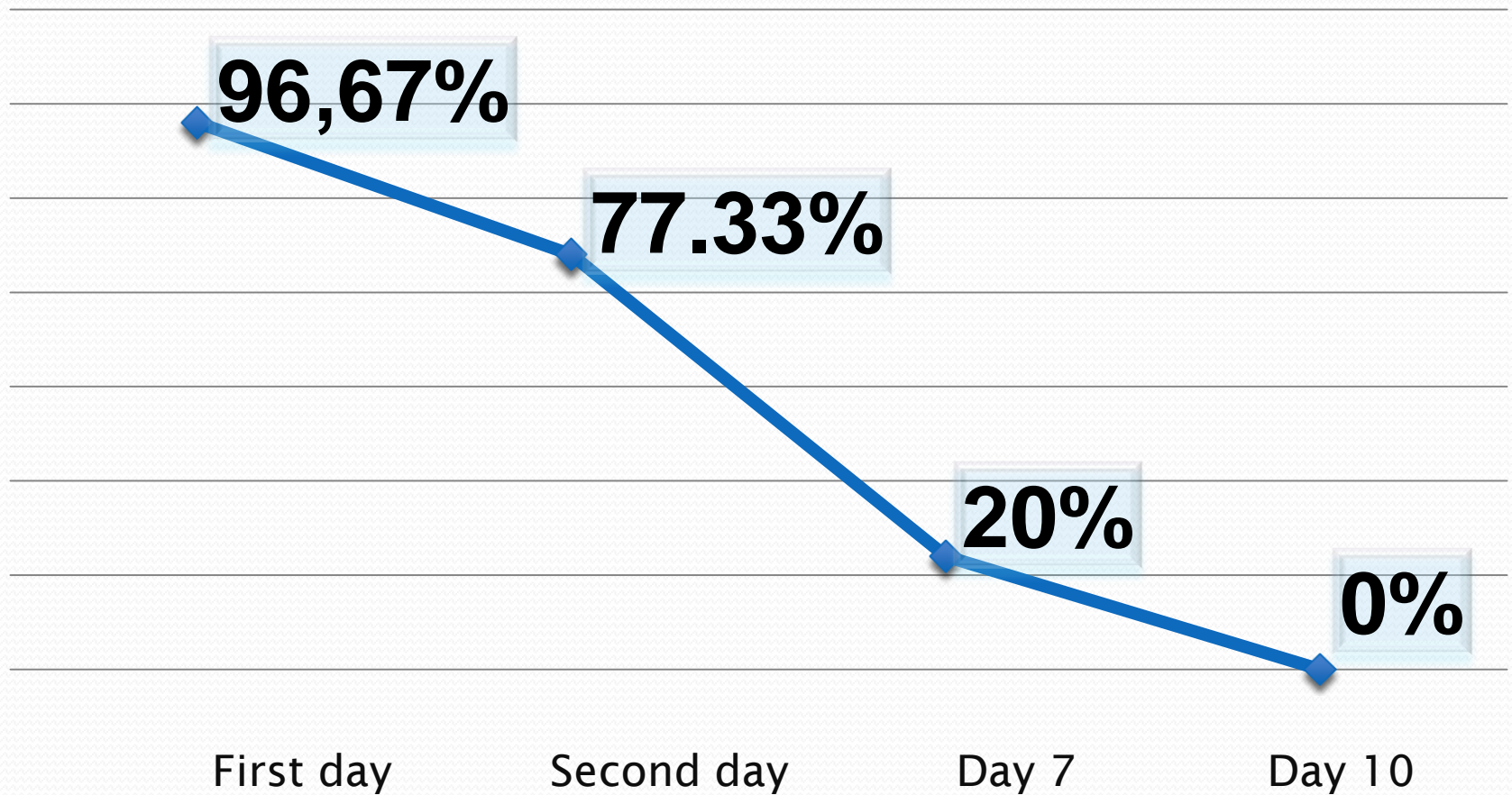
● Extraction technique



Main disadvantages



Presence of pain during control checkups



Conclusion

Based on the collected data and subsequent analysis, we can make this conclusion - because of the high incidence of complications, it can be noted that they affect the daily life and hence a violation of the quality of life of people.





THANK YOU FOR
YOUR ATTENTION