

## ORIGINAL ARTICLE

# The risk of incidental gallbladder cancer is negligible in macroscopically normal cholecystectomy specimens

Hanna Koppatz<sup>1</sup>, Arno Nordin<sup>2</sup>, Tom Scheinin<sup>1</sup> & Ville Sallinen<sup>1,2</sup><sup>1</sup>Department of Abdominal Surgery, and <sup>2</sup>Department of Transplantation and Liver Surgery, Helsinki University Hospital and University of Helsinki, Helsinki, Finland

## Abstract

**Background:** Cholecystectomy is usually carried out for benign indications. Most perform routine histopathologic examination to detect incidental gallbladder cancer (GBC).

**Methods:** Cholecystectomies performed at four hospitals in the Helsinki Metropolitan Area during 2010–2012 were analyzed retrospectively. Patients with preoperative suspicion of neoplasia, active malignancy, or in whom cholecystectomy was performed as a secondary procedure were excluded.

**Results:** A total of 2034 cholecystectomies were included. In ten patients (0.5%), GBC was identified, each with an associated macroscopic finding, including local hardness ( $n = 1$ ), a thickened wall ( $n = 5$ ), acute inflammation and necrosis ( $n = 1$ ), or suspected neoplasia ( $n = 3$ ). No GBC was found in macroscopically normal gallbladders ( $n = 1464$ ). Of the ten patients with GBC, five underwent subsequent liver resection, four had metastatic disease, and one had locally advanced inoperable disease. Three of the five patients who underwent liver resection were alive and disease-free at final follow-up (median 48 months). The remaining seven patients with GBC died of the disease, with a median survival of 14 months (range 10–48 months).

**Conclusions:** Routine histopathologic examination of a macroscopically normal gallbladder does not improve diagnosis of GBC. A histopathological examination is, however, mandatory when a macroscopic abnormality is present.

Received 7 August 2017; accepted 22 November 2017

## Correspondence

Ville Sallinen, Department of Transplantation and Liver Surgery Helsinki University Hospital, Haartmaninkatu 4, 00029 HUS, Finland. E-mail: [ville.sallinen@helsinki.fi](mailto:ville.sallinen@helsinki.fi)

## Introduction

Cholecystectomy (open or laparoscopic) is one of the most common surgical operations, with approximately 8000, 65 000, and 460 000 operations performed annually in Finland, UK, and USA, respectively.<sup>1–3</sup> Cholecystectomy is usually performed due to symptomatic or complicated cholelithiasis, and rarely due to a suspicion of neoplasm. Occasionally, surgeons encounter incidental gallbladder cancer (GBC) after routine cholecystectomy for a non-neoplastic indication. Therefore, in most centers, the excised gallbladder is routinely sent for a histopathological

examination (HPE).<sup>4–7</sup> While GBC is relatively common in Asian countries, it is a rare malignancy in Western populations.<sup>5,6,8–13</sup>

The only possibility for curative treatment of GBC is early diagnosis and radical surgery.<sup>9,14</sup> According to current guidelines, cholecystectomy is sufficient for stage T1aN0 cancer.<sup>15</sup> However, for tumors beyond this stage, radical cholecystectomy with en bloc resection of adjacent liver parenchyma and regional lymphadenectomy is advised.<sup>15</sup> Overall survival remains exceptionally poor (5.1–9.5 months) in patients with unresectable GBC, but radical surgery extends the median survival to 35–53 months.<sup>11,16,17</sup> Several retrospective studies have shown a survival benefit for resection with lymphadenectomy after incidentally detected GBC,<sup>17–20</sup> and such an approach is recommended for T1b–T3 tumors.<sup>15</sup> Survival after

This paper was presented orally at the Finnish National Surgical Week (Operatiiviset päivät) in November, 2016.

incidental GBC does not appear to rely on whether liver resection is carried out in the same operation or during reoperation at a later stage.<sup>16,17</sup> Furthermore, incidental GBC has a better prognosis than symptomatic GBC.<sup>14,17</sup> For these reasons, routine HPE has been recommended to detect incidental GBC.<sup>15</sup> However, even if a reoperation and resection is recommended after identification of incidental GBC, it is not clear whether routine HPE of all excised gallbladders offers a diagnostic advantage over macroscopic examination and selective HPE for those with macroscopic abnormalities. The aim of this study, therefore, was to assess the rate of incidental GBC in macroscopically normal gallbladders.

## Material and methods

This was a retrospective cohort study including patients treated in 4 hospitals in the Helsinki Metropolitan Area (Surgical Hospital, Meilahti Hospital, Jorvi Hospital, and Peijas Hospital), all of which are administratively part of the Helsinki University Hospital, with a total patient catchment area of approximately 1 000 000 individuals. Patients were identified from an electronic operative registry using the procedure codes for open and laparoscopic cholecystectomy (JKA20 and JKA21).

The aim was to collect at least 2000 patients undergoing cholecystectomy to detect at least 10 patients with incidental gallbladder cancer, assuming an incidence of 0.5%. Based on initial calculations, a 1.5 year time period was chosen, which was then extended by 2 months to obtain the target study population. Furthermore, the period was chosen such that a sufficient follow-up of at least 3 years from cholecystectomy would be available. The final index cholecystectomy period was from November 2010 to May 2012, and data were collected during 2016. Patients who had undergone open or laparoscopic cholecystectomy as their primary operation (i.e. not as a secondary operation performed concomitantly with an alternative primary operation) during the chosen time period were included. Exclusion criteria were: 1) clinical or radiological suspicion of gallbladder neoplasia prior to the operation, and 2) any active malignancy or malignancy that had been in remission less than 5 years.

Data were collected from electronic patient records in a preformatted SPSS sheet (SPSS Statistics ver. 22, IBM, Armonk, NY). Basic demographics, operative details, macro- and microscopic findings, and follow-up were extracted. The indication for surgery was defined as the main reason for cholecystectomy at the time of the operation, although other indications, such as previous episodes of cholecystitis or pancreatitis, might have been present. Cholecystectomies performed during an emergency admission were classified as emergent, whilst others were classified as elective procedures.

Any macroscopic description of thickening, tumor, polyp, or necrosis in the operation record was interpreted as a pathology of

the gallbladder. The routine method to evaluate the resected gallbladders in these hospitals is to open the gallbladder after resection, inspect the mucosa, and mark the contents of the gallbladder (stones, sludge, etc). The end of follow-up was defined as the last verified contact or visit based on the electronic patient records. Patients whose gallbladder was not sent for HPE were crosschecked using the Finnish Cancer Registry (FCR) in 2015 to verify that no malignancies were missed in these patients. FCR covers the whole Finland with 96% completeness regarding solid tumors.<sup>21</sup> This study was approved by the institutional review board of Helsinki University Hospital and the National Institute for Health and Welfare.

## Results

### Patients

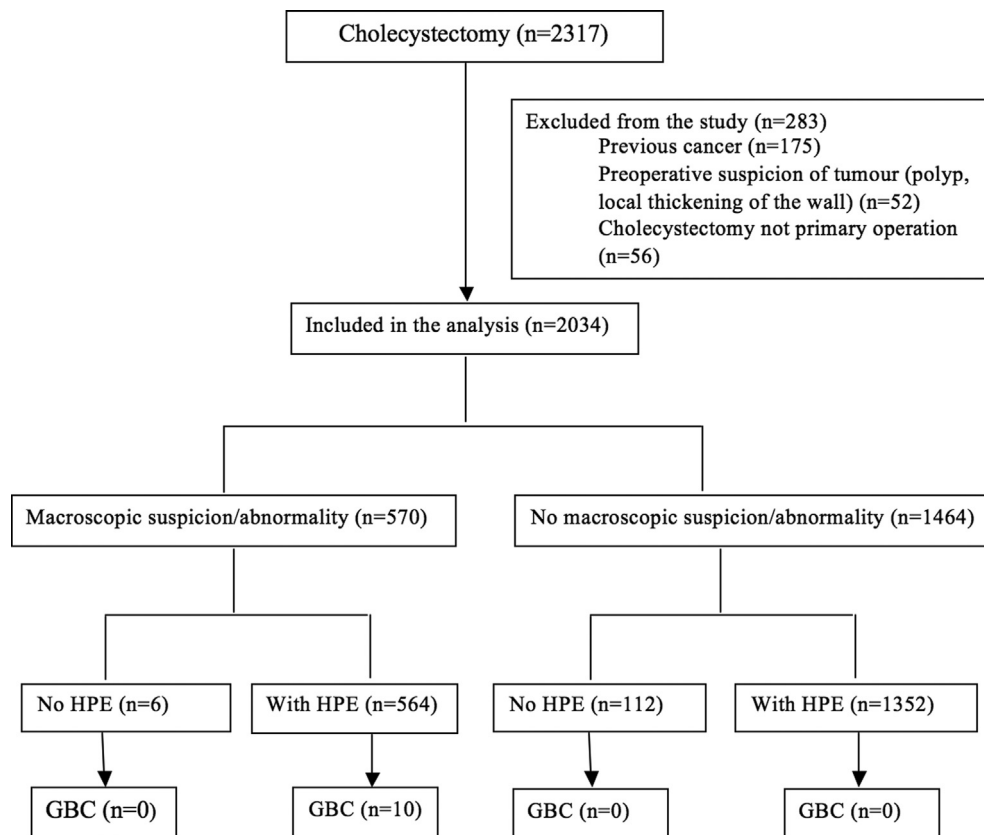
Of the 2317 patients identified, 2034 patients met the inclusion and exclusion criteria and were included in the study (Fig. 1). The basic patient and operative characteristics are shown in Table 1.

### Micro- and macroscopic findings

The macroscopic description was normal in 70.0% and 60.8% of gallbladders, as assessed by the surgeon and pathologist, respectively (Table 2). Histopathological analysis was performed on 94% of gallbladders ( $n = 1916$ ). Of the 118 gallbladders not sent for HPE, 112 were reported as macroscopically normal, while six exhibited a thickened or necrotic wall. Ten GBC were found by HPE. The macroscopic appearance of these gallbladders, as described by the surgeon, was as follows: local hardness ( $n = 1$ ), thickened wall ( $n = 5$ ), acute cholecystitis ( $n = 1$ ), and neoplastic ( $n = 3$ ). Thus, the rate of GBC in patients without signs of malignancy in preoperative imaging was 0.5% ( $n = 10$ ). No GBC was found in patients with a macroscopically normal gallbladder. Of note, one other patient derived diagnostic benefit from HPE when a suspicion of primary sclerosing cholangitis was established on the basis of histopathological findings. In this patient, the gallbladder wall was also thickened. Patients whose gallbladders were not sent for HPE were crosschecked with the Finnish Cancer Registry for instances of missed GBC; however, none were identified.

### Patients with incidental GBC

The male/female ratio among patients with GBC was similar to patients undergoing cholecystectomy (two-thirds female) (Table 3). The median age was 74 years (range 49–84 years), with only one patient younger than 50 years of age. Six of these patients (60%) underwent elective cholecystectomy, and none had a history of acute cholecystitis. Four patients underwent emergency cholecystectomy due to acute cholecystitis. Of note, nine patients had been evaluated with US, one with CT, and three with MRI prior to the operation without



**Figure 1** Flowchart of patient selection and outcomes. GBC – gallbladder cancer, HPE – histopathological examination

suspicion of malignancy. Five patients underwent further liver resection to obtain wider margins. Two patients were deemed inoperable at exploratory laparotomy, and three patients were found to have metastatic disease in their preoperative CT scans (Table 4).

Seven of the 10 patients died of disseminated disease during the follow-up, with an overall median survival of 14 months (IQR 12.1–28.4). Patients with metastatic disease who did not undergo liver resection ( $n = 5$ ) had a similar survival to that observed for all seven patients dying during the study period (14 months, IQR 11–38.5). However, the median survival of patients who underwent liver resection could not be determined, as three of the five patients were alive and disease-free after a median of 48 months follow-up (36–56 months).

## Discussion

In the present study, GBC was found in 10 out of 2034 patients (0.5%) undergoing cholecystectomy for a benign indication without any suspicion of malignancy prior to surgery. No GBC was found in gallbladders deemed normal upon macroscopic examination by the surgeon, and all cases of GBC had some form

of abnormal macroscopic appearance, albeit not necessary a tumor. These findings suggest that selective HPE after cholecystectomy is sufficient. However, it must be stressed that the surgeon should carefully examine the specimen, with only macroscopically normal gallbladders qualifying for omission from routine HPE.

The necessity of HPE after cholecystectomy has been assessed in several studies before, with conflicting evidence. Some studies have claimed that all GBC can be detected macroscopically, and routine histopathology is not needed.<sup>7,22</sup> Others have suggested that a thickened wall is always present in cases of GBC.<sup>11</sup> The rate of incidental GBC in these reports varied between 0.2% and 0.4%, which is similar to the present study. However, a number of reports advocate for routine HPE of all cholecystectomy specimens. In such studies, the rates of incidental GBC were similar to that observed in this study, but these studies did not consider the role of macroscopic examination and the possibility of selective HPE.<sup>23,24</sup> Furthermore, recent studies have found that all GBC is associated with some form of macroscopic abnormality, with no GBC found in patients with a macroscopically normal gallbladder.<sup>4,5,25</sup> Our results mirror such findings, with all cases in this study exhibiting a thickened wall, macroscopically

**Table 1** Patient and operative characteristics in 2034 cholecystectomies

	<b>N (%); median (IQR)</b>
Age, years	53 (40.97–64.62)
Sex, male/female	661 (32.5)/1373 (67.5)
Indication for surgery	
Symptomatic gallstones	1189 (58.5)
Acute cholecystitis	484 (23.8)
Prior cholecystitis	136 (6.7)
Pancreatitis	136 (6.7)
Cholangitis	77 (3.8)
Asymptomatic gallstones <sup>a</sup>	12 (0.6)
Operative approach	
Laparoscopic	1838 (90.4)
Converted cholecystectomy	117 (5.8)
Open cholecystectomy	79 (3.9)
Level of urgency	
Elective	1488 (73.2)
Emergent	546 (26.8)
Preoperative diagnostic imaging	
Ultrasound	1930 (94.9)
Computed tomography	270 (13.3)
Magnetic resonance imaging	462 (22.7)
Follow-up, years	2.9 (0.1–4.06)

<sup>a</sup> Prophylactic cholecystectomy performed prior to transplantation.

neoplastic lesion, or, in 1 case, acute inflammatory findings. Importantly, previous work has suggested that a policy shift towards selective HPE would save 1.3 million EUR a year in the Netherlands alone.<sup>4</sup> The cost of gallbladder HPE in our hospital district is approximately 80 EUR, meaning that selective HPE for macroscopically abnormal cholecystectomy specimens would save roughly 0.5 million EUR per year in Finland (assuming 70% exhibit a grossly normal appearance and an annual rate of 8000 cholecystectomies).

Previous studies have reported macroscopic abnormality rates of between 13% and 43% in gallbladders removed for benign indications,<sup>4,25</sup> similar to that observed in this study (30%). Although the rate of GBC among macroscopically abnormal gallbladders is minimal (1–3%), it would appear that routine HPE in these cases is justified. If GBC is diagnosed symptomatically following previous cholecystectomy without routine HPE, the overall resectability rate is 8%, compared to 70% if GBC is detected early based on HPE.<sup>26</sup> This is confirmed by our findings of a 50% resectability rate for incidental GBC, and the fact that 3 of these patients were disease-free at a median 48 months of follow-up. Notably, these patients had T2N0 GBC without residual tumor found during reoperation, while patients

**Table 2** Macro- and microscopic findings of gallbladders removed at cholecystectomy

	<b>N (%)</b>
Macroscopic appearance (surgeon) (n = 2034)	
No abnormalities <sup>a</sup>	1423 (70.0)
Thickened wall	407 (20.0)
Necrotic wall	98 (4.8)
Cholesterolosis	41 (2.0)
Polyp	6 (0.3)
Tumor	4 (0.2)
Other	55 (2.7)
Macroscopic appearance (pathologist) (n = 1916)	
No abnormalities	1164 (60.8)
Thickened wall	457 (23.9)
Necrotic wall	68 (3.5)
Cholesterolosis	109 (5.7)
Polyp	9 (0.5)
Tumor	4 (0.2)
Other	105 (5.5)
Histopathology (n = 1916)	
No specific findings/cholecystolithiasis	267 (13.9)
Chronic cholecystitis/fibrosis	1223 (63.9)
Acute cholecystitis	393 (20.5)
Dysplasia levis/adenoma	20 (1.0)
Dysplasia gravis	3 (0.2)
Gallbladder carcinoma	10 (0.5)

<sup>a</sup> Includes no statement of macroscopic appearance (n = 679).

with lymph node metastases exhibited poor survival. Although 6 macroscopically abnormal gallbladders were not sent for HPE and exhibited no late GBC, we do not recommend such a policy.

Several limitations should be noted with respect to this study. First, this was a retrospective study, which may limit the accuracy of the data due to an inability to prospectively control potential confounders, such as a lack of formal standardization for macroscopic examination of the gallbladder. Second, despite a relatively high number of patients undergoing cholecystectomy, the incidence of GBC was very low, limiting the power of the study.

Many traditions remain in modern medicine. Routine HPE for all cholecystectomy specimens is one such tradition. This study, along with previous studies, suggests that selective HPE may be safe, financially advantageous, and effective in reducing the load on pathology departments in an era when healthcare resources are already heavily strained. Based on our study, and similar results from others, we have changed our policy towards selective HPE in macroscopically abnormal gallbladders only.

**Table 3** Characteristic of patients with gallbladder cancer found after cholecystectomy

Case	Sex	Age	Indication	Operative approach	Urgency	Perioperative findings	Tumor type
1	Male	65	Acute cholecystitis	Converted	Emergent	Hard fibrotic tissue, necrotic and thickened wall	Adenocarcinoma
2	Female	81	Acute cholecystitis	Laparoscopic	Emergent	Necrotic wall	Adenocarcinoma
3	Male	83	Symptomatic gallstones	Laparoscopic	Elective	Unclear anatomy, tumor	Adenocarcinoma
4	Female	49	Acute cholecystitis	Laparoscopic	Emergent	Onion-like thickened wall	Mucocellular carcinoma
5	Female	67	Symptomatic gallstones	Converted	Elective	"Difficult anatomy", unclear tissue planes, thickened wall	Adenocarcinoma
6	Female	77	Symptomatic gallstones	Laparoscopic	Elective	Dense adhesions to the liver, circumferential tumor around the bladder	Adenocarcinoma
7	Female	70	Symptomatic gallstones	Converted	Elective	Very hard, fibrotic, and chronic inflammation	Adenocarcinoma
8	Female	78	Previous pancreatitis	Laparoscopic	Elective	Thickened wall	Adenocarcinoma
9	Male	84	Acute cholecystitis	Converted	Emergent	Tumor	Adenocarcinoma
10	Female	63	Symptomatic gallstones	Laparoscopic	Elective	Local hardness	Adenocarcinoma

**Table 4** Staging, tumor characteristics, and survival of patients with gallbladder cancer

Case	Primary stage	Grade	Secondary stage	Other pathological features	Oncological reoperation	Residual tumor in specimen	Survival (months)
1	pT2	2	pT2N0M0	Acute infection	Liver resection, lymphadenectomy	No	Alive and disease-free at 56 months
2	pT2	2	–	Perineural invasion	No; kidney and breast tumor in CT	N/A	48
3	pT2	2	pT2N1M0	Lymphovascular and perineural invasion	Liver resection, lymphadenectomy	Yes: Lymph node metastases only	13
4	pT2	3	pT2NXM1	–	Exploration	Yes: Peritoneal carcinosis	12
5	pT2	2	pT4N0M0	–	Exploration	Yes: periportal invasive tumor growth	28
6	pT3N1	NS	pT3N1M0	Lymphovascular invasion	Liver resection, portal lymphadenectomy, port site excision	Yes: Lymph node metastases only	16
7	pT2	3	–	–	No; tumor progression during neoadjuvant therapy	N/A	14
8	pT2	2	pT2N0M0	–	Liver resection, portal lymphadenectomy, wound resection	No	Alive and disease-free at 49 months
9	pT3N1	1	–	Lymphovascular and perineural invasion	No; locally advanced in MRI	N/A	10
10	pT2	2	pT2N0M0	–	Liver resection, portal lymphadenectomy, port site excision	No	Alive and disease-free at 48 months

Abbreviations: N/A – Not available.

#### Acknowledgments

This study was funded by Helsinki University Hospital research funds, grants from the Vatsatautien Tutkimussäätiö Foundation, and grants from the Mary and Georg Ehrnrooth Foundation.

#### Funding

Helsinki University Hospital research funds, Vatsatautien Tutkimussäätiö Foundation, Mary and Georg Ehrnrooth Foundation.

#### Conflicts of interest

None to declare.

#### References

- Järvelin J, Heino A. (2017) *Periods of care with procedures by primary procedure 2014–2015*. Available at: <https://www.thl.fi/fi/tilastot/tilastot-aiheittain/erikoissairaanhoidon-palvelut/somaattinen-erikoissairaanhoido>. (Accessed 20 September 2016).

2. Digital NHS. (2012) *Hospital Episode Statistics [HES], main procedures and interventions summary 2011–2012*. Available at: <http://content.digital.nhs.uk/catalogue/PUB08288>. (Accessed 16 February 2017). November 2012.
3. Weiss A. (2014) *Trends in operating room procedures in U.S. Hospitals 2001–2011*. Available at: <https://www.hcup-us.ahrq.gov/reports/statbriefs/sb171-Operating-Room-Procedure-Trends.pdf>. (Accessed 16 February 2017). March 2014.
4. van Vliet JL, van Gulik TM, Verbeek PC. (2013) Is it necessary to send gallbladder specimens for routine histopathological examination after cholecystectomy? The use of macroscopic examination. *Dig Surg* 30: 472–475.
5. Tayeb M, Rauf F, Ahmad K, Khan FM. (2015) Is it necessary to submit grossly normal looking gall bladder specimens for histopathological examination? *Asian Pac J Cancer Prev* 16:1535–1538.
6. Wrenn SM, Callas PW, Abu-Jaish W. (2017) Histopathological examination of specimen following cholecystectomy: are we accepting resect and discard? *Surg Endosc* 31:586–593.
7. Darmas B, Mahmud S, Abbas A, Baker AL. (2007) Is there any justification for the routine histological examination of straightforward cholecystectomy specimens? *Ann R Coll Surg Engl* 89:238–241.
8. Randi G, Franceschi S, La Vecchia C. (2006) Gallbladder cancer worldwide: geographical distribution and risk factors. *Int J Cancer* 118: 1591–1602.
9. Kai K, Aishima S, Miyazaki K. (2014) Gallbladder cancer: clinical and pathological approach. *World J Clin Cases* 2:515–521.
10. Akyurek N, Irkorucu O, Salman B, Erdem O, Sare M, Tatlicioglu E. (2004) Unexpected gallbladder cancer during laparoscopic cholecystectomy. *J Hepatobiliary Pancreat Surg* 11:357–361.
11. Bazoua G, Hamza N, Lazim T. (2007) Do we need histology for a normal-looking gallbladder? *J Hepatobiliary Pancreat Surg* 14:564–568.
12. Ramraje SN, Pawar VI. (2014) Routine histopathologic examination of two common surgical specimens-appendix and gallbladder: is it a waste of expertise and hospital resources? *Indian J Surg* 76:127–130.
13. Choi KS, Choi SB, Park P, Kim WB, Choi SY. (2015) Clinical characteristics of incidental or unsuspected gallbladder cancers diagnosed during or after cholecystectomy: a systematic review and meta-analysis. *World J Gastroenterol* 21:1315–1323.
14. Cavallaro A, Piccolo G, Panebianco V, Lo Menzo E, Berretta M, Zanghi A *et al.* (2012) Incidental gallbladder cancer during laparoscopic cholecystectomy: managing an unexpected finding. *World J Gastroenterol* 18:4019–4027.
15. Aloia TA, Jarufe N, Javle M, Maithel SK, Roa JC, Adsay V *et al.* (2015) Gallbladder cancer: expert consensus statement. *HPB* 17:681–690.
16. Lohe F, Meimarakis G, Schauer C, Angele M, Jauch KW, Schauer RJ. (2009) The time of diagnosis impacts surgical management but not the outcome of patients with gallbladder carcinoma. *Eur J Med Res* 14: 345–351.
17. Shih SP, Schulick RD, Cameron JL, Lillemoe KD, Pitt HA, Choti MA *et al.* (2007) Gallbladder cancer: the role of laparoscopy and radical resection. *Ann Surg* 245:893–901.
18. Fuks D, Regimbeau JM, Le Treut YP, Bachellier P, Raventos A, Pruvot FR *et al.* (2011) Incidental gallbladder cancer by the AFC-GBC-2009 study Group. *World J Surg* 35:1887–1897.
19. Butte JM, Waugh E, Meneses M, Parada H, De La Fuente HA. (2010) Incidental gallbladder cancer: analysis of surgical findings and survival. *J Surg Oncol* 102:620–625.
20. Dixon E, Vollmer CM, Jr., Sahajpal A, Cattral M, Grant D, Doig C *et al.* (2005) An aggressive surgical approach leads to improved survival in patients with gallbladder cancer: a 12-year study at a North American Center. *Ann Surg* 241:385–394.
21. Leinonen MK, Miettinen J, Heikkinen S, Pitkaniemi J, Malila N. (2017) Quality measures of the population-based Finnish Cancer Registry indicate sound data quality for solid malignant tumours. *Eur J Cancer* 77:31–39.
22. Dix FP, Bruce IA, Krypczyk A, Ravi S. (2003) A selective approach to histopathology of the gallbladder is justifiable. *Surgeon* 1:233–235.
23. Basak F, Hasbahceci M, Canbak T, Sisik A, Acar A, Yucel M *et al.* (2016) Incidental findings during routine pathological evaluation of gallbladder specimens: review of 1,747 elective laparoscopic cholecystectomy cases. *Ann R Coll Surg Engl* 98:280–283.
24. Lohsiriwat V, Vongjirad A, Lohsiriwat D. (2009) Value of routine histopathologic examination of three common surgical specimens: appendix, gallbladder, and hemorrhoid. *World J Surg* 33:2189–2193.
25. Talreja V, Ali A, Khawaja R, Rani K, Samnani SS, Farid FN. (2016) Surgically resected gall bladder: is histopathology needed for all? *Surg Res Pract* 2016:1–4.
26. Agarwal AK, Kalayarsan R, Singh S, Javed A, Sakhujia P. (2012) All cholecystectomy specimens must be sent for histopathology to detect inapparent gallbladder cancer. *HPB* 14:269–273.