

Original Paper

Fetal Diagnosis
and TherapyFetal Diagn Ther
DOI: 10.1159/000488282Received: December 19, 2017
Accepted after revision: March 7, 2018
Published online: May 17, 2018

Antenatal Workup of Early Megacystis and Selection of Candidates for Fetal Therapy

Federica Fontanella^a Leonie Duin^a Phebe N. Adama van Scheltema^b
Titia E. Cohen-Overbeek^c Eva Pajkrt^d Mireille Bekker^{e, f} Christine Willekes^g
Caroline J. Bax^h Dick Oepkes^b Catia M. Bilardo^a

^aDepartment of Obstetrics, Gynecology and Prenatal Diagnosis, University Medical Center Groningen, University of Groningen, Groningen, The Netherlands; ^bDepartment of Obstetrics, Gynecology and Prenatal Diagnosis, Leiden University Medical Center, Leiden, The Netherlands; ^cDepartment of Obstetrics, Gynecology and Prenatal Diagnosis, Erasmus MC University Medical Center, Rotterdam, The Netherlands; ^dDepartment of Obstetrics, Gynecology and Prenatal Diagnosis, Academic Medical Center Amsterdam, Amsterdam, The Netherlands; ^eDepartment of Obstetrics, Gynecology and Prenatal Diagnosis, Radboud University Medical Center, Nijmegen, The Netherlands; ^fDepartment of Obstetrics, Gynecology and Prenatal Diagnosis, University Medical Center Utrecht, Utrecht, The Netherlands; ^gDepartment of Obstetrics, Gynecology and Prenatal Diagnosis, University Medical Center, Grow School for Oncology and Medical Biology, Maastricht, The Netherlands; ^hDepartment of Obstetrics, Gynecology and Prenatal Diagnosis, VU University Medical Center, Amsterdam, The Netherlands

Keywords

Megacystis · First-trimester pregnancy · Lower urinary tract obstructions · Posterior urethral valves

Abstract

Objective: To investigate the best criteria for discriminating fetuses with isolated posterior urethral valves from those theoretically not eligible for fetal treatment because of complex megacystis, high chance of spontaneous resolution, and urethral atresia. **Methods:** A retrospective national study was conducted in fetuses with megacystis detected before 17 weeks' gestation (early megacystis). **Results:** In total, 142 cases with fetal megacystis were included in the study: 52 with lower urinary tract obstruction, 29 with normal micturition at birth, and 61 with miscellaneous syndromal associations, chromosomal and multiple structural abnormalities

(complex megacystis). Only a nuchal translucency >95th centile, and not a longitudinal bladder diameter ≤ 15 mm ($p = 0.24$), significantly increased the risk of complex megacystis ($p < 0.01$). Cases with a high chance of spontaneous resolution were identified by using the cut-off of 12 mm, as demonstrated in a previous study, and the finding of an associated umbilical cord cyst carried a high-risk of urethral atresia (odds ratio: 15; $p = 0.026$), an unfavorable condition for antenatal treatment. An algorithm encompassing these three criteria demonstrated good accuracy in selecting fetuses theoretically eligible for fetal treatment (specificity 73%; sensitivity 92%). **Conclusions:** Cases theoretically eligible for early fetal therapy are those with normal nuchal translucency, a longitudinal bladder diameter > 12 mm, and without ultrasound evidence of umbilical cord cysts.

© 2018 The Author(s)
Published by S. Karger AG, Basel

KARGER

E-Mail karger@karger.com
www.karger.com/fdt© 2018 The Author(s)
Published by S. Karger AG, Basel

This article is licensed under the Creative Commons Attribution-NonCommercial-NoDerivatives 4.0 International License (CC BY-NC-ND) (<http://www.karger.com/Services/OpenAccessLicense>). Usage and distribution for commercial purposes as well as any distribution of modified material requires written permission.

Federica Fontanella
Department of Obstetrics, Gynecology and Prenatal Diagnosis
University Medical Center Groningen, University of Groningen
Hanzeplein 1, NL-9713 GZ Groningen (The Netherlands)
E-Mail f.fontanella@umcg.nl

Introduction

An enlarged urinary bladder, also known as megacystis, is a rare ultrasound finding observed in 0.06% [1] of first-trimester pregnancies. This ultrasound anomaly is rather obvious and therefore, it is considered one of the anomalies “expected to be detected” at the currently widely performed first-trimester scans. In 1996, Sebire et al. [1] defined as megacystis a longitudinal bladder diameter (LBD) greater than 7 mm between 11 and 14 weeks’ gestation. The authors described three possible evolutions with different outcomes: chromosomal abnormalities, antenatal spontaneous resolution, or progression to obstructive uropathy [1]. In this historical study, the authors suggested to base the antenatal counseling and workup on the LBD. If this is between 7 and 15 mm, fetal karyotype is recommended, as the majority of chromosomal anomalies falls in this group, and if the karyotype is normal, a spontaneous resolution will occur in 90% of cases; while in cases with LBD >15 mm, the prognosis is poor, due to a high incidence of lower urinary tract obstruction (LUTO) and subsequent obstructive uropathy.

After the exclusion of cases where spontaneous resolution is likely, first-trimester counseling of fetal megacystis has traditionally been negative, due to the lack of available early therapeutic options [2]. Nowadays, thanks to technical improvements, early fetal therapy has however become plausible [3–5], as it appears that an early intervention is the only strategy potentially capable of preventing the occurrence of renal damage in the very few cases with truly isolated posterior urethral valves (PUV) [3, 6, 7]. In the attempt to identify these rare cases – should parents not consider termination of pregnancy as an option – the challenge remains which criteria should be used to effectively detect first-trimester fetuses with complex megacystis and very poor prognosis, on the one hand, and those with a high chance of spontaneous resolution and favorable prognosis, on the other.

As criterion for triaging fetuses with normal chromosomes and eligible for early intervention, the value of an LBD greater than 15 mm has not yet been extensively tested. Moreover, it is known that, besides chromosomal anomalies, there are other severe causes of complex megacystis that ideally should be identified as soon as possible in order to inform parents on the expected poor prognosis. To date, no effective criteria have been formulated for their identification. Conversely, regarding the prediction of spontaneous resolution, we have recently confirmed the accuracy of the LBD measurement and

suggested a new cut-off, i.e., 12 mm, rather than the classic 15 mm, as a more accurate predictor [8].

The aim of this study is therefore to construct a management algorithm aimed at excluding fetuses with complex megacystis or likely to undergo a spontaneous resolution, and at effectively identifying the very few cases with isolated PUV, theoretically eligible for early fetal intervention.

Methods

This was a retrospective multicenter study carried out at the Fetal Medicine Units of the eight University Hospitals in the Netherlands. Cases were collected at the Erasmus Medical Center, Academic Medical Center, Amsterdam, and at the University Medical Center, Maastricht from 2000 to 2015, between 2004 and 2015 at the University Medical Center Groningen and at the Radboud University Medical Center, Nijmegen, and between 2007 and 2014 in the remaining centers. Fetal megacystis was defined as an LBD ≥ 7 mm [1].

Collected prenatal data of referred cases included: gestational age at diagnosis, LBD, and eventual additional anomalies. The LBD was obtained from a midsagittal view of the fetus, by measuring the distance from fetal bladder dome to bladder neck. Umbilical cord cysts (UCC) were defined as anechoic structures within the umbilical cord eventually described at the ultrasound medical report. The nuchal translucency (NT) was considered increased if greater than the 95th percentile for the gestational age [9]. Final diagnosis was based on postnatal investigations or postmortem examinations. Three main categories of final diagnosis were identified: cases with LUTO, cases with complex megacystis, and cases with normal voiding at birth or isolated urological anomaly. The group with complex megacystis included cases with miscellaneous syndromal associations, chromosomal and multiple structural abnormalities. In 91 cases, a final diagnosis was not established because the pregnancy was terminated, the parents did not consent for the autopsy, and the prenatal investigations were not diagnostic.

In order to identify the candidates for intrauterine surgery, antenatal variables were investigated for their capability of predicting these 4 scenarios: only chromosomal abnormalities; chromosomal abnormalities or other conditions with poor prognosis (complex megacystis); urethral atresia, considered as a very severe form of LUTO; and spontaneous resolution, whereby megacystis is a temporary presentation and the prognosis is mostly benign. The predictors were investigated by using a bivariate logistic regression analysis and the association was described by odds ratios (OR) and 95% confidence intervals (CI). All statistical analyses were performed using SPSS 22.

Results

During the study period, 233 pregnancies were referred to one of the eight academic centers in the Netherlands owing to fetal megacystis, detected between the

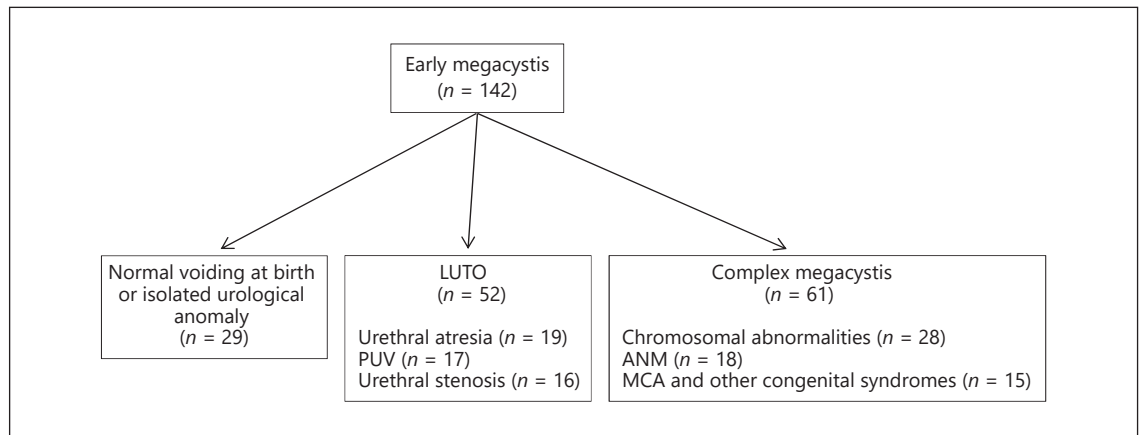


Fig. 1. Study population. LUTO, lower urinary tract obstruction; PUV, posterior urethral valves; ANM, anorectal malformations; MCA, multiple congenital anomalies.

Table 1. Nuchal translucency (NT) and longitudinal bladder diameter (LBD) according to final diagnosis

	NT >95th centile	LBD, mm	GA at diagnosis, weeks
LUTO (<i>n</i> = 52)	6%	32 (14)	15 (1.7)
Syndromes (<i>n</i> = 61)	23%	20 (13)	13 (1.6)
Chromosomal abnormalities (<i>n</i> = 28)	50%	15 (8)	13 (1.2)
Trisomy 13 (<i>n</i> = 3)	1.5 (1–2)	8.1 (8–10)	12 (12–13)
Trisomy 18 (<i>n</i> = 13)	4.2 (3–12)	13.0 (7–32)	13 (12–15)
Trisomy 21 (<i>n</i> = 3)	4.3 (4–5)	24.0 (8–29)	13 (13–17)
<i>p</i> value trisomy 13 – trisomy 18	0.06		
<i>p</i> value trisomy 13 – trisomy 21	0.35		
<i>p</i> value trisomy 18 – trisomy 21	0.25		

Categorical variables are expressed as percentage (%). Numerical variables are expressed as mean (standard deviation) or median (range). LUTO, lower urinary tract obstruction.

10th and 17th week of gestation. A clear final diagnosis was possible in 142 cases and included 61 fetuses with complex megacystis, 52 with isolated LUTO, and 29 with normal voiding at birth or isolated urological anomaly (Fig. 1). The group with complex megacystis (*n* = 61) presented miscellaneous syndromal associations, chromosomal and multiple structural abnormalities and included 28 cases with chromosomal abnormalities (46%), 18 fetuses with anorectal malformations (30%), and 15 cases with other multiple congenital anomalies (25%). LBD and NT were measured at the first ultrasound examination in 124 and 110 pregnancies, respectively.

The most common chromosomal abnormality was trisomy 18 (*n* = 13; 46%), followed by trisomy 21 (*n* = 3; 11%), trisomy 13 (*n* = 3; 11%), Turner syndrome (*n* = 3;

11%), and other chromosomal abnormalities (*n* = 6; 21%). The median LBD in fetuses with trisomy 13, 18, and 21 was 8.1 mm, 13 mm, and 24 mm, respectively (Table 1). In total, the LBD was ≤15 mm in 42 cases and >15 mm in 82 cases, and the incidence of chromosomal abnormalities was 36% (15/42) in the first group and 13% (11/82) in the second group with LBD >15 mm. Forty-five percent of fetuses with trisomy 18 and 21 had an LBD >15 mm. Out of 28 cases with abnormal karyotype, 57% (16/28) had an LBD ≤15 mm and 43% (12/28) had an LBD >15 mm. The accuracy of the classic 15-mm cut-off for the LBD was tested and compared to the accuracy of the NT measurement for identifying fetuses with complex megacystis. The classic criteria of an LBD ≤15 mm slightly increased the risk of chromosomal abnormalities (OR: 0.3

Fig. 2. Decision tree analysis for detecting isolated posterior urethral valves (PUV) in fetuses with early megacystis. Out of 17 cases with isolated PUV, 4 were excluded from the algorithm as their longitudinal bladder diameter (LBD) measurement was not available. NT, nuchal translucency; UCC, umbilical cord cyst.

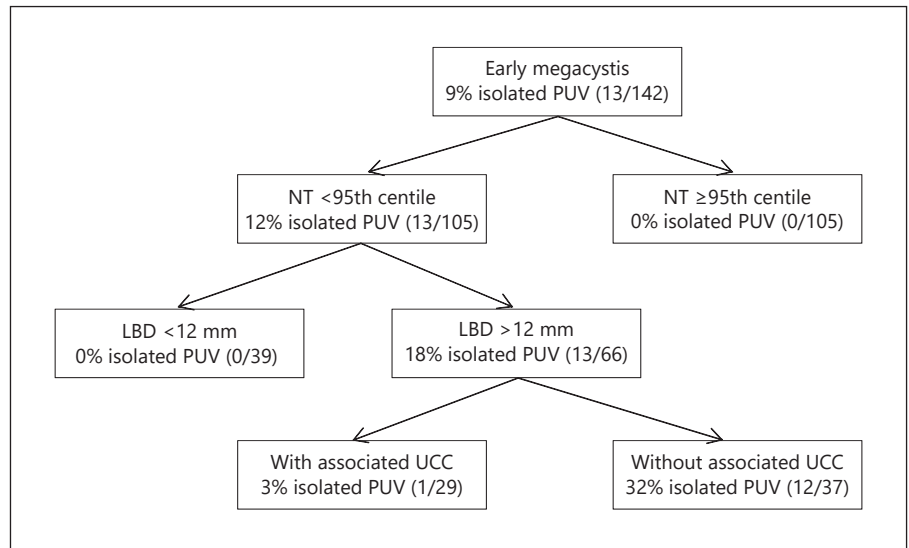


Table 2. Odds ratio of nuchal translucency (NT) >95th centile, longitudinal bladder diameter (LBD) >12 mm, and evidence of umbilical cord cysts (UCC) for predicting complex megacystis, spontaneous resolution, and urethral atresia, respectively

	Odds ratio obtained by considering the whole population	Odds ratio obtained by following the proposed management algorithm
NT >95th centile for complex megacystis	14 ($p < 0.001$)	14 ($p < 0.001$)
LBD >12 mm for spontaneous resolution	10 ($p < 0.001$)	16 ($p < 0.001$)
Evidence of UCC for urethral atresia	7 ($p = 0.003$)	15 ($p = 0.026$)

[95% CI: 0.1–0.7], $p = 0.01$), whereas only an NT >95th centile, and not an LBD ≤ 15 mm, significantly increased the risk of complex megacystis in general, including fetuses with miscellaneous syndromal associations, chromosomal and multiple structural abnormalities (NT > 95th centile: OR: 13.7 [95% CI: 3.8–48.5], $p < 0.001$; LBD ≤ 15 mm: OR: 0.6 [95% CI: 0.3–1.4], $p = 0.24$).

In order to define an algorithm capable of selecting fetuses with isolated PUV, 37 fetuses with NT >95th centile and at risk of complex megacystis were excluded from further analysis.

The chance of an antenatal spontaneous resolution was then evaluated by measuring the LBD and using the new cut-off of 12 mm, as suggested by our previous study [8]. Therefore, another 39 cases with LBD ≤ 12 mm were considered to have a high chance of spontaneous resolution and excluded.

Of the 66 remaining cases with suspected isolated LUTO, 29 cases presented an associated UCC at the ul-

trasound examination, and 15 cases in total (7 female and 8 male fetuses; 23%) showed a urethral atresia at the post-mortem examination. The evidence of an associated UCC significantly increased the risk of urethral atresia with an OR of 15 ($p = 0.026$).

These three antenatal parameters (NT >95th centile, LBD >12 mm, and evidence of UCC) showed a good predictive value for each outcome (complex megacystis, spontaneous resolution, and urethral atresia, respectively), as reported in Table 2. For each parameter, the OR was higher if calculated by following our management algorithm (Table 2; Fig. 2) rather than considering the whole population.

Among fetuses with early megacystis, an algorithm encompassing these three criteria (Fig. 2) can guide counseling and management of this condition and discriminate fetuses theoretically eligible for fetal treatment with a specificity and sensitivity of 73% and 92%, respectively.

Discussion

This study shows that in fetuses with early megacystis, the best criteria to guide the parental counseling and select cases with isolated PUV are: a normal NT, an LBD greater than 12 mm, and absence of UCC. These criteria demonstrated good accuracy in evaluating the risk of complex megacystis, spontaneous resolution, and urethral atresia, and in selecting those fetuses theoretically eligible for antenatal treatment.

Historically, an LBD greater or lower than 15 mm was used to evaluate the chance of chromosomal abnormalities or spontaneous resolution [1, 10, 11]. In this study, we showed that an enlarged NT, rather than the LBD measurement, significantly increased the risk of complex megacystis, including fetuses with miscellaneous syndromal associations, chromosomal and multiple structural abnormalities carrying a poor prognosis. We recently demonstrated that the optimal LBD cut-off to predict the chance of spontaneous resolution of megacystis is 12 mm, rather than 15 mm. Therefore, to sum up, the LBD should be considered only as predictor of spontaneous resolution [8], while the NT measurement should be taken into account as predictor of complex megacystis.

Further support to this finding is provided by the prospective study by Syngelaki et al. [12], including 108,982 pregnancies undergoing first-trimester screening. This large study reported a similar distribution of chromosomal abnormalities in cases with megacystis with LBD >15 or ≤15 mm, and suggested to base the decision for invasive testing on the results of the combined test or, alternatively, offer cfDNA [12]. This new approach is at variance with the commonly used management protocol for first-trimester megacystis, based on the study by Liao et al. [10]. The discrepancy in results is probably due to the different distribution in chromosomal anomalies between our study, that of Syngelaki et al. [12], and Liao et al.'s study [10]. In fact, similarly to our study, Syngelaki et al. [12] reported trisomy 18 as the most common chromosomal abnormality in fetuses with first-trimester megacystis (5/15; 33%), followed by trisomy 21 (4/15; 27%) and trisomy 13 (3/15; 20%) [12], whereas in the study by Liao et al. [10], the most common chromosomal abnormality in fetuses with megacystis was trisomy 13 (17/29; 59%), followed by trisomy 18 (7/29; 24%) and, as least frequent, by trisomy 21, found in only 7% of cases (2/29; 7%). In this study, we observed that, in fetuses with trisomy 13, megacystis is typically mildly enlarged (mean LBD: 8.7 mm), whereas cases with trisomy 18 and 21 show a more severe degree of bladder distension (mean

LBD: 20 and 15 mm, respectively). To date, the pathological background of fetal obstructive uropathy in trisomic fetuses has not yet been fully clarified [13]. We speculate that, among trisomies, there may be a different underlying cause of megacystis, with a varying degree of bladder enlargement, depending on the type of chromosomal abnormality. Hence, an obstructive uropathy is more commonly reported in fetuses with trisomy 18 and 21, but rarely in trisomy 13 [13–15]. Therefore, the different prevalence of trisomies between the studies may explain the divergent results. In light of the prospective nature and the size of Syngelaki et al.'s study [12], this is more likely to reflect the true distribution of chromosomal anomalies in fetuses with first-trimester megacystis.

Since the study by Liao et al. [10], there has been an increased interest in fetal therapy for LUTO. Recent studies have suggested that antenatal treatment improves perinatal survival, but with little effect on postnatal renal function [16–18]. This is probably due to the fact that renal parenchyma is in most cases already damaged at the time of fetal intervention. Animal studies have demonstrated a correlation between early LUTO and severity of renal damage, thus suggesting that an early treatment, although technically more challenging, may potentially improve the outcome [19, 20]. New therapeutic attempts, based on recent technical improvements, aim at sparing renal function starting from 14–16 weeks' gestation [3–5]. In this context, it has become extremely important to be able to select, as early as possible, fetuses eligible for timely treatment, should the parents choose for this option. Among cases with LUTO, fetuses with urethral atresia often present other associated developmental abnormalities and a poorer prognosis, compared to those with PUV [21]. Furthermore, in cases with urethral atresia, fetal cystoscopy, which specifically attempts to ablate the PUV, is not indicated [17]. Urethral atresia is commonly considered in female fetuses without keyhole sign. However, in our cohort, after excluding fetuses at risk of complex megacystis and spontaneous resolution, half of the fetuses (8/15) with urethral atresia were male, and other studies have already demonstrated that the keyhole sign is not a reliable predictor of PUV [22]. No previous study has so far found other reliable antenatal signs for this subtle differential diagnosis in the first trimester.

In the literature, UCC are reported at the first-trimester scan in 0.4–3.4% of cases [23]. In our cohort, we found a UCC in 12% (29/233) of fetuses with early megacystis. Previous studies have suggested that UCC may be an early sign of severe obstructive uropathy [24, 25]. This study is the first to clearly indicate that evidence of a UCC in

conjunction with a megacystis is a strong marker of urethral atresia, already from the first trimester of pregnancy. A plausible explanation for the association between megacystis and urethral atresia is that during the first stages of life, the bladder is connected with the umbilical cord through the allantois, which obliterates at 6–12 weeks' gestation to form the urachus, a fibromuscular tubular structure located between the apex of the bladder and the umbilical cord insertion. An abnormally distended urinary bladder could prevent the closure of the allantois and eventually lead to a cystic dilatation of the allantois or of the umbilical cord [25, 26]. This is more likely to occur in fetuses with an early and severe bladder enlargement, as it is the case in the setting of urethral atresia. This is another useful element to take into account when counseling parents on both prognosis and therapeutic options of fetal megacystis.

An important limitation of this study in assessing the real prevalence of UCC is that a complete examination of the umbilical cord, from placental to fetal insertion, was not routinely performed. We speculate that if this would have been done, theoretically even more UCC may have been seen. A second limitation is that, in this national cohort, the parental counseling was guided by Liao et al.'s results [10] and fetal karyotype was mainly recommended to fetuses with LBD ≤ 15 mm. Although this approach may have affected our results, the impact of this bias has been minimized by establishing the final diagnosis according to both postnatal and postmortem examinations, rather than only considering antenatal scans and fetal karyotype.

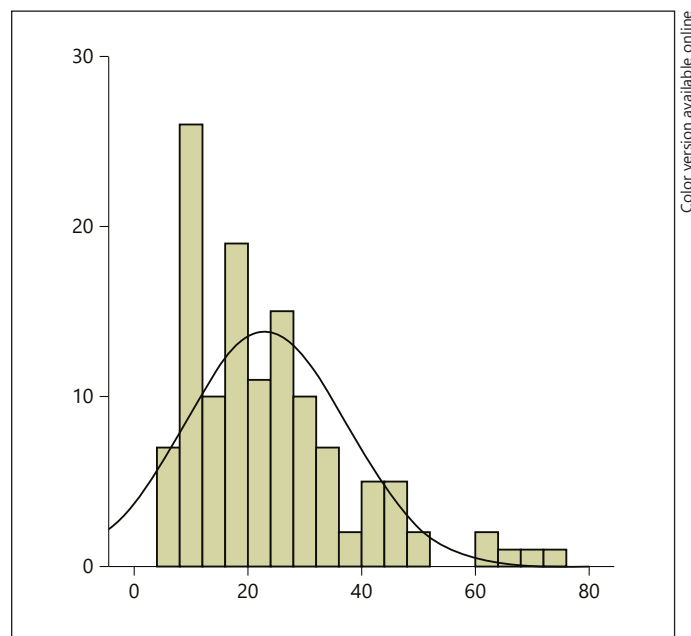
To summarize, we propose a new approach in the management and counseling of fetuses with early megacystis. Karyotyping should be offered more liberally and, for the detection of fetuses with complex megacystis, the focus should be on the NT rather than on the LBD. Moreover, cases with a high chance of spontaneous resolution should be identified by using the cut-off of 12 mm, as previously demonstrated. Besides this, the finding of a UCC should be regarded as an unfavorable prognostic factor because of its association with urethral atresia. Therefore, a thorough routine inspection of the umbilical cord should be carried out in all cases of megacystis to identify fetuses at risk of urethral atresia. We have summarized these recommendations in a flowchart to guide the antenatal workup and counseling in early megacystis cases, aiming at identifying fetuses with PUV only, theoretically eligible for early antenatal treatment.

Disclosure Statement

The authors of this paper have no conflicts of interest to declare.

Appendix

Histogram of longitudinal bladder diameter measurement.



References

- 1 Sebire NJ, Von Kaisenberg C, Rubio C, Snijders RJM, Nicolaidis KH: Fetal megacystis at 10–14 weeks of gestation. *Ultrasound Obstet Gynecol* 1996;8:387–390.
- 2 Jouannic J-M, Hyett JA, Pandya PP, Gulbis B, Rodeck CH, Jauniaux E: Perinatal outcome in fetuses with megacystis in the first half of pregnancy. *Prenat Diagn* 2003;23:340–344.
- 3 Ruano R, Yoshisaki CT, Salustiano EMA, Giron AM, Srougi M, Zugaib M: Early fetal cystoscopy for first-trimester severe megacystis. *Ultrasound Obstet Gynecol* 2011;37:696–701.
- 4 Kim SK, Won HS, Shim JY, Kim KS, Lee PR, Kim A: Successful vesicoamniotic shunting of posterior urethral valves in the first trimester of pregnancy. *Ultrasound Obstet Gynecol* 2005;26:666–668.
- 5 Dębska M, Kretowicz P, Olędzka A, Gastoł P, Dangel J, Świątkowska-freund M, Dębski R: Early vesico-amniotic shunting – does it change the prognosis in fetal lower urinary tract obstruction diagnosed in the first trimester? *Ginekol Pol* 2017;88:486–491.
- 6 Carroll SGM, Soothill PW, Tizard J, Kyle PM: Vesicocentesis at 10–14 weeks of gestation for treatment of fetal megacystis. *Ultrasound Obstet Gynecol* 2001;18:366–370.

- 7 Ruano R, Yoshisaki CT, Salustiano EMA, Giron AM, Srougi M, Zugaib M: Early fetal cystoscopy for first-trimester severe megacystis. *Ultrasound Obstet Gynecol* 2011;37:696–701.
- 8 Fontanella F, Duijn L, Adama van Scheltema PN, Cohen-Overbeek TE, Pajkrt E, Bekker M, Willekes C, Bax CJ, Bilardo CM: Fetal megacystis: prediction of spontaneous resolution and outcome. *Ultrasound Obstet Gynecol* 2017;50:458–463.
- 9 Sharifzadeh M, Adibi A, Kazemi K, Hovsepian S: Normal reference range of fetal nuchal translucency thickness in pregnant women in the first trimester, one center study. *J Res Med Sci* 2015;20:969–973.
- 10 Liao AW, Sebire NJ, Geerts L, Cicero S, Nicolaides KH: Megacystis at 10–14 weeks of gestation: chromosomal defects and outcome according to bladder length. *Ultrasound Obstet Gynecol* 2003;21:338–341.
- 11 Kagan KO, Staboulidou I, Syngelaki A, Cruz J, Nicolaides KH: The 11–13-week scan: diagnosis and outcome of holoprosencephaly, exomphalos and megacystis. *Ultrasound Obstet Gynecol* 2010;36:10–14.
- 12 Syngelaki A, Guerra L, Ceccacci I, Efeturk T, Nicolaides KH: Impact of holoprosencephaly, exomphalos, megacystis and high NT in first trimester screening for chromosomal abnormalities. *Ultrasound Obstet Gynecol* 2017;50:45–48.
- 13 Hoagland MH, Frank KA, Hutchins GM: Prune-belly syndrome with prostatic hypoplasia, bladder wall rupture, and massive ascites in a fetus with trisomy 18. *Arch Pathol Lab Med* 1988;112:1126–1128.
- 14 Qureshi F, Jacques SM, Feldman B, Doss BJ, Johnson A, Evans MI, Johnson MP: Fetal obstructive uropathy in trisomy syndromes. *Fetal Diagn Ther* 2000;15:342–347.
- 15 Frydman M, Magenis RE, Mohandas TK, Kaback MM: Chromosome abnormalities in infants with prune belly anomaly: association with trisomy 18. *Am J Med Genet* 1983;15:145–148.
- 16 Nassr AA, Shazly SAM, Abdelmagied AM, Araujo Júnior E, Tonni G, Kilby MD, Ruano R: Effectiveness of vesico-amniotic shunt in fetuses with congenital lower urinary tract obstruction: an updated systematic review and meta-analysis. *Ultrasound Obstet Gynecol* 2017;49:696–703.
- 17 Ruano R, Sananes N, Sangi-Haghpeykar H, Hernandez-Ruano S, Moog R, Becmeur F, Zaloszc A, Giron AM, Morin B, Favre R: Fetal intervention for severe lower urinary tract obstruction: a multicenter case-control study comparing fetal cystoscopy with vesicoamniotic shunting. *Ultrasound Obstet Gynecol* 2015;45:452–458.
- 18 Morris RK, Malin GL, Quinlan-Jones E, Middleton LJ, Hemming K, Burke D, Daniels JP, Khan SK, Deeks J, Kilby MD; Percutaneous vesicoamniotic shunting in Lower Urinary Tract Obstruction (PLUTO) Collaborative Group: Percutaneous vesicoamniotic shunting versus conservative management for fetal lower urinary tract obstruction (PLUTO): a randomised trial. *Lancet* 2013;382:1496–1506.
- 19 Glick PL, Harrison MR, Noall RA, Villa RL: Correction of congenital hydronephrosis in utero III. Early mid-trimester ureteral obstruction produces renal dysplasia. *J Pediatr Surg* 1983;18:681–687.
- 20 McVary KT, Maizels M: Urinary obstruction reduces glomerulogenesis in the developing kidney: a model in the rabbit. *J Urol* 1989;142:646–651.
- 21 Haeri S: Fetal Lower Urinary Tract Obstruction (LUTO): a practical review for providers. *Matern Neonatol Perinatol* 2015;1:26.
- 22 Bernardes LS, Aksnes G, Saada J, Masse V, Elie C, Dumez Y, Lortat-Jacob SL, Benachi A: Keyhole sign: how specific is it for the diagnosis of posterior urethral valves? *Ultrasound Obstet Gynecol* 2009;34:419–423.
- 23 Ross JA, Jurkovic D, Zosmer N, Jauniaux E, Hackett E, Nicolaides KH: Umbilical cord cysts in early pregnancy. *Obstet Gynecol Surv* 1997;89:442–445.
- 24 Sepulveda W, Rompel SM, Cafici D, Carstens E, Dezerega V: Megacystis associated with an umbilical cord cyst: a sonographic feature of a patent urachus in the first trimester. *J Ultrasound Med* 2010;29:295–300.
- 25 Riddell JVB, Houle AM, Franc-Guimond J, Barrieras D: Prenatal vesico-allantoic cyst outcome – a spectrum from patent urachus to bladder exstrophy. *Prenat Diagn* 2015;35:1342–1346.
- 26 Sepulveda W, Rompel SM, Cafici D, Carstens E, Dezerega V: Megacystis associated with an umbilical cord cyst. *J Ultrasound Med* 2010;29:295–300.