

COMPARISON OF REAL-TIME ULTRASOUND APPROACH
TO NON ULTRASOUND-ASSISTED APPROACH
IN PARAMEDIAN LATERAL SPINAL ANAESTHESIA
FOR LOWER LIMB SURGERY

by

DR CHONG SOON EU

Dissertation Submitted in Partial Fulfillment of the Requirements For The
Degree Of Master Of Medicine
(ANAESTHESIOLOGY)



UNIVERSITI SAINS MALAYSIA

2015

ACHIEVEMENT

This clinical trial has won the first prize in the poster presentation during the Malaysian Society of Anaesthesiologists & College of Anaesthesiologists Annual Scientific Congress 2015 & 13th Asian Society of Paediatric Anaesthesiologists Congress held in Penang on the 11th – 14th June 2015.

ACKNOWLEDGEMENTS

I am thankful to God, whose guidance had led me to choose anaesthesia as my career and I am always grateful for that.

I am forever indebted to my parents Mr. Chong Hoe Hoi and Madam Tan Jew Sek whom no replacement can substitute their kindness and care, their enthusiasm and prayers, their patience and love in perpetuating and upholding virtues especially to their children.

My heartfelt gratitude to my beloved wife, Dr Lim Jo Anne, whose endurance and patience has become my inner strength and motivation.

My sincere appreciation to my mentor and supervisor, Dr Mohd Nikman Ahmad and Associate Professor Dr Saedah Ali, whose wisdom, knowledge and understanding are always beyond my grasp. To Professor Shamsul Kamalrujan, the Head of Anaesthesiology Department, HUSM, for his kind support. I would also like to acknowledge the Advance Medical and Dental Institute (AMDI), USM for funding this clinical trial.

I would also like to thank to Dr Wan Nor Arifin Wan Mansor and Dr Kueh Yee Cheng from Department of Biostatistics, for providing the help and guidance in data analysis and interpretation. Lastly, I would like to thank my fellow colleagues, staff nurses, OT attendants and all the patients who willingly participated in the study. May their support and benevolence earn His acceptance and recognition.

TABLE OF CONTENTS

ACHIEVEMENT	i
ACKNOWLEDGEMENTS	ii
TABLE OF CONTENTS	iii
LIST OF FIGURES	viii
LIST OF TABLES	x
LIST OF ABBREVIATIONS	xii
DEFINITIONS	xiv
ABSTRAK	xvi
ABSTRACT	xviii
1 INTRODUCTION	1
2 LITERATURE REVIEW	3
2.1 Spinal Anaesthesia	3
2.2 The Spinal Cord	3
2.2.1 Anatomy of spinal Cord and Vertebra Column	3
2.2.2 Layers	5
2.2.3 Surface Anatomy	6
2.3 Clinical Considerations to Spinal Anaesthesia	7

2.3.1	Indications and Advantage	7
2.3.2	Contraindications of spinal Anaesthesia	7
2.3.3	Preparation of spinal Anaesthesia	8
2.3.4	Patient Positioning	9
2.3.4.	(a) Sitting Position	9
2.3.4.	(b) Lateral Position	9
2.3.4.	(c) Buie's (Jackknife) Position	10
2.3.5	Local Anaesthetics	10
2.3.6	Anatomical Approach	12
2.3.6.	(i) Midline approach of Spinal Anaesthesia	12
2.3.6.	(ii) Paramedian approach of Spinal Anaesthesia	14
2.3.6.	(iii) Why Paramedian Approach was Chosen?	15
2.4	Ultrasound Guided Spinal Anaesthesia	17
2.4.1	Why using ultrasound guidance in spinal anaesthesia?	17
2.4.2	Equipment	19
2.4.2.	(i) Spinal Needle Selection	19
2.4.2.	(ii) Concept of Ultrasound	20
2.4.2.	(iii) Ultrasound Machine	23
2.4.2.	(iv) Different Types of Probe and Probe Selection	24
2.4.2.	(v) Ultrasound Scan Planes	25
2.4.2.	(vi) Probe orientation	26
2.4.2.	(vi) (a) Transverse view	27
2.4.2.	(vi) (b) Longitudinal view	28

2.4.2.	(vi)	(c)	Paramedian View	30
2.4.2.	(vii)		Preparing A Sterile Probe	31
2.4.2.	(viii)		Ultrasound Imaging of the Spine	32
2.4.2.	(ix)		The water-based spine phantom	32
2.5			Real-time Ultrasound in Paramedian Approach	34
2.5.1			Real-time Ultrasound-guided lumbar puncture	35
2.6			Confirmation of Spinal Anaesthesia Blockade	37
2.6.1			Afferent function	38
2.6.2			Efferent function	38
2.6.3			Routine methods	39
2.6.4			Anatomical innervations	40
2.7			Complications	41
2.7.1			Bloody Tap	41
2.7.2			Failed Spinal Anaesthesia	41
2.7.3			Post Dural Puncture Backache (PDPB)	42
2.7.4			Postdural Puncture Headache (PDPH)	43
2.7.5			High Spinal Anaesthesia	44
2.7.6			Cardiovascular Collapse	46
2.7.7			Cauda Equina Syndrome	47
2.7.8			Spinal Hematoma	48
2.7.9			Permanent Neurologic Injury	50
2.7.10			Meningitis	51

3	OBJECTIVES	52
3.1	General Objectives	52
3.2	Specific Objectives	52
3.3	Study Hypothesis	53
3.4	Justification of the Study	53
4	METHODOLOGY	55
4.1	Study Design	55
4.2	Study Period	55
4.3	Study Sample	55
4.4	Sample Size Calculation	56
4.5	Sampling Method	58
4.6	Inclusion Criteria	59
4.7	Exclusion Criteria	59
4.8	Apparatus	60
4.9	Study Protocol	61
5	RESULTS AND DATA ANALYSIS	68
5.1	Patients' Characteristics	68
5.2	Success Rate between Ultrasound and Palpation Groups	71
5.3	Success Rate of Single Needle Pass between Groups	72
5.4	Durations for Successful Needle Puncture and Total Procedure	73
5.5	Complications	74
5.6	Influence of BMI on number of Attempt	76
5.7	Vital Signs	81

6	DISCUSSION	
6.1	Overview	83
6.2	Demographic Data between Studied Populations	83
6.3	Attempt of Spinal Anaesthesia	84
6.4	Single Needle Pass	87
6.5	Duration of Successful Puncture and Duration of Procedure	89
6.6	Complication Rate	90
6.7	Influence of BMI on number of Attempt	92
6.8	Haemodynamic Stability	94
7	STUDY LIMITATIONS	95
8	CONCLUSION	97
	REFERENCES	98
	APPENDICES	116
I	Data Collection Sheet	116
II	Patient Information and Consent Forms	118
III	Test of Normality	124

LIST OF FIGURES

Figure 1:	Cross Section of the Spinal Canal	5
Figure 2:	Midline vs. Paramedian Spinal Anaesthesia Approach	14
Figure 3:	Paramedian Approach of Spinal Anaesthesia	14
Figure 4:	Transmission, Reflection and Reception of Ultrasound Wave	22
Figure 5:	Different Types of Ultrasound Probes	25
Figure 6:	Anatomic Planes of the Body	26
Figure 7:	Transverse View of Lumbar Spine	27
Figure 8:	Cross Sectional View from Transverse View of Lumbar Spine	27
Figure 9:	Longitudinal View of Spine	28
Figure 10:	Longitudinal View of Two Adjacent Spinous Processes	28
Figure 11:	Pre-procedural Labeling	29
Figure 12:	Paramedian Sagittal Scan of the Lumbar Spine	30
Figure 13:	Preparation of Sterile Probe	31
Figure 14:	The Water-Based Spine Phantom	33
Figure 15:	Paramedian Sagittal View from the Water-Based Spine Phantom	35

Figure 16:	Paramedian Sagittal Sonogram of the Lumbosacral Junction	37
Figure 17:	Level of Spinal Dermatomes	40
Figure 18:	The Sonosite M-Turbo Ultrasound System	60
Figure 19:	Patient Positioned in Lateral Position	62
Figure 20:	Identification of Sacrum and Lumbar Vertebra	63
Figure 21:	Paramedian Oblique Sagittal (PMOS) View	64
Figure 22:	Insertion of Introducer and Spinal Needle	65
Figure 23:	Mean Arterial Pressure between Ultrasound Group versus Palpation Group	81
Figure 24:	Mean Heart Rate between Ultrasound Group versus Palpation Group	82

LIST OF TABLES

Table 2.1:	Speed of Ultrasound Wave in Various Tissue	21
Table 2.2:	Buttons & Dials on Ultrasound Machine	23
Table 2.3:	Bromage Scale	38
Table 5.1:	Descriptive Statistic of Numerical Variables and Mean Difference between Ultrasound and Palpation Group	69
Table 5.2:	Descriptive Statistic of Categorical Variable and its Association with Ultrasound and Palpation Group	70
Table 5.3:	Comparison Number of Attempt between Ultrasound and Palpation Group	71
Table 5.4:	Comparison Number of Successful Single Needle Pass between Ultrasound and Palpation Group	72
Table 5.5:	Comparison Puncture Time and Total Procedure Time between Ultrasound and Palpation Group	73
Table 5.6:	Comparison of Complication Rate between Ultrasound and Palpation Group	75
Table 5.7:	Comparison of BMI Group between Ultrasound and Palpation Group	76

Table 5.8:	Comparison Number of Single Needle Pass amongst patients with BMI < 25 between Ultrasound and Palpation Group	77
Table 5.9:	Comparison Number of Single Needle Pass amongst patients with BMI \geq 25 between Ultrasound and Palpation Group	78
Table 5.10:	Comparison Number of attempt amongst patients with BMI < 25 between Ultrasound and Palpation Group	79
Table 5.11:	Comparison Number of attempt amongst patients with BMI > 25 between Ultrasound and Palpation Group	80

LIST OF ABBREVIATIONS

ACLS	Advanced Cardiac Life Support
AC	anterior complex
ASA	American Society of Anaesthesiologists
ASRA	American Society of Regional Anaesthesia
BP	blood pressure
BBB	blood brain barrier
CBF	cerebral blood flow
CNS	central nervous system
CSE	combined spinal epidural
ESM	erector spinae muscle
ES	epidural space
ECG	electrocardiogram
GA	general anaesthesia
HR	heart rate
IV	intravenous
ITS	intrathecal space

LF	ligamentum flavum
MAP	mean blood pressure
NICE	National Institute for Health & Clinical Excellence
NMDA	N-Methyl-D-Aspartate
OT	operation theater
PCA	patient-controlled-analgesia
PD	posterior dura
PDPB	post dural puncture backache
PDPH	postdural puncture headache
PMOS	paramedian oblique sagittal
PMOSS	paramedian oblique sagittal scan
PONV	post-operative nausea and vomiting
SD	standard deviation
SpO ₂	oxygen saturation
VAS	visual analogue scale

DEFINITIONS

ASA (American Society of Anaesthesiologists) Classification

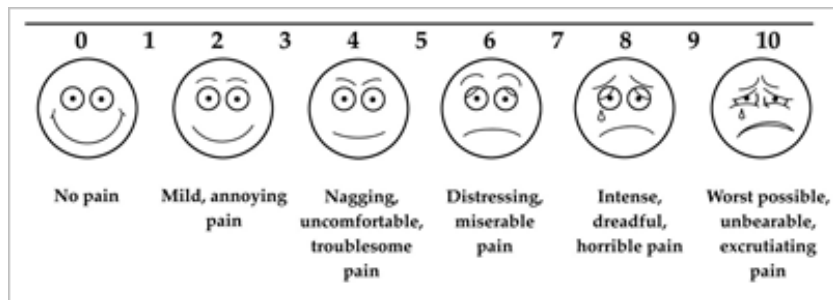
Class I	Healthy, non-smoking patient, no medical problems
Class II	Mild systemic disease
Class III	Severe systemic disease, but not incapacitating
Class IV	Severe systemic disease that is a constant threat to life
Class V	Moribund, not expected to live 24 hours irrespective of operation
Class VI	A declared brain-dead patient whose organs are being removed for donor purposes

An 'E' is added to the status number to designate an emergency surgery.

(Adapted from www.asahq.org)

Visual Analogue Scale (VAS)

A Visual Analogue Scale (VAS) is a measurement instrument that tries to measure a characteristic or attitude which is presumed to range across continuous values and cannot easily be measured directly. VAS is usually presented as a horizontal line, 10 cm in length, explained by word descriptors at each end (as shown below). The patient marks at the point on the line that they feel represent their perception of current state of pain.



(Adapted from Wong DL, Perry SE, Hockenberry MJ *et al.* 2002)

ABSTRAK

Tajuk: Kajian Perbandingan antara bantuan ultrasound-masa-nyata dan tanpa-bantuan-ultrasound semasa pembiusan spinal pendekatan paramedian dalam kedudukan sisi untuk pembedahan anggota kaki.

Latar belakang: Bantuan ultrasound-masa-nyata dalam anesthesia spina merupakan satu teknik yang baru dalam bidang pembiusan. Kami menjalankan kajian ini untuk menentukan sama ada teknik ini memperbaiki anesthesia spina dari pelbagai aspek.

Objektif: Kajian ini bertujuan untuk membuat perbandingan antara bantuan ultrasound-masa-nyata dan tanpa-bantuan-ultrasound semasa pembiusan spinal pendekatan paramedian pada kedudukan sisi. Perbandingan dinilai dari segi kadar kejayaan dan kemampuan untuk mengurangkan bilangan tusukan jarum, serta kesan-kesannya.

Kaedah: Sebanyak 60 pesakit dewasa yang mempunyai indeks jisim tubuh (IJT, atau "BMI") kurang daripada 30 yang dirancang untuk pembedahan anggota kaki dipilih dalam kajian ini. Pemilihan pesakit adalah secara rawak dan pesakit-pesakit dibahagikan kepada kumpulan Ultrasound (bantuan ultrasound-masa-nyata) dengan kumpulan Palpasi (tanpa bantuan ultrasound). 30 pesakit dalam kumpulan Ultrasound menjalani pembiusan spinal pendekatan paramedian dalam kedudukan sisi dengan bantuan ultrasound-masa-nyata. 30 pesakit dalam kumpulan Palpasi pula menjalani pembiusan spinal pendekatan paramedian dalam kedudukan sisi dengan cara standard, iaitu tanpa bantuan ultrasound. Ciri-ciri pesakit, bilangan tusukan dan ulangan tolakan jarum spina untuk anastesia spina yang

berjaya, jumlah masa tusukan, jangkamasa masa prosedur, komplikasi serta-merta, komplikasi lewat dan perubahan tanda-tanda vital dikaji.

Keputusan: Data dermografi adalah setara antara kumpulan. Kumpulan Ultrasound menunjukkan kadar kejayaan yang lebih tinggi dalam tusukan dura pada percubaan pertama berbanding kumpulan Palpasi (86.7% vs. 43.3%, $p < 0.01$). Kumpulan Ultrasound turut menunjukkan kadar kejayaan yang lebih tinggi dalam tusukan dura pada tolakan tunggal berbanding kumpulan Palpasi (46.7% vs. 20%, $p = 0.028$).

Antara pesakit yang berlebihan berat badan atau “overweight” ($BMI \geq 25$), kadar kejayaan tusukan dura pada percubaan pertama untuk kumpulan Ultrasound adalah 17 pesakit (85%) berbanding kumpulan Palpasi, iaitu 6 pesakit (33.3%) ($p = 0.001$). Kadar kejayaan tusukan dura pada tolakan tunggal juga menunjukkan perbezaan yang ketara antara kumpulan Ultrasound dan Kumpulan Palpasi (50% vs. 16.7%, $p = 0.033$). Bagaimanapun, antara pesakit-pesakit yang mempunyai indeks jisim tubuh < 25 , perbezaan antara kedua-dua kumpulan untuk kedua-dua ciri-ciri tersebut adalah tidak ketara. Jangkamasa diambil untuk mendapatkan tusukan dura adalah (0.69 ± 1.01) minit untuk kumpulan Ultrasound dan (1.60 ± 1.19) minit dalam kumpulan Palpasi. ($p = 0.002$).

Kesimpulan: Bantuan ultrasound-masa-nyata meningkatkan kadar kejayaan tusukan dura pada percubaan pertama dan dapat mencapai kadar tolakan tunggal yang lebih tinggi berbanding dengan kaedah klasik yang tidak menggunakan ultrasound. Perbezaan ini adalah ketara terutamanya dalam kalangan pesakit yang berlebihan berat badan ($BMI \geq 25$).

Kata Kunci: Bantuan ultrasound-masa-nyata / paramedian / anestesia spina / sisi.

ABSTRACT

Title: Comparison of real-time ultrasound approach to non ultrasound-assisted approach in paramedian lateral spinal anaesthesia for lower limb surgery.

Background: Real-time ultrasound-guided neuraxial blockade remains a largely experimental technique. We investigated if this technique might improve the approach of spinal anaesthesia in different aspects.

Objectives: To compare the clinical efficacy of real-time ultrasonographic localization of the intrathecal space by comparing success rate, first needle pass and immediate complications.

Methods: 60 patients with BMI less than 30 kg/m² undergoing lower limb surgery under spinal anaesthesia were recruited. Following palpation and a pre-procedural ultrasound scan, a spinal needle introducer was inserted in-plane to the ultrasound probe. The angle of introducer was adjusted in real-time until it pointed in between two vertebral laminae. A 25G Pencan spinal needle was inserted. Successful dural puncture was confirmed by backflow of cerebrospinal fluid. This was compared to paramedian spinal anaesthesia via palpation method.

Results: There were no differences in age, weight, height, BMI, or ASA grading between the two groups. Successful dural puncture on first skin puncture was significantly higher in the ultrasound group than palpation group (86.7% vs. 43.3%, $P<0.01$). The success rate of single needle pass was also significantly higher in the ultrasound group (46.7% vs. 20%, $p=0.028$).

Among the overweight ($BMI\geq 25$) patients, dural puncture was successful on the first skin puncture in 17 patients (85%) in ultrasound group vs. 6 patients (33.3%) in palpation group. ($p=0.001$). Successful rate of single needle pass was also significant in ultrasound group (50% vs. 16.7%, $p = 0.033$). Amongst patients with $BMI<25$, there were no significant difference in both groups.

Duration taken for determining puncture site was (0.69 ± 1.01) minutes in the ultrasound group and (1.60 ± 1.19) minutes in the palpation group. ($p=0.002$).

Conclusion: Real-time ultrasound-guidance improves the success rate of paramedian spinal anaesthesia in lateral position, especially in overweight patients. It has not much of role in patients who are thin and have easily palpable spinous process.

Key words: Real-time ultrasound-guided / paramedian / spinal anaesthesia / lateral

CHAPTER 1: INTRODUCTION

Spinal anaesthesia, also known as subarachnoid block, is one the most commonly used anesthetic technique for patients undergoing lower limb surgery. This technique of anaesthesia has been advancing for more than a hundred years. (Looseley 2009, Wulf 1998, Arthur 1907, Bier 1899)

A successful subarachnoid block is dependent on accuracy of the puncture site, which is usually located by anaesthetist via palpation of anatomical landmarks.

However, study has shown that accuracy of identifying interspace by palpation method is only 29% (Broadbent 2000). Apart from increasing success rate of block, the choice of interspace is important as the spinal needle should not be introduced at a level that may cause it to enter the spinal cord. (Ellis 2008)

In order to increase success rate of subarachnoid block, patient should also be asked to flex his or her spine as much as possible, thereby widening the gaps between the lumbar spinous processes.

As some of the orthopedic patients are unable to sit up due to pain, frailness or degenerative changes of joints, flexion of spine is sometimes difficult to be performed. Hence, the identification of the puncture site may become more difficult, and repeated needle probing is needed, causing increased risk of hematoma, neurological damage, infection, bloody tap, post-dural puncture back pain or headache. (Horlocker 2000, Bromage 1997)

Paramedian approach of spinal anaesthesia may be particularly useful in this type of patients, or in those patients whose supraspinous or interspinous ligaments are so calcified that passage of a needle through them are difficult. (Ellis 2004)

Recent studies have shown that ultrasound may facilitate identification of the lumbar intervertebral space and improve the success rate of central neuraxial blockade. This has been shown to be particularly valuable in patients with challenging anatomy. (Grau 2001, 2002, Chin 2009)

Real-time ultrasound-guided neuraxial blockade (Chin 2009, Wang 2012, Grau 2012) which was described in the past decade has also shown promising result of greater precision to delineate the underlying anatomy, enabling a more accurate angulations of spinal needle. The optimum window for real-time-ultrasound image to access the intrathecal space is paramedian approach (Grau 2001)

However, the application of real-time ultrasound guided spinal anaesthesia has so far been mainly limited to be descriptive observational study and not a comparative randomised controlled trial (Conroy 2012).

We therefore designed this randomized controlled trial among orthopaedic patients to determine whether real-time ultrasound imaging improves the success rate of paramedian spinal anaesthesia when patient lying laterally. We are interested to know if this new technique might improve quality of spinal anaesthesia in different aspects.

CHAPTER 2: LITERATURE REVIEW

2.1 Spinal Anaesthesia

Spinal anaesthesia, also known as sub-arachnoid block (SAB), is one of the regional anaesthesia techniques by injecting local anaesthetic drugs into the subarachnoid space, through a spinal needle. (Barash 2005) Spinal anaesthesia was first reported being performed in human in a surgery by August Bier in 1899 (Bier 1899, Wulf 1998). It is indicated in surgical procedures to the lower body.

Spinal Anaesthesia results in a rapid onset of block, usually within 5 to 30 minutes. The local anaesthetics injected mainly acts at spinal nerve roots. Smaller sympathetic fibres are more easily blocked than larger sensory and motor fibres. Hence, the 'sympathetic' level is higher than the sensory level (Barash 2005).

2.2 The Spinal Cord

2.2.1 Anatomy of spinal Cord and Vertebra Column

The spinal cord is a long, thin, tubular bundle of nervous tissue that extends from the medulla oblongata to the lumbar region of the vertebral column. It is part of the central nervous system (CNS). In a normal adult, the spinal cord is around 45 cm in men and

around 43 cm long in women. Also, the spinal cord has a varying width, ranging from 13 mm thick in the cervical and lumbar regions to 6.4 mm thick in the thoracic area.

Before reaching adulthood, the length of the spinal cord varies according to age. In the first trimester, the spinal cord extends to the whole spinal column. As the fetus grows, the vertebral column lengthens more than the spinal cord. At birth, the spinal cord ends at approximately L3 and in the adult, the cord terminates at approximately L1/L2. 30% of people having a cord that ends at T12 and 10% at L3. (Boon 2004; Reimann 1944, cited by Barash 2005).

The enclosing bony vertebral column protects the relatively shorter spinal cord, provides structural support for body and allows a degree of mobility. The spine is composed of vertebral bones and intervertebral disks. There are 7 cervical, 12 thoracic, 5 Lumbar vertebrae.

Lower nerve roots of spinal cord course some distance before exiting the intervertebral foramina. These lower spinal nerves form the cauda equina (“Horse tail”). Damage to cauda equina is unlikely, as these nerve roots float in dural sac below L1 and tend to be pushed away by advancing needle. Thus, performing lumbar puncture below L1 in adult usually avoid potential needle trauma to the spinal cord. (Butterworth 2013)

The length of the spinal cord must always be kept in mind when a neuraxial anesthetic is performed, as injection into the cord can cause great damage and result in paralysis. (Bromage 1997).

The spinal cord has three major functions. First, it functions as a conduit for motor information, which travels down the spinal cord. Second, it also functions as a conduit for sensory information in the reverse direction. Finally, it also acts as a center for coordinating certain reflexes in the body.

2.2.2 Layers

The layers passed through during midline approach of subarachnoid block are: skin, subcutaneous fat, supraspinous ligament, interspinous ligament, ligamentum flavum, epidural space, dura, subdural space, arachnoid mater, and the subarachnoid space.

(Ankorn1993) (Figure 1)

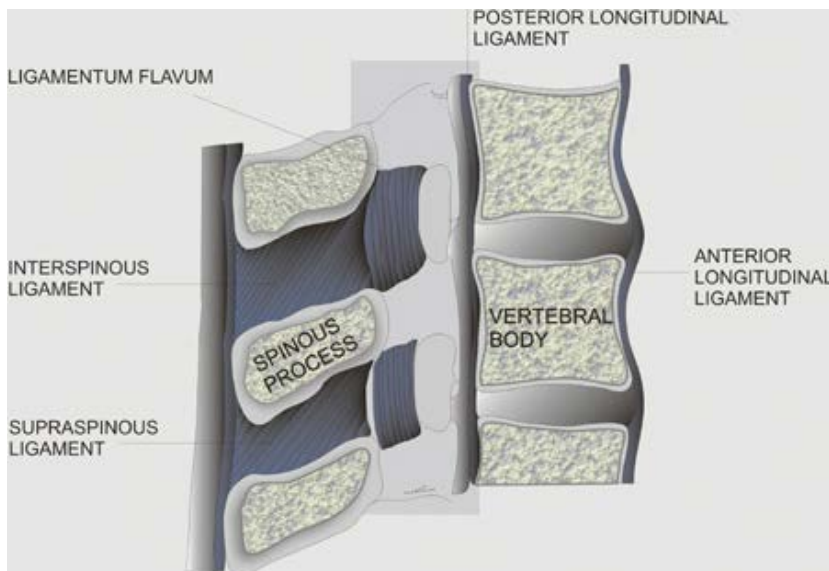


Figure 1: Cross section of the spinal canal is shown with the ligaments, vertebral body, and spinous processes. (source: www.nysora.com)

On the other hand, during paramedian approach of subarachnoid block, the spinal needle pass through the skin, subcutaneous tissues, ligamentum flavum, dura mater, subdural space, arachnoid mater, and then passes into the subarachnoid space.

2.2.3 Surface Anatomy

The line joining the iliac crests is called Tuffier's line. Traditionally, Identification of iliac crests is used to approximately determine the location of the vertebral body of L4. (Tuffier 1901, cited by Snider 2011). However, studies have shown that Tuffier's line demonstrated predictable sex-related differences: men had an intercrystal line that most often intersected the L4 body or inferior end plate whereas the women's intercrystal line most often intersected the L5 body or superior end plate (Snider 2011). Nevertheless, in patients with BMI >30 kg/m², or in patients who are edematous, palpatory accuracy of lumbar vertebrae decreases. (Snider 2011)

The subarachnoid space extends laterally along the nerve roots to the dorsal root ganglia. The subarachnoid space ends at S2 in adults and lies lower in children. (Hansen 2014, Allman 2011)

2.3 Clinical Considerations to Spinal Anaesthesia

2.3.1 Indications and Advantage

Spinal anaesthesia has proved most useful in lower abdominal, inguinal, urogenital, rectal, and lower extremity surgery. Spinal anaesthesia is the technique of choice for Caesarean Section as it avoids a general anaesthetic and the risk of failed intubation. If surgery allows, spinal anaesthesia is very useful in patients with severe respiratory disease e.g. chronic obstructive pulmonary disease (COPD) as it avoids intubation and ventilation. It may also be very useful in patients with difficult airway.

2.3.2 Contraindications of spinal Anaesthesia

Absolute contraindications for spinal anaesthesia are allergic to local anaesthetics, patient refusal, localised skin infection, patient on anticoagulation therapy or coagulopathic with INR of more than 1.5, severe hypovolaemia, increased intracranial pressure, severe aortic or mitral stenosis. Relative contraindications of spinal anaesthesia include systemic sepsis, uncooperative patient, preexisting neurological deficits, demyelinating lesions, stenotic valvular heart lesions, severe spinal deformity is also one of the relative contraindication. Nevertheless, neurological diseases are also relatively contraindicated in view of medico-legal implications. (Malaysian Society of Anaesthesia 2013, Butterworth 2013)

2.3.3 Preparation of spinal Anaesthesia

Prior to spinal anaesthesia, full preoperative assessment of the patient, as for a general anaesthetic is required. Facilities for full monitoring, resuscitation and progression to general anaesthesia is mandatory. Good intravenous access must be available before performing this technique.

The patient will be placed sitting or lying laterally on one side. Back flexed to open the intervertebral spaces. The back should be cleaned using antiseptic solution, using an aseptic technique. Subsequently, anaesthetist will palpate the iliac crest to get approximate level of L4, and aim to identify the L3/4, L4/5 or L5/S1 interspace using Tuffier's line.

Skin of the chosen interspace is infiltrated with local anaesthetic. Spinal needle is inserted, aiming slightly cranially. Resistance increases as the ligamentum flavum is entered and when the dura is encountered, with a sudden "pop" sensation as the dura is punctured. Correct placement of the needle is confirmed by cerebrospinal fluid backflow of spinal needle.

Apart from obese and edematous patients, landmark-based approaches are less accurate in patients with anatomical variations or abnormalities, and frequently lead to incorrect identification of a given lumbar interspace. (Broadbent 2000).

Accurate identification of the subarachnoid space is paramount as multiple attempts at needle placement may cause patient discomfort, higher incidence of spinal hematoma, post-dural puncture headache, (Kenneth 2003, Zeidan 2006) and trauma to neural structures. (Adekola 2015, Horlocker 2000) Therefore, having alternative approaches may help improve success and mitigate the limitations of the current techniques.

2.3.4 Patient Positioning

2.3.4. (a) Sitting Position

The anatomic midline is often easier to appreciate when the patient is in sitting position than when the patient is in lateral decubitus position. Flexion of the spine maximizes the intervertebral space and brings the spine closer to skin surface. (Butterworth 2013)

2.3.4. (b) Lateral Position

In this position, patient lie on one side with knee flexed and pulled high against abdomen and chest, assuming a “fetal position”. (Butterworth 2013). Many clinicians prefer lateral position for neuraxial blocks , especially when patient are unable to sit up.

2.3.4. (c) Buie's (Jackknife) Position

This position is suitable for anorectal procedures. The advantage is that the block is done in the same position as the operative procedure, so that the patient does not have to be repositioned again after block. A prone position is typically used when fluoroscopic guidance is required.

2.3.5 Local Anaesthetic Used and Factors Influencing Level of Block

'Heavy' Bupivacaine (0.5% in 8% dextrose; specific gravity 1.026) is the local anaesthetic most commonly used to produce spinal anaesthesia, although lignocaine, ropivacaine, levobupivacaine may also be used. Sometimes, opioids are added to improve the block and provide post-operative pain relief. These include morphine, fentanyl, diamorphine or buprenorphine. Non-opioids like clonidine may also be added to prolong the duration of analgesia (for example clonidine, dexmedetomidine, magnesium).

The spread of hyperbaric 'heavy' bupivacaine in the CSF is affected by gravity and by posture. In patients with normal spinal anatomy, the apex of the thoracolumbar curvature is at T4. In the supine position, this should limit a hyperbaric solution to produce a level of anaesthesia at or below T4. When hyperbaric bupivacaine is injected in the mid-lumbar region at sitting position and the patient is placed supine immediately, blockade usually spreads to the mid-thoracic level (T4-T7). This is because the local anaesthetic agent will

move more cephalad to the dependent region defined by the thoracolumbar curve, as full protein binding has not yet occurred. When the patient remains in the sitting position for 1-2 minutes after injection, blockade only extend T7-T10. Spinal curvature might affect the ultimate level by changing the contour of the subarachnoid space. (Butterworth 2013)

When local anaesthetic agent is injected at L4-L5 level and the patient remains sitting for 3-5 min following injection, only the lower lumbar nerves and sacral nerves are blocked. a 'saddle blockade' is produced, which can be used for perineal surgery. When Hyperbaric anesthetics agent injected intrathecally with the patient in a lateral decubitus position, with the extremity to be operated on in a dependent position, and kept in this position for about 5 min following injection, the block will tend to be denser and achieve a higher level on the operative dependent side. This is called a unilateral block and is useful for unilateral lower extremity procedures. (Butterworth 2013)

Hyperbaric anesthetics injected intrathecally with the patient in a lateral decubitus position are useful for unilateral lower extremity procedures. The patient is placed laterally with the extremity to be operated on in a dependent position. If the patient is kept in this position for about 5 min following injection, the block will tend to be denser and achieve a higher level on the operative dependent side.

On the other hand, cerebrospinal fluid (CSF) volume inversely correlates with level of anesthesia. Increased intraabdominal pressure or any condition that causes engorgement of the epidural veins, thus decreasing CSF volume, are associated with a higher spinal

blockade. These conditions include pregnancy, ascites, and large abdominal tumors. In patients with these clinical situations, higher levels of anesthesia are achieved with a given dose of local anesthetic than would otherwise be expected.

Another factor affecting level of block is age. Age-related decreases in CSF volume are responsible for the higher anesthetic levels achieved in the elderly. Severe kyphosis or kyphoscoliosis can also be associated with a decreased volume of CSF and often results in a higher than expected level, especially with a hypobaric agent or a rapid injection technique. (Butterworth 2013)

Bupivacaine and dextrose are not metabolized in the CSF, but are taken up by the spinal cord or absorbed by spinal arteries, which form a vascular network in the pia mater. (Calvey 2009)

2.3.6 Anatomic Approach

2.3.6. (i) Midline approach of Spinal Anaesthesia

The spine is palpated, the depression between spinous process of desired space felt, and spinal needle is introduced in the midline. The needle is advanced forward penetrating the ligamentum flavum and dura-subarachnoid membrane, giving the “pop” sensation. This will be followed by a freely backflow of cerebrospinal fluid (Butterworth 2013,

www.nysora.com). Midline approach is the most common technique when spinal anaesthesia is performed. (Wantman 2006)

2.3.6. (ii) Paramedian approach of Spinal Anaesthesia

Spinal anaesthesia can also be given from paramedian approach. The advantage of the paramedian approach is a larger target. (Ellis 2008, International federation of nurse anesthetists 2014). By placing the needle laterally, the anatomical limitation of the spinous process is avoided. (Baheti 2014).

For paramedian method of spinal anaesthesia, the approach is from lateral to midline. (Figure 2) Patient can be placed in sitting, lateral, or even prone jackknife position. This approach does not require much back flexion (Ellis 2008, Biawas 2012). Anaesthetist will palpate the spinous process and iliac crest, identify the Tuffier's line and correct level. He will then infiltrate the skin with local anaesthetic 1.5 cm lateral to the inferior border of the spinous process at the interspace. The needle inserted at this point, and directed towards the middle of the interspace by angling it $\sim 45^\circ$ cephalic with just enough medial angulations ($\sim 15^\circ$). (Figure 3) If the lamina is engaged, walk the needle off its cranial edge in a cephalic direction until it passes through the ligamentum flavum. (Barash 2005, Ellis 2008).

The paramedian technique has been performed since more than a century ago. Professor Arthur EB at the University of London, reported on this technique in 1907, including general believe that its more easier to perform midline over paramedian dural puncture.

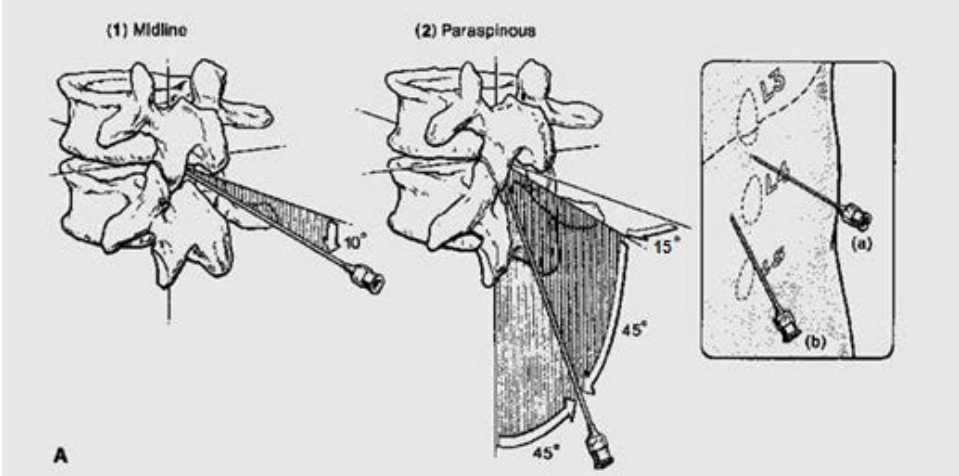


Figure 2: Midline vs. Paramedian Spinal Anaesthesia Approach (Cousins 1998)

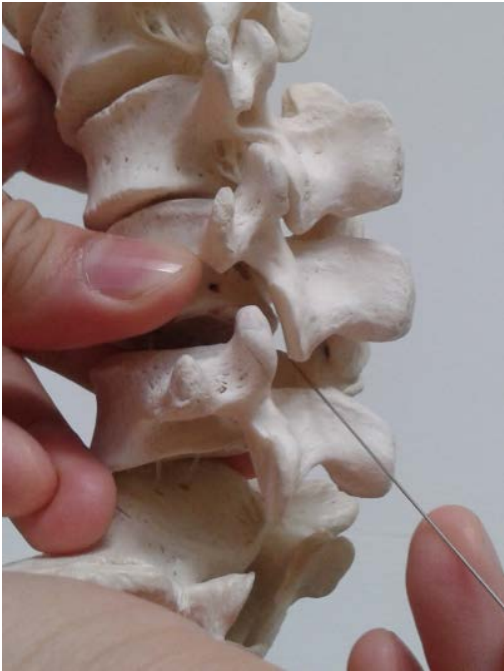

Figure 3: Paramedian Approach of Spinal Anaesthesia (Photo by: Chong SE)

2.3.6. (iii) Why Paramedian Approach was Chosen?

Studies have shown that midline approach of spinal anaesthesia is often technically difficult in certain group of patients. One of them is the geriatric population because of degenerative changes in the structural elements of the spine (Rabinowitz 2007, Ellis 2008) Thus, a paramedian approach may be more appropriate in this patient population because it is less affected by osteoarthritis changes.

K.C. Khanduri has shown that there is a high success rate of paramedian approach of spinal anaesthesia and several various advantage of this technique in 2002. By using the paramedian technique, anaesthetist can use a smaller size spinal needle because they can avoid from transversing through the calcified supraspinous & interspinous ligaments. This will reduce the incidence of PDPH. Hence, spinal anaesthesia using lateral paramedian approach seems to be a better option. (Ghaleb 2012, Mosaffa 2011, Shaikh 2008, Khanduri 2002) Apart from that, Haider *et al.* also reported in 2005 that incidence of PDPH was demonstrated to be lower with paramedian approach as compared to the midline for dural puncture. The ease of dural puncture was noted with paramedian approach. This was a possible explanation because multiple small dural holes can result in the same loss of CSF as from one large hole, which in turn result in headache. (Kenneth 2003)

Paramedian approach of spinal anaesthesia had also shown an increased in success rate in elderly and patients with difficult spine. In 2007, Study by Robinowitz revealed that paramedian approach is associated with a higher success rate compare to midline approach

in elderly patients, during the combined spinal epidural anaesthesia. In 1994, Muranaka K. and colleagues concluded that though the paramedian approach of spinal epidural anaesthesia may be extremely useful for patients with a midline scar or for those with a rigid spine, just that it required a longer spinal needle compared to the median approach. Bowens and colleagues also reported a case in 2013 in which computed tomography was used to guide placement of an epidural catheter in a patient with severe scoliosis and congenital dwarfism by using paramedian approach.

In 1989, Blomberg *et al.* compared the midline and paramedian approaches for lumbar epidural block and concluded that the paramedian approach was superior due to the following reasons:

1. Easier to locate the epidural space and reduced incidence of technical and catheter-related problems - extreme flexion of the back to open up the interlaminar space is not required;
2. Higher success rate;
3. Reduced risk of trauma to the epidural veins and lower incidence of epidural vein cannulation;
4. Less paraesthesia on catheter insertion and fewer traumas to the ligaments of the back, with fewer complaints of postpartum backache;
5. Easier catheter insertion - the needle is angulated substantially more cephalic resulting in less “tenting” of the dura and a straighter catheter path.

2.4 Ultrasound Guided Spinal Anaesthesia

2.4.1 Why using ultrasound guidance in spinal anaesthesia?

Ultrasound for lumbar puncture was first reported in the Russian literature in 1971. Yeo and French, in 1999, were the first to describe the successful use of Ultrasound to assist spinal injection in a patient with abnormal spinal anatomy. They used Ultrasound to locate the vertebral midline in a patient with severe scoliosis with Harrington rods in situ.

Subsequently it is followed by few case reports by anaesthetist on ultrasound guidance spinal anaesthesia on difficult spine. (Costello 2008, Prasad 2008, McLeod 2005).

Ultrasound has also been reported to guide lumbar punctures by radiologists (Coley 2001) and emergency physicians (Peterson 2014, Nomura 2007).

Most studies currently accessed the usage of prepuncture ultrasound. A prepuncture ultrasound scan allows the operator to identify the midline and accurately determine the interspace for needle insertion. (Karmakar 2009b, Grau 2005) This is useful in patients in whom anatomic landmarks are difficult to palpate, such as in those with obesity (Carvalho 2008, Yeo 1999), or edema of the back, or abnormal anatomy, such as scoliosis. (Bowens 2013, Costello 2008) More and more evidence suggests that a ultrasound examination performed before the epidural puncture improves the success rate of epidural access on the first attempt (Grau 2004), reduces the number of puncture attempts (Vallejo 2010, Grau 2002), and also improves patient comfort during the procedure. (Grau 2002)

Nevertheless, ultrasound imaging has been shown to be superior to palpation in correctly identifying lumbar intervertebral level. (Schlotterbeck 2008)

Usage of real-time ultrasound facilitates spinal anaesthesia in adults with severe scoliosis has avoided general anaesthesia in the patients with associated severe restrictive lung disease. (Chin 2010) Sometimes, elderly patients also have deformation of the spine by compression fracture or abnormal calcification. Real-time ultrasound guidance can also be helpful for optimal needle manipulation. (Yamauchi 2012)

On the other hand, study done by Grau in 2004 showed that real-time guidance facilitated performance of combined spinal-epidural by allowing fewer attempt to get a higher success rate of interspinal access. Recently, there was more and more study done to prove that real-time ultrasound-guidance was feasible and was able to improve patient's satisfaction during spinal anaesthesia (Niazi 2014, Brinkmann 2013, and Grau 2012)

Real-time ultrasound-guided spinal anaesthesia, despite its promise of greater precision, remains at present a largely experimental technique, mainly due to the technical difficulty associated with maintaining adequate target and needle tip visualization throughout the procedure. (Niazi 2014, Conroy 2012) Few researchers has overcome this problem with The SonixGPS® system (Brinkmann 2013 Niazi and Chin 2014). However, The SonixGPS is a relatively expensive technique and might not be cost effective. Prior to this study, we have found out usage of introducer do aid in visualization and angulations of spinal needle in order to perform a successful dural puncture.

In January 2008, National Institute for Health & Clinical Excellence (NICE) issued guidance on the use of ultrasound imaging to facilitate epidural catheter insertion. It recommended an ultrasound scan of the patient's lumbar spine prior to procedure so that the midline and middle of an interspinous space can be located and marked. At the same time, the estimated depth of skin to epidural space can also be determined. This is followed by needle insertion using the traditional 'loss-of-resistance' technique. The guidance also recommended that epidural puncture may also be performed under continuous real-time ultrasound-guidance according to familiarity of performer. Until now, there is still no guidance stated on ultrasound guided spinal anaesthesia.

2.4.2 Equipment

The equipment required for regional anaesthesia are widely available such as spinal needles, syringes, local anaesthetic drugs, gauze, sterile cleansing solutions, sterile gloves, mask, and larger clear sterile fenestrated drape. For ultrasound guided spinal anaesthesia, a marking pen is needed.

2.4.2. (i) Spinal Needle Selection.

Spinal needle with smaller gauge and introducer is preferred as it reduces the attempt of redirection and does not lead to extra risk of post-dural puncture headache or backache

(International federation of nurse anesthetics, 2014). Moreover, 18G introducer will be easier to be seen under ultrasound. Small size in gauge, pencil point (Whitacare, pengan) spinal needle is recommended due to decreased incidence of post-dural-puncture headache (Vallejo 2000, Jabbari 2012). 22-Gauge needle maybe useful for difficult blocks but has a higher risk of PDPH. (Chu 2011).

Apart from that, there is a bedside ultrasound machine used in this study, and the equipments to maintain its sterility during the procedure e.g. Tegaderm and sterile cover.

2.4.2. (ii) Concept of Ultrasound

Ultrasound is a form of acoustic energy which is generated when multiple piezoelectric crystals in a transducer vibrate at high frequency in response to an alternating current. The propagation velocity of these sound waves (acoustic velocity) is fairly constant in the human body and is approximately 1540 meters per second for soft tissue and 4000meters per second for bones. The greater the tissue density, the faster the ultrasound wave will travel. (Table 2.1)

Medium	Ultrasound Speed (m/sec)
Air	300
Lung	500
Fat	1,450
Soft Tissue	1,540
Bone	4,000

Table 2.1: Speed of ultrasound in various tissue (Source: Arbona FL, 2011 : Ultrasound-Guided Regional Anaesthesia, page 11)

The ultrasound waves must bounce off the tissues and return to the probe in order to generate a clinically useful image. Reflection occurs when sound waves encounter tissues with different acoustic impedance. Bone has very high tissue impedance and reflects a hyperechoic (white) image to the transducer, with an area of anechoic (black) "shadowing" just behind the image. In spinal imaging the identification of bony landmarks is important in locating the interspinous space.

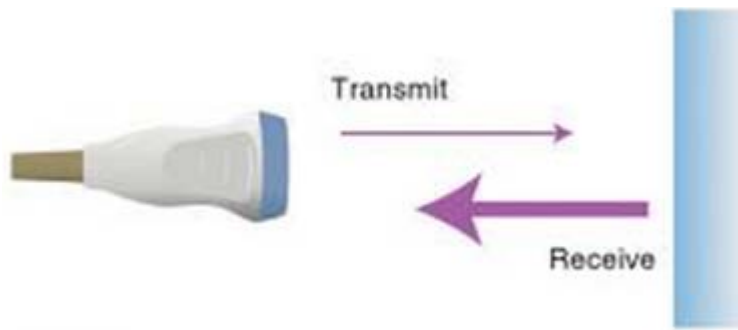


Figure 4: Transmission, Reflection and Reception (Source: Arbona FL 2011, Ultrasound-Guided Regional Anaesthesia, page 11)

After producing the sound wave, the probe switches to a receiving mode and the piezoelectric crystals will vibrate again, this time transforming the sound energy into electrical energy. (Figure 4) This process of transmission, reflection and reception can be repeated more than 7000 times a second. When coupled to an ultrasound machine, it will be processed and produce a real-time 2-Dimensional image that appears seamless.

Ultrasound machines can typically deliver sound waves of 2–15 MHz. The higher the frequency, the better the resolution it can show but the less the penetration depth it can achieve. In the ultrasound guided spinal anaesthesia, a low frequency curvilinear probe is usually used as the depth of structure is quite deep, with a relatively lower resolution.

Signals of least intensity appear dark (hypoechoic) or black as with body fluids, while signals of greatest intensity appear white (hyperechoic) as with bones and with intermediate intensities appearing in between these two, e.g. soft tissues.

2.4.2. (iii) Ultrasound Machine

The basic ultrasound machine contains a number of dials and buttons. It should be understood that only a few of these buttons and dials are required for daily working of the machine. These buttons and dials should be known as they can enhance our image and help to identify key anatomical structures in the image (Table 2.2).

Depth	Allows the depth of the image to be changed, from 2.3cm to a depth of 16cms
Focus	This allows the user to focus at a certain depth in the image
Save	This button is important as it allows the user to save any images or videos they find interesting
Colour	Allows the user to apply colour to an image. This is useful in identifying vascular structures. The colour which is either red or blue does not indicate direction of flow if the probe is placed on the vessel at a cross section.
Doppler	Is available on all machines and provides a Doppler sound and image if placed on a vessel. Doppler, like colour can be used to identify an artery.
Gain	This allows the user to brighten or darken the grey scale image. This will make the image easier to be seen and will help to highlight various structures in the image.

Table 2.2 : Buttons & Dials on Ultrasound Machine (source : www.usra.ca)

2.4.2. (iv) Different Types of Probe and Probe Selection

Three types probe are used for the vast majority of 2D ultrasound imaging:

a. Linear arrays

- High frequency (6–13 MHz). These provide the greatest axial resolution, but the higher the frequency the more attenuation occurs as they pass through the tissues, limiting the depth of penetration. Best for superficial structures (*e.g.* brachial plexus).

b. Curvilinear arrays

- Low frequency (2–5 MHz). These are able to image deeper structures, but with a decreased axial resolution. Best for large or deep structures (*e.g.* sciatic nerve, abdomen, spine).

c. Phased arrays

- This probe consists of many small ultrasonic elements that can be pulsed individually. By varying the timing a tightly-focused, high resolution beam can be produced that may be electronically steered. This probe is mainly used for bedside echocardiography. (Figure 5)