



Središnja medicinska knjižnica

Pavlović I., Ruška B., Pavičić T., Krbot Skorić M., Crnošija L., Adamec I., Habek M. (2017) *Video head impulse test can detect brainstem dysfunction in multiple sclerosis*. *Multiple Sclerosis and Related Disorders*, 14. pp. 68-71. ISSN 2211-0348

<http://www.elsevier.com/locate/issn/22110348>

<http://www.sciencedirect.com/science/journal/22110348>

<http://dx.doi.org/10.1016/j.msard.2017.04.001>

<http://medlib.mef.hr/2903>

University of Zagreb Medical School Repository

<http://medlib.mef.hr/>

Video head impulse test can detect brainstem dysfunction in multiple sclerosis

Ivan Pavlović^{1*}, Berislav Ruška^{1*}, Tin Pavičić^{1*}, Magdalena Krbot Skorić², Luka Crnošija¹, Ivan Adamec², Mario Habek^{1,2}

¹ University Hospital Center Zagreb, Department of Neurology, Referral Center for Autonomic Nervous System Disorders, Zagreb, Croatia

² School of Medicine, University of Zagreb, Zagreb, Croatia

*These authors contributed equally.

Corresponding author:

Mario Habek, MD, PhD

University Department of Neurology, University Hospital Center Zagreb

Kišpatićeva 12

HR-10000 Zagreb

Croatia

Phone/Fax: +38512388033; e-mail: mhabek@mef.hr

Word count: 1999

Number of references: 28

Number of tables: 2

Number of figures: 1

Authors' contributions

Study concept and design: Habek. Acquisition of data: Pavlović, Ruška, Pavičić, Crnošija, Krbot Skorić, Adamec, Habek. Analysis and interpretation of data: Pavlović, Ruška, Pavičić, Crnošija, Krbot Skorić, Adamec, Habek. Drafting of the manuscript: Pavlović, Ruška, Pavičić. Critical revision of the manuscript for important intellectual content: Pavlović, Ruška, Pavičić, Crnošija, Krbot Skorić, Adamec, Habek. Administrative, technical, and material support: Pavlović, Ruška, Pavičić, Crnošija, Krbot Skorić, Adamec, Habek.

Financial & competing interest disclosure

None of the authors have relevant affiliations or financial involvement with any organization or entity with a financial interest in or financial conflict with the subject matter or materials discussed in the manuscript. This includes employment, consultancies, honoraria, stock ownership or options, expert testimony, grants or patents received or pending, or royalties. No writing assistance was utilized in the production of this manuscript.

Abstract

Background: The aim of this study was to investigate the potential role of video head impulse test (vHIT) in the detection of brainstem lesions in patients with multiple sclerosis (MS).

Methods: Sixty-eight participants were enrolled and divided into two groups: 39 healthy subjects (HC) (78 ears, 20 females, mean age $25,3\pm 6,3$) and 29 MS patients (58 ears, 14 females, mean age $33,7\pm 7,7$). Both groups underwent vHIT, and in MS group MRI was analyzed for the presence of brainstem lesions. vHIT pathology was defined as presence of overt saccades ($<200\text{ms}$) or lateral gain lower than 0.8 for lateral canal, and presence of overt saccades ($<200\text{ms}$) or posterior/anterior slope lower than 0.7.

Results: In HC, decreased gain on horizontal canals was found in 8 out of 78 ears (11%), while 16 out of 58 ears (38%) had pathological results in the MS group. Mean gain of the lateral canals (60ms) was significantly reduced in MS group compared to HC ($0.874\pm 0,143$ vs. $0.954\pm 0,170$, $p=0.004$, respectively). Compared to HC overt saccades <200 ms in the lateral canals ($p=0.018$) and in the posterior canals ($p=0.011$), overt saccades $>200\text{ms}$ in lateral ($p<0.001$), anterior ($p=0.019$) and posterior canals ($p=0.009$), and covert saccades in the anterior ($p=0.042$) and posterior canals ($p=0.046$) were more frequent in the MS group. There was statistically significant association between the presence of BS MR lesions and bilateral pathology on vHIT for lateral semicircular canal ($\chi(1)=3.982$, $p=0.046$).

Conclusion: These results indicate that vHIT can detect brainstem dysfunction in patients with MS.

Key Words: video head impulse test, vestibulo-ocular reflex, multiple sclerosis

Highlights:

- MS patients have significantly lower gains of lateral canals at 60 ms compared to healthy controls.

- The number of pathological findings for all three canals were more frequent in MS patients.
- Bilateral pathology on vHIT for lateral semicircular canal is associated with brainstem lesions.

Introduction

Involvement of the brainstem in multiple sclerosis (MS) has significant implications on the disease course and can be presented with different symptoms amongst which are the ones associated with vestibular system. Lesions of vestibular system can be subclinical or present with equilibrium disorders such as vertigo and dizziness [Habek, 2013]. There are many tests which are able to detect brainstem involvement in MS with various degrees of success [Magnano, 2014].

It has been shown that the video head impulse test (vHIT) is of great importance in evaluating the function of the peripheral vestibular system [MacDougall, 2009]. vHIT uses head-mounted high-speed camera for tracking eye movements during short head impulses. Eye to head ratio measured by this device then enables clinicians to assess the main indicator of the peripheral vestibular function: vestibulo-ocular reflex (VOR) gain [MacDougall, 2009]. Although primary use of vHIT is to make a distinction between peripheral and central vestibular disorders by detecting peripheral vestibular dysfunction, some researches have shown that VOR can also be impaired when central part of the vestibular system is damaged [Kim, 2014]. With presumption that demyelinating lesions affecting central part of vestibular system could possibly cause impairment in VOR gain, we performed vHIT examination in patients with MS and compared their results with the ones of healthy subjects. Due to weak correlation between radiological extent of the disease measured by MRI and its clinical presentation [Barkhof, 2002], it is of great importance to find potential methods for testing brainstem involvement in MS patients. This study therefore investigates the potential role of vHIT in the detection of brainstem lesions in patients with MS.

Materials and methods

In this case-control, prospective study, sixty-eight participants underwent vHIT testing from March 2016 to November 2016 at the University Hospital Center Zagreb, Croatia.

Participants were divided into two groups, a group of healthy control subjects (HC) (78 ears, 20 females, mean age $25,3 \pm 6,3$) and a group of patients previously diagnosed with relapsing remitting multiple sclerosis (MS) (58 ears, 14 females, mean age $33,7 \pm 7,7$) according to the revised McDonald criteria [Polman, 2011]. All patients performed routine MRI within 30 days prior to vHIT. In both groups presence of peripheral vestibular disorder was excluded by

history taking and clinical examination. Furthermore, it was ensured that subjects were not taking medications known to affect the vestibular system (tranquilizers, sedatives, vestibular suppressants).

MRIs performed on a 1.5T MRI scanner were considered eligible. Brainstem multi-planar dual fast spin-echo PD and T2-WI sequences were analyzed for presence of demyelinating lesions in the brainstem as a whole. All MRIs were reviewed by two independent investigators who were blinded for patients' symptoms and vHIT results at the time of analysis, and only lesions identified by both investigators were considered as present.

The protocol was approved by the ethical committee of the University Hospital Center Zagreb. Before the study, the protocol was explained and discussed with the participants and they all signed informed consent. Video head impulse test has already been described in great detail by MacDougall and Curthoys [MacDougall, 2009; Curthoys, 2014]. The system used in this study was the EyeSeeCam vHIT (Interacoustics, 5500 Middlefart, Denmark). The system consists of a small high-quality camera which focuses the left eye and is mounted on the frame of the goggles. After placing the participant 1.5m in front of the eye-leveled target [Mossman, 2015] and checking whether all the necessary head movements are doable and painless without complications, the goggles with an elastic band are comfortably locked onto the subject's head. The goggles were locked tightly onto the bridge of the nose and around the eye sockets in order to reduce the slippage to the minimum, therefore decreasing the chance of the artifacts occurrence. In order to assure the pupil is accurately tracked, the subject was instructed to keep the eyes widely open and to blink as less as possible. Calibration was performed for the eyes and head movements prior to formal testing. The VOR was generated through the rotation of the subjects head unpredictable in direction and time (peak head velocity 150 °/s to 300 °/s) by the examiner. The impulses of the head were delivered in 3 planes: lateral, right anterior-left posterior (RALP) and left anterior-right posterior (LARP) with a minimum of 5 head impulses in each plane and direction.

Following vHIT parameters were analyzed: for the right and left lateral canals gain at 60ms, presence of covert and overt saccades and gain asymmetry. For right anterior (RA), left posterior (LP), left anterior (LA) and right posterior (RP) slope and presence of covert and overt saccades. Gain, slope and asymmetry were automatically calculated by OtoAccess. Each test was visually inspected for presence of saccades. vHIT pathology was defined by the presence of overt saccades (<200ms) or lateral gain lower than 0.8 for lateral canals, and

presence of overt saccades (<200ms) or posterior/anterior slope lower than 0.7 for anterior and posterior canals [Yang, 2016].

The primary outcome was comparison of vHIT results in subjects diagnosed with MS and the healthy control group.

Secondary outcome was to correlate pathological findings of vHIT with the existence of brainstem lesions visible on MRI in subjects with MS.

Statistical analysis was performed using the IBM SPSS software, version 20. The Kolmogorov-Smirnov test was applied to test whether the data have a normal distribution. Differences in the distribution of qualitative variables were determined with the χ^2 test, while the differences in quantitative variables were determined with independent sample t-test. P values less than 0.05 were considered significant.

Results

Results of vHIT parameters and differences between groups are presented in table 1.

Compared to healthy controls overt saccades <200 ms in the lateral canals (p=0.018) and in the posterior canals (p=0.011), overt saccades >200 ms in lateral (p<0.001), anterior (p=0.019) and posterior canals (p=0.009), and covert saccades in the anterior (p=0.042) and posterior canals (p=0.046) were more frequent in the MS group. The distribution of subjects in MS and HC group according to the pathological findings of vHIT gains/slopes (if we use the cut off values for lateral canal gain at 60 ms of 0.8 and for the anterior and posterior canal slope 0.7) are presented in Table 2.

Finally, results were considered pathological if there was presence of overt saccades (<200ms) or lateral gain lower than 0.8 for lateral semicircular canal, and presence of overt saccades (<200ms) or posterior/anterior slope lower than 0.7 for posterior/anterior semicircular canal. Bilateral pathology was regarded as presence of pathological responses on both sides for specific semicircular canal. Six patients had bilateral pathology on lateral canals and all of them had BS lesions evident on MRI. Analysis showed that there is statistically significant association between the presence of BS MRI lesions and bilateral pathology on vHIT for lateral semicircular canals ($\chi(1)=3.982$, p=0.046). The example of a patient with brainstem lesions and bilateral vHIT pathology is presented in Figure 1.

Discussion

The main finding of this study was a significantly more frequent pathological vHIT test in patients diagnosed with MS compared to healthy controls. Furthermore, we have shown that bilaterally pathologic vHIT finding can detect brainstem lesions in MS. This finding is of particular relevance, since detecting a central etiology of vertigo is of greatest clinical interest since the prognosis and management differ completely.

Current research has already shown the capability of vHIT to detect certain central causes of vertigo and differentiate them from their peripheral counterparts. Stroke is the most common and therefore the most studied cause of central vertigo. It accounts for approximately 25% of all patients presenting with acute vestibular syndrome (AVS) [Lee, 2015]. Posterior circulation strokes make up for 20% of all ischemic strokes [Nouh, 2014] and 20% of those are estimated to present with isolated vertigo without other focal neurologic signs [Venhovens, 2016]. Current research has demonstrated that posterior inferior cerebellar artery strokes present with vHIT gains larger than 0.7 and vHIT gain asymmetry smaller than 20% and can therefore be accurately differentiated from vestibular neuritis. On the other hand, anterior inferior cerebellar artery strokes show more heterogeneity and can present with a decreased vHIT gain if labyrinth (internal auditory artery), entry zone of the eighth nerve, vestibular nuclei or cerebellar flocculus are affected [Mantokoudis, 2015]. Rarely, a stroke can infarct solely the vestibular nuclei or the entry zone of the eighth nerve causing AVS with combined features of peripheral and central vestibular lesion [Kim, 2014].

Of other central causes of vertigo, vHIT has been shown as pathological in around 10% of patients diagnosed with vestibular migraine (VM) [Blödow 2014; Yoo, 2016; Kang, 2016], and the presence of a pathological vHIT in the initial presentation has been linked to worse response to medication at 6-month follow-up [16]. vHIT can be pathological in some rarer causes of central vestibulopathy as well like retinitis pigmentosa and Usher's syndrome [Magliulo, 2015], superficial siderosis [Kang 2015], spinocerebellar and Friedreich's ataxia [Luis, 2016] and maternally-inherited diabetes mellitus and deafness [Cardenas-Robledo, 2016]. In all aforementioned disorders, except in VM, the vHIT was bilaterally pathological.

As stated above, vHIT has already found its use in the evaluation of many central vestibulopathies. We haven't found any previous studies reporting vHIT findings in MS despite the high prevalence of vertigo and dizziness in this population. Vertigo can be the presenting symptom of MS in 4-20 % of patients [Karatatou, 2008; Mostafa, 2014] and occurs

in the course of the disease in 50% of patients [Karatas, 2008]. Two main presentations are either AVS or positional vertigo. Positional vertigo in MS is caused by lesions located in the brainstem region around the fourth ventricle caused by the interruption of otolithic projections from vestibular nuclei to fastigial nucleus in the superior cerebellar peduncle [Karatas, 2008; Anagnostou, 2008]. AVS in MS can be caused by lesions involving the eighth nerve fascicle, vestibular nuclei and other anatomic structures in all three levels of brainstem known to be involved in vestibular signaling. Most of the patients presenting with AVS caused by MS have additional focal neurologic signs, but close mimics of peripheral vestibulopathy occasionally occur [Pula, 2013].

The present study has identified significantly more frequent pathological vHIT test in patients diagnosed with MS compared to healthy controls, and this was evident in number of ears with decreased gains and/or present refixating saccades. Recently it has been shown that refixating saccades increase with higher age, they are not caused by a deficient VOR, but might be caused by a deficient suppression of saccades to novel targets. [Rambold, 2016] On the other hand, refixating saccades are more prevalent in patients with unilateral vestibular loss and decreased gain: isolated covert saccades (13.7%), isolated overt saccades (34.3%) and the combination of overt and covert saccades (52.0%). [Blödow, 2013] Both pathologies on VHIT could be the consequence of demyelinating lesions in the root exit zone of the vestibular nerve, vestibular nucleus or deep cerebellar nuclei that modulate the VOR, however the present study is underpowered to answer this question.

Brainstem involvement in clinically isolated syndrome carries an increased risk of conversion into clinically definite MS. Furthermore, it is a major predictive factor of future disability and carries worse long term prognosis [Tintore, 2010]. Brainstem involvement can manifest itself with various clinical presentations and may even be asymptomatic, detectable only by different paraclinical tests such as vestibular evoked myogenic potentials [Pula, 2013; Crnosija, 2016]. In spite of being clinically silent, these lesions may have an impact on future disability [Habek, 2013].

This study's main limitation is a relatively small sample size, thus, we suggest a future confirmatory study on a larger sample. Should that study confirm the association between bilaterally pathological vHIT and the existence of an MRI brainstem lesions, there might be a potential use of vHIT in detection of brainstem demyelinating lesions in MS.

Conclusion

Our study has shown that patients with MS have significantly reduced gains on vHIT. Additionally, we have found a significant association between bilateral pathology on vHIT for lateral semicircular canal and MRI confirmed brainstem lesion. These results argue that bilateral pathology on vHIT can suggest central vestibulopathy.

References

- Anagnostou E, Varaki K, Anastasopoulos D. A minute demyelinating lesion causing acute positional vertigo. *J Neurol Sci* 2008;266:187-9.
- Barkhof F. The clinico-radiological paradox in multiple sclerosis revisited. *Curr Opin Neurol* 2002;15:239–245.
- Blödown A, Pannasch S, Walther LE. Detection of isolated covert saccades with the video head impulse test in peripheral vestibular disorders. *Auris Nasus Larynx* 2013;40:348-51.
- Blödown A, Heinze M, Bloching MB, von Brevern M, Radtke A, Lempert T. Caloric stimulation and video-head impulse testing in Ménière's disease and vestibular migraine. *Acta Otolaryngol* 2014;134:1239-44.
- Cardenas-Robledo S, Saber Tehrani A, Blume G, Kattah JC. Visual, Ocular Motor, and Cochleo-Vestibular Loss in Patients With Heteroplasmic, Maternally-Inherited Diabetes Mellitus and Deafness (MIDD), 3243 Transfer RNA Mutation. *J Neuroophthalmol* 2016;36:134-40.
- Crnošija L, Krbot Skorić M, Gabelić T, Adamec I, Habek M. Vestibular evoked myogenic potentials and MRI in early multiple sclerosis: Validation of the VEMP score. *J Neurol Sci* 2017;372:28-32.
- Curthoys IS, MacDougall HG, McGarvie LA, Weber KP, Szmulewicz D, Manzari L, et al. The video head impulse test (vHIT). 2nd ed. In: Jacobson GP, Shepard NT, editors. *Balance Function Assessment and Management*. SanDiego, CA: Plural Publishing (2014).p.391–430
- Habek M. Evaluation of brainstem involvement in multiple sclerosis. *Expert Rev Neurother* 2013; 13: 299–311.
- Kang KW, Lee C, Kim SH, Cho HH, Lee SH. Bilateral Vestibulopathy Documented by Video Head Impulse Tests in Superficial Siderosis. *Otol Neurotol* 2015;36:1683-6.
- Kang WS, Lee SH, Yang CJ, Ahn JH, Chung JW, Park HJ. Vestibular Function Tests for Vestibular Migraine: Clinical Implication of Video Head Impulse and Caloric Tests. *Front Neurol* 2016;7:166.
- Karatas M. Central vertigo and dizziness: epidemiology, differential diagnosis, and common causes. *Neurologist* 2008;14:355-64.
- Kim HJ, Lee SH, Park JH, Choi JY, Kim JS. Isolated vestibular nuclear infarction: report of two cases and review of the literature. *J Neurol* 2014;261:121-9.

Lee SH, Kim JS. Acute Diagnosis and Management of Stroke Presenting Dizziness or Vertigo. *Neurol Clin* 2015;33:687-98.

Luis L, Costa J, Muñoz E, de Carvalho M, Carmona S, Schneider E, Gordon CR, Valls-Solé J. Vestibulo-ocular reflex dynamics with head-impulses discriminates spinocerebellar ataxias types 1, 2 and 3 and Friedreich ataxia. *J Vestib Res* 2016;26:327-34.

MacDougall HG, Weber KP, McGarvie LA, Halmagyi GM, Curthoys IS. The video head impulse test: diagnostic accuracy in peripheral vestibulopathy. *Neurology* 2009;73:1134–41.

Magliulo G, Iannella G, Gagliardi S, Iozzo N, Plateroti R, Plateroti P, Re M, Vingolo EM. Usher's Syndrome: Evaluation of the Vestibular System with Cervical and Ocular Vestibular Evoked Myogenic Potentials and the Video Head Impulse Test. *Otol Neurotol* 2015;36:1421-7.

Magnano I, Pes GM, Pilurzi G, Cabboi MP, Ginatempo F, Giacconi E, Tolu E, Achene A, Salis A, Rothwell JC, Conti M, Deriu F. Exploring brainstem function in multiple sclerosis by combining brainstem reflexes, evoked potentials, clinical and MRI investigations. *Clin Neurophysiol* 2014;125:2286-96.

Mantokoudis G, Tehrani AS, Wozniak A, Eibenberger K, Kattah JC, Guede CI, Zee DS, Newman-Toker DE. VOR gain by head impulse video-oculography differentiates acute vestibular neuritis from stroke. *Otol Neurotol* 2015;36:457-65.

Mossman B, Mossman S, Purdie G, Schneider E. Age dependent normal horizontal VOR gain of head impulse test as measured with video-oculography. *J Otolaryngol Head Neck Surg* 2015;44:29.

Mostafa BE, Kahky AO, Kader HM, Rizk M. Central vestibular dysfunction in an otorhinolaryngological vestibular unit: incidence and diagnostic strategy. *Int Arch Otorhinolaryngol* 2014;18:235-8.

Nouh A, Remke J, Ruland S. Ischemic posterior circulation stroke: a review of anatomy, clinical presentations, diagnosis, and current management. *Front Neurol* 2014;5:30.

Polman CH, Reingold SC, Banwell B, Clanet M, Cohen JA, Filippi M, Fujihara K, Havrdova E, Hutchinson M, Kappos L, Lublin FD, Montalban X, O'Connor P, Sandberg-Wollheim M, Thompson AJ, Waubant E, Weinshenker B, Wolinsky JS. Diagnostic criteria for multiple sclerosis: 2010 revisions to the McDonald criteria. *Ann Neurol* 2011;69:292-302.

Pula JH, Newman-Toker DE, Kattah JC. Multiple sclerosis as a cause of the acute vestibular syndrome. *J Neurol* 2013;260:1649-54.

Rambold HA. Age-related Refixating Saccades in the Three-Dimensional Video-Head-Impulse Test: Source and Dissociation From Unilateral Vestibular Failure. *Otol Neurotol* 2016;37:171-8.

Tintore M, Rovira A, Arrambide G, Mitjana R, Ríó J, Auger C, Nos C, Edo MC, Castelló J, Horga A, Perez-Miralles F, Huerga E, Comabella M, Sastre-Garriga J, Montalban X. Brainstem lesions in clinically isolated syndromes. *Neurology* 2010;75:1933-8.

Venhovens J, Meulstee J, Verhagen WI. Acute vestibular syndrome: a critical review and diagnostic algorithm concerning the clinical differentiation of peripheral versus central aetiologies in the emergency department. *J Neurol* 2016;263:2151-2157.

Yang CJ, Lee JY, Kang BC, Lee HS, Yoo MH, Park HJ. Quantitative analysis of gains and catch-up saccades of video-head-impulse testing by age in normal subjects. *Clin Otolaryngol* 2016;41:532-8.

Yoo MH, Kim SH, Lee JY, Yang CJ, Lee HS, Park HJ. Results of video head impulse and caloric tests in 36 patients with vestibular migraine and 23 patients with vestibular neuritis: a preliminary report. *Clin Otolaryngol* 2016;41:813-817.

Tables

Table 1. Results of vHIT parameters and differences between groups.

vHIT parameter	Group	Mean	SD	p value
Lateral canal gain (40ms)	MS	1.018	0.214	0.010
	HC	1.126	0.256	
Lateral canal (60ms)	MS	0.874	0.143	0.004
	HC	0.954	0.170	
Lateral canal (80ms)	MS	0.850	0.137	0.088
	HC	0.888	0.120	
Anterior canal slope	MS	1.249	0.607	0.264
	HC	1.153	0.282	
Posterior canal slope	MS	1.009	0.438	0.140
	HC	1.110	0.360	

Table 2. The distribution of subjects in MS and HC group according to the pathological findings of vHIT gains/slopes (if we use the cut off values for lateral canal gain at 60 ms of 0.8 and for the anterior and posterior canal slope 0.7).

vHIT parameter	Group	Pathological value of the vHIT parameter		p value
		No	Yes	
Lateral canal (60ms)	MS	42	16	0.009
	HC	70	8	
Anterior canal slope	MS	51	7	0.027
	HC	76	2	
Posterior canal slope	MS	47	11	0.004
	HC	75	3	

Figures

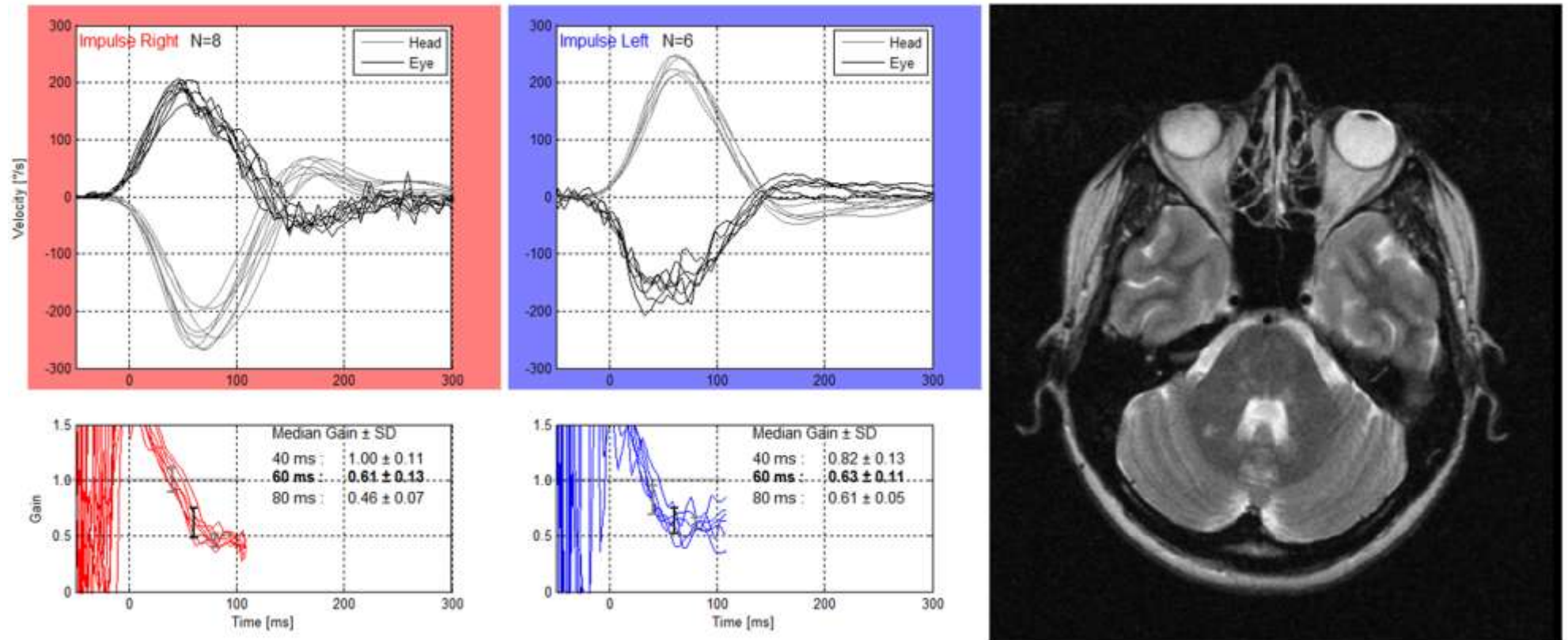


Figure 1. An example of the patient with brainstem lesions on the MRI and bilateral vHIT pathology.