



**University of
Zurich**^{UZH}

**Zurich Open Repository and
Archive**

University of Zurich
Main Library
Strickhofstrasse 39
CH-8057 Zurich
www.zora.uzh.ch

Year: 2018

Basal Cell Carcinoma Mimicking Desmoplastic Trichoepithelioma: A Case with Correlation of Dermoscopy and Histology

Kunz, Michael; Kerl, Katrin; Braun, Ralph Peter

Abstract: Basal cell carcinoma (BCC) is the most common cancer in humans worldwide. Many highly specific dermoscopic criteria for BCC are well established in the literature. On the contrary, other malignant or benign skin tumors may mimic BCC by exhibiting similar or even the same dermoscopic features and therefore obscuring the diagnosis of BCC in certain situations. We herein report a case of BCC with dermoscopic features of both BCC and desmoplastic trichoepithelioma (DT). We would like to remind of the often neglected differential diagnosis of DT in a lesion with arborizing vessels and otherwise unusual dermoscopic presentation.

DOI: <https://doi.org/10.1159/000489164>

Posted at the Zurich Open Repository and Archive, University of Zurich

ZORA URL: <https://doi.org/10.5167/uzh-151667>

Published Version



Originally published at:

Kunz, Michael; Kerl, Katrin; Braun, Ralph Peter (2018). Basal Cell Carcinoma Mimicking Desmoplastic Trichoepithelioma: A Case with Correlation of Dermoscopy and Histology. *Case Reports in Dermatology*, (10):133-137.

DOI: <https://doi.org/10.1159/000489164>

Single Case

Basal Cell Carcinoma Mimicking Desmoplastic Trichoepithelioma: A Case with Correlation of Dermoscopy and Histology

Michael Kunz · Katrin Kerl · Ralph Peter Braun

Dermatology Clinic, University Hospital Zurich, Zurich, Switzerland

Keywords

Basal cell carcinoma · Desmoplastic trichoepithelioma · Dermoscopy · Histology · Ivory white background · Keratin-filled cysts

Abstract

Basal cell carcinoma (BCC) is the most common cancer in humans worldwide. Many highly specific dermoscopic criteria for BCC are well established in the literature. On the contrary, other malignant or benign skin tumors may mimic BCC by exhibiting similar or even the same dermoscopic features and therefore obscuring the diagnosis of BCC in certain situations. We herein report a case of BCC with dermoscopic features of both BCC and desmoplastic trichoepithelioma (DT). We would like to remind of the often neglected differential diagnosis of DT in a lesion with arborizing vessels and otherwise unusual dermoscopic presentation.

© 2018 The Author(s)
Published by S. Karger AG, Basel

Introduction

Basal cell carcinoma (BCC) is the most common form of cancer in white-skinned humans with a still increasing incidence between 33.6/100,000 person years in certain parts of Europe (Croatia) up to an incidence of >1,000/100,000 person years in Australia. In North America the incidence of BCC lies between 93.9 and 935.9/100,000 person years [1].

With the use of dermoscopy, BCC is usually diagnosed clinically, with a high positive predictive value for multiple dermoscopic features. Dermoscopic features such as spoke-wheel areas, leaf-like areas, large blue-gray ovoid nests, multiple blue-gray globules, short fine telangiectasias, arborizing vessels, annular distribution of telangiectatic vessels, white rosettes, annular hypopigmentation, multiple erosions/ulcerations, and translucency all showed a significant positive predictive value of 95–100% for BCC in larger studies [2–5]. Nevertheless, criteria usually specific for BCC can be seen in other skin tumors such as desmoplastic trichoepithelioma (DT).

DT is a rare benign adnexal neoplasm with trichogenic differentiation. It usually presents on the face of young to middle-aged adults, with a female predominance [6, 7]. Its dermoscopic features have been described as arborizing telangiectasias, ivory (or pearl) white background, and keratin cysts. There always was a lack of blue-gray ovoid nests and leaf-like structures [8–11]. Histologically, DT is characterized by basaloid cells arranged in small cords and infundibulocystic structures containing keratin surrounded by fibrotic collagen.

Here we present a case of BCC that was dermoscopically mimicking DT. We also include a dermoscopic comparison of these two entities and a review of the respective literature.

Case Report

A 38-year-old male patient presented with a slowly growing painless nonpruritic papule on the left cheek. His personal history included a micronodular BCC on the same area of the left cheek, which had been biopsied 4 years before and for which he had been treated with photodynamic therapy with methyl aminolevulinate. Physical examination revealed a flat, skin-colored papule with slightly pronounced and clearly demarcated borders. One part of the lesion showed whitish scar-like atrophy, another part small slightly shiny papules (Fig. 1, 2). Dermoscopically, the center of the lesion was covered with an ivory white background. Peripherally, the lesion revealed multiple grouped keratin cysts and arborizing telangiectasias of different caliber (small to medium size). The differential diagnosis included both DT and morpheiform BCC and the lesion was biopsied. Histological examination showed a micronodular BCC with sclerosing parts. A correlation could be made between the dermoscopic findings of the multiple grouped keratin cysts and the scar-like atrophy with its respective histology (Fig. 3). The BCC was completely removed by micrographic surgery.

Discussion

We evaluated the published literature on PubMed searching for the terms “desmoplastic trichoepithelioma” or “basal cell carcinoma” combined with the terms “dermoscopy” or “dermoscopic features.” In summary, for DT the most specific dermoscopic features comprise an ivory white background throughout the lesion [9]. Keratin-filled cysts were detected by reflectance confocal microscopy by Ardigo et al. [8] in a study involving 4 trichoepitheliomas and have been a feature of trichoepithelioma on correlation of dermoscopy and histology in two case reports [10, 11]. The finding in our patient, in whom multiple keratin cysts were detected dermoscopically in BCC, makes this finding less specific for DT. What is demonstrated in Figures 2 and 3 is the clear correlation of dermoscopy with histology of the keratin-filled cysts.

Blue-gray ovoid nests and leaf-like structures clearly suggest BCC as they have not been described in DT before. Both lesions can exhibit arborizing vessels, which makes this otherwise so useful criterion in the diagnosis of BCC of no particular avail to differentiate it from DT [9, 10]. The only hint could be that arborizing vessels in DT typically are scarcely branched in contrast to the often more prominent vessels in BCC.

This case reflects the close relationship between different tumors with follicular differentiation, such as BCC and DT, and the value of dermoscopy in their diagnosis. Correlation with histological findings helps to further understand and interpret their specific dermoscopic features. Further studies should focus on evidence, including histopathological correlation, for specific dermoscopic criteria of DT.

Statement of Ethics

All procedures followed were in accordance with the ethical standards of the responsible committee on human experimentation (institutional and national) and with the Helsinki Declaration of 1975, as revised in 2008. Informed consent was obtained from the patient for being included in the study.

Disclosure Statement

The authors have no conflicts of interest. This paper has not been published elsewhere.

References

- 1 Lomas A, Leonardi-Bee J, Bath-Hextall F. A systematic review of worldwide incidence of nonmelanoma skin cancer. *Br J Dermatol*. 2012 May;166(5):1069–80.
- 2 Altamura D, Menzies SW, Argenziano G, Zalaudek I, Soyer HP, Sera F et al. Dermoscopy of basal cell carcinoma: morphologic variability of global and local features and accuracy of diagnosis. *J Am Acad Dermatol*. 2010 Jan;62(1):67–75.
- 3 Menzies SW, Westerhoff K, Rabinovitz H, Kopf AW, McCarthy WH, Katz B. Surface microscopy of pigmented basal cell carcinoma. *Arch Dermatol*. 2000 Aug;136(8):1012–6.
- 4 Popadić M. Statistical evaluation of dermoscopic features in basal cell carcinomas. *Dermatol Surg*. 2014 Jul;40(7):718–24.
- 5 Nelson SA, Scope A, Rishpon A, Rabinovitz HS, Oliviero MC, Laman SD et al. Accuracy and confidence in the clinical diagnosis of basal cell cancer using dermoscopy and reflex confocal microscopy. *Int J Dermatol*. 2016 Dec;55(12):1351–6.
- 6 Mamelak AJ, Goldberg LH, Katz TM, Graves JJ, Arnon O, Kimyai-Asadi A. Desmoplastic trichoepithelioma. *J Am Acad Dermatol*. 2010 Jan;62(1):102–6.
- 7 Wang Q, Ghimire D, Wang J, Luo S, Li Z, Wang H et al. Desmoplastic trichoepithelioma: A clinicopathological study of three cases and a review of the literature. *Oncol Lett*. 2015 Oct;10(4):2468–76.
- 8 Ardigo M, Zieff J, Scope A, Gill M, Spencer P, Deng L et al. Dermoscopic and reflectance confocal microscope findings of trichoepithelioma. *Dermatology*. 2007;215(4):354–8.
- 9 Khelifa E, Masouyé I, Kaya G, Le Gal FA. Dermoscopy of desmoplastic trichoepithelioma reveals other criteria to distinguish it from basal cell carcinoma. *Dermatology*. 2013;226(2):101–4.
- 10 Lazaridou E, Fotiadou C, Patsatsi A, Fotiadu A, Kyrmanidou E, Kemanetzi C et al. Solitary trichoepithelioma in an 8-year-old child: clinical, dermoscopic and histopathologic findings. *Dermatol Pract Concept*. 2014 Apr;4(2):55–8.
- 11 Stoica LE, Dascalu RC, Patrascu V, Ciurea RN, Branisteanu DE, Georgescu DM et al. Solitary trichoepithelioma: clinical, dermoscopic and histopathological findings. *Rom J Morphol Embryol*. 2015;56(2 Suppl):827–32.

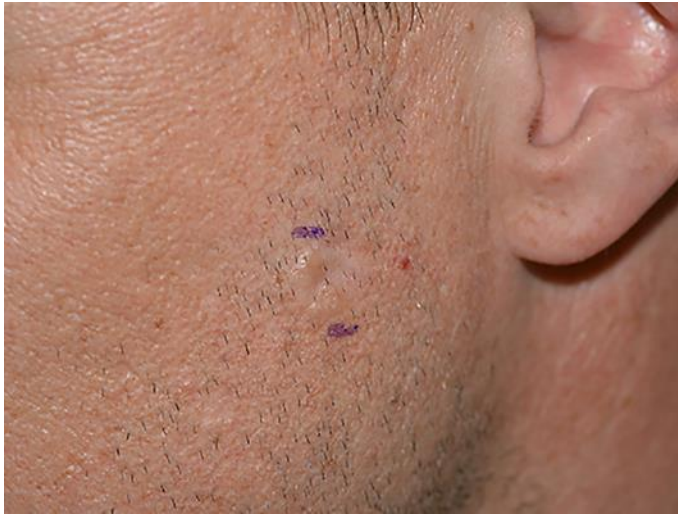

Fig. 1. Clinical picture of the tumor showing a flat, skin-colored papule with slightly pronounced and clearly demarcated borders, whitish scar-like atrophy, and small slightly shiny papules.

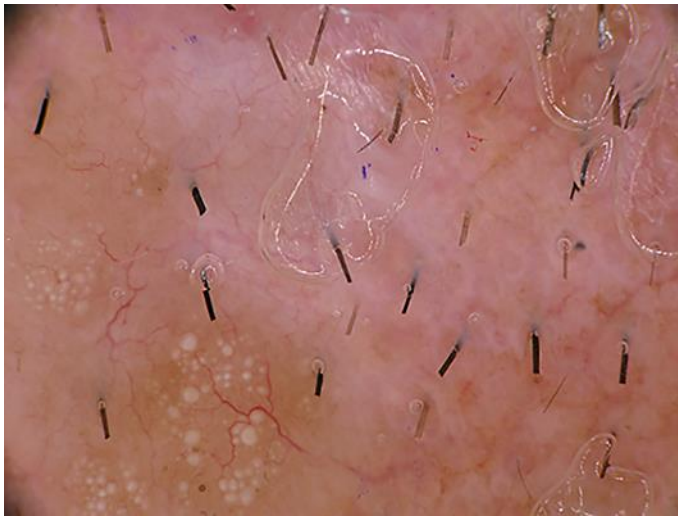

Fig. 2. Dermoscopic picture showing an ivory white background, multiple grouped keratin cysts, and arborizing telangiectasias of different caliber.

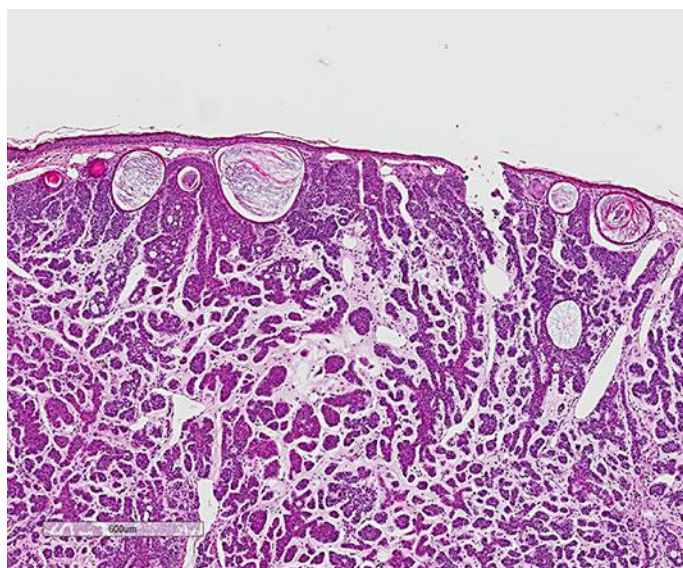


Fig. 3. Basaloid tumor cell complexes with multiple keratin-filled horn cysts and a few smaller tumor nests in a fibrosing stroma in the deeper part (hematoxylin and eosin staining).