



Carr, M., Curtis, S., & Marek, J. (2018). Educational series in congenital heart disease: Congenital left-sided heart obstruction. *Echo Research and Practice*, 5(2), R23-R36. <https://doi.org/10.1530/ERP-18-0016>

Publisher's PDF, also known as Version of record

License (if available):
CC BY-NC

Link to published version (if available):
[10.1530/ERP-18-0016](https://doi.org/10.1530/ERP-18-0016)

[Link to publication record in Explore Bristol Research](#)
PDF-document

This is the final published version of the article (version of record). It first appeared online via Bioscientifica at <http://www.echorespract.com/content/5/2/R23.full.pdf+html> . Please refer to any applicable terms of use of the publisher.

University of Bristol - Explore Bristol Research

General rights

This document is made available in accordance with publisher policies. Please cite only the published version using the reference above. Full terms of use are available:
<http://www.bristol.ac.uk/pure/about/ebr-terms>

REVIEW

EDUCATIONAL SERIES IN CONGENITAL HEART DISEASE

Congenital left-sided heart obstruction

Michelle Carr MB BCH BAO¹, Stephanie Curtis BSc (Hons) MB ChB MD FRCP FESC² and Jan Marek MD PhD FESC^{1,3}

¹Great Ormond Street Hospital for Children NHS Foundation Trust, London, UK

²Bristol Heart Institute, University Hospitals Bristol, Bristol, UK

³Institute of Cardiovascular Sciences, University College London, London, UK

Correspondence should be addressed to S Curtis: Stephanie.Curtis@UH Bristol.nhs.uk

Abstract

Congenital obstruction of the left ventricular outflow tract remains a significant problem and multilevel obstruction can often coexist. Obstruction can take several morphological forms and may involve the subvalvar, valvar or supra-valvar portion of the aortic valve complex. Congenital valvar stenosis presenting in the neonatal period represents a spectrum of disorders ranging from the hypoplastic left heart syndrome to almost normal hearts. Treatment options vary dependent on the severity of the left ventricular outflow tract obstruction (LVOTO) and the variable degree of left ventricular hypoplasia as well as the associated lesions such as arch hypoplasia and coarctation.

Key Words

- ▶ left ventricular outflow tract obstruction
- ▶ congenital heart defects
- ▶ bicuspid aortic valve
- ▶ coarctation of the aorta
- ▶ aortic stenosis

There are four broad categories of LVOTO (listed below) and each will be discussed in turn, in terms of their morphology, clinical and echocardiographical features, and management:

1. Subvalvar aortic stenosis;
2. Valvar aortic stenosis;
3. Supra-valvar aortic stenosis;
4. Coarctation of the aorta.

Sub(valvar) aortic stenosis

Subaortic stenosis describes a group of congenital heart lesions that result in obstruction of blood flow just under the aortic valve in the left ventricular outflow tract. It is relatively rare, accounting for around 1% of all congenital heart disease and, as with many left-sided congenital heart disease, it is more common in males.

Subvalvar aortic stenosis (SAS) can occur in isolation or in association with other structural heart defects.

Isolated SAS is relatively uncommon representing 8–30% LVOTO (1). It is an intriguing lesion and generally is not present at birth. Usually once present it is progressive. It can be due to a discrete fibrous membrane, a muscular narrowing or a combination of both. Discrete subaortic stenosis can recur after surgical resection. This has led to the theory that the pathophysiological mechanism of its formation suggests an abnormal underlying endothelial substrate that is stimulated to undergo proliferation by shear stresses caused by abnormal flow patterns and chronic turbulence (2). Patients may present in adulthood with previously undiagnosed subaortic stenosis, but most of the time, the condition has been diagnosed in childhood and repaired. However, recurrence is common, occurring in adults in up to 50% all patients, particularly in those patients repaired early in life, those left with a residual gradient and in those where the obstruction has been severe (1).

Blood flows across the obstruction and causes turbulence at the level of the left ventricular outflow tract and aortic valve. The turbulent flow damages the aortic valve and

aortic regurgitation is often present. In unrepaired subaortic stenosis diagnosed in adulthood it is unusual for the aortic valve not to be regurgitant. At this stage, surgery to remove the obstruction will not save the valve from progressive aortic regurgitation and repair or replacement need to be considered. It is important that the echocardiographer fully assesses the aortic valve structurally and functionally prior to surgery. Transoesophageal echocardiography is often very helpful in studying the relationship between the SAS and the aortic valve.

Morphology of subvalvar aortic stenosis

There are four anatomic types of SAS, listed below:

1. Discrete fibrous membrane or fibro-muscular ridge with a muscular base at the septal crest;
2. Diffuse muscular tunnel;
3. Association with a membranous ventricular septal defect;
4. Hypertrophic obstructive cardiomyopathy (HOCM).

Discrete fibromuscular

A discrete fibromuscular ridge or membrane is the most common form of subaortic stenosis. It is sometimes confined to the left ventricular aspect of the infundibular septum but is more often circumferential (Figs 1, 2 and 3). It typically extends from the infundibular septum around the

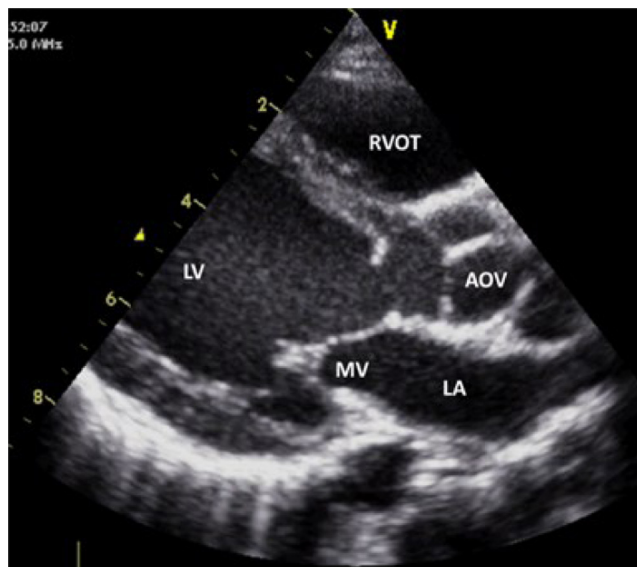


Figure 1
Circular fibromuscular shelf seen in 2D parasternal long axis view. AOV, aortic valve; LA, left atrium; LV, left ventricle; MV, mitral valve; RVOT, right ventricular outflow tract.

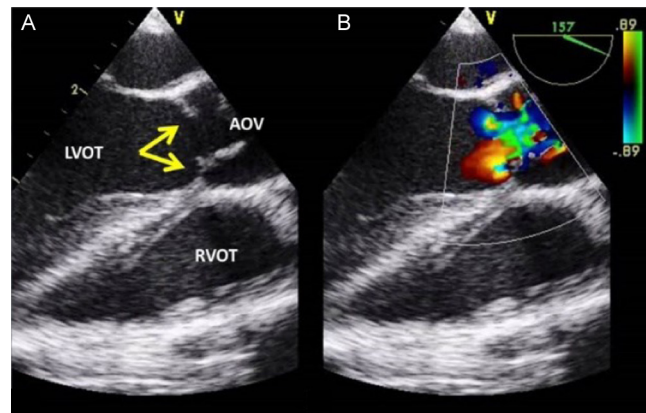


Figure 2
Circular subaortic membrane (arrows) adherent to aortic valve (AOV) visualised in transoesophageal 2D imaging (A) and colour flow mapping (B) in long axis view (130°). LVOT, left ventricular outflow tract; RVOT, right ventricular outflow tract.

margins of the left ventricular outflow tract to the anterior leaflet of the mitral valve. This form of subaortic stenosis is rare in infancy and usually seen after 3 years of age (3).

Tunnel

This type refers to a long segment of subaortic narrowing generally caused by muscle, which can be a combination of septal and accessory anterolateral papillary muscle. Hypertrophy of the interventricular septum bulges into the left ventricular outflow tract. Conditions with similar echocardiographic appearances include hypertrophic obstructive cardiomyopathy, glycogen storage diseases and idiopathic myocardial hypertrophy. Rarely, muscular obstruction can be caused by a hypertrophied subaortic conus associated with aorto-mitral discontinuity (Fig. 4).

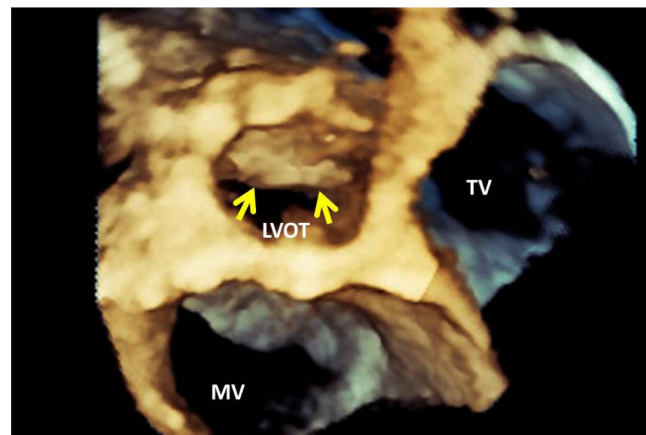


Figure 3
Fibromuscular semicircular shelf (arrows) in real-time 3D transthoracic echocardiography as would be seen by a surgeon (surgeon's view). LVOT, left ventricular outflow tract; MV, mitral valve; TV, tricuspid valve.

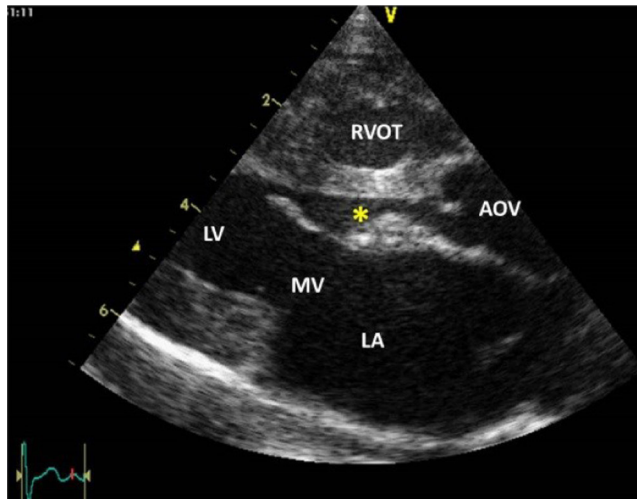


Figure 4
LV outflow tract obstruction caused by hypertrophied subaortic conus in 2D parasternal long axis view. AOV, aortic valve; LA, left atrium; LV, left ventricle; MV, mitral valve; RVOT, right ventricular outflow tract.

Association with membranous ventricular septal defect

A concomitant ventricular septal defect can be seen in approximately 37% patients with subaortic stenosis (4). Posterior deviation of the outlet septum can be seen with a ventricular septal defect or atrioventricular septal defect. The deviated infundibular septum leads to crowding and narrowing of the left ventricular outflow tract and

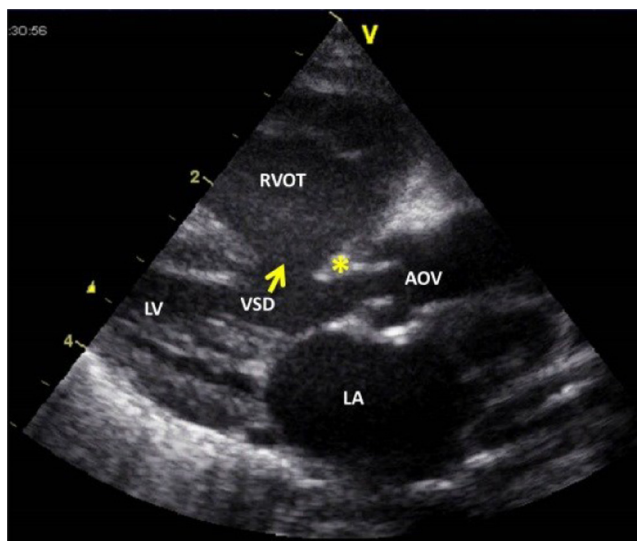


Figure 5
LV outflow tract obstruction caused by posterior deviation of infundibular septum (asterisk) in association with ventricular septal defect (VSD, arrow), bicuspid aortic valve (AOV) in a newborn baby with interrupted aortic arch. 2D image in parasternal long axis view. LA, left atrium; LV, left ventricle; RVOT, right ventricular outflow tract.

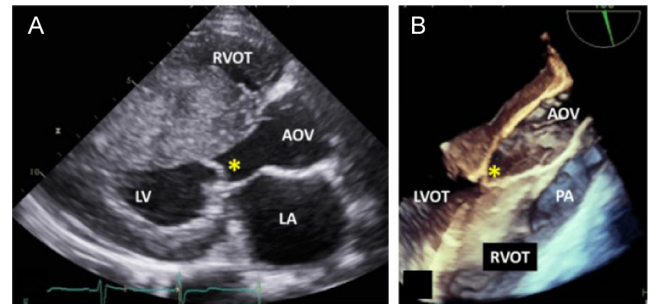


Figure 6
LV outflow tract obstruction in patient with HOCM. Obstruction caused by dynamic LV outflow tract obstruction and chordal attachment from anterior mitral leaflet (asterisk). 2D parasternal long axis view (A) and real-time 3D small-volume transoesophageal echocardiography (B). RVOT, right ventricular outflow tract; AOV, aortic valve; LA, left atrium; LV, left ventricle.

subaortic obstruction. This morphology is commonly associated with coarctation or interruption of the aortic arch (Fig. 5).

Hypertrophic obstructive cardiomyopathy (HOCM)

Though LVOTO from sarcomeric disease is a distinct pathophysiological entity from congenital subaortic stenosis, it can mimic it echocardiographically. It is therefore useful to consider it briefly here. LVOTO is a characteristic and an integral finding in the obstructive form of hypertrophic cardiomyopathy. However, echocardiography often demonstrates systolic anterior motion (SAM) of the anterior leaflet of the mitral valve, which comes into contact with the hypertrophied ventricular septum, and this is not the case in subaortic stenosis. Furthermore, additional attachments of accessory chords from the anterior mitral leaflet are not uncommonly seen in HOCM (Figs 6 and 7).

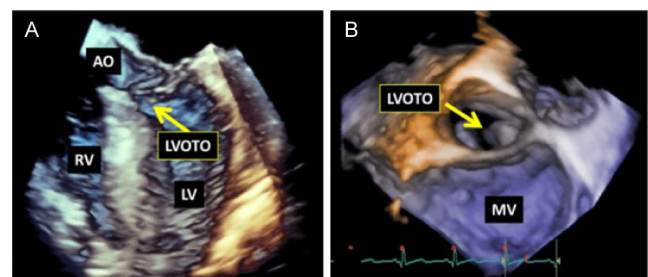


Figure 7
Real-time 3D transthoracic echocardiography (A) with LV outflow tract obstruction visualised from LV apex (A) and surgeon's view (B) demonstrating obstructive tissue (arrows) protruding to LV outflow tract (LVOTO) during systole when mitral valve (MV) is completely closed. AOV, aortic valve; LV, left ventricle; RV, right ventricle.

Doppler interrogation at rest or on exertion typically shows dynamic flow acceleration with a late systolic peak in both conditions. However, in HOCM with SAM, a posteriorly directed mitral regurgitant jet is often seen. This can be confused with the outflow from the left ventricle as both occur in systole. They can be differentiated echocardiographically as the mitral regurgitation peak is mid-systolic with a higher velocity than the left ventricular outflow tract flow velocity and tends not to change with exercise and the Valsalva manoeuvre (Fig. 8).

Echocardiographic assessment of subvalvar aortic stenosis

- Assess morphology of the stenosis from the parasternal long axis and apical five-chamber and three-chamber views (comment on type and extent);
- Estimate severity of the stenosis using continuous-wave Doppler and pulsed-wave Doppler (do not use the modified Bernoulli equation – quote velocity, rather than pressure gradient);
- Examine the aortic valve for stenosis and regurgitation (mechanism of regurgitation is important);
- Make aortic measurements including annulus, sinus of Valsalva, sinotubular junction, ascending aorta and transverse aorta in the parasternal long axis view (leading edge to leading edge). In children, compare absolute figures to reference values for body surface area and express results as a z-score;
- Look for associated left-sided congenital lesions;

- Assess size, degree of hypertrophy and function of the left ventricle (for serial observations in children generate z-scores similar to aortic root measurements);
- Doppler (pulsed and continuous wave) interrogation will help distinguish dynamic left ventricular outflow tract obstruction from mitral regurgitation in HOCM.

Management of subvalvar aortic stenosis

Optimal treatment of subaortic stenosis has been the subject of debate for some time. Many patients are asymptomatic. There is a clear indication for surgical resection in instances of severe LVOTO (1) and where symptoms are evident. In young children, the obstruction may progress rapidly, and serial echocardiography should be performed to detect rapid progression. Turbulent motion across the valve may interfere with valve function and lead to regurgitation (5). Series have reported a mild degree of aortic regurgitation in more than half of patients with subaortic stenosis and up to 12% have moderate or severe aortic regurgitation (4). Increasing severity of left ventricular outflow tract gradient (>50 mmHg), increases the risk of moderate-to-severe aortic regurgitation (6). Consequently, some centres have advocated early intervention to reduce this risk (4, 7, 8).

Surgical resection is the treatment of choice for subaortic stenosis when criteria for intervention are met (7). Comprehensive echocardiographic evaluation is important in the preoperative assessment. The type and extent of the subvalvar obstruction will determine

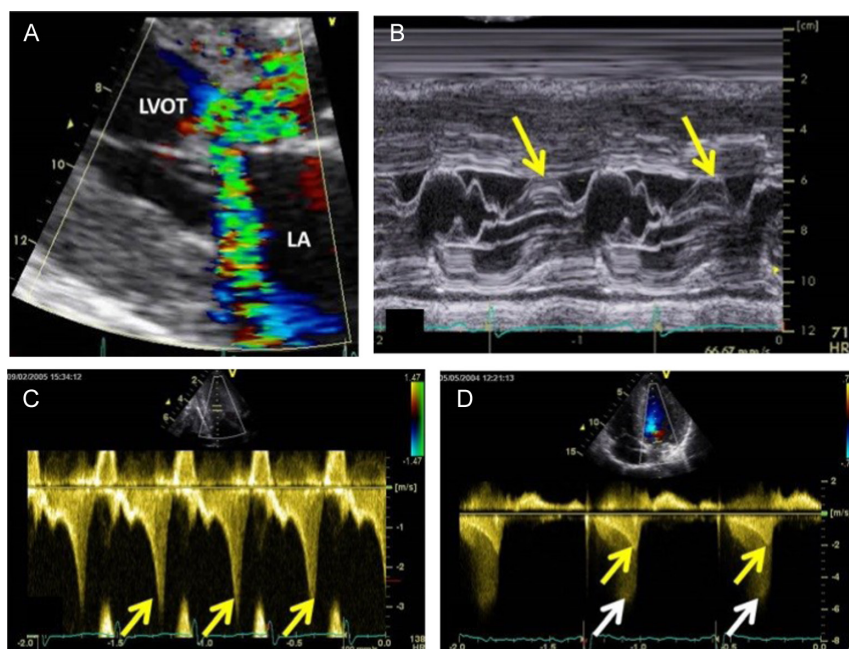


Figure 8

An adolescent with HOCM. 2D parasternal long axis view with colour flow mapping (A) demonstrates flow turbulence within narrow LV outflow tract (LVOT) simultaneously with moderate mitral regurgitant jet diverted very posteriorly. M-mode technique (B) taken from same long axis view confirms systolic anterior motion (SAM) of usually elongated mitral leaflet or supporting chord (arrows). CW Doppler (C) indicates late systolic peak (arrows) confirming dynamic LV outflow tract obstruction. Another CW Doppler (D) displayed simultaneously very high mid-systolic peak from mitral regurgitation (white arrows) and late systolic peak from LV outflow tract (yellow arrows). LA, left atrium.

the appropriate therapy. Discrete membranes may be managed by simple excision whereas diffuse involvement of the subvalvar region may require a more extensive reconstructive procedure such as the Konno procedure (9). Repair of the aortic valve may be necessary if there is more than mild regurgitation. Intraoperative imaging is performed to ensure adequate relief of the LVOTO. It is also important to assess the competence of the aortic valve and the mitral valve function perioperatively.

Postoperative follow-up should include regular echocardiographic screening for recurrence of the subaortic stenosis and aortic regurgitation. In previous surgical series, recurrence is seen more frequently in patients with tunnel or muscular obstruction rather than a discrete membranous obstruction (4). Progressive aortic regurgitation may occur despite the resection of the subaortic stenosis. Postoperative studies have reported a lower incidence of aortic regurgitation in patients who underwent resection at a younger age and with lower left ventricular outflow tract gradients (10, 11).

Valvar aortic stenosis

Valvar aortic stenosis is the most common type of LVOTO, accounting for 80% all cases. Aortic valve stenosis in the paediatric population is due to a congenitally abnormal valve. A bicuspid (bi-commissural) aortic valve is the most common type of congenital heart lesion with a prevalence of 0.5–2% in the adult population (12). In a screening study, where 1075 newborns were assessed by echocardiography, the prevalence was reported as 4.6 per 1000 live births (13). There is a strong genetic component and 1st degree relatives of patients with left ventricular outflow tract lesions are at increased risk of having a bi-commissural aortic valve (14).

Embryologically, aortic valve formation occurs early in foetal life. The definitive reason for abnormal valve morphogenesis is not clear and likely multifactorial. Some of the theories include reduced flow across the leaflets resulting in failure of separation of the individual leaflets. The strong genetic association seen in bicuspid aortic valve disease suggest that factors such as abnormal signalling pathways and cellular migration may be involved in the underdevelopment of one or more commissures, annular hypoplasia and myxomatous thickened valve leaflets. Although many instances of familial clustering have been described, determining inheritance patterns remains elusive. Mutations in GATA4 are associated with bicuspid aortic valve disease and pulmonary valve disease

and receptor signalling mutations in NOTCH 1 (gene map locus 9q34.3) been clearly shown to result in abnormal aortic valve development with a tendency for premature calcium deposition (15).

In utero, severe left ventricular outflow tract obstruction increases the afterload to which the left ventricle is exposed. The increased intra-cavity pressure and severe hypertrophy can lead to subendocardial ischaemia and ultimately to endocardial fibroelastosis. In addition to reduced flow through the left heart, there can also be hypoplastic left heart structures, ranging from the borderline left ventricle to hypoplastic left heart syndrome (Fig. 9).

Morphology of valvar aortic stenosis

The morphology of the valve varies according to which commissures are fused. Less commonly, the valve can be uni-commissural and rarely quadri-commissural (Fig. 10). There are three broad anatomic types of bi-commissural aortic valve disease, depending on which of the three coronary leaflets did not separate during development. These should be thought of as non-separated, rather than fused as they were never developmentally separate in the first place (Figs 11 and 12). The most common type is non-separation of the left and right coronary leaflets. This type accounts for around 73% of bicuspid aortic valves (16, 17). Right and left leaflet non-separation, which is relatively less common, accounts for 24% of all bicuspid valves. Left and non-leaflet separation is seen in only a small numbers of bicuspid aortic valves (3%). Uni-commissural aortic valves can be thought of as on the spectrum of bicuspid aortic valve disease but are relatively rare. The bi-commissural valve typically has two non-symmetrical

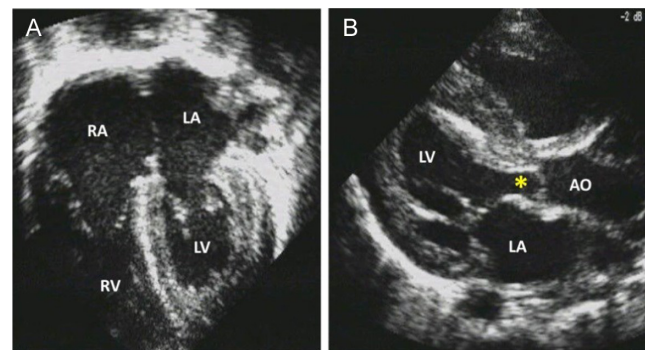


Figure 9

Four chamber (A) and parasternal long axis view (B) in neonate with critical aortic stenosis (asterisk) and endocardial fibroelastosis (EFE) seen as hyperechogenic layer within hypertrophied left ventricle (LV). LA, left atrium; RA, right atrium; RV, right ventricle.

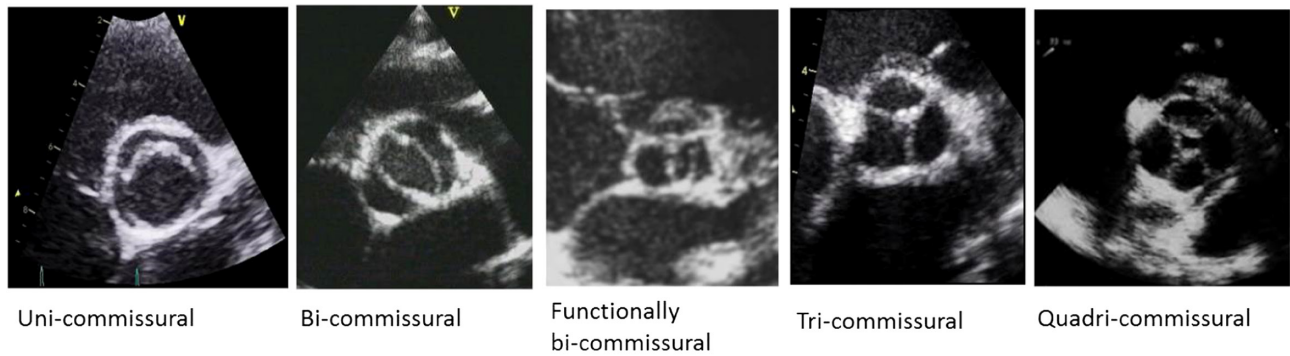


Figure 10

Panel of morphological variants of aortic valves visualised in 2D transthoracic echocardiography in parasternal short axis view.

cusps; the larger leaflet has a ridge or ‘raphe’ where there has been fusion of the commissure (Fig. 11C and D). Less commonly, there can be a true bicuspid valve where the leaflets are symmetrical and there is no raphe (Fig. 11A and B). In the most common bi-commissural valve, there is fusion of the right and left coronary leaflets, and this is associated with coarctation.

Aortopathy in bicuspid aortic valve disease

Bicuspid aortic valve disease carries with it a lifetime risk of ascending aortopathy, which occurs to varying degrees in around three-quarters of patients. Patients with bicuspid aortic valve disease-related aortopathy are five to ten times more likely to suffer from an aortic dissection than

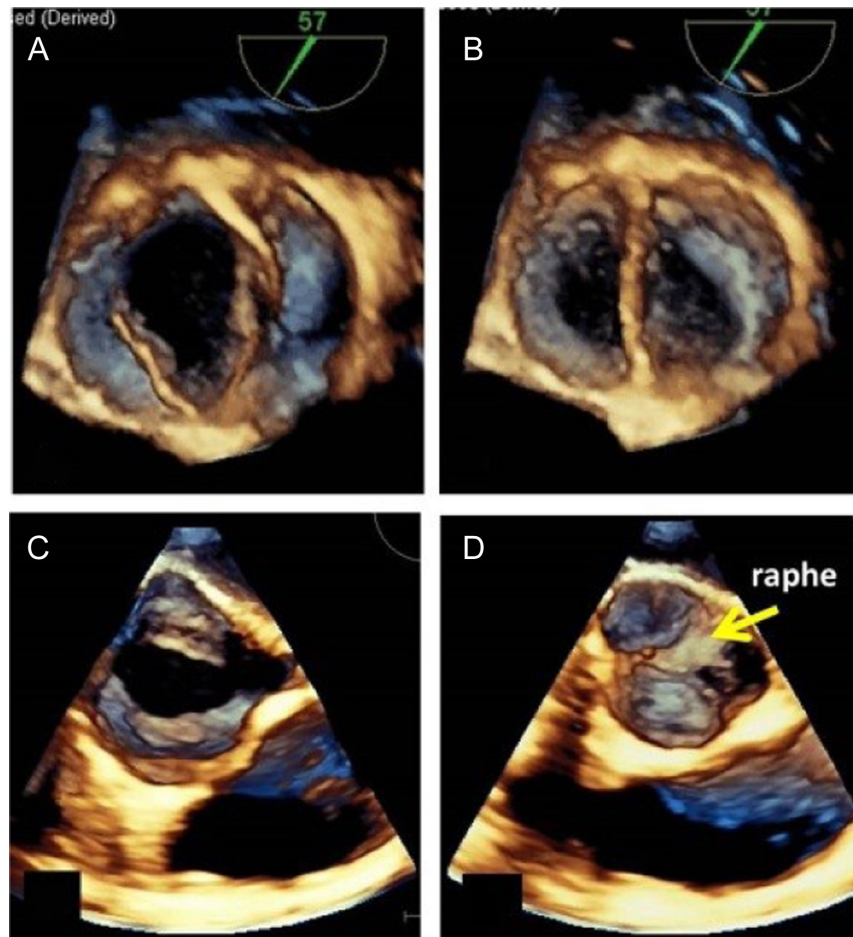


Figure 11

Bicuspid (bi-commissural) aortic valve with vertical orientation of effective orifice imaged by transoesophageal real-time 3D echocardiography. Purely bicuspid valve with vertical orientation of effective orifice and absence of raphe or fused commissure seen during systole (A) and diastole (B). Another example of bicuspid aortic valve demonstrates horizontal orientation of effective orifice during systole (C) and thick raphe within Valsalva sinuses at 2 o'clock (arrow) seen within pockets of sinuses during diastolic closure (D).

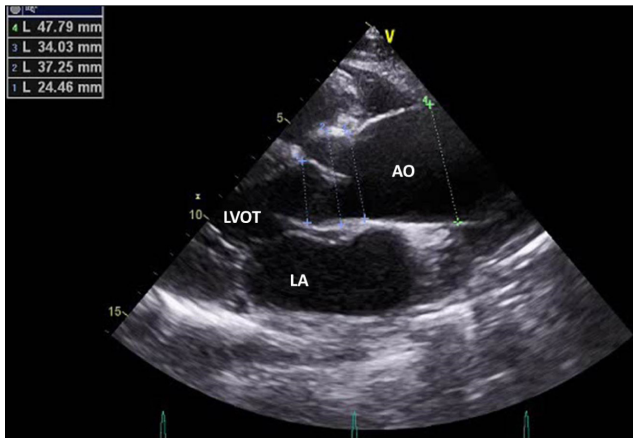


Figure 12

Echocardiographic measurement of aortic root (AO) in parasternal long axis view: annulus, Valsalva sinuses, sinotubular junction and ascending aorta dimensions measured in a patient with Marfan syndrome. Measurements performed during systole, aortic annulus measured at the level of aortic leaflet hinge points. AO, aorta; LA, left atrium; LVOT, left ventricular outflow tract.

those with a similarly dilated aorta in the context of a tri-commissural aortic valve. Moreover, the dissections tend to occur ten years earlier in bicuspid aortic valve disease. The risk is increased in Turner's syndrome, in which there is an increased prevalence of bicuspid aortic valve disease with aortopathy (18, 19, 20).

The most common part of the aorta that dilates in bicuspid aortic valve disease is the ascending aorta just distal to the sinotubular junction (in 76% cases). The sinotubular junction may also be dilated, sparing the sinuses, and this is important when planning surgery as non-dilated sinuses can be left *in situ* and the ascending aorta replaced in isolation. Dilatation of the sinuses is increasingly recognised as a less common pattern of aortic dilatation and occurs in 34% cases (16). Aortic dimensions are bigger if the valve is regurgitant than if it is stenotic.

The aorta should be measured at four levels, illustrated in Fig. 12. The annulus should be measured at end systole, the sinuses of Valsalva, sinotubular junction and ascending aorta at end diastole. For some time, no consensus existed between the American College of Cardiology, European Association of Cardiovascular Imaging (EACVI) and British Society of Echocardiography as to whether to use the leading edge to leading edge technique or the internal diameter technique. However, in October 2017, the EACVI issued a working group statement (21) stating that the leading edge technique should be used to bring their recommendations in line with the American College of Cardiology.

If the aorta cannot be seen, it is important that this information is given in the report. Measurements should be corrected for body surface area in extremes of size (such as in Turner's syndrome) and changes over time should be commented on if previous echoes are available. The suprasternal view is mandatory as the transverse arch may dilate in bicuspid valve disease-related aortopathy. It is worth noting that a bicuspid valve with aortopathy can be an expression of a genetic mutation causing familial thoracic aortic dilatation and dissection syndrome. Implicated genes include MYH11, SMAD3 and ACTA2. A patent arterial duct may also be present.

Associated lesions

These are common in bicuspid aortic valve disease, affecting half of the patients, and several can coexist in the same patient. All echoes on patients with bicuspid aortic valve disease should include assessment for all of these lesions. When several obstructive lesions are found, this is called Shone Complex (or Syndrome).

Cardiac lesions associated with bicuspid aortic valve disease are listed below:

- Coarctation (occurs in 55–75%, more commonly left and right leaflet non-separation);
- Ascending aortopathy;
- Subaortic stenosis;
- Supramitral membrane;
- Hypoplastic mitral valve annulus;
- Left ventricular hypertrabeculation (which can resemble non-compaction cardiomyopathy);
- Patent ductus arteriosus;
- Ventricular septal defect;
- Pulmonary stenosis and pulmonary artery dilatation;
- Sinus of Valsalva aneurysm.

Clinical presentation is on a spectrum and depends on the function of the valve. Natural history studies show that aortic valve stenosis in children is generally progressive. An increase in catheterisation gradient was measured in a third of children over a 4- to 8-year follow-up period (22, 23) and children followed in a UK cohort were found to have similar progression of the aortic valve disease, with more than 80% of those with mild stenosis in childhood progressing to more severe disease at 30-year follow-up (24). Children with measured gradients across the aortic valve >50mmHg were at increased risk (1.2% per year) of adverse cardiac events (25). In the severest form of critical aortic stenosis, the systemic circulation is dependent on

the arterial duct after birth. The clinical presentation is in the neonatal period. Children presenting with AS in infancy have more severe disease and poorer outcomes (22).

Adults may present *de novo* or having been followed from childhood. Presentation can be wide ranging from an incidental finding of a bicuspid aortic valve or murmur to severe aortic stenosis/regurgitation or endocarditis.

Echocardiographic assessment of valvar aortic stenosis

- Assess the morphology of the aortic valve;
- Make aortic measurements including annulus, Valsalva sinuses, sinotubular junction and transverse aorta in parasternal long axis view (leading edge to leading edge). In children, compare absolute figures to reference values for body surface area and express results in z-score (Fig. 12);
- Look for coexisting lesions;
- Assess the function of the aortic valve from the suprasternal or right parasternal approach (Fig. 13). Using the continuous-wave pencil probe is advisable in young adults in the apical five-chamber view. Peak forward flow velocity (Vmax) and peak and mean gradient should be measured, and proximal velocity should be included in the Bernoulli equation ($\Delta P_{max} = 4(v^2_{max} - v^2_{proximal})$);
- Aortic valve area should be calculated using the continuity equation, when there is no subaortic stenosis;
- Assess the size, degree of hypertrophy and function of left ventricle (for serial observations in children, generate z-scores similar to aortic root measurements).

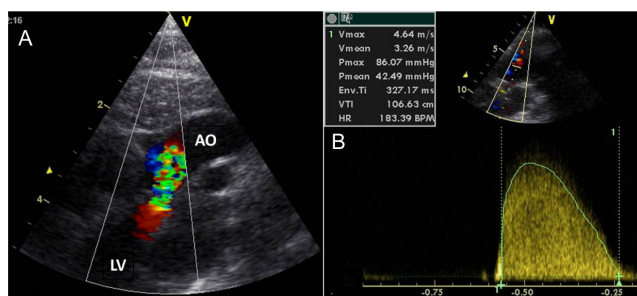


Figure 13
2D and colour flow mapping taken from high parasternal transthoracic approach (A) confirms optimal blood flow alignment for correct measurement of flow on CW Doppler (B). AO, ascendant aorta; LV, left ventricle.

Supravalvar aortic stenosis

Supravalvar aortic stenosis is the least common type of LVOTO, accounting for around 2% of all lesions. Typically, it involves a discrete narrowing of the aortic lumen at the level of the sinotubular junction. There is a strong genetic component involving the elastin gene (7q11.2) associated with supravalvar aortic stenosis (26). There may be stenosis or hypoplasia of additional arterial vessels: the aorta, head and neck vessels, renal and pulmonary arteries and segmental arterial stenosis, as well as hypertension and the echo should be done with this in mind. Careful assessment of branch pulmonary arteries should be done, as well as a thorough assessment of the left ventricle. Assessing the left ventricle for regional wall motion abnormalities is important.

Accompanied by distinctive features and phenotype (developmental delay, 'cocktail chatter', elfin facies), it is pathognomonic for Williams-Beuren syndrome (27). Sporadic cases of supravalvar aortic stenosis can occur, as can familial cases. There is a slight male preponderance in these cases and, in familial cases, supravalvar aortic stenosis can coexist with other congenital heart lesions. In non-Williams cases, genetic testing for elastin and cascade screening of the family is advised.

There is limited data on the natural history of supravalvar aortic stenosis, but over time in children, there is limited growth of the sinotubular region, and increased stenosis occurs (28). Adult patients have usually undergone a repair in childhood, but re-narrowing can occur. Some unoperated cases are seen in adulthood and if mild tend not to progress.

Morphology of supravalvar aortic stenosis

In supravalvar aortic stenosis, the sinotubular junction is markedly thickened (Fig. 14), and there can be an increase in size of the aortic root and sinuses of Valsalva giving an 'hourglass' appearance. In some patients, particularly those with Williams-Beuren syndrome, the entire ascending aorta can be diffusely small due to extreme thickness of the aortic wall (Fig. 15). Commonly, there can be tethering of the leaflets of the aortic valve and coronary ostial stenosis. In 50% of cases, there is a bi-commissural aortic valve (29). The poorly distensible sinotubular junction and the increased shear forces on the valve lead to leaflet thickening and damage (30). The obstruction leads to increased afterload and left ventricular hypertrophy. If additional systemic arterial stenoses are present, the abnormal vessel wall with

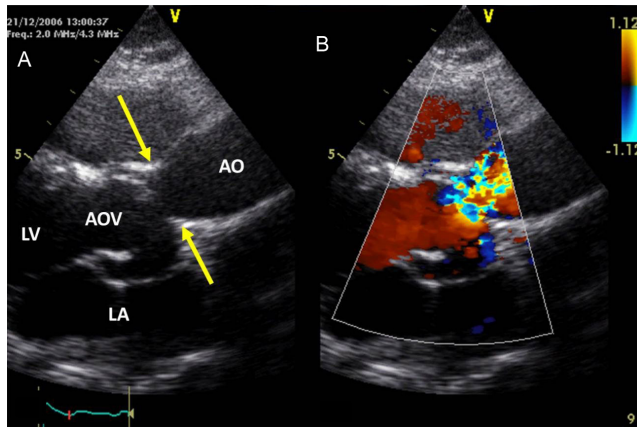


Figure 14
2D parasternal long axis (A) and colour flow mapping (B) in a patient with severe narrowing at the level of sinotubular junction (arrows). AO, aorta; AOV, aortic valve; LA, left atrium; LV, left ventricle.

reduced elasticity will further increase the left ventricular afterload. Myocardial ischaemia has been described; it is generally as a result of adherence of the aortic valve leaflets to the sinotubular junction. This can restrict diastolic filling of the coronaries and most commonly the left coronary artery is affected (31). Coronary blood supply can be limited and cases of sudden cardiac death have been described (32).

Echocardiographic assessment of supralvalvar aortic stenosis

- Identify the anatomical nature of the narrowing on the parasternal long axis view;
- The distal aortic root can be seen from the high parasternal long axis view;
- Examine the aortic valve for stenosis and regurgitation (mechanism is important);
- Measure the aorta including annulus, Valsalva sinuses, sinotubular junction and transverse aorta in the parasternal long axis view (leading edge to leading edge). In children, compare absolute figures to reference values for body surface area and express results expressed as a z-score;
- Assess the size, degree of hypertrophy and function of the left ventricle (for serial observations in children, generate z-scores similar to aortic root measurements);
- Assess the branch pulmonary arteries for stenoses on the parasternal short axis view;
- Estimate the severity using continuous-wave Doppler, quoting the peak velocity as with subaortic stenosis, rather than the pressure gradient;
- Assess the aortic arch from the suprasternal view.

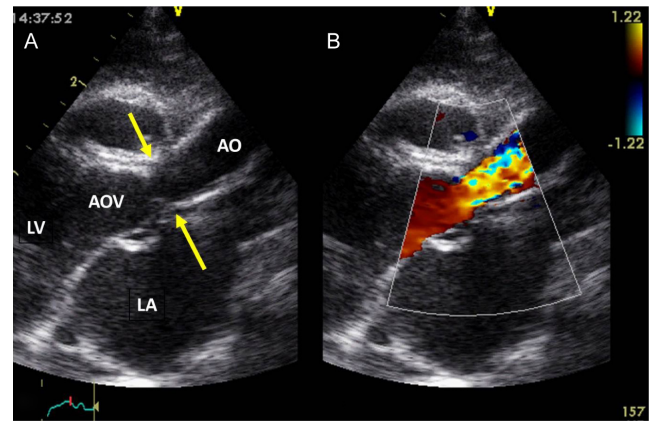


Figure 15
2D parasternal long axis (A) and colour flow mapping (B) in a patient with Williams-Beuren syndrome. Diffuse hypoplasia with markedly thickened aortic wall with flow turbulence occurring just at the level of sinotubular junction (B). AO, aorta; AOV, aortic valve; LA, left atrium; LV, left ventricle.

Management of supralvalvar aortic stenosis

Symptomatic patients with progression of the stenosis (mean gradient >50 mmHg) across the sinotubular junction should be referred for surgical enlargement of the sinotubular region. Relief of obstruction can be achieved by excision of a focal stenosis with end-to-end anastomosis of the ascending aorta, patch enlargement of the sinotubular junction or more complex aortoplasty involving patch placement into two or more of the sinuses of Valsalva. The most common reason for reoperation in this cohort of patients is dysfunction of the aortic valve (33, 34, 35). Aggressive valvuloplasty may help decrease the incidence of late aortic valve replacement, whereas the Ross procedure may be a preferable approach in some patients with complex outflow tract obstruction (29). Further imaging with CT is routinely done in adults before repair to assess the coronary arteries in detail.

Coarctation of the aorta

Coarctation of the aorta refers to narrowing of the aortic isthmus. It is a common congenital heart lesion, which usually presents in infancy with reduced femoral pulses and accounts for 5–8% of all congenital heart defects. The term is also used to describe the rare occurrence of strictures of other segments of the thoracic or the abdominal aorta. No single aetiological cause has been proven and evidence points to an interplay between genetic, environmental and haemodynamic factors (36, 37). Abnormal flow distribution during foetal life

with decreased aortic flow has long been suspected. This is supported by the observation that 71% of cases of aortic atresia also have coarctation (38). The role of genetic factors is increasingly recognised. For example, coarctation occurs in 12% of patients with Turner's syndrome and the incidence of chromosome 22q11 microdeletion is increased in patients with coarctation or interruption of the aortic arch (39, 40). Associated lesions are common; a bicuspid aortic valve is associated with coarctation in 50–85% of patients. Hypoplasia of the aortic arch and other associated cardiovascular anomalies are common (41).

Morphology of coarctation of the aorta

The aortic arch is divided into three segments, as follows:

1. the proximal arch – between the brachiocephalic and the left carotid arteries;
2. the distal arch – between the left carotid and the left subclavian arteries (transverse arch); and
3. the isthmus – between the left subclavian and the arterial duct (Fig. 16).

The aortic arch is defined as being hypoplastic if any segment is particularly small with reference to the diameter of the ascending aorta (AAd). If either the proximal segment is less than 60% AAd, the distal segment

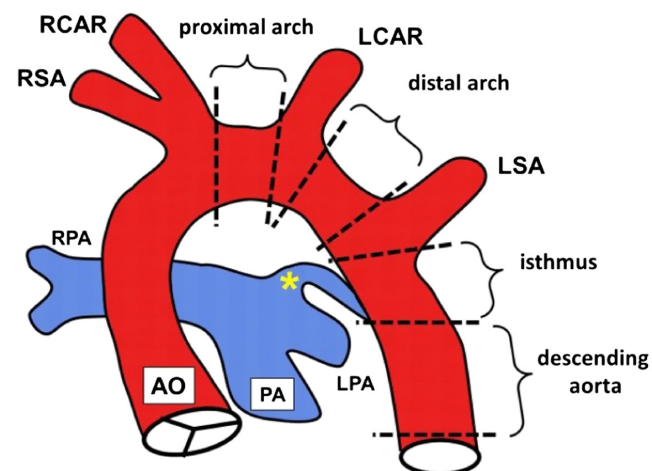


Figure 16
Schematic drawing of proximal and distal aortic arch, aortic isthmus, arterial duct or ligamentum (asterisk) and descending aorta. LCAR, left carotid artery; LPA, left pulmonary artery; PA, pulmonary trunk; RCAR, right carotid artery; RPA, right pulmonary artery; RSA, right subclavian artery. Reproduced, with permission, from Marek J, Fenton M & Khambadkone S (2015) Aortic arch anomalies: coarctation of the aorta and interrupted aortic arch. In *Echocardiography in Pediatric and Congenital Heart Disease: From Fetus to Adult*, 2nd edn, ch 21. Eds WW Lai, LL Mertens, MS Cohen, T Geva. Copyright 2015 Wiley-Blackwell.

less than 50% AAd or isthmus less than 40% AAd, the arch is hypoplastic. Transverse aortic arch hypoplasia is often defined echocardiographically in neonates as an internal diameter of less than 1 mm per 1 kg weight. Z-scores are also used commonly. If the z-score is less than 2 standard deviations below the mean of the normal population, the arch is hypoplastic.

The most common type of coarctation is juxtaductal. This results from narrowing of the isthmus at its junction with the proximal descending aorta in the region of the insertion of the arterial duct.

There is a wide spectrum of anatomy, but there are distinguishable morphologic patterns, based on age at the time of diagnosis: in foetal life, in early infancy and in older children and adults. In the foetus and infant, the following pattern is most often seen: the distal transverse arch (between the left common carotid and left subclavian arteries) is elongated and hypoplastic (tubular hypoplasia), the angle between the transverse arch and ascending aorta is acute and the isthmus is diffusely hypoplastic (38) with an almost always widely patent arterial duct (Fig. 17).

In neonates, gradual development of coarctation can develop during closure of the arterial duct. Histological studies have shown ductal tissue surrounding the juxtaductal portion of the aorta in a circumferential

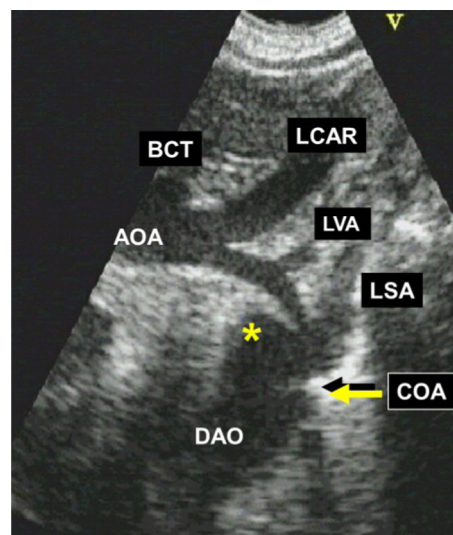


Figure 17
Neonatal coarctation (COA) with severe transverse aortic arch hypoplasia from suprasternal view. Elongated hypoplastic arch with maximum of narrowing between left carotid artery (LCAR), left vertebral artery (LVA) and left subclavian artery (LSA), which is predominantly supplied by arterial duct (asterisk). BCT, brachiocephalic trunk; DAO, descendent aorta. Reproduced, with permission, from Marek J, Fenton M & Khambadkone S (2015) Aortic arch anomalies: coarctation of the aorta and interrupted aortic arch. In *Echocardiography in Pediatric and Congenital Heart Disease: From Fetus to Adult*, 2nd edn, ch 21. Eds WW Lai, LL Mertens, MS Cohen, T Geva. Copyright 2015 Wiley-Blackwell.

fashion (39). Although the distal isthmus is typically the site of stenosis, other locations or multiple sites can be affected, for example, opposite or proximal to the origin of the left subclavian or brachiocephalic artery. In older children and adults, arch hypoplasia is less common. The segment of coarctation is most often discrete, and collateral arteries are commonly present, bypassing the coarctation. These collateral vessels develop because of increased blood flow through the intercostals, internal mammary and scapular arteries.

In all age groups, the coarctation segment is characterised by three elements: luminal narrowing due to thickening of the tunica intima and media, hypoplasia and tortuosity. The protrusion of the intimal-medial ridge (or 'shelf') into the lumen is usually circumferential (as described earlier) but is often seen to be more prominent on the posterior and lateral walls of the isthmus (Fig. 18). The stenotic segment varies in length from a discrete area, measuring only 2–3 mm to a long segment, which can be 7–20 mm. Immediately distal to the coarctation, the proximal descending aorta is often dilated. This is called post-stenotic dilatation and is more frequently seen in older children and adults.

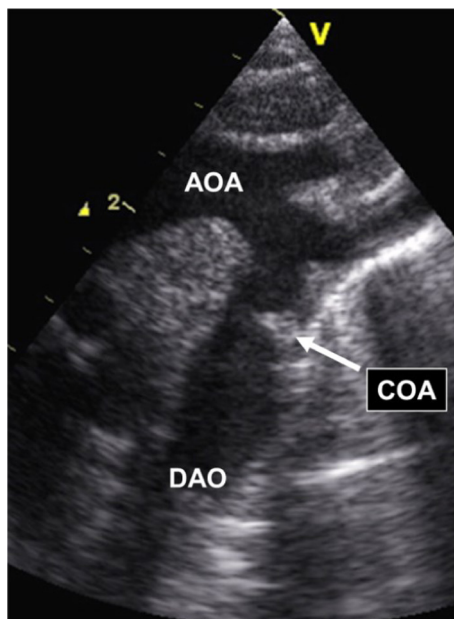


Figure 18

Imaging of COA from the suprasternal notch view. Coarctation ridge (COA) located ~5 mm below the origin of left subclavian artery. Descendent thoracic aorta (DAO) below obstruction is dilated. AOA, aortic arch. Reproduced, with permission, from Marek J, Fenton M & Khambadkone S (2015) Aortic arch anomalies: coarctation of the aorta and interrupted aortic arch. In *Echocardiography in Pediatric and Congenital Heart Disease: From Fetus to Adult*, 2nd edn, ch 21. Eds WW Lai, LL Mertens, MS Cohen, T Geva. Copyright 2015 Wiley-Blackwell.

Echocardiographic assessment of coarctation of the aorta

- In children, assess the flow profile in abdominal aorta in subcostal sagittal view (Fig. 19);
- Assess the appearance of coarctation/repair on 2D from suprasternal view;
- Look out for dilated vessels or collaterals on 2D and with colour Doppler;
- Assess the severity of the coarctation using continuous wave Doppler – identify diastolic tail if present (Fig. 20);
- Do not use the modified Bernoulli equation – quote peak flow velocity not peak pressure drop;
- Quote peak diastolic velocity /peak systolic velocity, diastolic pressure half-time index and diastolic velocity half-time index;
- Look for associated left-sided congenital lesions, including bicuspid aortic valve and ascending aortopathy;
- Assess the size, degree of hypertrophy and function of left ventricle (for serial observations in children, generate z-scores similar to aortic root measurements).

Echo assessment of coarctation after surgical or catheter-based repair is similar to that of assessment of native coarctation. Imaging the distal arch, isthmus and descending aorta from the suprasternal window can be difficult in older adults due to body habitus and postoperative changes. It is essential to be aware of the

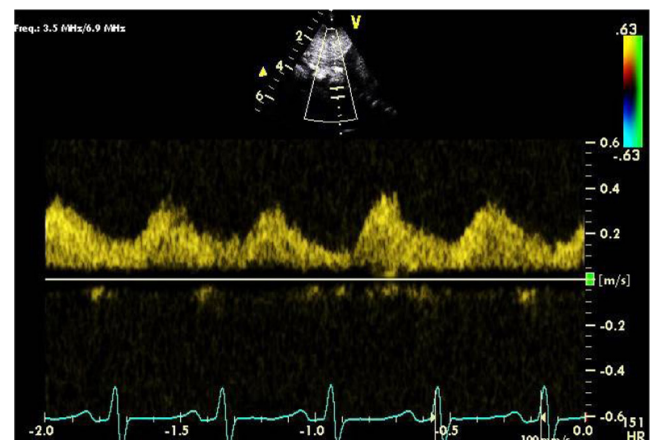


Figure 19

Pulsed Doppler flow pattern in the abdominal aorta from subcostal sagittal view. Systolic wave form amplitude is low; antegrade diastolic flow indicates the obstruction proximal to sample volume. Reproduced, with permission, from Marek J, Fenton M & Khambadkone S (2015) Aortic arch anomalies: coarctation of the aorta and interrupted aortic arch. In *Echocardiography in Pediatric and Congenital Heart Disease: From Fetus to Adult*, 2nd edn, ch 21. Eds WW Lai, LL Mertens, MS Cohen, T Geva. Copyright 2015 Wiley-Blackwell.

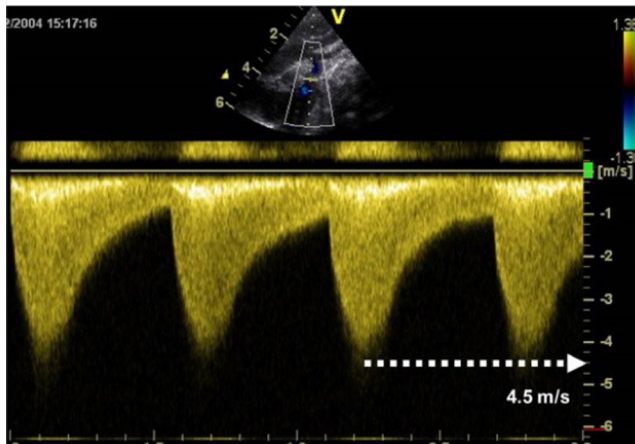


Figure 20

Continuous wave Doppler through the aortic isthmus of a patient with severe COA. Note the high-velocity systolic amplitude (4.5 m/s) with continuous antegrade flow throughout diastole. Reproduced, with permission, from Marek J, Fenton M & Khambadkone S (2015) Aortic arch anomalies: coarctation of the aorta and interrupted aortic arch. In *Echocardiography in Pediatric and Congenital Heart Disease: From Fetus to Adult*, 2nd edn, ch 21. Eds WW Lai, LL Mertens, MS Cohen, T Geva. Copyright 2015 Wiley-Blackwell.

details of the previous surgical or catheter procedure before performing the study. For example, in a subclavian flap coarctation repair, the surgeon will use the left subclavian artery in the operation, and it will be absent. If views are good, the brachiocephalic trunk, left carotid artery and left subclavian arteries can be seen. If balloon dilatation of multilevel narrowing has occurred, restenosis may be visualised between these vessels. Stents implanted in the isthmus in adolescents and adults can be difficult to visualise due to artefacts produced by acoustic reflections from the stent but may be acceptable in younger patients (Fig. 21). Long-term complications of surgical or transcatheter coarctation repair include aneurysm formation and aortic dissection at the repair site, though it is rarely possible to visualise these on echocardiography. Similarly, visualisation of vascular prostheses after extra-anatomic bypass is also difficult but ought to be attempted where appropriate.

In both repaired and native coarctation, a comprehensive assessment of the left ventricular size and function, inflow and outflow tracts and both mitral and aortic valves should be performed as well as a detailed assessment of the aortic root and ascending aorta.

Management of coarctation of the aorta

Treatment options for the repair of coarctation of the aorta include surgery, percutaneous balloon angioplasty

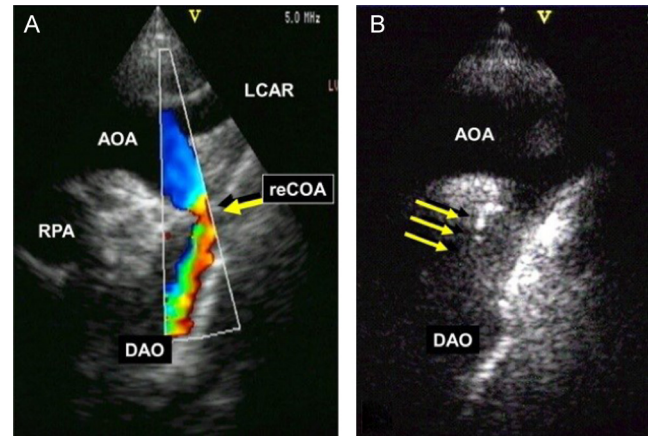


Figure 21

(A) Recurrent coarctation of aorta (reCOA) in a patient after left subclavian flap aortoplasty (Waldhausen procedure). Narrowing with flow acceleration seen by colour Doppler flow mapping at the level of origin of left subclavian artery, which was used to extend tubular aortic narrowing. (B) Stent implantation at the level of residual narrowing in a patient with recurrent coarctation (arrows). AOA, aortic arch; LCAR, left carotid artery; RPA, right pulmonary artery. Reproduced, with permission, from Marek J, Fenton M & Khambadkone S (2015) Aortic arch anomalies: coarctation of the aorta and interrupted aortic arch. In *Echocardiography in Pediatric and Congenital Heart Disease: From Fetus to Adult*, 2nd edn, ch 21. Eds WW Lai, LL Mertens, MS Cohen, T Geva. Copyright 2015 Wiley-Blackwell.

+/- stent implantation. Surgery is the usual treatment choice for native coarctation in neonates, whereas percutaneous options are usually first line for recurrent or native coarctation in older children and adults (42, 43). The surgical treatment of choice is resection of the coarctation with end-to-end anastomosis. If a patent arterial duct is present, it is ligated at the time of surgery. In cases of aortic arch hypoplasia, the arch is augmented either by a reversed subclavian flap aortoplasty or an extended anastomosis between the undersurface of the arch and the descending aorta. Less commonly, the surgeon may have performed a subclavian flap aortoplasty or bypass of the stenotic aortic segment with placement of a conduit, and patch repair of the coarctation site. Patch aortoplasty has been associated with a high incidence of aneurysm at the repair site (44, 45, 46).

Persistence or recurrence of the coarctation is a known complication of the repair in a small but significant number of patients. Reintervention can be required in 10% of patients (47). Regardless of the specific intervention, the aorta in patients with coarctation repair remains abnormal. This group of patients remains at lifelong risk of hypertension as well as complications such as the need for reintervention (48). Lifelong follow-up is necessary to identify and treat these if they occur.

Declaration of interest

The authors declare that there is no conflict of interest that could be perceived as prejudicing the impartiality of this review.

Funding

This work did not receive any specific grant from any funding agency in the public, commercial, or not-for-profit sector.

References

- Katz NM, Buckley MJ & Liberthson RR. Discrete membranous subaortic stenosis. Report of 31 patients, review of the literature, and delineation of management. *Circulation* 1977 **56** 1034–1038. (<https://doi.org/10.1161/01.CIR.56.6.1034>)
- Gewillig M, Daenen W, Dumoulin M & Van der Hauwaert L. Rheologic genesis of discrete subvalvular aortic stenosis: a Doppler echocardiographic study. *Journal of the American College of Cardiology* 1992 **19** 818–824. ([https://doi.org/10.1016/0735-1097\(92\)90524-Q](https://doi.org/10.1016/0735-1097(92)90524-Q))
- Choi JY & Sullivan ID. Fixed subaortic stenosis: anatomical spectrum and nature of progression. *British Heart Journal* 1991 **65** 280–286. (<https://doi.org/10.1136/hrt.65.5.280>)
- Brauner R, Laks H, Drinkwater DC Jr, Shvarts O, Eghbali K & Galindo A. Benefits of early surgical repair in fixed subaortic stenosis. *Journal of the American College of Cardiology* 1997 **30** 1835–1842. ([https://doi.org/10.1016/S0735-1097\(97\)00410-5](https://doi.org/10.1016/S0735-1097(97)00410-5))
- Wright GB, Keane JF, Nadas AS, Bernhard WF & Castaneda AR. Fixed subaortic stenosis in the young: medical and surgical course in 83 patients. *American Journal of Cardiology* 1983 **52** 830–835. ([https://doi.org/10.1016/0002-9149\(83\)90423-X](https://doi.org/10.1016/0002-9149(83)90423-X))
- McMahon CJ, Gauvreau K, Edwards JC & Geva T. Risk factors for aortic valve dysfunction in children with discrete subvalvular aortic stenosis. *American Journal of Cardiology* 2004 **94** 459–464. (<https://doi.org/10.1016/j.amjcard.2004.05.005>)
- Gersony WM. Natural history of discrete subvalvular aortic stenosis: management implications. *Journal of the American College of Cardiology* 2001 **38** 843–845. ([https://doi.org/10.1016/S0735-1097\(01\)01454-1](https://doi.org/10.1016/S0735-1097(01)01454-1))
- Karamlou T, Gurofsky R, Bojcevski A, Williams WG, Caldarone CA, Van Arsdell GS, Paul T & McCrindle W. Prevalence and associated risk factors for intervention in 313 children with subaortic stenosis. *Annals of Thoracic Surgery* 2007 **84** 900–906. (<https://doi.org/10.1016/j.athoracsur.2007.03.059>)
- Rastan H & Koncz J. Aortoventriculoplasty: a new technique for the treatment of left ventricular outflow tract obstruction. *Journal of Thoracic and Cardiovascular Surgery* 1976 **71** 920–927.
- Rizzoli G, Tiso E, Mazzucco A, Daliotto L, Rubino M, Tursi V & Fracasso A. Discrete subaortic stenosis. Operative age and gradient as predictors of late aortic valve incompetence. *Journal of Thoracic and Cardiovascular Surgery* 1993 **106** 95–104.
- Douville EC, Sade RM, Crawford FA Jr & Wiles HB. Subvalvular aortic stenosis: timing of operation. *Annals of Thoracic Surgery* 1990 **50** 29–33. ([https://doi.org/10.1016/0003-4975\(90\)90076-1](https://doi.org/10.1016/0003-4975(90)90076-1))
- Siu SC & Silversides CK. Bicuspid aortic valve disease. *Journal of the American College of Cardiology* 2010 **55** 2789–2800. (<https://doi.org/10.1016/j.jacc.2009.12.068>)
- Tutar E, Ekici F, Atalay S & Nacar N. The prevalence of bicuspid aortic valve in newborns by echocardiographic screening. *American Heart Journal* 2005 **150** 513–515. (<https://doi.org/10.1016/j.ahj.2004.10.036>)
- Lewin MB, McBride KL, Pignatelli R, Fernbach S, Combes A, Menesses A, Lam W, Bezold LI, Kaplan N, Towbin JA, *et al.* Echocardiographic evaluation of asymptomatic parental and sibling cardiovascular anomalies associated with congenital left ventricular outflow tract lesions. *Pediatrics* 2004 **114** 691–696. (<https://doi.org/10.1542/peds.2003-0782-L>)
- Garg V, Muth AN, Ransom JF, Schluterman MK, Barnes R, King IN, Grossfeld PD & Srivastava D. Mutations in NOTCH1 cause aortic valve disease. *Nature* 2005 **437** 270–274. (<https://doi.org/10.1038/nature03940>)
- Evangelista A, Gallego P, Calvo-Iglesias F, Bermejo J, Robledo-Carmona J, Sánchez V, Saura D, Arnold R, Carro A, Maldonado G, *et al.* Anatomical and clinical predictors of valve dysfunction and aortic dilation in bicuspid aortic valve disease. *Heart* 2017 **104** 566–573. (<https://doi.org/10.1136/heartjnl-2017-311560>)
- Fernandes SM, Sanders SP, Khairy P, Jenkins KJ, Gauvreau K, Lang P, Simonds H & Colan SD. Morphology of bicuspid aortic valve in children and adolescents. *Journal of the American College of Cardiology* 2004 **44** 1648–1651. (<https://doi.org/10.1016/j.jacc.2004.05.063>)
- Tzemos N, Therrien J, Yip J, Thanassoulis G, Tremblay S, Jamorski MT, Webb GD & Siu SC. Outcomes in adults with bicuspid aortic valves. *JAMA* 2008 **300** 1317–1325. (<https://doi.org/10.1001/jama.300.11.1317>)
- Michelena HI, Khanna AD, Mahoney D, Margaryan E, Topilsky Y, Suri RM, Eidem B, Edwards WD, Sundt TM 3rd & Enriquez-Sarano M. Incidence of aortic complications in patients with bicuspid aortic valves. *JAMA* 2011 **306** 1104–1112. (<https://doi.org/10.1001/jama.2011.1286>)
- Januzzi JL, Isselbacher EM, Fattori R, Cooper JV, Smith DE, Fang J, Eagle KA, Mehta RH, Nienaber CA, Pape LA, *et al.* Characterizing the young patient with aortic dissection: results from the International Registry of Aortic Dissection (IRAD). *Journal of the American College of Cardiology* 2004 **43** 665–669. (<https://doi.org/10.1016/j.jacc.2003.08.054>)
- Baumgartner H, Falk V, Bax JJ, De Bonis M, Hamm C, Holm PJ, Jung B, Lancellotti P, Lansac E, Rodriguez Muñoz D, *et al.* 2017 ESC/EACTS guidelines for the management of valvular heart disease. *European Heart Journal: Cardiovascular Imaging* 2017 **38** 2739–2791.
- Nadas AS. Report from the joint study on the natural history of congenital heart defects. IV. Clinical course. Introduction. *Circulation* 1977 **56** 136–138.
- Wagner HR, Ellison RC, Keane JF, Humphries JO & Nadas AS. Clinical course in aortic stenosis. *Circulation* 1977 **56** 147–156.
- Kitchiner D, Jackson M, Walsh K, Peart I & Arnold R. The progression of mild congenital aortic valve stenosis from childhood into adult life. *International Journal of Cardiology* 1993 **42** 217–223. ([https://doi.org/10.1016/0167-5273\(93\)90051-H](https://doi.org/10.1016/0167-5273(93)90051-H))
- Keane JF, Driscoll DJ, Gersony WM, Hayes CJ, Kidd L, O'Fallon WM, Pieroni DR, Wolfe RR & Weidman WH. Second natural history study of congenital heart defects. Results of treatment of patients with aortic valvar stenosis. *Circulation* 1993 **87** (Supplement 2) I16–I27.
- Nickerson E, Greenberg F, Keating MT, McCaskill C & Shaffer LG. Deletions of the elastin gene at 7q11.23 occur in approximately 90% of patients with Williams syndrome. *American Journal of Human Genetics* 1995 **56** 1156–1161.
- Bruno E, Rossi N, Thüer O, Córdoba R & Alday LE. Cardiovascular findings, and clinical course, in patients with Williams syndrome. *Cardiology in the Young* 2003 **13** 532–536.
- Kim YM, Yoo SJ, Choi JY, Kim SH, Bae EJ & Lee YT. Natural course of supravalvular aortic stenosis and peripheral pulmonary arterial stenosis in Williams' syndrome. *Cardiology in the Young* 1999 **9** 37–41.
- McElhinney DB, Petrossian E, Tworetzky W, Silverman NH & Hanley FL. Issues and outcomes in the management of supravalvular aortic stenosis. *Annals of Thoracic Surgery* 2000 **69** 562–567. ([https://doi.org/10.1016/S0003-4975\(99\)01293-X](https://doi.org/10.1016/S0003-4975(99)01293-X))

- 30 Braunstein PW Jr, Sade RM, Crawford FA Jr & Oslizlok PC. Repair of supravalvar aortic stenosis: cardiovascular morphometric and hemodynamic results. *Annals of Thoracic Surgery* 1990 **50** 700–707. ([https://doi.org/10.1016/0003-4975\(90\)90665-S](https://doi.org/10.1016/0003-4975(90)90665-S))
- 31 Stamm C, Li J, Ho SY, Redington AN & Anderson RH. The aortic root in supravalvular aortic stenosis: the potential surgical relevance of morphologic findings. *Journal of Thoracic and Cardiovascular Surgery* 1997 **114** 16–24. ([https://doi.org/10.1016/S0022-5223\(97\)70112-0](https://doi.org/10.1016/S0022-5223(97)70112-0))
- 32 Thiene G & Ho SY. Aortic root pathology and sudden death in youth: review of anatomical varieties. *Applied Pathology* 1986 **4** 237–245.
- 33 Sharma BK, Fujiwara H, Hallman GL, Ott DA, Reul GJ & Cooley DA. Supravalvar aortic stenosis: a 29-year review of surgical experience. *Annals of Thoracic Surgery* 1991 **51** 1031–1039. ([https://doi.org/10.1016/0003-4975\(91\)91045-W](https://doi.org/10.1016/0003-4975(91)91045-W))
- 34 van Son JA, Danielson GK, Puga FJ, Schaff HV, Rastogi A, Edwards WD & Feldt RH. Supravalvular aortic stenosis. Long-term results of surgical treatment. *Journal of Thoracic and Cardiovascular Surgery* 1994 **107** 103–114.
- 35 Delius RE, Steinberg JB, L'Ecuyer T, Doty DB & Behrendt DM. Long-term follow-up of extended aortoplasty for supravalvular aortic stenosis. *Journal of Thoracic and Cardiovascular Surgery* 1995 **109** 155–162. ([https://doi.org/10.1016/S0022-5223\(95\)70431-0](https://doi.org/10.1016/S0022-5223(95)70431-0))
- 36 Campbell M & Polani PE. The aetiology of coarctation of the aorta. *Lancet* 1961 **1** 463–468. ([https://doi.org/10.1016/S0140-6736\(61\)90055-1](https://doi.org/10.1016/S0140-6736(61)90055-1))
- 37 Bower C & Ramsay JM. Congenital heart disease: a 10 year cohort. *Journal of Paediatrics and Child Health* 1994 **30** 414–418. (<https://doi.org/10.1111/j.1440-1754.1994.tb00691.x>)
- 38 Mahowald JM, Lucas RV Jr & Edwards JE. Aortic valvular atresia. Associated cardiovascular anomalies. *Pediatric Cardiology* 1982 **2** 99–105. (<https://doi.org/10.1007/BF02424944>)
- 39 Ho VB, Bakalov VK, Cooley M, Van PL, Hood MN, Burklow TR & Bondy CA. Major vascular anomalies in Turner syndrome: prevalence and magnetic resonance angiographic features. *Circulation* 2004 **110** 1694–1700. (<https://doi.org/10.1161/01.CIR.0000142290.35842.B0>)
- 40 Goldmuntz E, Clark BJ, Mitchell LE, Jawad AF, Cuneo BF, Reed L, McDonald-McGinn D, Chien P, Feuer J, Zackai EH, *et al.* Frequency of 22q11 deletions in patients with conotruncal defects. *Journal of the American College of Cardiology* 1998 **32** 492–498. ([https://doi.org/10.1016/S0735-1097\(98\)00259-9](https://doi.org/10.1016/S0735-1097(98)00259-9))
- 41 Reifenshtein GH, Levine SA & Gross RE. Coarctation of the aorta; a review of 104 autopsied cases of the adult type, 2 years of age or older. *American Heart Journal* 1947 **33** 146–168. ([https://doi.org/10.1016/0002-8703\(47\)90002-1](https://doi.org/10.1016/0002-8703(47)90002-1))
- 42 Redington AN, Booth P, Shore DF & Rigby ML. Primary balloon dilatation of coarctation of the aorta in neonates. *British Heart Journal* 1990 **64** 277–281. (<https://doi.org/10.1136/hrt.64.4.277>)
- 43 Grinda JM, Mace L, Dervanian P, Folliguet TA & Neveux JY. Bypass graft for complex forms of isthmic aortic coarctation in adults. *Annals of Thoracic Surgery* 1995 **60** 1299–1302. ([https://doi.org/10.1016/0003-4975\(95\)00557-2](https://doi.org/10.1016/0003-4975(95)00557-2))
- 44 Rodes-Cabau J, Miró J, Dancea A, Ibrahim R, Piette E, Lapierre C, Jutras L, Perron J, Tchervenkov CI, Poirier N, *et al.* Comparison of surgical and transcatheter treatment for native coarctation of the aorta in patients > or = 1 year old. The Quebec Native Coarctation of the Aorta study. *American Heart Journal* 2007 **154** 186–192. (<https://doi.org/10.1016/j.ahj.2007.03.046>)
- 45 Dietl CA, Torres AR, Favaloro RG, Fessler CL & Grunkemeier GL. Risk of recoarctation in neonates and infants after repair with patch aortoplasty, subclavian flap, and the combined resection-flap procedure. *Journal of Thoracic and Cardiovascular Surgery* 1992 **103** 724–731.
- 46 Sciolaro C, Copeland J, Cork R, Barkenbush M, Donnerstein R & Goldberg S. Long-term follow-up comparing subclavian flap angioplasty to resection with modified oblique end-to-end anastomosis. *Journal of Thoracic and Cardiovascular Surgery* 1991 **101** 1–13.
- 47 Brown JW, Ruzmetov M, Hoyer MH, Rodefeld MD & Turrentine MW. Recurrent coarctation: is surgical repair of recurrent coarctation of the aorta safe and effective? *Annals of Thoracic Surgery* 2009 **88** 1923–1930. (<https://doi.org/10.1016/j.athoracsur.2009.07.024>)
- 48 Brouwer RM, Erasmus ME, Ebels T & Eijgelaar A. Influence of age on survival, late hypertension, and recoarctation in elective aortic coarctation repair. Including long-term results after elective aortic coarctation repair with a follow-up from 25 to 44 years. *Journal of Thoracic and Cardiovascular Surgery* 1994 **108** 525–531.

Received in final form 5 March 2018

Accepted 16 March 2018

Accepted Preprint published online 16 March 2018