

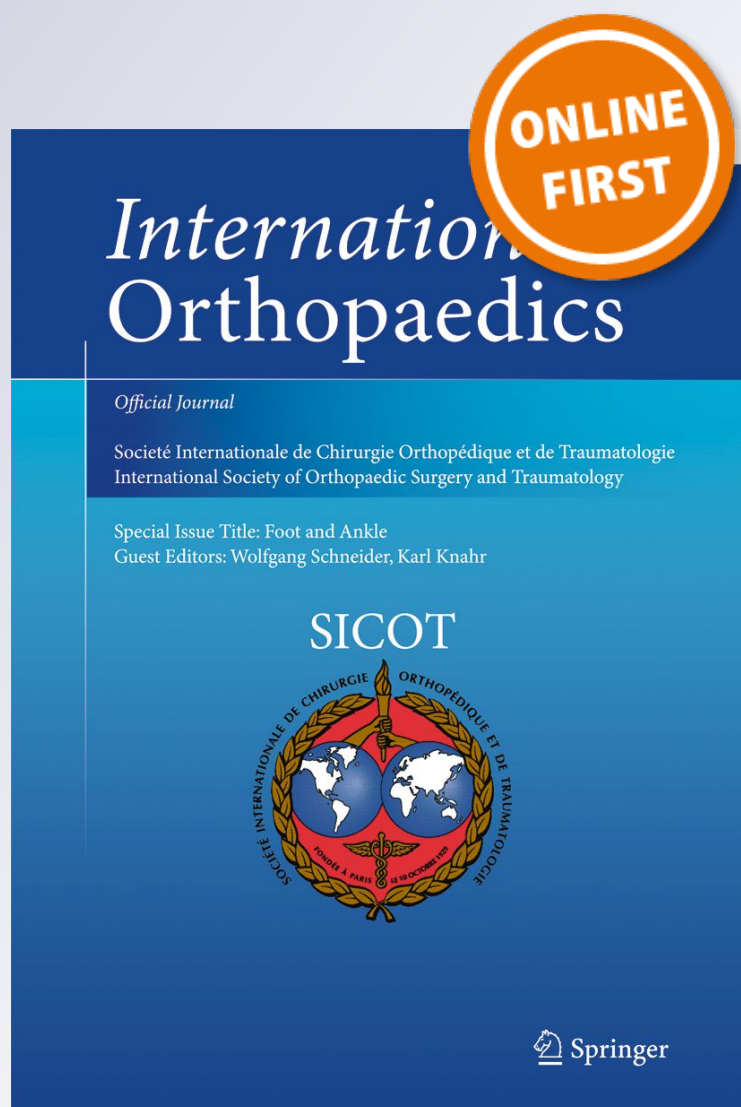
# Outcomes of cartilage repair techniques for chondral injury in the hip—a systematic review

**Naoki Nakano, Chetan Gohal, Andrew Duong, Olufemi R. Ayeni & Vikas Khanduja**

**International Orthopaedics**

ISSN 0341-2695

International Orthopaedics (SICOT)  
DOI 10.1007/s00264-018-3862-6



**Your article is published under the Creative Commons Attribution license which allows users to read, copy, distribute and make derivative works, as long as the author of the original work is cited. You may self-archive this article on your own website, an institutional repository or funder's repository and make it publicly available immediately.**



# Outcomes of cartilage repair techniques for chondral injury in the hip—a systematic review

Naoki Nakano<sup>1</sup> · Chetan Gohal<sup>2</sup> · Andrew Duong<sup>2</sup> · Olufemi R. Ayeni<sup>2</sup> · Vikas Khanduja<sup>1</sup> 

Received: 20 December 2017 / Accepted: 21 February 2018  
© The Author(s) 2018

## Abstract

**Objective/purpose** The aim of the study was to assess the options of treatment and their related outcomes for chondral injuries in the hip based on the available evidence whilst highlighting new and innovative techniques.

**Methods** A systematic review of the literature from PubMed (Medline), EMBASE, Google Scholar, British Nursing Index (BNI), Cumulative Index to Nursing and Allied Health Literature (CINAHL) and Allied and Complementary Medicine Database (AMED) was undertaken from their inception to March 2017 using the Preferred Reporting Items for Systematic Reviews and Meta-Analyses (PRISMA) guidelines. Clinical outcome studies, prospective/retrospective case series and case reports that described the outcome of cartilage repair technique for the chondral injury in the hip were included. Studies on total hip replacement, animal studies, basic studies, trial protocols and review articles were excluded.

**Results** The systematic review found 21 relevant papers with 596 hips. Over 80% of the included studies were published in or after 2010. Most studies were case series or case reports (18 studies, 85.7%). Arthroscopy was used in 11 studies (52.4%). The minimum follow-up period was six months. Mean age of the participants was 37.2 years; 93.5% of patients had cartilage injuries of the acetabulum and 6.5% of them had injuries of the femoral head. Amongst the 11 techniques described in the systematic review, autologous matrix-induced chondrogenesis, osteochondral autograft transplantation and microfracture were the three frequently reported techniques.

**Conclusion** Over ten different techniques are available for cartilage repair in the hip, and most of them have good short- to medium-term outcomes. However, there are no robust comparative studies to assess superiority of one technique over another, and further research is required in this arena.

**Keywords** Cartilage repair · Hip · Chondral injury · Arthroscopy · Systematic review

## Introduction

Isolated chondral and osteochondral defects within the hip joint often present a technical challenge for the hip surgeon. Common causes of cartilage damage in the hip include femoroacetabular impingement (FAI), developmental dysplasia, osteonecrosis, osteochondritis dissecans, loose bodies,

slipped capital femoral epiphysis, and trauma [1–5]. Amongst them, FAI has increasingly gained recognition as a major cause of chondral injury and subsequent development of arthritis in the hip joint [6–10]. In CAM FAI, the abnormal contact between the aspherical femoral head-neck junction and the acetabular rim results in a large amount of shear stress being transmitted to the labro-chondral junction. Over a period of time, labral detachment and acetabular chondral damage ensues [2, 11, 12]. On the other hand, the pincer FAI, in which a deep or retroverted acetabulum makes contact with a normal-shaped femoral neck, has a recognised pattern of damage to the labrum, femoral head cartilage and a postero-medial acetabular countercoup lesion [13]. Furthermore, in imaging and surgical techniques like hip arthroscopy have led to increased recognition of chondral lesions. The incidence of chondral lesions at hip arthroscopy for FAI has been reported to be up to 67.3% of the patients in one series [14].

✉ Vikas Khanduja  
vk279@cam.ac.uk

<sup>1</sup> Department of Trauma and Orthopaedics, Addenbrooke's Hospital, Cambridge University Hospitals NHS Foundation Trust, Box 37, Hills Road, Cambridge CB2 0QQ, UK

<sup>2</sup> Department of Orthopaedics, McMaster University, 1280 Main Street West, Hamilton, ON L8S 4K1, Canada

There is relatively little information about articular cartilage restoration in the hip when compared with what is known about cartilage restoration in the knee. Currently, most cartilage repair methods for the hip are based on basic science and strategies that were developed for the knee. Awareness of young adult hip disease has been increasing in recent years, and thus, the field of hip preservation continues to develop; several new innovative techniques have been performed and described in the literature. They include microfracture, autologous chondrocyte implantation (ACI), matrix-associated chondrocyte implantation (MACI), autologous matrix-induced chondrogenesis (AMIC), osteochondral autograft/allograft transplantation, implantation of artificial plug, sticking down of chondral flaps with fibrin adhesive and an intra-articular injection of bone marrow mesenchymal stem cells (BM-MSCs).

Currently, there is a gap in information particularly regarding systematic reviews in the literature that provide hip surgeons with evidence-based recommendations, therefore, on treating cartilage injuries in the hip. The aim of this study was to provide the reader with options of treatment and their related outcomes for chondral injuries in the hip based on the available evidence whilst highlighting new and innovative techniques involved in chondral repair.

## Methods

### Search strategy

Two reviewers (NN and CG) searched the online databases (PubMed (Medline), EMBASE, Google Scholar, British Nursing Index (BNI), Cumulative Index to Nursing and Allied Health Literature (CINAHL) and Allied and Complementary Medicine Database (AMED) for literature describing the outcome of cartilage repair techniques for the chondral injury in the hip. The Preferred Reporting Items for Systematic Reviews and Meta-Analyses (PRISMA) guidelines were used for designing this study. A detailed search strategy is described in the [Appendix](#).

### Study screening/data abstraction

The inclusion and exclusion criteria are shown in [Table 1](#). Both the reviewers independently abstracted the relevant study data from the final pool of included articles and recorded this data on a spreadsheet designed a priori. Participant-specific demographics extracted from each study included the number of hips, gender distribution, mean age with range (years), length of follow-up, location of the cartilage injury (acetabulum or femoral head), surgical approach (open dislocation, arthroscopy or injection), cartilage restoration technique used in the

**Table 1** Inclusion and exclusion criteria applied to articles identified in the literature

#### Inclusion criteria

1. All levels of evidence
2. Written in the English language
3. Studies on humans
4. Studies reporting the outcome of cartilage repair techniques for cartilage injuries in the hip

#### Exclusion criteria

1. Studies on other joints (e.g. knee)
2. Studies describing trial protocols without any results
3. Hip replacement surgery
4. Basic studies (e.g. cadaveric studies)
5. Reviews, systematic reviews

study, pre-operative condition of the damaged cartilage, final outcome and specific comments (if any).

## Statistics

The abstracted evidence was collected and analysed using Microsoft Excel 2013 spread sheet. Statistical analysis in this study focused on descriptive statistics.

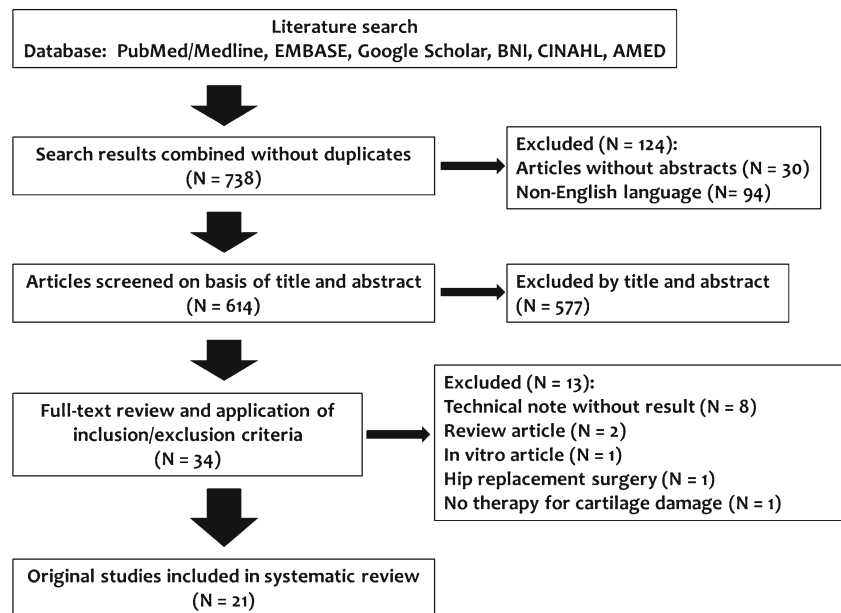
## Results

Flowchart of the literature search is shown in [Fig. 1](#). The oldest study included in this review was published in 2003, and over 80% of the included studies (17 out of 21 studies) were published in or after 2010. Study demographics are shown in [Table 2](#). A total of 11 techniques were found from the systematic review: AMIC (5 studies), osteochondral autograft transplantation (mosaicplasty) (5 studies), microfracture (4 studies), artificial plug (TruFit®) (2 studies), fibrin adhesive (2 studies), ACI (2 studies), debridement (1 study), MACI (1 study), osteochondral allograft transplantation (1 study), direct cartilage suture repair (1 study) and intra-articular BM-MSC injection (1 study). Three studies described two techniques and compared them to each other (microfracture and AMIC, 1 study; MACI and AMIC, 1 study; ACI and debridement, 1 study).

Details of the 21 studies included are shown in [Table 3](#).

## Discussion

Our objective was to discuss the outcomes of the current strategies for restoration of focal chondral injuries in the hip. This study reviews all the cases of cartilage repair for the chondral injuries in the hip (596 cases) reported in the English literature and describes the outcomes of 11 techniques (including debridement).

**Fig. 1** Flowchart of the literature search

Cartilage injuries in the hip have been previously shown to result in poor long-term outcomes, including pain and early secondary degenerative change followed by the subsequent development of osteoarthritis [15, 16]. The current trend is to focus on treating isolated cartilage damage and underlying morphological pathology in younger patients in order to prevent progression to end-stage degeneration. Although a number of procedures for the management of chondral lesions in other large joints (e.g. knee) have been reported, there currently remains little information available for appropriate management of these lesions in the hip [17]. All the techniques found in the systematic review are described and discussed below.

## Debridement

Debridement of a cartilage flap from a chondral injury may allow symptoms to resolve and permit a return to activity or sports [6, 18]. Arthroscopy is essential for the diagnosis of an unstable flap if pre-operative imaging is unclear, and arthroscopic debridement is often the definitive therapy. Fontana et al. [19] carried out a controlled retrospective study of 30 patients (15 ACI, 15 arthroscopic debridements) affected by a post-traumatic hip chondropathy (Outerbridge classification grades 3–4, measuring 2 cm<sup>2</sup> in area or more). The post-operative Harris Hip Scores (HHS) in the ACI group were significantly better than those in the debridement group.

## Microfracture

Microfracture involves the use of an arthroscopic awl or drill to perforate exposed subchondral bone to create multiple holes and provide an entry portal for marrow-derived cells. The rationale of the technique is to recruit mesenchymal stem cells

into the cartilage defect to create fibrocartilage. Following microfracture, a marrow clot forms and provides the ideal environment for mesenchymal stem cells to differentiate into stable repair tissue [20]. The advantages of this technique are that it is technically straightforward, can be performed arthroscopically, without donor site morbidity, and has a low cost. The disadvantage compared with other cartilage repair techniques is that it produces less type II cartilage and has different biomechanical properties than hyaline cartilage, which may raise questions of its resilience and longevity

**Table 2** Demographics of the study

Parameter	
Studies analysed	21 studies
Levels of evidence	
3b	3 studies (14.3%)
4	18 studies (85.7%)
Participants (hips)	596
Male	216 (56.1%)
Female	169 (43.9%)
Unclear	211
Range of follow-up time	6–74 months
Mean participant age (range)	37.2 (15–63) years
Surgical approach	
Arthroscopy	11 studies (52.4%)
Open	9 studies (42.9%)
Injection	1 study (4.8%)
Location of cartilage defect (participants)	
Acetabulum	534 (93.5%)
Femoral head	37 (6.5%)
Unclear	25

**Table 3** Details of 21 studies included in the systematic review. Studies are ordered by the year of publishing (new to old). Age are shown in years

Publication year	First author	Level of evidence	Mean age (range)	Number of cases	Male	Female	Acetabulum/femoral head	Follow-up period	Surgical approach	Technique used
2016	Mardones [57]	4	51.8 (39–60)	29	10	10	NA	24 months	Injection	Intra-articular BM-MSC injection
2016	Fontana [31]	4	36.4 (18–50)	201	NA	NA	201/0	5 years	Arthroscopy	AMIC
2015	Fontana [25]	3b	39.2 (18–55)	147	91	56	147/0	5 years	Arthroscopy	77 MFx, 70 AMIC
2014	Mancini [28]	3b	36.2 (19–50)	57	25	32	57/0	Up to 5 years	Arthroscopy	26 MACI, 31 AMIC
2012	Zaltz [24]	4	27 (16–31)	10	7	3	0/10	29 months	Open	3 AMIC, 7 MFx
2012	Vundelinckx [59]	4	34	1	NA	NA	0/1	6 months	Arthroscopy	Artificial plug (TruFit®)
2012	Leunig [30]	4	22.7 (15–31)	6	5	1	1/5	Minimum 1 year	Open	AMIC
2012	Krych [36]	4	22 (15–29)	2	1	1	0/2	4.3 years	Open	Osteochondral autograft transfer from the ipsilateral knee (mosaicplasty)
2012	Karthikeyan [23]	4	37 (17–54)	20	16	4	20/0	17 months	Arthroscopy	MFx
2012	Fontana [19]	3b	41.5 (20–53)	30	12	18	30/4	74 months	Arthroscopy	15 ACI, 15 debridement
2012	Emre [34]	4	22	1	1	0	0/1	3 years	Open	Osteochondral autograft transfer from the ipsilateral knee (mosaicplasty)
2011	Stafford [50]	4	34.2 (18–53)	43	25	18	43/0	28 months	Arthroscopy	Fibrin adhesive
2011	Krych [40]	4	28 (24–32)	2	1	1	2/0	Minimum 24 months	Open	Osteochondral allograft transplantation
2011	Girard [37]	4	18 (15–21)	10	7	3	0/10	29.2 months	Open	Osteochondral autograft transfer from the inferior portion of the femoral head (mosaicplasty)
2011	Field [58]	4	48.6 (31–63)	4	1	3	4/0	10 months	Arthroscopy	Artificial plug (TruFit®)
2010	Tzaveas [49]	4	36 (18–57)	19	5	14	19/0	19 months	Arthroscopy	Fibrin adhesive
2010	Nam [35]	4	18 (15–21)	2	2	0	0/2	Minimum 1 year	Open	Osteochondral autograft transfer from (1) the ipsilateral knee and (2) the inferior portion of the femoral head (mosaicplasty)
2009	Sekiya [42]	4	17	1	1	0	1/0	2 years	Arthroscopy	Direct cartilage suture repair
2008	Philippou [22]	4	37.2 (21–47)	9	5	4	9/0	20 months	Arthroscopy	MFx
2008	Ellender [27]	4	19	1	0	1	0/1	2 years	Open	ACI (following previous mosaicplasty)
2003	Hart [33]	4	28	1	1	0	0/1	6 months	Open	Osteochondral autograft transfer from the ipsilateral knee (mosaicplasty)
Publication year	Pre-operative condition	Post-operative rehabilitation protocol	Final outcome	Other comments						
2016	Symptomatic FAI and focal chondral delaminations (Outerbridge classification grades III–IV) with mild to moderate OA (Tönnis scale II–III)	Walking with 2 crutches and weight bearing as tolerated was allowed on the first post-operative day.	The median pre-operative mHHS, WOMAC and VAS scores were 64.3, 73 and 56.5, respectively, and they increased to 91, 97 and 83 at final follow-up ( $p < 0.05$ ). The VAS score also improved from a median of 6 to 2.	Four patients received a THR (13% of the hips) at the median of 9 months post-intervention (range 6–36 months); 80 mL of bone marrow was aspirated from the anterior iliac crest during hip arthroscopy. Each patient received 3 intra-articular injections of $20 \times 10^6$ BM-MSCs post-operatively (4–6 weeks).						

**Table 3** (continued)

Publication year	Pre-operative condition	Post-operative rehabilitation protocol	Final outcome	Other comments
2016	Outerbridge grade III and/or IV chondral lesions located in the superior area of the acetabulum. Acetabular chondral lesion size was between 2 and 4 cm <sup>2</sup> ; radiological Tönnis degree of osteoarthritis was ≤2. The mean defect size was 2.9 ± 0.8 cm <sup>2</sup> .	Walking was allowed with the aid of 2 crutches with partial weight bearing (30% of body weight) on the operated leg for 3 weeks.	Pre-operative mHHS had a mean score of 44.9 ± 5.9. Significant improvement, as measured by the mHHS, was observed at 6 months in comparison to pre-operative levels (80.3 ± 8.3) ( <i>p</i> < 0.001). Continuous improvement with respect to each previous evaluation time point was seen, reaching the highest improvement level at the 3-year follow-up (85.5 ± 7.2). The mean mHHS improvement recorded at the 5-year follow-up compared with pre-operative scores was 39.1 ± 5.9.	No failure resulting in hip arthroplasty was detected in any of these patients during the 5-year follow-up. No patient had a poor post-operative mHHS (> 60).
2015	Acetabular grade III and IV chondral lesions (Outerbridge classification) measuring between 2 and 8 cm <sup>2</sup> . Less than grade 2 degenerative changes radiologically according to the Tönnis classification	Non-weight bearing for 4 weeks. Partial load bearing up to 7 weeks, afterwards full.	The mean mHHS had improved significantly in both groups 6 months post-operatively (76.3 for MFx (58 to 98) and 79.5 for AMIC (68 to 96), <i>p</i> < 0.001). At this time, there were significantly better results in the AMIC group ( <i>p</i> < 0.025). Differences in outcome between the 2 groups became more apparent 1 year post-operatively, and this trend continued throughout the subsequent follow-up. The mean mHHS in the MFx group was lowest at between 4 and 5 years (72.4: 48 to 92) post-operatively. Conversely, the improvement in mHHS seen in the AMIC group was maintained throughout the 5-year assessment period. AMIC group had better and more durable improvement, particularly in patients with large (≥ 4 cm <sup>2</sup> ) lesions. The outcome was significantly better in the AMIC group for both men and women at 2, 3, 4 and 5 years, except for women 5 years post-operatively.	A total of 6 patients (7.8%) in the MFx group required THR at a mean of 3.2 years (1 to 5) post-operatively. None in the AMIC group required THR.
2014	Grade III and IV (Outerbridge classification) acetabular chondral lesions, mostly located in the superior chondral acetabulum. Patients with acetabular chondral lesion size between 2 and 4 cm <sup>2</sup> with radiological Tönnis degree < 2.	Partial weight bearing (30% of body weight) on the operated leg for 3 weeks. At 4 weeks post-op, walking with the aid of 1 crutch opposite to the recovering leg was allowed for 7 days, then normal walking thereafter.	In both the MACI and AMIC groups, significant hip score improvements were measured over baseline levels at 6 months post-op (81.2 ± 8.4 for MACI, 80.3 ± 8.3 for AMIC, both <i>p</i> < 0.001). Statistically significant differences between the groups were not observed. The mean mHHS improvement at the 5-year follow-up with respect to pre-operative level was 37.8 ± 5.9 and 39.1 ± 5.9 in patients who underwent MACI and AMIC, respectively (not significant).	No failure resulting in hip arthroplasty was detected in any of these patients during the 5-year follow-up
2012	Full-thickness parafoveal chondral lesions localised anterolateral to the fovea confirmed	Patients were limited to toe-touch weight bearing for approximately 6 weeks. After 6 weeks	The Tegner-Lysholm score at latest follow-up ranged from 5 to 9 (mean, 7.4). All patients	

**Table 3** (continued)

Publication year	Pre-operative condition	Post-operative rehabilitation protocol	Final outcome	Other comments
2012	at the time of surgical dislocation. The lesion size ranged from 96 to 513 mm <sup>2</sup> with a mean of 184 mm <sup>2</sup> .	and radiographic confirmation of trochanteric union, progressive weight bearing was encouraged.	were able to return to their pre-operative level of function with the exception of patient 6 whose contralateral hip precluded participation. There was no obvious asymmetric joint space narrowing visible on an AP pelvis view in any of the patients.	
2012	Severe osteochondral lesion with a subchondral cyst on the femoral head seen on MRI.	Restricted weight bearing during 4 weeks (walking with crutches and plantar touch).	MRI scanning at 6 months showed the TruFit plug in situ, without subsidence, whilst there still is an irregularity on the border of the articular cartilage surface. At 6 months, the right hip showed an abduction of 35°, a symmetric endorotation and exorotation of 30° and an adduction of 10°. Flexion was 95°, compared to 110° at the contralateral side.	
2012	Large (> 2 cm <sup>2</sup> ) femoral head or acetabular chondral or osteochondral lesions. All were classified as ICRS grade 3 or 4 lesions and Tönnis grade < 2.	Not mentioned	Post-operative Oxford Hip Scores ranged from 13 to 17, UCLA Activity Scores ranged from 5 to 10 and MOCART scores ranged from 55 to 75.	Two patients (33%) were lost to follow-up.
2012	2 cm × 5 to 8 mm area of osteochondral defect in patient 1 and 1 × 2 cm area of osteochondral defect in patient 2. Both defects were in the anterosuperior weight-bearing portion of the femoral head.	Patients were kept partial weight bearing for 2 months after surgery and then were gradually returned to full weight bearings.	MRI at 6 months showed complete incorporation of the osteochondral plugs into the femoral head. At 4 years follow-up, patient 1 had mHHS 96, HOS 100 and patient 2 had mHHS 100, HOS 100.	Radiographs showed heterotopic ossification post-operatively in both of the patients.
2012	Full-thickness acetabular chondral defects in the superior and anterosuperior zones of the acetabulum (average 154mm <sup>2</sup> , range 48–300 mm <sup>2</sup> )	For the first 6 weeks, only foot-flat non-weight bearing was allowed. Full weight bearing was achieved over the following 2 weeks.	The mean NAHS improved from 55 to 78. Excluding 1 patient who only had a 25% fill, 19 of the 20 patients had a mean fill of 96% (range, 75–100%) with macroscopically good quality (grade 1) repair tissue as per Blevins et al.'s classification.	
2012	Post-traumatic hip chondropathy of grade 3 or 4 according to the Outerbridge classification, measuring 2 cm <sup>2</sup> in area or more. The mean size of the defect was 2.6 cm <sup>2</sup> .	Non-weight bearing for 4 weeks. Partial load was allowed after 4 weeks in group A (ACI) and after 2 weeks in group B (debridement).	The patients who underwent ACI (group A) improved after the procedure compared with the group that underwent debridement alone (group B). The mean HHS pre-operatively was 48.3 (95% confidence interval, 45.4 to 51.2) in group A and 46 (95% CI, 42.7 to 49.3) in group B (no significant difference). The final HHS was 87.4 (95% CI, 84.3 to 90.5) in group A and 56.3 (95% CI, 54.4 to 58.7) in group B ( <i>p</i> < 0.001).	
2012	The radiographs displayed a chondral defect in the superolateral aspect of the femoral head. Pre-operative HHS was 43.	Not mentioned	mHHS improved from 43 to 96 at 24 weeks. At a 3-year follow-up, the patient was symptom-free with near complete incorporation of the graft radiographically.	The patient had past history of Perthes disease.
2011	Delaminated acetabular articular cartilage (A positive 'wave sign' at the chondrolabral	Toe-touch weight bearing with crutches is advised for 4 weeks.	mHHS for pain improved significantly from 21.8 (95% CI 19.0 to 24.7) pre-operatively to 35.8 (95% CI 32.6 to 38.9) post-operatively	There were 3 patients who required further arthroscopic interventions for persistent symptoms, created by iliopsoas irritation. At



**Table 3** (continued)

Publication year	Pre-operative condition	Post-operative rehabilitation protocol	Final outcome	Other comments
2011	junction indicated delamination of articular cartilage from the subchondral bone).  18 × 18 mm isolated defect of the superior acetabular dome in patient 1 and 12 mm diameter × 10 mm deep osteochondral defect in the weight-bearing dome of the superior acetabulum in patient 2	Eight weeks of protected weight bearing	( $p < 0.0001$ ). The MHHS for function also showed significant, although more modest, improvements from 40.0 (95% CI 37.7 to 42.3) pre-operatively to 43.6 (95% CI 41.4 to 45.8) post-operatively ( $p = 0.0006$ ). There were 3 patients who had early (within 12 months of the index procedure) revision arthroscopy for iliopsoas pathology. An MRI at 18 months in both cases demonstrated incorporation of the allograft bone into the host acetabulum. At 24 months in patient 1 and 42 months in patient 2, radiographs showed no progressive joint space narrowing compared to pre-operative radiographs. Patient 1 had improvement in mHHS from 75 pre-operatively to 97 at 2 years follow-up. mHHS improved from 79 pre-operatively to 100 at the time of 3 years follow-up in patient 2. Both patients' HOS subsets for activities of daily living and sports score were 100 points each.	each of these procedures, the previously repaired articular cartilage was seen to be in good condition.  Patient 2 had 2 previous open hip operations for fibrous dysplasia.
2011	Intra-operatively, the mean area of cartilaginous damage on the femoral head was 4.8 cm <sup>2</sup> (3–9 cm <sup>2</sup> ).	Patients were kept non-weight bearing for 6 weeks and then progressed to weight bearing as tolerated.	HHS increased from 52.8 (35–74) to 79.5 points (65–93). The Oxford Hip Score decreased indicating function improvement from 34.5 points (22–48) to 19.2 points (14–26). At latest follow-up, all autograft plugs appeared to be well incorporated on radiological examination. CT-arthrography at 6 months revealed intact cartilage over the plugs with smooth interfaces between the articulating bones in all cases.	No THR was required by the time of the last follow-up.
2011	CT confirmed the presence of solitary subchondral cysts in the weight-bearing portion of the acetabulum in all 4 patients. Patient 1 was also found to have subchondral cysts on the opposing surface of the femoral head and a labral tear.	Patients were mobilised 50% weight bearing with crutches for the first 6 weeks. This was gradually increased to full weight bearing by 8 weeks.	The mean NAHS improved from 53.8 (range 43.8 to 70) pre-operatively, to 66.9 (SD 18.5, range 53.8 to 80) at the 6-week time point and 84.6 (SD 5.1, range 78.8 to 87.5) at 6 months. Computed tomography and magnetic resonance imaging at 6 months confirmed the stability of the osteochondral plugs and on-going healing. None of the patients have developed collapse of the femoral head or avascular necrosis.	Mean BMI was 27.4. A bone tunnel was prepared from the region of the iliac crest to the acetabular articular surface. A synthetic osteochondral plug was inserted in an antegrade fashion and positioned flush with the lunare articular cartilage. Two patients had undergone previous hip arthroscopy.
2010	Acetabular articular cartilage delamination or debonding, identified as macroscopically sound cartilage, but with loss of fixation to the subchondral bone and a 'carpet phenomenon' or positive 'wave' sign. Acetabular cartilage	Patients were instructed to touch weight bear for the first 4 weeks.	There were 5 patients who required a secondary intervention because of persistent pain or disability; 1 received a steroid and local anaesthetic injection to the affected hip; 2 required revision hip arthroscopy because of	

**Table 3** (continued)

Publication year	Pre-operative condition	Post-operative rehabilitation protocol	Final outcome	Other comments
	delamination was found adjacent to the anterior labrum in 16 patients and to the anterosuperior area in 3.			
2010	(1) The full-thickness cartilage defect in the anterior-superior weight-bearing zone of the femoral head that measured approximately 2 cm in length and was tapered down from approximately 8 to 5 mm in width. (2) A large osteochondral fracture was appreciated measuring approximately 3 × 3 cm, which had been displaced distally and superiorly. There was also a full-thickness cartilaginous injury at the apex of the fracture, in the anterior-superior weight-bearing zone of the femoral head. This zone of injury was approximately 10 mm in size.	Post-operatively, the patients were kept non-weight bearing for 6 weeks and then progressed to weight bearing as tolerated.	<p>persistent pain, the first as a result of iliopsoas tendinitis and the second for residual femoroacetabular and pectineofoveal impingement, which was both excised. One patient received a resurfacing arthroplasty because of rapidly destructive osteoarthritis and another is scheduled to undergo revision arthroscopy in due course for persisting discomfort. For those patients who underwent revision arthroscopy or subsequent arthrotomy, the area of chondral repair appeared macroscopically intact and secure. Mean mHHS scores improved pre-operatively to 1 year post-operatively from 15.7 to 28.9 for pain and 37.2 to 44.1 for function.</p> <p>(1) An MRI performed at 24 weeks post-operatively demonstrated well-incorporated autograft plugs and intact cartilage over the plugs with smooth interfaces with the remaining bone. At 1 year follow-up, the patient has no complaints of pain, good mechanics with ambulation and has returned to running and physical activity without difficulty. (2) Radiographs and an MRI performed at 1 year post-operatively demonstrated a well-incorporated autograft plug with minimal fibrillation and no evidence of osteonecrosis. At over 5 years of follow-up, the patient continues to have no complaints of pain and has returned to his baseline physical activities without difficulty.</p>	
2009	Peripheral acetabular articular cartilage delamination with chondral labral separation. This intact 1-cm delaminated articular cartilage flap (Outerbridge grade 0) was partially off the subchondral bone.	Patient was allowed 30% weight bearing with crutches for 6 weeks, gradually progressing to 100% over the following 2 weeks.	The patient reported being pain-free 90% of the time with pain 2/10 at worst. He scored 96 on mHHS, 93 on HOS Activities of Daily Living subscale and 81 on HOS Sports subscale.	
2008	The average acetabular chondral lesion size was 163 mm <sup>2</sup> . All lesions were located in the superior acetabular quadrant.	Weight bearing was restricted to toe-touch for 8 weeks.	The average percent fill of the acetabular chondral lesions at second look was 91% (range, 25 to 100%). Eight of the 9 patients had grade 1 or 2 repair product at second look (grade 1 was normal-appearing articular cartilage, difficult to discern borders of lesion and normal surrounding cartilage; grade 2 was mild fibrillation, discoloured, softer-than-normal cartilage; grade 3 was deep fissures or cobblestone surface, no exposed	

**Table 3** (continued)

Publication year	Pre-operative condition	Post-operative rehabilitation protocol	Final outcome	Other comments
2008	MR arthrogram revealed full-thickness loss of the surrounding articular cartilage on the major weight-bearing portion of the femoral head. Intra-operative measurement of the chondral defect measured 4.0 cm by 2.5 cm around intact osteochondral plugs.	Progressive weight-bearing activity can begin as early as 6 weeks but is usually delayed until 8 to 12 weeks.	bone; and grade 4 was full-thickness cartilage loss with exposed subchondral bone). One patient who had diffuse osteoarthritis failed, with only 25% coverage with a grade 4 appearance of the repair product 10 months after index arthroscopy and required total hip arthroplasty 66 months after the index microfracture.	The patient had progression of disease after prior autologous osteochondral mosaicplasty. Fixation of the membrane was performed with the use of 6.0 Vicryl suture. Fibrin glue was used to further seal the membrane.
2003	The diameter of the round defect was 14 mm, and its depth was 16 mm.	Partial weight bearing was permitted at 6 weeks and full weight bearing at 10 weeks after the surgery.	HHS improved from 69 to 100 points. At 6 months post-operatively, the patient showed the full range of painless motion with no further complaints of rest pain or pain related to activities.	The defect was caused by penetrated resorbable screw used in the past surgical fixation of a displaced large single fragment of the posterior acetabular rim.

*FAI* femoroacetabular impingement, *MFx* microfracture, *BM-MSCs* bone marrow mesenchymal stem cells, *ACI* autologous chondrocyte implantation, *MACI* matrix-associated chondrocyte implantation, *AMIC* autologous matrix-induced chondrogenesis, *(m) HHS* (modified) Harris Hip Score, *VAS* visual analogue scale, *MOCART* magnetic resonance observation of cartilage repair tissue, *HOS* Hip Outcome Score, *NAHS* Non-Arthritic Hip Score, *BMI* body mass index, *THR* total hip replacement

[20]. Also, the concentration of mesenchymal cells in the bone marrow is relatively low and their chondrogenic potential declines with age [21]. Philippon et al. [22] reported the outcome of microfracture in nine patients with a full-thickness chondral defect of the acetabulum. The average percent fill of the acetabular chondral lesions at second-look arthroscopy was 91%, and eight of the nine patients had grade 1/2 repair product at second look. Karthikeyan et al. [23] described the outcome of 20 patients who underwent arthroscopic surgery for FAI with a localised full-thickness acetabular chondral defect which were treated by microfracture. At an average follow-up of 17 months, 19 of the 20 patients had a mean fill of 96% with macroscopically good quality repair tissue. Zaltz and Leunig [24] reviewed ten patients with symptomatic FAI diagnosed with parafoveal chondral defects confirmed at the time of surgical dislocation. Seven of the ten patients were treated by microfracture (other 3 were treated by AMIC), and all the patients were able to return to their pre-operative level of function with the exception of one patient who had a problem in the contralateral hip. At the last follow-up, there was no obvious asymmetric joint space narrowing visible on an AP pelvis view in any of the patients. Fontana et al. [25] compared the outcome of 77 patients who had a microfracture and 70 patient who had AMIC for cartilage injuries in the hip. Although the outcome in both groups significantly improved at six months and one year post-operatively, the outcome in the microfracture group slowly deteriorated four years after surgery, whilst that in the AMIC group remained stable.

### Autologous chondrocyte implantation

ACI includes the harvest of chondrocytes with growth and expansion at an off-site facility, followed by reimplantation of the cells into the affected area. ACI is indicated for symptomatic, well-contained defects that are between 2 and 10 cm<sup>2</sup> and with less than 6–8 mm of bone loss [26]. Most surgeons who perform ACI regularly are now using a synthetic collagen membrane to cover the implanted chondrocytes [19, 27]. Ellender and Minas [27] presented a clinical case and described ACI for a femoral head chondral defect of 10 cm<sup>2</sup> in a 19-year-old female college student who had progression of disease after prior mosaicplasty. Two years after ACI, she remained free of pain. Her post-operative contrast-enhanced MRI demonstrated repair tissue fill and radiographs showed a normal joint space without any sign of change.

### Matrix-associated chondrocyte implantation

MACI is a second-generation ACI technique that utilises absorbable scaffolds to support the implanted chondrocytes during healing. Theoretically, it should restore hyaline cartilage at the defect. Unfortunately, same as ACI, it is a two-stage procedure where chondrocytes are harvested from the patient,

cultured and then returned to the patient via open surgical dislocation of the hip which is a technically demanding surgical approach. Mancini and Fontana [28] assessed and compared the clinical outcomes of arthroscopic MACI and AMIC for the treatment of acetabular chondral defects between 2 and 4 cm<sup>2</sup> consequent to FAI. In both groups, significant improvement in modified HHS (mHHS) was measured over baseline levels at six months post-operation. It continued to improve up to three years post-operation and remained stable until five years follow-up. There was no statistically significant difference between the two groups.

### Autologous matrix-induced chondrogenesis

AMIC is a novel single-step procedure in which the microfracture technique has been enhanced by the use of a collagen matrix. The Chondro-Gide matrix is placed in the defect and a porcine collagen I/III matrix is sewn over the lesion to stabilise the fragile blood clot that arises from the microfracture to provide a stable infrastructure for the formation of repair tissue [29]. No cells have to be harvested, cultured and re-implanted in AMIC. Therefore, there is no harvest site morbidity, and the operation can be performed as a single procedure. Moreover, AMIC does not require complex cell expansion techniques. Other than comparative studies with microfracture [24, 25] or MACI [28] described above, Leunig et al. [30] reported six patients with AMIC using surgical dislocation of the hip. No complications occurred, and good post-operative outcome scores were reported. Fontana [31] treated 201 patients with AMIC arthroscopically for Outerbridge grade III/IV chondral lesions of the acetabulum. Modified HHS improved significantly at six months post-operatively in comparison with pre-operative levels, reaching the highest level of improvement at the three year follow-up.

### Osteochondral autograft transplantation (mosaicplasty)

Mosaicplasty involves transplanting healthy, mature cartilage from a non-weight-bearing part of the hip or knee to an articular defect. The transplanted cartilage integrates with the adjacent host cartilage via fibrocartilage [32]. The inferior aspect of the femoral head, the femoral head-neck junction and the periphery of the femoral trochlea of the knee can be the potential donor sites. Mosaicplasty offers many potential advantages, including the ability to transfer new mature hyaline cartilage into the defect in a single-stage procedure and the absence of potential disease transmission, which can occur in allograft transplantation. On the contrary, owing to the autologous nature of this technique, it is limited by donor site morbidity, graft availability and the potential for dead space between the grafts [32]. Hart et al. [33] first reported the case of an osteochondral defect of the femoral head and subsequent

treatment using mosaicplasty with open surgical dislocation of the hip. At six months following surgery, the patient had a full range of painless movement of the hip with no further complaints of pain related to activities. Emre et al. [34] also presented a case where the defect of the femoral head was treated with surgical dislocation of the hip and mosaicplasty. The patient was symptom-free with nearly complete incorporation of the graft radiologically at three years after the operation. Nam et al. [35] reported two cases of a chondral defect on the femoral head after a traumatic hip dislocation, treated with mosaicplasty from the ipsilateral knee, and the inferior femoral head, respectively. At 1 and five years of follow-up, MRI showed good autograft incorporation with the maintenance of articular surface conformity. Krych et al. [36] reported two cases of post-traumatic osteochondral defects of the femoral head. Both the patients were treated with mosaicplasty from the ipsilateral knee to the femoral head, with successful clinical and radiological results at a mean follow-up of 4.3 years. Girard et al. [37] treated 10 patients for femoral cartilage defects by mosaicplasty of the femoral head through a trochanteric flip osteotomy with surgical dislocation of the hip. At the mean follow-up of 29.2 months, clinical score and range of motion improved significantly. All radiological investigations at the latest follow-up showed that the grafts were well-incorporated at the site of mosaicplasty with intact cartilage over them and smooth interfaces between articulating bony surfaces.

### Osteochondral allograft transplantation

Mosaicplasty has been shown to be a useful procedure, but there can be donor site morbidity and there is a limit to the size of the treatable defect. Allograft transplantation can also be a successful solution for the treatment of cartilage defects. It offers not only the potential advantages of transferring immediate functional hyaline cartilage but also the ability to resurface a large area without associated donor site morbidity. Potential allograft donor sources for defects within the acetabular side of the hip were a cadaveric acetabulum or medial tibial plateau. Cartilage is relatively immunoprivileged and avascular; thus, the host immune reaction is considered to be limited [38]. Allograft bone becomes necrotic and is reabsorbed via creeping substitution during the healing process. This provides a scaffold and supports the articular surface as part of gradual incorporation [39]. In the systematic review, Krych et al. [40] reported their experience in two patients who underwent osteochondral allograft transplantation for the acetabular cartilage defects. MRI at 18 months in both cases demonstrated incorporation of the graft into the host acetabulum. Hip Outcome Scores (HOS) were 100 points each in both patients two years post-operatively.

### Direct cartilage suture repair

Delamination is a full-thickness cartilage separation from the underlying subchondral bone, which forms an unstable flap at risk for complete detachment [41]. Our review found a case report that presented direct cartilage repair as a possible technique to treat large delaminated full-thickness acetabular cartilage repairs. Sekiya et al. [42] described a case of a 17-year-old boy presented with bilateral hip pain because of bilateral CAM-type FAI and a 1-cm delaminated unstable cartilage flap in the anterior-superior acetabulum. Arthroscopic microfracture underneath the flap of anterior-superior acetabular cartilage and an absorbable monofilament suture repair of the cartilage was conducted. At two years post-operatively, the patient reported 95% of normal function for both hips. Overall, the patient was satisfied with the outcome including a score of 96 on the mHHS, 93 on the HOS Activities of Daily Living subscale and 81 on the HOS Sports subscale at the final follow-up.

### Fibrin adhesive

The earliest stage in the formation of an articular cartilage flap is delamination of the overlying articular cartilage from the underlying subchondral bone [43]. Particularly, if the articular cartilage itself may contain a significant number of viable chondrocytes, debriding such an area of chondral instability seems an unnecessary surgical procedure. Fibrin adhesive is a biological substance, which has already been used in general surgery, ophthalmology, neurosurgery, otolaryngology and orthopaedics, thanks to its adhesive properties [44–48]. This procedure involved creating an incision at the periphery of the acetabular labrum and passing an awl underneath to create microfracture. Fibrin glue was inserted between subchondral bone and delaminated cartilage, and the cartilage was pressed down until the adhesive had set. Tzaveas and Villar [49] analysed the efficacy of using fibrin adhesive for arthroscopic repair of chondral delamination lesions with intact gross cartilage structure in 19 patients. Mean mHHS was improved significantly after surgery, and in all five patients who underwent revision arthroscopy at a later date, the chondral repair appeared intact. Stafford et al. [50] reported the results of 43 patients with FAI who have undergone fibrin adhesive technique for re-attachment of delaminated chondral flaps. Both mHHS for pain and function improved significantly after the operation. In three patients who required further arthroscopic interventions for persistent symptoms created by iliopsoas irritation, the previously repaired articular cartilage was found in a good condition.

### Intra-articular BM-MSC injection

Adult MSCs were originally believed to only differentiate into tissue-specific cells. However, these cells were recently proven to have the ability to differentiate into a different tissue in response

to specific signals released by the site of injury, including cartilage injury [51, 52]. Adding to animal studies, several authors reported on intra-articular injection of MSCs into the knee for the treatment of cartilage defects and showed good results with regard to pain and clinical outcomes [53–56]. Injected MSCs were incorporated into the articular cartilage of the injected joint. They integrate into the surface of the cartilage and also the interior of the cartilage [52]. Mardones et al. [57] first reported the outcome of intra-articular BM-MSC injection for the cartilage injury in the hip. Three intra-articular injections of  $20 \times 10^6$  BM-MSCs were conducted from four to six weeks post-operatively in 29 hips that received hip arthroscopy for FAI and focal cartilage injuries. Clinical outcome scores and VAS improved significantly after surgery, and no major complications had been reported at the time of the last follow-up.

### Artificial plug

The systematic review found two articles that used an artificial plug, and both of them utilise the TruFit cartilage/bone (CB) plug (Smith & Nephew). It is a resorbable polymer scaffold that can be inserted into osteochondral defects, which acts as a scaffold that provides structural support. Also, native marrow elements can migrate into the plug to promote bone in-growth as well as articular cartilage regeneration. Field et al. [58] described the use of TruFit for the treatment of acetabular cystic cartilage lesions in four patients. Patients underwent hip arthroscopy followed by the antegrade insertion of a plug through the ilium until the surface of the plug coincided with the articular surface. At ten months follow-up, patients reported increased function and improvement in Non-Arthritic Hip Score (NAHS). CT and MRI showed incorporation and continued healing of the plug six months post-operatively. Vundelinckx et al. [59] reported a case of a 34-year-old employee (gender was not described) who underwent TruFit for an osteochondral injury of the femoral head. MRI at six months showed the TruFit was placed in situ whilst there was an irregularity on the border of the articular cartilage surface. They mentioned it was very difficult to interpret early MRI images of ingrowth of TruFit plugs, as described by authors of past radiographic studies [60].

Of the 21 studies found in the systematic review, only 3 studies are level IIIb (retrospective comparative study) and the rest were level IV (case series/report). Two studies described superiority of one cartilage repair method over another [19, 25], and one study showed there was no difference in clinical outcome between two methods [28]. Fontana's study [19] was limited by the reduced number of patients and the lack of an objective method for the evaluation of the results. Other limitations are the criteria for patient inclusion and selection bias in the randomisation process. Fontana's study [25] and Mancini's study [28] were also limited by the lack of randomisation, and clinical outcomes were only assessed using the mHHS.

The strengths of this systematic review include the pursuit of knowledge in an important novel area of investigation and a rigorous methodological approach. Regarding the methodological approach, a broad-based and comprehensive literature search of multiple databases with multiple reviewers allowed for a very inclusive approach to capture the vast majority of existing literature. Nonetheless, there are limitations which include the inclusion of English only studies and the overall low level of evidence available in the included studies on this topic (mostly level IIIb and IV studies). Retrospective designs are prone to data inaccuracy as well as missing information, which subject them to selection and detection bias. Without a doubt, this diminishes the accuracy of the data collected and, therefore, limits the quality of a systematic review, whilst this current level of evidence reflects the novel and emerging nature of cartilage repair strategies in the hip joint. Additionally, our results include a wide spectrum of pathologies and methods of treatment, which also made drawing conclusions and giving specific guidelines difficult. Furthermore, pre-operative condition and post-operative rehabilitation protocol were different in each study, which made comparison among studies difficult as well. Future studies should address comparative effectiveness of the various treatment options, and long-term registry-based studies that report patient reported outcomes and radiographic outcomes will help inform treatment decisions.

### Conclusion

Although there are many different cartilage restoration techniques available, current best evidence does not support any one surgical technique as a superior method for treating cartilage injuries in the hip. Unfortunately there remains a paucity of randomised trials with long-term follow-up, which makes it difficult to perform a meaningful assessment of the outcome of each procedure. Of the 21 studies found in the systematic review, AMIC, mosaicplasty and microfracture were relatively well-reported, though they were only described in very limited case series. Also, only two studies described superiority of one cartilage repair method over another—one showed superiority of AMIC over microfracture [25] and another showed superiority of ACI over debridement [19], and one study showed that there was no statistically significant difference between MACI and AMIC in terms of post-operative mHHS [28]. To make any specific recommendations for orthopaedic surgeons with regards to treatment decisions, adequately powered long-term large-scale high-quality randomised-control trials focusing on two or three specific methods of treatment need to be conducted in the future.

**Contribution of authors** VK takes responsibility for the integrity of the work as a whole, from inception to the finished manuscript. NN, CG, AD, OA and VK were responsible for the conception and design; NN, CG and VK for the collection,

assembly, analysis and interpretation of data; NN, OA and VK for drafting; and NN, CG, AD, OA and VK for the final approval of the manuscript and for the critical revision for important intellectual contents.

## Compliance with ethical standards

**Conflict of interest** The authors declare that they have no conflict of interest.

**Ethical approval** This article does not contain any studies with human participants.

## Appendix

### Search strategy

Two reviewers (NN and CG) searched the online databases (PubMed (Medline), EMBASE, Google Scholar, BNI, CINAHL and AMED) for literature describing the outcome of cartilage repair techniques for the chondral injury in the hip. The Preferred Reporting Items for Systematic Reviews and Meta-Analyses (PRISMA) guidelines were used for designing this study. Database search was conducted on 1st March 2017 and retrieved articles from database inception to the search date. The research question and individual study eligibility criteria were established a priori. We used medical subject headings including the following key search terms: hip, cartilage, chondral, repair, regeneration, restoration, refixation, implantation, chondroplasty and chondrogenic. Terms were connected by the Boolean operators 'AND' and 'OR'. Levels I, II, III, IV and V evidence (according to the Oxford Centre for Evidence-Based Medicine) English-language studies were eligible for inclusion in the systematic review. The search also included the *yet to be printed* search results. Results were pooled, and duplicate searches were excluded by having two reviewers (NN and CG) independently review all the titles and abstracts. Both of the reviewers had been trained in a field of clinical research and had enough experience at the stage of abstract screening and manuscript review. Any discrepancies at the title and abstract stage were resolved by automatic inclusion to ensure thoroughness. The remaining search results were divided equally between two reviewers (NN and CG) and reviewed in duplicate applying the inclusion and exclusion criteria. Any discrepancies at the full-text stage were resolved by consensus between the two reviewers. If a consensus could not be reached, a third more senior reviewer (VK) was consulted to resolve the discrepancy. Also, for quality control, VK reviewed a 25% random sample of excluded studies and all included title and abstracts.

**Open Access** This article is distributed under the terms of the Creative Commons Attribution 4.0 International License (<http://creativecommons.org/licenses/by/4.0/>), which permits unrestricted use, distribution, and reproduction in any medium, provided you give appropriate credit to the original author(s) and the source, provide a link to the Creative Commons license, and indicate if changes were made.

## References

1. Crawford K, Philippon MJ, Sekiya JK, Rodkey WG, Steadman JR (2006) Microfracture of the hip in athletes. *Clin Sports Med* 25: 327–335
2. Yen YM, Kocher MS (2010) Chondral lesions of the hip: microfracture and chondroplasty. *Sports Med Arthrosc Rev* 18: 83–89
3. Beaulieu PE, Bleeker H, Singh A, Dobransky J (2017) Defining modes of failure after joint-preserving surgery of the hip. *Bone Joint J* 99-B:303–309
4. Fayad TE, Khan MA, Haddad FS (2013) Femoroacetabular impingement: an arthroscopic solution. *Bone Joint J* 95-B:26–30
5. Leunig M, Ganz R (2014) The evolution and concepts of joint-preserving surgery of the hip. *Bone Joint J* 96-B:5–18
6. Bedi A, Kelly BT, Khanduja V (2013) Arthroscopic hip preservation surgery: current concepts and perspective. *Bone Joint J* 95-B: 10–19
7. Imam S, Khanduja V (2011) Current concepts in the diagnosis and management of femoroacetabular impingement. *Int Orthop* 35: 1427–1435
8. Khanduja V, Villar RN (2006) Arthroscopic surgery of the hip: current concepts and recent advances. *J Bone Joint Surg Br* 88: 1557–1566
9. Khanduja V, Villar RN (2007) The arthroscopic management of femoroacetabular impingement. *Knee Surg Sports Traumatol Arthrosc* 15:1035–1040
10. Anderson LA, Peters CL, Park BB, Stoddard GJ, Erickson JA, Crim JR (2009) Acetabular cartilage delamination in femoroacetabular impingement. Risk factors and magnetic resonance imaging diagnosis. *J Bone Joint Surg Am* 91:305–313
11. Bedi A, Lynch EB, Sibilsky Enselman ER, Davis ME, Dewolf PD, Makki TA, Kelly BT, Larson CM, Henning PT, Mendias CL (2013) Elevation in circulating biomarkers of cartilage damage and inflammation in athletes with femoroacetabular impingement. *Am J Sports Med* 41:2585–2590
12. Johnston TL, Schenker ML, Briggs KK, Philippon MJ (2008) Relationship between offset angle alpha and hip chondral injury in femoroacetabular impingement. *Arthroscopy* 24:669–675
13. Ellis HB, Briggs KK, Philippon MJ (2011) Innovation in hip arthroscopy: is hip arthritis preventable in the athlete? *Br J Sports Med* 45:253–258
14. Nepple JJ, Carlisle JC, Nunley RM, Clohisy JC (2011) Clinical and radiographic predictors of intra-articular hip disease in arthroscopy. *Am J Sports Med* 39:296–303
15. Beck M, Kalhor M, Leunig M, Ganz R (2005) Hip morphology influences the pattern of damage to the acetabular cartilage: femoroacetabular impingement as a cause of early osteoarthritis of the hip. *J Bone Joint Surg Br* 87:1012–1018
16. Ganz R, Parvizi J, Beck M, Leunig M, Notzli H, Siebenrock KA (2003) Femoroacetabular impingement: a cause for osteoarthritis of the hip. *Clin Orthop Relat Res* 417:112–120
17. McCulloch PC, Kang RW, Sobhy MH, Hayden JK, Cole BJ (2007) Prospective evaluation of prolonged fresh osteochondral allograft transplantation of the femoral condyle: minimum 2-year follow-up. *Am J Sports Med* 35:411–420
18. Byrd JW (2001) Lateral impact injury. A source of occult hip pathology. *Clin Sports Med* 20:801–815
19. Fontana A, Bistolfi A, Crova M, Rosso F, Massazza G (2012) Arthroscopic treatment of hip chondral defects: autologous chondrocyte transplantation versus simple debridement—a pilot study. *Arthroscopy* 28:322–329
20. Frisbie DD, Oxford JT, Southwood L, Trotter GW, Rodkey WG, Steadman JR, Goodnight JL, McIlwraith CW (2003) Early events

- in cartilage repair after subchondral bone microfracture. *Clin Orthop Relat Res* 407:215–227
21. Payne KA, Didiano DM, Chu CR (2010) Donor sex and age influence the chondrogenic potential of human femoral bone marrow stem cells. *Osteoarthr Cartil* 18:705–713
  22. Philippon MJ, Schenker ML, Briggs KK, Maxwell RB (2008) Can microfracture produce repair tissue in acetabular chondral defects? *Arthroscopy* 24:46–50
  23. Karthikeyan S, Roberts S, Griffin D (2012) Microfracture for acetabular chondral defects in patients with femoroacetabular impingement: results at second-look arthroscopic surgery. *Am J Sports Med* 40:2725–2730
  24. Zaltz I, Leunig M (2012) Parafoveal chondral defects associated with femoroacetabular impingement. *Clin Orthop Relat Res* 470:3383–3389
  25. Fontana A, de Girolamo L (2015) Sustained five-year benefit of autologous matrix-induced chondrogenesis for femoral acetabular impingement-induced chondral lesions compared with microfracture treatment. *Bone Joint J* 97-B:628–635
  26. Pestka JM, Bode G, Salzmann G, Sudkamp NP, Niemeyer P (2012) Clinical outcome of autologous chondrocyte implantation for failed microfracture treatment of full-thickness cartilage defects of the knee joint. *Am J Sports Med* 40:325–331
  27. Ellender P, Minas T (2008) Autologous chondrocyte implantation in the hip: case report and technique. *Oper Tech Sports Med* 16:201–206
  28. Mancini D, Fontana A (2014) Five-year results of arthroscopic techniques for the treatment of acetabular chondral lesions in femoroacetabular impingement. *Int Orthop* 38:2057–2064
  29. Erggelet C, Endres M, Neumann K, Morawietz L, Ringe J, Haberstroh K, Sittinger M, Kaps C (2009) Formation of cartilage repair tissue in articular cartilage defects pretreated with microfracture and covered with cell-free polymer-based implants. *J Orthop Res* 27:1353–1360
  30. Leunig M, Tibor LM, Naal FD, Ganz R, Steinwachs MR (2012) Surgical technique: second-generation bone marrow stimulation via surgical dislocation to treat hip cartilage lesions. *Clin Orthop Relat Res* 470:3421–3431
  31. Fontana A (2016) Autologous membrane induced chondrogenesis (AMIC) for the treatment of acetabular chondral defect. *Muscles Ligaments Tendons J* 6:367–371
  32. Lane JG, Healey RM, Chen AC, Sah RL, Amiel D (2010) Can osteochondral grafting be augmented with microfracture in an extended-size lesion of articular cartilage? *Am J Sports Med* 38:1316–1323
  33. Hart R, Janecek M, Visna P, Bucek P, Kocis J (2003) Mosaicplasty for the treatment of femoral head defect after incorrect resorbable screw insertion. *Arthroscopy* 19:E1-5
  34. Emre TY, Cift H, Seyhan B, Ceyhan E, Uzun M (2012) Mosaicplasty for the treatment of the osteochondral lesion in the femoral head. *Bull NYU Hosp Jt Dis* 70:288–290
  35. Nam D, Shindle MK, Buly RL, Kelly BT, Lorich DG (2010) Traumatic osteochondral injury of the femoral head treated by mosaicplasty: a report of two cases. *HSS J* 6:228–234
  36. Krych AJ, Lorich DG, Kelly BT (2012) Osteochondral autograft transfer for a posttraumatic osteochondral defect of the femoral head. *Am J Orthop (Belle Mead NJ)* 41:472–476
  37. Girard J, Roumazielle T, Sakr M, Migaud H (2011) Osteochondral mosaicplasty of the femoral head. *Hip Int* 21:542–548
  38. Bugbee WD, Convery FR (1999) Osteochondral allograft transplantation. *Clin Sports Med* 18:67–75
  39. Williams SK, Amiel D, Ball ST, Allen RT, Tontz WL Jr, Emmerson BC, Badlani NM, Emery SC, Haghighi P, Bugbee WD (2007) Analysis of cartilage tissue on a cellular level in fresh osteochondral allograft retrievals. *Am J Sports Med* 35:2022–2032
  40. Krych AJ, Lorich DG, Kelly BT (2011) Treatment of focal osteochondral defects of the acetabulum with osteochondral allograft transplantation. *Orthopedics* 34:e307–e311
  41. Beaulé PE, Zaragoza EJ (2003) Surgical images: musculoskeletal acetabular cartilage delamination demonstrated by magnetic resonance arthrography: inverted “Oreo” cookie sign. *Can J Surg* 46:463–464
  42. Sekiya JK, Martin RL, Lesniak BP (2009) Arthroscopic repair of delaminated acetabular articular cartilage in femoroacetabular impingement. *Orthopedics* 32(9)
  43. Beck M, Leunig M, Parvizi J, Boutier V, Wyss D, Ganz R (2004) Anterior femoroacetabular impingement: part II. Midterm results of surgical treatment. *Clin Orthop Relat Res* 418:67–73
  44. Kennedy JG, Saunders RL (1984) Use of cryoprecipitate coagulum to control tumor-bed bleeding. Case report *J Neurosurg* 60:1099–1101
  45. Lagoutte FM, Gauthier L, Comte PR (1989) A fibrin sealant for perforated and preperforated corneal ulcers. *Br J Ophthalmol* 73:757–761
  46. Matthew TL, Spotnitz WD, Kron IL, Daniel TM, Tribble CG, Nolan SP (1990) Four years’ experience with fibrin sealant in thoracic and cardiovascular surgery. *Ann Thorac Surg* 50:40–44
  47. Shah MA, Ebert AM, Sanders WE (2002) Fibrin glue fixation of a digital osteochondral fracture: case report and review of the literature. *J Hand Surg Am* 27:464–469
  48. Silberstein LE, Williams LJ, Hughlett MA, Magee DA, Weisman RA (1988) An autologous fibrinogen-based adhesive for use in otologic surgery. *Transfusion* 28:319–321
  49. Tzaveas AP, Villar RN (2010) Arthroscopic repair of acetabular chondral delamination with fibrin adhesive. *Hip Int* 20:115–119
  50. Stafford GH, Bunn JR, Villar RN (2011) Arthroscopic repair of delaminated acetabular articular cartilage using fibrin adhesive. Results at one to three years. *Hip Int* 21:744–750
  51. Chen A, Siow B, Blamire AM, Lako M, Clowry GJ (2010) Transplantation of magnetically labeled mesenchymal stem cells in a model of perinatal brain injury. *Stem Cell Res* 5:255–266
  52. Mokbel AN, El Tookhy OS, Shamaa AA, Rashed LA, Sabry D, El Sayed AM (2011) Homing and reparative effect of intra-articular injection of autologous mesenchymal stem cells in osteoarthritic animal model. *BMC Musculoskelet Disord* 12:259
  53. Bornes TD, Adesida AB, Jomha NM (2014) Mesenchymal stem cells in the treatment of traumatic articular cartilage defects: a comprehensive review. *Arthritis Res Ther* 16:432
  54. Davatchi F, Abdollahi BS, Mohyeddin M, Shahram F, Nikbin B (2011) Mesenchymal stem cell therapy for knee osteoarthritis. Preliminary report of four patients. *Int J Rheum Dis* 14:211–215
  55. Emadedin M, Aghdami N, Taghiyar L, Fazeli R, Moghadasali R, Jahangir S, Farjad R, Baghaban Eslaminejad M (2012) Intra-articular injection of autologous mesenchymal stem cells in six patients with knee osteoarthritis. *Arch Iran Med* 15:422–428
  56. Lee KB, Hui JH, Song IC, Ardany L, Lee EH (2007) Injectable mesenchymal stem cell therapy for large cartilage defects—a porcine model. *Stem Cells* 25:2964–2971
  57. Mardones R, Via AG, Jofre C, Minguel J, Rodriguez C, Tomic A, Salineros M (2016) Cell therapy for cartilage defects of the hip. *Muscles Ligaments Tendons J* 6:361–366
  58. Field RE, Rajakulendran K, Strambi F (2011) Arthroscopic grafting of chondral defects and subchondral cysts of the acetabulum. *Hip Int* 21:479–486
  59. Vundelinckx B, De Mulder K, De Schepper J (2012) Osteochondral defect in femoral head: Trufit implantation under fluoroscopic and arthroscopic control. *Acta Orthop Belg* 78:796–799
  60. Shindle MK, Foo LF, Kelly BT, Khanna AJ, Domb BG, Farber A, Wanich T, Potter HG (2006) Magnetic resonance imaging of cartilage in the athlete: current techniques and spectrum of disease. *J Bone Joint Surg Am* 88(Suppl 4):27–46