



Antifertility effects of *Solanum xanthocarpum* seeds on female albino rats

S.P. Singh and Shiv Pratap Singh*

Reproductive Biology Cell, Department of Zoology, D.B.S. (P.G.) College, Dehradun - 248001 (Uttarakhand), INDIA

*Corresponding author. E-mail: drshivpalsingh49@yahoo.com

Received: February 26, 2013; Revised received: March 29, 2013; Accepted: April 19, 2013

Abstract: The effect of *Solanum xanthocarpum* seed powder as aqueous suspension on genital organs and fertility of female albino rats was studied at doses of 50, 100 & 150 mg/kg/day for 30 days. The genital organ weight of albino rats was reduced significantly ($P < 0.05$) after the treatment at 100 and 150 mg/kg doses of seed powder of *S. xanthocarpum* for 30 days. The higher doses caused histopathological changes in the ovary and uterus leading to 100% control of fertility as no implants were recorded in treated female rats on the day 10th of pregnancy.

Keywords: Contraception, Fertility control, Genital organs, Herbal drugs, *Solanum xanthocarpum*

INTRODUCTION

Global search on antifertility agents is going on to tackle the problem of "Population Explosion". Many hormonal preparations are available for the purpose but they are not free from side effects. Hence, the search for suitable product from indigenous medicinal plants is proposed, which could be effectively used in place of "Pill".

Indian medicinal plants associated with antifertility property are numerous. They are enlisted under the possible antifertility plants (Chaudhury, 1966 and Farnsworth *et al.*, 1975; Aswal *et al.*, 1984; Sharma *et al.*, 2003; Pokharkar *et al.*, 2010; Jain and Bharathi, 2011). *Solanum xanthocarpum* Linn. (Family Solanaceae) is one of them. This plant is known as Kateli or Kantkari. The seeds of this plant are considered as a local contraceptive by tribals of India. The powdered seeds and steroidal fraction, Solasodine (Dixit & Gupta, 1982) of this plant was reported to interfere with spermatogenesis of Indian dog (*C. familiaris*). Rao (1986, 88) reported antifertility effects in male albino rats. Antifertility study of this plant in female albino rat is lacking. On the basis of above information, the experimental work was done to find out the antifertility effects of seeds of *Solanum xanthocarpum* on female albino rats (*Rattus norvegicus*).

MATERIALS AND METHODS

The fresh, air dried, powdered seeds filtered through muslin cloth were used at 50, 100 and 150 mg/kg doses. Each dose along with 05 mg. gum acacia powder was suspended in distilled water. The volume was adjusted in such way that 01 ml. of suspension corresponded to each dose.

Adult, cyclic female albino rats (150 - 180 g.) were divided into 08 groups each with 05 animals. They were maintained

under uniform laboratory conditions with free access of food (Hindustan Lever) and tap water. The seed powder as aqueous solution was administered orally by an intragastric catheter. The I and II groups served as control in which 01 ml. of gum acacia (05 mg/ml) was administered. In III, IV and V groups 50, 100 and 150 mg. kg doses were administered to each rat respectively for 30 days. Similarly, VI, VII and VIII groups received the same doses respectively for 30 days. Before the start of experiment, the body weight of each rat was recorded. On day 31st, the rats of group I, III, IV and V were weighed and sacrificed.

The ovaries and uteri were dissected out, freed from surrounding tissues, blotted on filter paper and weighed quickly on a semi microbalance. For histopathological studies, the ovaries and uteri were fixed in Bouin's fluid and dehydrated, The paraffin sections of tissues were cut at 6 μ m. and stained with Ehrlich's haematoxylin and eosin.

RESULTS

Effects on body and genital organ weight: Table 1 displays the changes in body and genital organ weight of the rats. The rats of control group did not show any change in body weight and genital organ weight. It was maintained throughout the experimental period. No effect on body weight was observed at any dose of seed powder administered to albino rats. However, the genital organ weight was reduced significantly ($P < 0.05$) after the treatment at 100 and 150 mg/kg doses of seed powder for 30 days.

Effect on histology of genital organ:

Ovaries: The cellular organization of the ovaries of control rats presented normal features as evidenced by presence of all types of follicles, few atretic follicles,

corpora lutea and normal vascularity in compact stroma. The germinal epithelium was intact (Fig. 1). The dose 50 mg/kg for 30 days of administration caused no deleterious effect on ovarian tissues whereas 100 mg/kg dose within 30 days adversely affected the ovarian structure. Large number of developing as well as mature follicles underwent atresia. Some developing follicles showed lysis of their ova. The stroma was compact with poor vascularity (Fig. 2).

The dose 150 mg/kg appeared highly effective to cause degenerative changes in the ovary. The administration of this dose for 30 days caused severe damage to cellular organization. Even the large antric follicles underwent atresia and nuclear degeneration. The stroma became fibrotic with poor vasculature. The germinal epithelium was atrophied and devoid of primordial oocytes (Fig. 3).

Uterii: The uterine histology of the control rats presented normal structure. The endometrium was provided with large epithelial cells having basal and middle nuclei. The uterine glands were numerous, irregular and tortuous. The uterine lumen was highly distended and loose stroma with normal vascularity (Fig. 4). The dose 50 mg/kg for 30 days did not alter the endometrial height and uterine lumen. The uterine glands were irregular and tortuous. The stroma and vascularity appeared normal. At the dose 100 mg/kg, endometrial height appeared normal. No effect was noticed on musculature, stroma and vascularity. The uterine lumen was reduced significantly. Lack of uterine glands were also noted (Fig. 5). The administration of 150 mg/kg for 30 days caused great reduction in endometrial height. The uterine glands were shrunken. In the compact stroma, the vascularity was poor. The musculature was

also affected (Fig. 6).

Effect on fertility: Table 2 shows the effect of *S. xanthocarpum* seed on fertility of treated female rats and the control group of rats. All rats became pregnant and showed good number of implants. Treated with 50 mg/kg dose, only 20% of rats showed pregnancy and reduction of implants. The doses 100 and 150 mg/kg showed 100% antifertility activity and no implants were recorded in the horns of uteri of these rats on 10th day of pregnancy.

DISCUSSION

In the present study, no significant reduction in the weight of body was observed after 30 days of administration of seed powder *S. xanthocarpum*. A significant reduction in genital organ weight was noticed at 100 and 150 mg/kgs doses. The results noticed in the present study on histopathology of genital organs are comparable to the studies made by Chakraborti *et al.* (1968) when the female rats were fed with green leaves of *A. odoratissimus* Linn. Dixit (1977) reported the follicular degeneration and uterine dysfunction by daily administration (25 days) of *Malva viscus conzattii* flower extract. Follicular atresia and other changes were reported by Kholkute and Udupa (1974) and Kholkute *et al.* (1976) following the treatment of extract of *Hibiscus rosa sinensis* Linn. Flower. The histological changes in the uteri were reported by (Prakash, 1979) on administering the extracts of *Embelia ribes* Burm. Seeds in albino female rats. The present observations are in agreement with Munshi and Rao (1972) who had reported the effects on endometrial glands, musculature and uterine lumen in female rats after the application of an indigenous plant preparation ROC 101. Lal and Udupa (1993) also reported

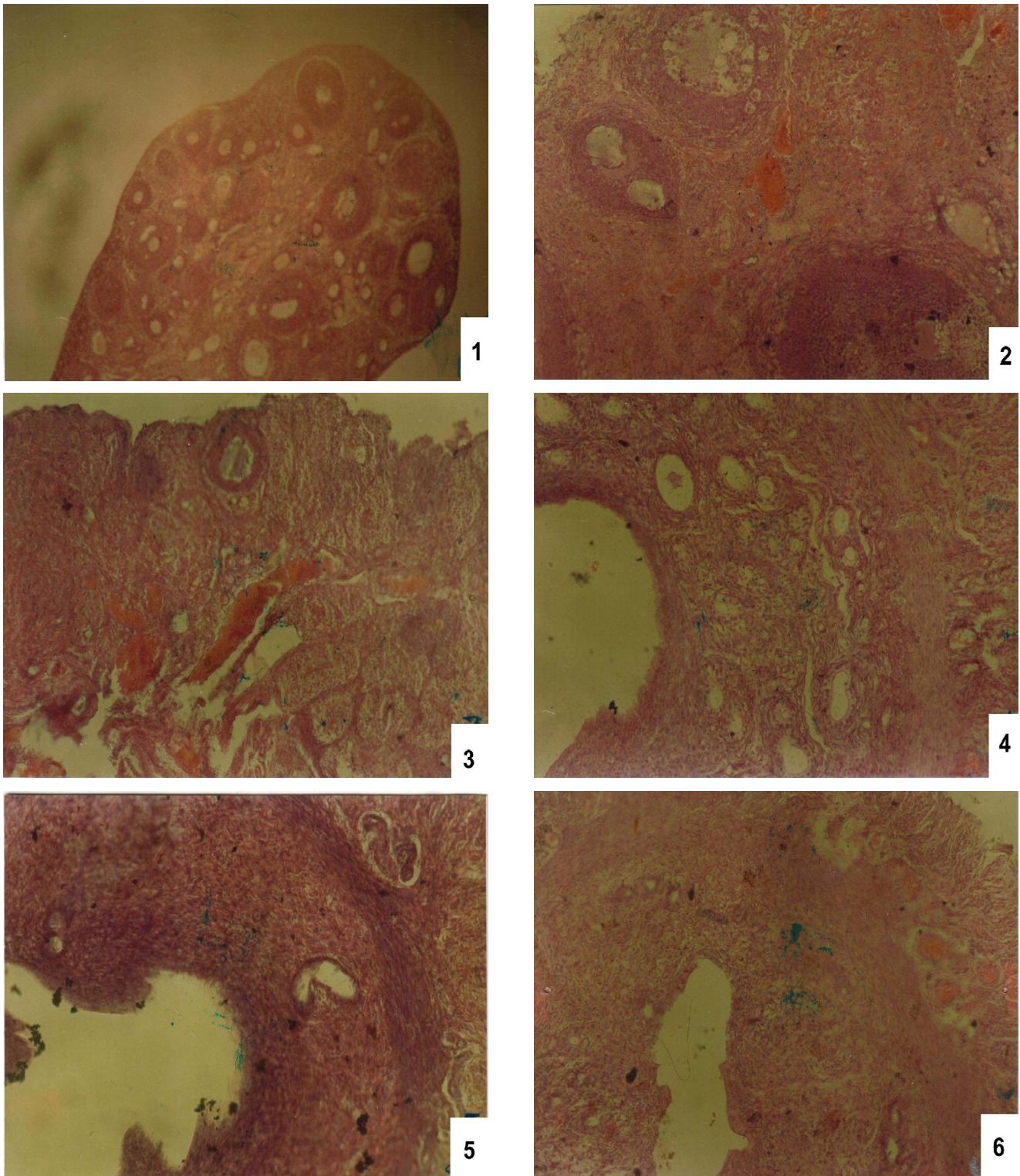
Table 1. Effect of *S. xanthocarpum* seed on body weight and genital organ weight of female albino rats treated for 30 days at different doses (mg/kg/day). 05 rats were included in each group. Values are mean \pm S.E.

Treatment	Doses (mg/kg)	Body weight (g)		Genital organ wt. (mg)	
		Initial	Final	Ovaries	Uterii
Control	Vehicle	159.00 \pm 0.71	183.80 \pm 0.45	39.40 \pm 0.92	107.00 \pm 1.12
<i>S. xanthocarpum</i> seed	50	157.00 \pm 0.84	170.20 \pm 2.24	35.90 \pm 0.80	102.50 \pm 0.20
<i>S. xanthocarpum</i> seed	100	160.60 \pm 2.15	165.00 \pm 2.11	27.50 \pm 0.40*	84.10 \pm 40.70*
<i>S. xanthocarpum</i> seed	150	157.10 \pm 4.89	163.40 \pm 2.16	26.00 \pm 0.30*	61.20 \pm 0.20*

*Significance: P < 0.05

Table 2. Antifertility activity of *S. xanthocarpum* seed in female albino rats. Values are mean \pm S.E.

Treatment/ Group	Doses (mg/kg)	Number of rats		% Antifertility activity	Number of implantations Mean \pm S.E.
		Mated	Pregnant on day 10 th		
Control	Vehicle	5	5	0	9.30 \pm 0.47
<i>S. xanthocarpum</i> seed	50	5	4	20	4.33 \pm 0.66
<i>S. xanthocarpum</i> seed	100	5	0	100	Nil
<i>S. xanthocarpum</i> seed	150	5	0	100	Nil



Figs. 1-6. Showing effects of *Solanum xanthocarpum* on ovary and uterus at different doses for 30 days of administration. (1) T.S. of Ovary of control albino rats with normal histo-architecture, all kinds of follicles, stroma and vascularity. X 100. (2) T.S. of ovary of treated albino rats with *S. xanthocarpum* 100 mg/kg/day for 30 days. Note the arrest of follicle development and degeneration of other parts. X 200. (3) T.S. of ovary of treated albino rats with *S. xanthocarpum* 150 mg/kg/day for 30 days. Note increased follicular atretia and total arrest of follicle development X200. (4) T.S. of uterus of controlled albino rats with normal histo-architecture, normal endometrium, columnar epithelium, loose stroma, vascularity and uterine glands. X 200. (5) T.S. of uterus of treated albino rats with *S. xanthocarpum* 100 mg/kg/day for 30 days. Note histopathological changes in endometrium uterine gland and vascularity. X 200. (6) T.S. of uterus of treated albino rats with *S. xanthocarpum* 150 mg/kg/day for 30 days. Note the atrophy of uterine glands, reeduced endometrium and loss of vascularity. X 200.

similar effect of the drug-Arjuna. Pathania *et al.* (2000) observed histological changes in ovary and uterus including oestrus cycle.

Bhardwaj and Mathur (1979) presented the results of an antifertility studies of *Cassia fistula* Linn. Fruit extracts on oestrus cycle, uterus and implantation. The higher doses showed encouraging activity which can be corroborated with the present study, Agarwal *et al.* (1980) found similar activity in fruits of *Juniperus communis* which resulted in 100% anti implantation at a dose of 500 mg/kg in female albino rats. Padmashali *et al.* (2006) tested fruits of *Balanites roxburghii* (crude extract) at doses of 300 and 600 mg/kg doses and found abortifacient. Similarly, Balamurugan *et al.* (2009) reported that *S. officinarum* L. (leaves) methanolic extract at a dose of 500 mg/kg for 21 days caused prevention of pregnancy. It is concluded that *S. xanthocarpum* seed powder inhibited the ovarian function, change the uterine structure and prevent the implantation, thus, control the fertility of female albino rats.

ACKNOWLEDGEMENT

This work was supported by U.G.C., New Delhi, No. F. 6 1(98) 2006 (MRP/ARCB).

REFERENCES

- Agarwal, O.P., Bhardwaj, S. and Mathur, R. (1980). Antifertility effects of fruits of *Juniperus communis*. *Planta Medica*. (Supl.), 98-101.
- Aswal, B.S.; Bhakuni, D.S.; Goel, A.K.; Kar, K.; Mehrotra, B.N. and Mukherjee, K. (1984). Screening of Indian plants for Biological activity. Part X. *Indian J. Exp. Biol.*, 22 : 312-332.
- Balamurugan, K., Kalaichelvan, V.K., Anuradha, G., Madhana Gopal, K., Meganathan, M. and Manavalan, R. (2009). Antifertility activity of Methanolic extract of *Saccharum officinarum* Linn. (leaves) on female albino rats. *Int. Pharm. Tech. Res.*, 1(4) : 1621-1634.
- Bhardwaj, S. and Mathur, R. (1979). Antifertility screening of fruits of *Cassia fistula* Linn. In female albino rats. *Comp. Physiol. Ecol.*, 4 (4) 277 - 279.
- Chaudhury, R.R. (1966). Plants with possible antifertility activity. Special report series No. 55, I.C.M.R., New Delhi.
- Chakraborti, B. Chaudhary, A. and Chaudhury, R.R. (1968). Antifertility effect of green leaves of *Artobotrys odoratissimus*. *J. Indian Med. Asso.*, 31 (5): 227 - 229.
- Dixit, V.P. (1977). Effect of Chronically administration of *Malva viscus* conzattii flower extract on the female genital tract of gerbil, *Merionis hurrianae*, Jerdon. *Indian J. Exp. Biol.*, 15 (8): 1650-1652.
- Dixit, V.P. and Gupta R.S. (1982). Antispermatogenic/antiandrogenic properties of solasodine obtained from *Solanum xanthocarpum* berries on the male genital tract of dog (*canis familiaris*) a histophysiological approach. *Intern. J. Androl.*, 4:1 - 8.
- Farnsworth, N.R., Bingel, A.S., Cordell, S.A., Crane, F.A. and Fong H.H.S. (1975). Potential value of plants as sources of new antifertility agents. I. *J. Pharma. Sci. U.S.A.*, 64 (4): 535 - 558.
- Jain, C.M. and Bharathi, K. (2011). Critical Review of Scientific validity of indigenous female contraceptive drugs described in Ayurvedic literature. *Indian J. Trad. Knowl.*, 10(4) : 678-681.
- Kholkute, S.D. and Udupa, K.N. (1974). Antifertility properties of *Hibiscus rosa sinensis* Linn. *J. Res. Indian Med.*, 9 (4): 99 - 102.
- Kholkute, S.D., Chatterjee, S. and Udupa, K.N. (1976). Effect of *Hibiscus rosa sinensis* Linn. on oestrus cycle and reproductive organs in rats. *Indian J. Exp. Biol.*, 14 (11): 703 - 704.
- Lal, B. and Udupa, K.N. (1993) . A preliminary study of antifertility effect of an indigenous drug – Arjuna (*Terminalia arjuna*). *Jour. Res. Ayur. Siddha*, 14(1) : 165-169.
- Munshi, S.R. and Rao, S.S. (1972). Antifertility activity of an indigenous plant preparation ROC 101. Effect on reproduction. *Indian J. Med. Res.* 60: 1054 - 1060.
- Padmashali, B.; Vaidya, V.P.; Vagdevi, H.M. and Satyanarayana, N.D. (2006). Antifertility efficacy of the plant *Balanites roxburghii* (Balanitaceae) in female rats. *Indian J. Pharma. Sci.*, 68(3) : 347-351.
- Pathania, P.C.; Singh, S.P. and Bhatia, D.K. (2000). Effect of *Lantana camara* Linn. leaves on ovarian and uterine histology, oestrus cycle and ovulation in Albino rats. *Indian Jour. Env. Sci.*, 4(1) : 53-60.
- Pokharkar, R.D.; Saraswat, R.K. and Sheetal Kotkar (2010). Survey of plants having antifertility activity from Western ghat area of Maharashtra state. *Jour. Herb Med. Toxicol.*, 4(2) : 71-75
- Prakash, A.O. (1979). Effect of *Embelia ribes* Burm. Extracts on the uterus of rat: a histological study. *Probe*, 18 (3): 178- 184.
- Rao, M.V. (1986). Effect of *Solanum xanthocarpum* seed extracts on reproductive organs of male rats. *Bio Sci. Res. Bull.*, 2: 22 - 28
- Rao, M.V. (1988). Effect of alcoholic extract of *Solanum xanthocarpum* seeds in adult male rats. *Indian J. Exp. Biol.*, 26: 95 - 98.
- Sharma, R.K., Chopra, G., Gyan Bhushan and Munjal, K. (2003). Use of Indian medicinal plants for infertility regulation in mammal. *J. Exp. Zool.*, 6(1) : 57-74.